

# MANUAL OF ANATOMY

PUBLISHED BY THE JOINT COMMITTEE OF HENRY FROWDE AND HODDER & STOUGHTON
AT THE OXFORD PRESS WAREHOUSE, FALCON SQUARE, LONDON, E.C.

# CUNNINGHAM'S MANUAL

OF

# PRACTICAL ANATOMY

REVISED AND EDITED BY

ARTHUR ROBINSON

PROFESSOR OF ANATOMY IN THE UNIVERSITY OF EDINBURGH

SIXTH EDITION

*VOLUME FIRST*

SUPERIOR EXTREMITY; INFERIOR EXTREMITY; ABDOMEN

*WITH 249 ILLUSTRATIONS IN THE TEXT AND 22 PLATES*
*SIX OF WHICH ARE IN COLOURS*

MC LIBRARY

NEW YORK

WILLIAM WOOD AND COMPANY

MDCCCCXIV

*Printed by* R. & R. CLARK, LIMITED, *Edinburgh.*

*1st Edition*, 1896.
*2nd Edition*, 1903.
*3rd Edition*, 1906.
*4th Edition*, 1907.
*5th Edition*, 1912.
*6th Edition*, 1914.

LAKE LIBRARY

*All rights reserved.*

# PREFACE TO SIXTH EDITION

For the purpose of this edition the whole of the text has been revised, some of the figures have been altered, several new figures have been introduced, and a series of radiographs of joints and other organs have been placed at the end of the volume, so that the student may familiarise himself with the very different appearances presented by dissected parts as contrasted with those produced by X-rays.

As in the case of the last edition, I am greatly indebted to my Senior Assistant, Dr. E. B. Jamieson, for help in the revision of the text and figs., and to my Second Assistant, Mr. T. B. Johnston, M.B., Ch.B., for dissections made to elucidate or confirm doubtful points.

The new figs. are reproduced from drawings made by Mr. J. T. Murray with his well-known skill.

ARTHUR ROBINSON.

104651

# CONTENTS

## THE SUPERIOR EXTREMITY.


| | PAGE |
|---|---|
| AXILLA, | 1 |
| DISSECTION OF THE BACK, | 37 |
| SHOULDER—SCAPULAR REGION, | 48 |
| FRONT OF THE ARM, | 62 |
| DORSUM OF THE ARM, | 83 |
| SHOULDER-JOINT, | 88 |
| FOREARM AND HAND, | 94 |
| VOLAR SURFACE AND MEDIAL BORDER OF THE FOREARM, | 97 |
| WRIST AND PALM, | 110 |
| DORSUM AND LATERAL BORDER OF THE FOREARM, | 132 |
| DORSAL ASPECT OF THE WRIST AND HAND, | 142 |
| ARTICULATIONS, | 148 |


## THE INFERIOR EXTREMITY.


| | |
|---|---|
| THE THIGH, | 166 |
| SUPERFICIAL DISSECTION OF THE THIGH, | 169 |
| DEEP DISSECTION OF THE THIGH, | 180 |
| MEDIAL SIDE OF THE THIGH, | 204 |
| GLUTEAL REGION, | 215 |
| POPLITEAL SPACE, | 234 |
| BACK OF THE THIGH, | 245 |
| THE LEG, | 257 |
| ANTERIOR CRURAL REGION AND DORSUM OF FOOT, | 259 |
| LATERAL CRURAL OR PERONEAL REGION, | 273 |
| MEDIAL CRURAL REGION, | 275 |
| POSTERIOR CRURAL REGION, | 276 |

PAGE
SOLE OF THE FOOT, . . . . . 289
ARTICULATIONS, . . . . . 310

## ABDOMEN.

MALE PERINEUM, . . . . . 340
ANAL TRIANGLE, . . . . . 345
UROGENITAL TRIANGLE . . . . . 349
FEMALE PERINEUM, . . . . . 364
ANAL TRIANGLE, . . . . . 369
UROGENITAL TRIANGLE, . . . . . 369
ABDOMINAL WALL, . . . . . 376
LUMBAR TRIANGLE AND LUMBAR FASCIA, . . . 418
HERNIA, . . . . . 420
ABDOMINAL CAVITY, . . . . . 426
VESSELS ON THE POSTERIOR WALL OF THE ABDOMEN, . 539
FASCIA AND MUSCLES ON THE POSTERIOR WALL OF THE ABDOMEN, . . . . . 547
NERVES ON THE POSTERIOR WALL OF THE ABDOMEN, . 550
PELVIS, . . . . . 555
MALE PELVIS, . . . . . 557
LIGAMENTS OF THE PELVIC ARTICULATIONS, . . . 612
THE FEMALE PELVIS, . . . . . 619
THE PELVIC BLOOD-VESSELS, . . . . . 646
THE VISCERAL NERVES OF THE PELVIS, . . . 647
THE PELVIC DIAPHRAGM, . . . . . 650

INDEX . . . . . 651

# A GLOSSARY

OF THE

# INTERNATIONAL (B.N.A.) ANATOMICAL TERMINOLOGY

## GENERAL TERMS.

### Terms indicating Situation and Direction.

| | | |
|---|---|---|
| Longitudinalis | Longitudinal | Referring to the long axis of the body. |
| Verticalis | Vertical | Referring to the position of the long axis of the body in the erect posture. |
| Anterior | Anterior | Referring to the front and back of the body or of the limbs. |
| Posterior | Posterior | |
| Ventral | Ventral | Referring to the anterior and posterior aspects, respectively, of the body, and to the flexor and extensor aspects of the limbs, respectively. |
| Dorsal | Dorsal | |
| Cranial | Cranial | Referring to position nearer the head or the tail end of the long axis. Used only in reference to parts of the head, neck, or trunk. |
| Caudal | Caudal | |
| Superior | Superior | Used in reference to the head, neck, and trunk. Equivalent to cranial and caudal respectively. |
| Inferior | Inferior | |
| Proximalis | Proximal | Used only in reference to the limbs. Proximal nearer the attached end. Distal nearer the free end. |
| Distalis | Distal | |
| Sagittalis | Sagittal | Used in reference to planes parallel with the sagittal suture of the skull, *i.e.* vertical antero-posterior planes. |
| Frontalis | Frontal | Used in reference to planes parallel with the coronal suture of the skull, *i.e.* transverse vertical planes. |

| | | |
|---|---|---|
| Horizontalis | Horizontal | Used in reference to planes at right angles to vertical planes. |
| Medianus | Median | Referring to the median vertical antero-posterior plane of the body. |
| Medialis | Medial | Referring to structures relatively nearer to or further away from the median plane. |
| Lateralis | Lateral | |
| Intermedius | Intermediate | Referring to structures situated between more medial and more lateral structures. |
| Superficialis | Superficial | Referring to structures nearer to and further away from the surface. |
| Profundus | Deep | |
| Externus | External | Referring, with few exceptions, to the walls of cavities and hollow organs. *Not* to be used as synonymous with medial and lateral. |
| Internus | Internal | |
| Ulnaris | Ulnar | Used in reference to the medial and lateral borders of the forearm, respectively. |
| Radialis | Radial | |
| Tibial | Tibial | Used in reference to the medial and lateral borders of the leg, respectively. |
| Fibular | Fibular | |

## THE BONES.

| B.N.A. Terminology. | Old Terminology. |
|---|---|
| **Vertebræ** | **Vertebræ** |
| Fovea costalis superior | Incomplete facet for head of rib, upper |
| Fovea costalis inferior | Incomplete facet for head of rib, lower |
| Fovea costalis transversalis | Facet for tubercle of the rib |
| Radix arcus vertebræ | Pedicle |
| **Atlas** | **Atlas** |
| Fovea dentis | Facet for odontoid process |
| **Epistropheus** | **Axis** |
| Dens | Odontoid process |
| **Sternum** | **Sternum** |
| Corpus sterni | Gladiolus |
| Processus xiphoideus | Ensiform process |
| Incisura jugularis | Supra-sternal notch |
| Planum sternale | Anterior surface |
| **Ossa Cranii.** | **Bones of Skull.** |
| **Os frontale** | **Frontal** |
| Spina frontalis | Nasal spine |
| Processus zygomaticus | External angular process |
| Facies cerebralis | Internal surface |
| Facies frontalis | Frontal surface |
| Pars orbitalis | Orbital plate |

| B.N.A. Terminology. | Old Terminology. |
|---|---|
| **Os parietale** | **Parietal** |
| Lineæ temporales | Temporal ridges |
| Sulcus transversus | Groove for lateral sinus |
| Sulcus sagittalis | Groove for sup. long. sinus |
| **Os occipitale** | **Occipital** |
| Canalis hypoglossi | Anterior condyloid foramen |
| Foramen occipitale magnum | Foramen magnum |
| Canalis condyloideus | Posterior condyloid foramen |
| Sulcus transversus | Groove for lateral sinus |
| Sulcus sagittalis | Groove for sup. long. sinus |
| Clivus | Median part of upper surface of basi-occipital |
| Linea nuchæ suprema | Highest curved line |
| Linea nuchæ superior | Superior curved line |
| Linea nuchæ inferior | Inferior curved line |
| **Os sphenoidale** | **Sphenoid** |
| Crista infratemporalis | Pterygoid ridge |
| Sulcus chiasmatis | Optic groove |
| Crista sphenoidalis | Ethmoidal crest |
| Spina angularis | Spinous process |
| Lamina medialis processus pterygoidei | Internal pterygoid plate |
| Lamina lateralis processus pterygoidei | External pterygoid plate |
| Canalis pterygoideus [Vidii] | Vidian canal |
| Fossa hypophyseos | Pituitary fossa |
| Sulcus caroticus | Cavernous groove |
| Conchæ sphenoidales | Sphenoidal turbinal bones |
| Hamulus pterygoideus | Hamular process |
| Canalis pharyngeus | Pterygo-palatine canal |
| Tuberculum sellæ | Olivary eminence |
| Fissura orbitalis superior | Sphenoidal fissure |
| **Os temporale** | **Temporal Bone** |
| Canalis facialis [Fallopii] | Aqueduct of Fallopius |
| Hiatus canalis facialis | Hiatus Fallopii |
| Vagina processus styloidei | Vaginal process of tympanic bone |
| Incisura mastoidea | Digastric fossa |
| Impressio trigemini | Impression for Gasserian ganglion |
| Eminentia arcuata | Eminence for sup. semicircular canal |
| Sulcus sigmoideus | Fossa sigmoidea |
| Fissura petrotympanica | Glaserian fissure |
| Fossa mandibularis | Glenoid cavity |
| Semicanalis tubæ auditivæ | Eustachian tube |
| **Os ethmoidale** | **Ethmoid** |
| Labyrinthus ethmoidalis | Lateral mass |
| Lamina papyracea | Os planum |
| Processus uncinatus | Unciform process |

| B.N.A. Terminology. | Old Terminology. |
|---|---|
| **Os lacrimale** | **Lachrymal Bone** |
| Hamulus lacrimalis | Hamular process |
| Crista lacrimalis posterior | Lachrymal crest |
| **Os nasale** | **Nasal Bone** |
| Sulcus ethmoidalis | Groove for nasal nerve |
| **Maxilla** | **Superior Maxillary Bone** |
| Facies anterior | Facial or external surface |
| Facies infra-temporalis | Zygomatic surface |
| Sinus maxillaris | Antrum of Highmore |
| Processus frontalis | Nasal process |
| Processus zygomaticus | Malar process |
| Canales alveolares | Posterior dental canals |
| Canalis naso-lacrimalis | Lacrimal groove |
| Os incisivum | Premaxilla |
| Foramen incisivum | Anterior palatine foramen |
| **Os palatinum** | **Palate Bone** |
| Pars perpendicularis | Vertical plate |
| Crista conchalis | Inferior turbinate crest |
| Crista ethmoidalis | Superior turbinate crest |
| Pars horizontalis | Horizontal plate |
| **Os zygomaticum** | **Malar Bone** |
| Processus temporalis | Zygomatic process |
| Processus fronto-sphenoidalis | Frontal process |
| Foramen zygomatico-orbitale | Tempora-malar canal |
| Foramen zygomatico-faciale | Malar foramen |
| **Mandibula** | **Inferior Maxillary Bone** |
| Spina mentalis | Genial tubercle or spine |
| Linea obliqua | External oblique line |
| Linea mylohyoidea | Internal oblique line |
| Incisura mandibulæ | Sigmoid notch |
| Foramen mandibulare | Inferior dental foramen |
| Canalis mandibulæ | Inferior dental canal |
| Protuberantia mentalis | Mental process |

## The Skull as a Whole.

| | |
|---|---|
| Ossa suturarum | Wormian bones |
| Foveolæ granulares (Pacchioni) | Pacchionian depressions |
| Fossa pterygo-palatina | Spheno-maxillary fossa |
| Canalis pterygo-palatinus | Posterior palatine canal |
| Foramen lacerum | Foramen lacerum medium |
| Choanæ | Posterior nares |
| Fissura orbitalis superior | Sphenoidal fissure |
| Fissura orbitalis inferior | Spheno-maxillary fissure |

## Upper Extremity.

| B.N.A. Terminology. | Old Terminology. |
|---|---|
| **Clavicula** | **Clavicle** |
| Tuberositas coracoidea | Impression for conoid ligament |
| Tuberositas costalis | Impression for rhomboid ligament |
| **Scapula** | **Scapula** |
| Incisura scapularis | Supra-scapular notch |
| Angulus lateralis | Anterior or lateral angle |
| Angulus medialis | Superior angle |
| **Humerus** | **Humerus** |
| Sulcus intertubercularis | Bicipital groove |
| Crista tuberculi majoris | External lip |
| Crista tuberculi minoris | Internal lip |
| Facies anterior medialis | Internal surface |
| Facies anterior lateralis | External surface |
| Margo medialis | Internal border |
| Margo lateralis | External border |
| Sulcus nervi radialis | Musculo-spiral groove |
| Capitulum | Capitellum |
| Epicondylus medialis | Internal condyle |
| Epicondylus lateralis | External condyle |
| **Ulna** | **Ulna** |
| Incisura semilunaris | Greater sigmoid cavity |
| Incisura radialis | Lesser sigmoid cavity |
| Crista interossea | External or interosseous border |
| Facies dorsalis | Posterior surface |
| Facies volaris | Anterior surface |
| Facies medialis | Internal surface |
| Margo dorsalis | Posterior border |
| Margo volaris | Anterior border |
| **Radius** | **Radius** |
| Tuberositas radii | Bicipital tuberosity |
| Incisura ulnaris | Sigmoid cavity |
| Crista interossea | Internal or interosseous border |
| Facies dorsalis | Posterior surface |
| Facies volaris | Anterior surface |
| Facies lateralis | External surface |
| Margo dorsalis | Posterior border |
| Margo volaris | Anterior border |
| **Carpus** | **Carpus** |
| **Os naviculare** | **Scaphoid** |
| **Os lunatum** | **Semilunar** |
| **Os triquetrum** | **Cuneiform** |
| **Os multangulum majus** | **Trapezium** |
| **Os multangulum minus** | **Trapezoid** |
| **Os capitatum** | **Os magnum** |
| **Os hamatum** | **Unciform** |

## Lower Extremity.

| B.N.A. Terminology. | Old Terminology. |
|---|---|
| **Os coxæ** | **Innominate Bone** |
| Linea glutæa anterior | Middle curved line |
| Linea glutæa posterior | Superior curved line |
| Linea terminalis | Margin of inlet of true pelvis |
| Spina ischiadica | Spine of the ischium |
| Incisura ischiadica major | Great sacro-sciatic notch |
| Incisura ischiadica minor | Lesser sacro-sciatic notch |
| Tuberculum pubicum | Spine of pubis |
| Ramus inferior oss. pubis | Descending ramus of pubis |
| Ramus superior oss. pubis | Ascending ramus of pubis |
| Ramus superior ossis ischii | Body of ischium |
| Ramus inferior oss. ischii | Ramus of ischium |
| Pecten ossis pubis | Pubic part of ilio-pectineal line |
| Facies symphyseos | Symphysis pubis |
| **Pelvis** | **Pelvis** |
| Pelvis major | False pelvis |
| Pelvis minor | True pelvis |
| Apertura pelvis minoris superior | Pelvic inlet |
| Apertura pelvis minoris inferior | Pelvic outlet |
| Linea terminalis | Margin of inlet of true pelvis |
| **Femur** | **Femur** |
| Fossa trochanterica | Digital fossa |
| Linea intertrochanterica | Spiral line |
| Crista intertrochanterica | Post. intertrochanteric line |
| Condylus medialis | Inner condyle |
| Condylus lateralis | Outer condyle |
| Epicondylus medialis | Inner tuberosity |
| Epicondylus lateralis | Outer tuberosity |
| **Tibia** | **Tibia** |
| Condylus medialis | Internal tuberosity |
| Condylus lateralis | External tuberosity |
| Eminentia intercondyloidea | Spine |
| Tuberositas tibiæ | Tubercle |
| Malleolus medialis | Internal malleolus |
| **Fibula** | **Fibula** |
| Malleolus lateralis | External malleolus |
| Apex capituli fibulæ | Styloid process |

## Bones of the Foot.

| | |
|---|---|
| **Talus** | **Astragalus** |
| **Calcaneus** | **Os calcis** |
| Tuber calcanei | Tuberosity of |
| Processus medialis tuberis calcanei | Inner |
| Processus lateralis tuberis calcanei | Outer |
| **Os cuneiforme primum** | **Inner cuneiform** |
| **Os cuneiforme secundum** | **Middle cuneiform** |
| **Os cuneiforme tertium** | **Outer cuneiform** |

# THE LIGAMENTS.

## Ligaments of the Spine.

| B.N.A. Terminology. | Old Terminology. |
|---|---|
| Lig. longitudinale anterius | Anterior common ligament |
| Lig. longitudinale posterius | Posterior common ligament |
| Lig. flava | Ligamenta subflava |
| Membrana tectoria | Posterior occipito-axial ligament |
| Articulatio atlanto-epistrophica | Joint between the atlas and the axis |
| Lig. alaria | Odontoid or check ligaments |
| Lig. apicis dentis | Suspensory ligament |

## The Ribs.

| | |
|---|---|
| Lig. capituli costæ radiatum | Anterior costo-vertebral or stellate ligament |
| Lig. sterno-costale interarticulare | Interarticular chondro-sternal ligament |
| Lig. sterno-costalia radiata | Anterior and posterior chondro-sternal ligament |
| Lig. costoxiphoidea | Chondro-xiphoid ligaments |

## The Jaw.

| | |
|---|---|
| Lig. temporo-mandibulare | External lateral ligament of the jaw |
| Lig. spheno-mandibulare | Internal lateral ligament of the jaw |
| Lig. stylo-mandibulare | Stylo-maxillary ligament |

## Upper Extremity.

| | |
|---|---|
| Lig. costo-claviculare | Rhomboid ligament |
| Labrum glenoidale | Glenoid ligament |
| Articulatio radio-ulnaris proximalis | Superior radio-ulnar joint |
| Lig. collaterale ulnare | Internal lateral ligament of elbow-joint |
| Lig. collaterale radiale | External lateral ligament |
| Lig. annulare radii | Orbicular ligament |
| Chorda obliqua | Oblique ligament of ulna |
| Articulatio radio-ulnaris distalis | Inferior radio-ulnar joint |
| Discus articularis | Triangular fibro-cartilage |
| Recessus sacciformis | Membrana sacciformis |
| Lig. radio-carpeum volare | Anterior ligament of the radio-carpal joint |
| Lig. radio-carpeum dorsale | Posterior ligament of the radio-carpal joint |
| Lig. collaterale carpi ulnare | Internal lateral ligament of the wrist joint |

| B.N.A. Terminology. | Old Terminology. |
|---|---|
| Lig. collaterale carpi radiale | External lateral ligament of the wrist joint |
| Articulationes intercarpæ | Carpal joints |
| Lig. accessoria volaria | Palmar ligaments of the metacarpo-phalangeal joints |
| Lig. capitulorum (oss. metacarpalium) transversa | Transverse metacarpal ligament |
| Lig. collateralia | Lateral phalangeal ligaments |

## The Lower Extremity.

| | |
|---|---|
| Lig. arcuatum | Subpubic ligament |
| Lig. sacro-tuberosum | Great sacro-sciatic ligament |
| Processus falciformis | Falciform process |
| Lig. sacro-spinosum | Small sacro-sciatic ligament |
| Labrum glenoidale | Cotyloid ligament |
| Zona orbicularis | Zonular band |
| Ligamentum iliofemorale | Y-shaped ligament |
| Lig. ischio-capsulare | Ischio-capsular band |
| Lig. pubo-capsulare | Pubo-femoral ligament |
| Lig. popliteum obliquum | Ligament of Winslow |
| Lig. collaterale fibulare | Long external lateral ligament |
| Lig. collaterale tibiale | Internal lateral ligament |
| Lig. popliteum arcuatum | Arcuate popliteal ligament |
| Meniscus lateralis | External semilunar cartilage |
| Meniscus medialis | Internal semilunar cartilage |
| Plica synovialis patellaris | Lig. mucosum |
| Plicæ alares | Ligamenta alaria |
| Articulatio tibio-fibularis | Superior tibio-fibular articulation |
| Lig. capituli fibulæ | Anterior and posterior superior tibio-fibular ligaments |
| Syndesmosis tibio-fibularis | Inferior tibio-fibular articulation |
| Lig. deltoideum | Internal lateral ligament of ankle |
| Lig. talo-fibulare anterius | Anterior fasciculus of external lateral ligament |
| Lig. talo-fibulare posterius | Posterior fasciculus of external lateral ligament |
| Lig. calcaneo-fibulare | Middle fasciculus of external lateral ligament |
| Lig. talo-calcaneum laterale | External calcaneo-astragaloid ligament |
| Lig. talo-calcaneum mediale | Internal calcaneo-astragaloid ligament |
| Lig. calcaneo-naviculare plantare | Inferior calcaneo-navicular ligament |
| Lig. talo-naviculare | Astragalo-scaphoid ligament |
| Pars calcaneo-navicularis } lig. bifurcatum | Superior calcaneo-scaphoid ligament |
| Pars calcaneo-cuboidea } lig. bifurcatum | Internal calcaneo-cuboid ligament |

# THE MUSCLES.

## Muscles of the Back.

### Superficial.

| B.N.A. Terminology. | Old Terminology. |
|---|---|
| Levator scapulæ | Levator anguli scapulæ |

## Muscles of the Chest.

| | |
|---|---|
| Serratus anterior | Serratus magnus |

## Muscles of Upper Extremity.

| | |
|---|---|
| Biceps brachii | Biceps |
| Lacertus fibrosus | Bicipital fascia |
| Brachialis | Brachialis anticus |
| Triceps brachii | Triceps |
| Caput mediale | Inner head |
| Caput laterale | Outer head |
| Pronator teres | Pronator radii teres |
| Caput ulnare | Coronoid head |
| Brachio-radialis | Supinator longus |
| Supinator | Supinator brevis |
| Extensor carpi radialis longus | Extensor carpi radialis longior |
| Extensor carpi radialis brevis | Extensor carpi radialis brevior |
| Extensor indicis proprius | Extensor indicis |
| Extensor digiti quinti proprius | Extensor minimi digiti |
| Abductor pollicis longus | Extensor ossis metacarpi pollicis |
| Abductor pollicis brevis | Abductor pollicis |
| Extensor pollicis brevis | Extensor primi internodii pollicis |
| Extensor pollicis longus | Extensor secundi internodii pollicis |
| Lig. carpi transversum | Anterior annular ligament |
| Lig. carpi dorsale | Posterior annular ligament |

## Muscles of Lower Extremity.

| | |
|---|---|
| Tensor fasciæ latæ | Tensor fasciæ femoris |
| Canalis adductorius (Hunteri) | Hunter's canal |
| Trigonum femorale (fossa Scarpæ major) | Scarpa's triangle |
| Canalis femoralis | Crural canal |
| Annulus femoralis | Crural ring |
| M. quadriceps femoris— | Quadriceps— |
| Rectus femoris | Rectus femoris |
| Vastus lateralis | Vastus externus |
| Vastus intermedius | Crureus |
| Vastus medialis | Vastus internus |
| M. articularis genu | Subcrureus |
| Tibialis anterior | Tibialis anticus |

| B.N.A. Terminology. | Old Terminology. |
|---|---|
| Tendo calcaneus | Tendo Achillis |
| Tibialis posterior | Tibialis posticus |
| Quadratus plantæ | Accessorius |
| Lig. transversum cruris | Upper anterior annular ligament |
| Lig. cruciatum cruris | Lower anterior annular ligament |
| Lig. laciniatum | Internal annular ligament |
| Retinaculum musculorum peronæorum superius | External annular ligament |
| Retinaculum musculorum peronæorum inferius | |

## Axial Muscles.

### Muscles of the Back.

| | |
|---|---|
| Serratus posterior superior | Serratus posticus superior |
| Serratus posterior inferior | Serratus posticus inferior |
| Splenius cervicis | Splenius colli |
| Sacro-spinalis | Erector spinæ |
| **Ilio-costalis—** | **Ilio-costalis—** |
| Lumborum | Sacro-lumbalis |
| Dorsi | Accessorius |
| Cervicis | Cervicalis ascendens |
| **Longissimus—** | **Longissimus—** |
| Dorsi | Dorsi |
| Cervicis | Transversalis cervicis |
| Capitis | Trachelo-mastoid |
| **Spinalis—** | **Spinalis—** |
| Dorsi | Dorsi |
| Cervicis | Colli |
| Capitis | Capitis |
| **Semispinalis—** | **Semispinalis—** |
| Dorsi | Dorsi |
| Cervicis | Colli |
| Capitis | Complexus |
| Multifidus | Multifidus spinæ |

### Muscles of Head and Neck.

| | |
|---|---|
| Epicranius | Occipito-frontalis |
| Galea aponeurotica | Epicranial aponeurosis |
| Procerus | Pyramidalis nasi |
| Pars transversa (nasalis) | Compressor naris |
| Pars alaris (nasalis) | Dilatores naris |
| Auricularis anterior | Attrahens aurem |
| Auricularis posterior | Retrahens aurem |
| Auricularis superior | Attollens aurem |
| Orbicularis oculi | Orbicularis palpebrarum |
| Pars lacrimalis | Tensor tarsi |

| B.N.A. Terminology. | Old Terminology. |
|---|---|
| Triangularis | Depressor anguli oris |
| Quadratus labii superioris— | |
| Caput zygomaticum | Zygomaticus minor |
| Caput infraorbitale | Levator labii superioris |
| Caput angulare | Levator labii superioris alæque nasi |
| Zygomaticus | Zygomaticus major |
| Caninus | Levator anguli oris |
| Quadratus labii inferioris | Depressor labii inferioris |
| Mentalis | Levator menti |
| Platysma | Platysma myoides |
| Sterno-thyreoid | Sterno-thyroid |
| Thyreo-hyoid | Thyro-hyoid |

## Muscles and Fascia of the Orbit.

| | |
|---|---|
| Fascia bulbi | Capsule of Tenon |
| Septum orbitale | Palpebral ligaments |
| Rectus lateralis | Rectus externus |
| Rectus medialis | Rectus internus |

## Muscles of the Tongue.

| | |
|---|---|
| Genio-glossus | Genio-hyo-glossus |
| Longitudinalis superior | Superior lingualis |
| Longitudinalis inferior | Inferior lingualis |
| Transversus linguæ | Transverse fibres |
| Verticalis linguæ | Vertical fibres |

## Muscles of the Pharynx.

| | |
|---|---|
| Pharyngo-palatinus | Palato-pharyngeus |
| M. uvulæ | Azygos uvulæ |
| Levator veli palatini | Levator palati |
| Tensor veli palatini | Tensor palati |
| Glosso-palatinus | Palato-glossus |

## Deep Lateral Muscles of Neck.

| | |
|---|---|
| Scalenus anterior | Scalenus anticus |
| Scalenus posterior | Scalenus posticus |
| Longus capitis | Rectus capitis anticus major |
| Rectus capitis anterior | Rectus capitis anticus minor |

## Muscles of Thorax.

| | |
|---|---|
| Transversus thoracis | Triangularis sterni |
| Diaphragma pars lumbalis | Diaphragm, lumbar part— |
| Crus mediale, Crus intermedium, Crus laterale | Crura and origins from arcuate ligaments |
| Arcus lumbo-costalis medialis (Halleri) | Ligamentum arcuatum internum |
| Arcus lumbo-costalis lateralis (Halleri) | Ligamentum arcuatum externum |

## Muscles of the Abdomen.

| B.N.A. Terminology. | Old Terminology. |
|---|---|
| Ligamentum inguinale (Pouparti) | Poupart's ligament |
| Ligamentum lacunare (Gimbernati) | Gimbernat's ligament |
| Fibræ intercrurales | Intercolumnar fibres |
| Ligamentum inguinale reflexum (Collesi) | Triangular fascia |
| Annulus inguinalis subcutaneus | External abdominal ring |
| Crus superius | Internal pillar |
| Crus inferius | External pillar |
| Falx aponeurotica inguinalis | Conjoined tendon |
| M. transversus abdominis | Transversalis muscle |
| Linea semicircularis (Douglasi) | Fold of Douglas |
| Annulus inguinalis abdominalis | Internal abdominal ring |

## Perineum and Pelvis.

| | |
|---|---|
| Transversus perinei superficialis | Transversus perinei |
| M. sphincter urethræ membranaceæ | Compressor urethræ |
| Diaphragma urogenitale | Deep transverse muscle and sphincter urethræ |
| Fascia diaphragmatis urogenitalis superior | Deep layer of triangular ligament |
| Fascia diaphragmatis urogenitalis inferior | Superficial layer of the triangular ligament |
| Arcus tendineus fasciæ pelvis | White line of pelvis |
| Ligamenta puboprostatica | Anterior and lateral true ligaments of bladder |
| Fascia diaphragmatis pelvis superior | Visceral layer of pelvic fascia |
| Fascia diaphragmatis pelvis inferior | Anal fascia |

# THE NERVOUS SYSTEM.

## Spinal Cord.

| | |
|---|---|
| Fasciculus anterior proprius (Flechsig) | Anterior ground or basis bundle |
| Fasciculus lateralis proprius | Lateral ground bundle |
| Nucleus dorsalis | Clarke's column |
| Pars thoracalis | Dorsal part of spinal cord |
| Sulcus intermedius posterior | Paramedian furrow |
| Columnæ anteriores, etc. | Anterior grey column |
| Fasciculus cerebro-spinalis anterior | Direct pyramidal tract |
| Fasciculus cerebro-spinalis lateralis (pyramidalis) | Crossed pyramidal tract |
| Fasciculus cerebello-spinalis | Direct cerebellar tract |
| Fasciculus antero-lateralis superficialis | Gowers' tract |

**The Brain** or **Encephalon** is divided into parts as follows :—

- **RHOMBENCEPHALON** = Myelencephalon (medulla) (after-brain) + Metencephalon (pons and cerebellum) (hind-brain) } Posterior primary vesicle.
- **CEREBRUM** = **MESENCEPHALON** (mid-brain, peduncles, corpora quadrigemina, etc.)—Middle primary vesicle.
- **PROSENCEPHALON** (fore-brain)
  - **Diencephalon** = Thalamencephalon (inter-brain)
    - Thalamus (optic thalamus).
    - Metathalamus (geniculate bodies).
    - Epithalamus (pineal body).
    - Mammillary portion of hypothalamus (subthalamic region).
    - Posterior part of 3rd ventricle.
  - **Telencephalon**
    - Optic portion of hypothalamus (hypophysis).
    - Optic nerves.
    - Anterior part of 3rd ventricle.
    - Pallium (cortex cerebri).
    - Lateral ventricles.

## Brain.

| B.N.A. Terminology. | Old Terminology. |
|---|---|
| **Rhombencephalon** | |
| Eminentia medialis | Eminentia teres |
| Ala cinerea | Trigonum vagi |
| Ala acustica | Trigonum acusticum |
| Nucleus nervi abducentis | Nucleus of 6th nerve |
| Nuclei n. acustici | Auditory nucleus |
| Fasciculus longitudinalis medialis | Posterior longitudinal bundle |
| Corpus trapezoideum | Corpus trapezoides |
| Incisura cerebelli anterior | Semilunar notch (of cerebellum) |
| Incisura cerebelli posterior | Marsupial notch |
| Sulcus horizontalis cerebelli | Great horizontal fissure |
| Lobulus centralis | Lobus centralis |
| Folium vermis | Folium cacuminis |
| Tuber vermis | Tuber valvulæ |
| Lobulus quadrangularis | Quadrate lobule |
| Brachium conjunctivum cerebelli | Superior cerebellar peduncle |
| Lobulus semilunaris superior | Postero-superior lobule |
| Lobulus semilunaris inferior | Postero-inferior lobule |
| **Cerebrum** | |
| Pedunculus cerebri | Crus cerebri |
| Colliculus superior | Anterior corpus quadrigeminum |
| Colliculus inferior | Posterior corpus quadrigeminum |
| Aqueductus cerebri | Iter e tertio ad quartum ventriculum, or aqued. of Sylvius |
| Foramen interventriculare | Foramen of Monro |
| Hypothalamus | Subthalmic region |
| Sulcus hypothalamicus | Sulcus of Monro |
| Massa intermedia | Middle commissure |
| Fasciculus thalamo-mammillaris | Bundle of Vicq d'Azyr |
| Pars opercularis | Pars basilaris |
| Thalamus | Optic thalamus |
| Pallium | Cortex cerebri |
| Gyri transitivi | Annectant gyri |
| Fissura cerebri lateralis | Fissure of Sylvius |
| Gyrus temporalis superior | First temporal gyrus |
| Gyrus temporalis medius | Second temporal gyrus |
| Gyrus temporalis inferior | Third temporal gyrus |
| Sulcus centralis (Rolandi) | Fissure of Rolando |
| Sulcus temporalis superior | Parallel sulcus |
| Sulcus temporalis medius | Second temporal sulcus |
| Sulcus circularis | Limiting sulcus of Reil |
| Sulcus temporalis inferior | Occipito-temporal sulcus |
| Gyrus fusiformis | Occipito-temporal convolution |
| Sulcus interparietalis | Intraparietal sulcus |
| Sulcus corporis callosi | Callosal sulcus |
| Sulcus cinguli | Calloso-marginal fissure |
| Fissura hippocampi | Dentate fissure |
| Gyrus cinguli | Callosal convolution |

| B.N.A. Terminology. | Old Terminology. |
|---|---|
| Stria terminalis | Tænia semicircularis |
| Trigonum collaterale | Trigonum ventriculi |
| Hippocampus | Hippocampus major |
| Digitationes hippocampi | Pes hippocampi |
| Fascia dentata hippocampi | Gyrus dentatus |
| Columna fornicis | Anterior pillar of fornix |
| Septum pellucidum | Septum lucidum |
| Inferior cornu | Descending horn of lateral ventricle |
| Commissura hippocampi | Lyra |
| Nucleus lentiformis | Lenticular nucleus |
| Pars frontalis capsulæ internæ | Anterior limb (of internal capsule) |
| Pars occipitalis capsulæ internæ | Posterior limb (of internal capsule) |
| Radiatio occipito-thalamica | Optic radiation |
| Radiatio corporis callosi | Radiation of corpus callosum |
| Pars frontalis | Forceps minor |
| Pars occipitalis | Forceps major |

## Membranes of Brain.

| | |
|---|---|
| Cisterna cerebello-medullaris | Cisterna magna |
| Cisterna interpeduncularis | Cisterna basalis |
| Granulationes arachnoideales | Pacchionian bodies |
| Tela chorioidea ventriculi tertii | Velum interpositum |
| Tela chorioidea ventriculi quarti | Tela choroidea inferior |

## Cerebral Nerves.

| | |
|---|---|
| N. oculomotorius | Third nerve |
| N. trochlearis | Fourth nerve |
| N. trigeminus | Fifth nerve |
| Ganglion semilunare (Gasseri) | Gasserian ganglion |
| N. naso-ciliaris | Nasal nerve |
| N. maxillaris | Superior maxillary nerve |
| N. meningeus (medius) | Recurrent meningeal nerve |
| N. zygomaticus | Temporo-malar nerve |
| Rami alveolares superiores posteriores | Posterior superior dental |
| Rami alveolares superiores medii | Middle superior dental |
| Rami alveolares superiores anteriores | Anterior superior dental |
| Ganglion spheno-palatinum | Meckel's ganglion |
| N. palatinus medius | External palatine nerve |
| N. mandibularis | Inferior maxillary nerve |
| Nervus spinosus | Recurrent nerve |
| N. alveolaris inferior | Inferior dental |
| N. abducens | Sixth nerve |
| N. facialis | Seventh nerve |
| N. intermedius | Pars intermedia of Wrisberg |
| N. acusticus | Eighth or auditory nerve |

| B.N.A. Terminology. | Old Terminology. |
|---|---|
| Ganglion superius | Jugular ganglion of 9th nerve |
| N. recurrens | Recurrent laryngeal nerve |
| Ganglion jugulare | Ganglion of root of vagus |
| Ganglion nodosum | Ganglion of trunk of vagus |
| Plexus œsophageus anterior / Plexus œsophageus posterior | Plexus gulæ |
| Nervus accessorius | Spinal accessory |
| Ramus internus | Accessory portion of spinal accessory nerve |
| Ramus externus | Spinal portion |

## Spinal Nerves.

| | |
|---|---|
| Rami posteriores | Posterior primary divisions |
| Rami anteriores | Anterior primary divisions |
| N. cutaneus colli | Superficial cervical nerve |
| Nn. supraclaviculares anteriores | Suprasternal nerves |
| Nn. supraclaviculares medii | Supraclavicular nerves |
| Nn. supraclaviculares posteriores | Supra-acromial nerves |
| N. dorsalis scapulæ | Nerve to the rhomboids |
| Nn. intercosto-brachiales | Intercosto-humeral nerve |
| N. thoracalis longus | Nerve of Bell |
| N. thoraco-dorsalis | Long subscapular nerve |
| N. cutaneus brachii medialis | Lesser internal cutaneous nerve |
| N. cutaneus brachii lateralis | Cutaneous branch of circumflex nerve |
| Fasciculus lateralis | Outer cord (of plexus) |
| Fasciculus medialis | Inner cord |
| N. cutaneus antibrachii lateralis | Cutaneous branch of musculo-cutaneous nerve |
| N. cutaneus antibrachii medialis | Internal cutaneous nerve |
| Ramus volaris | Anterior branch |
| Ramus ulnaris | Posterior branch |
| N. cutaneus antibrachii dorsalis | External cutaneous branch of musculo-spiral |
| N. axillaris | Circumflex nerve |
| N. interosseus volaris | Anterior interosseous |
| Ramus palmaris N. mediani | Palmar cutaneous branch of the median nerve |
| Nn. digitales volares proprii | Collateral palmar digital branches of median nerve |
| Ramus dorsalis manus | Dorsal cutaneous branch of ulnar nerve |
| Ramus cutaneus palmaris | Palmar cutaneous branch of ulnar nerve |
| N. radialis | Musculo-spiral nerve |
| N. cutaneus brachii posterior | Internal cutaneous branch of musculo-spiral nerve |
| N. cutaneus antibrachii dorsalis | External cutaneous branches of musculo-spiral nerve |

| B.N.A. Terminology. | Old Terminology. |
|---|---|
| N. radialis (*contd.*)— | Musculo-spiral nerve (*contd.*)— |
| Ramus superficialis | Radial nerve |
| N. interosseus dorsalis | Posterior interosseous nerve |
| Nn. digitales dorsales | Dorsal digital nerves |
| N. ilio-hypogastricus | Ilio-hypogastric nerve |
| Ramus cutaneus lateralis | Iliac branch of ilio-hypogastric nerve |
| Ramus cutaneus anterior | Hypogastric branch of ilio-hypogastric nerve |
| N. genito-femoralis | Genito-crural nerve |
| N. lumbo-inguinalis | Crural branch of genito-crural nerve |
| N. spermaticus externus | Genital branch of genito-crural nerve |
| N. cutaneus femoris lateralis | External cutaneous nerve |
| N. femoralis | Anterior crural nerve |
| N. saphenus | Long saphenous nerve |
| Ramus infrapatellaris | Patellar branch of long saphenous nerve |
| N. ischiadicus | Great sciatic nerve |
| N. peronæus communis | External popliteal nerve |
| Ramus anastomoticus peronæus | Nervus communicans fibularis |
| N. peronæus superficialis | Musculo-cutaneous nerve |
| N. peronæus profundus | Anterior tibial nerve |
| N. tibialis | Internal popliteal nerve |
| N. cutaneus suræ medialis | Nervus communicans tibialis |
| N. suralis | Short saphenous nerve |
| N. plantaris medialis | Internal plantar |
| N. plantaris lateralis | External plantar |
| N. pudendus | Pudic nerve |

## THE HEART AND BLOOD-VESSELS.

### Heart.

| | |
|---|---|
| Atrium | Auricle |
| Auricula cordis | Auricular appendix |
| Incisura cordis | Notch at apex of heart |
| Trabeculæ carneæ | Columnæ carneæ |
| Tuberculum intervenosum | Intervenous tubercle of Lower |
| Sulcus longitudinalis anterior | Anterior interventricular groove |
| Sulcus coronarius | Auriculo-ventricular groove |
| Limbus fossæ ovalis | Annulus ovalis |
| Valvula venæ cavæ | Eustachian valve |
| Valvula sinus coronarii | Valve of Thebesius |

## Arteries.

| B.N.A. Terminology. | Old Terminology. |
|---|---|
| Sinus aortæ | Sinuses of Valsalva |
| A. profunda linguæ | Ranine artery |
| A. maxillaris externa | Facial artery |
| A. alveolaris inferior | Inferior dental artery |
| Ramus meningeus accessorius | Small meningeal artery |
| A. buccinatoria | Buccal artery |
| A. alveolaris superior posterior | Posterior dental artery |
| Aa. alveolares superiores anteriores | Anterior superior dental arteries |
| Ramus carotico-tympanicus | Tympanic branch of int. carotid |
| A. chorioidea | Anterior choroidal artery |
| A. auditiva interna | Auditory artery |
| Rami ad pontem | Transverse arteries (branches of Basilar artery) |
| A. pericardiaco-phrenica | Arteria comes nervi phrenici |
| Rami intercostales | Anterior intercostal arteries |
| Truncus thyreo-cervicalis | Thyroid axis |
| A. transversa scapulæ | Suprascapular artery |
| A. intercostalis suprema | Superior intercostal |
| A. transversa colli | Transversalis colli |
| A. thoracalis suprema | Superior thoracic artery |
| A. thoraco-acromialis | Acromio-thoracic artery |
| A. thoracalis lateralis | Long thoracic artery |
| A. circumflexa scapulæ | Dorsalis scapulæ |
| A. profunda brachii | Superior profunda |
| A. collateralis radialis | Anterior branch of superior profunda |
| A. collateralis ulnaris superior | Inferior profunda |
| A. collateralis ulnaris inferior | Anastomotica magna |
| Ramus carpeus volaris | Anterior radial carpal |
| Ramus carpeus dorsalis | Posterior radial carpal |
| Aa. metacarpeæ dorsales | Dorsal interosseous arteries |
| A. volaris indicis radialis | Radialis indicis |
| Arcus volaris superficialis | Superficial palmar arch |
| Arcus volaris profundus | Deep palmar arch |
| A. interossea dorsalis | Posterior interosseous artery |
| A. interossea recurrens | Posterior interosseous recurrent artery |
| A. interossea volaris | Anterior interosseous artery |
| Ramus carpeus dorsalis | Posterior ulnar carpal |
| Ramus carpeus volaris | Anterior ulnar carpal |
| Aa. digitales volares communes | Palmar digital arteries |
| Aa. digitales volares propriæ | Collateral digital arteries |
| Arteriæ intestinales | Intestinal branches of sup. mesenteric |
| A. suprarenalis media | Middle capsular artery |
| A. hypogastrica | Internal iliac artery |
| A. umbilicalis | Obliterated hypogastric |
| A. pudenda interna | Internal pudic artery |
| A. epigastrica inferior | Deep epigastric artery |

| B.N.A. Terminology. | Old Terminology. |
|---|---|
| A. spermatica externa | Cremasteric artery |
| Aa. pudendæ externæ | Superficial and deep external pudic arteries |
| A. circumflexa femoris medialis | Internal circumflex artery |
| A. circumflexa femoris lateralis | External circumflex artery |
| A. genu suprema | Anastomotica magna |
| A. genu superior lateralis | Superior external articular artery |
| A. genu superior medialis | Superior internal articular artery |
| A. genu media | Azygos articular artery |
| A. genu inferior lateralis | Inferior external articular artery |
| A. genu inferior medialis | Inferior internal articular artery |
| A. malleolaris anterior lateralis | External malleolar artery |
| A. malleolaris anterior medialis | Internal malleolar artery |
| A. peronæa | Peroneal artery |
| Ramus perforans | Anterior peroneal artery |
| A. malleolaris posterior lateralis | Posterior peroneal artery |
| A. malleolaris posterior medialis | Internal malleolar artery |
| Rami calcanei laterales | External calcanean artery |
| Rami calcanei mediales | Internal calcanean artery |
| A. plantaris medialis | Internal plantar artery |
| A. plantaris lateralis | External plantar artery |
| Aa. metatarseæ plantares | Digital branches |
| Aa. digitales plantares | Collateral digital branches |

## Veins.

| | |
|---|---|
| V. cordis magna | Great cardiac vein |
| V. obliqua atrii sinistri | Oblique vein of Marshall |
| Lig. venæ cavæ sinistræ | Vestigial fold of Marshall |
| Vv. cordis minimæ | Veins of Thebesius |
| Sinus transversus | Lateral sinus |
| Confluens sinuum | Torcular Herophili |
| Plexus basilaris | Basilar sinus |
| Sinus sagittalis superior | Superior longitudinal sinus |
| Sinus sagittalis inferior | Inferior longitudinal sinus |
| Spheno-parietal sinus | Sinus alæ parvæ |
| V. cerebri internæ | Veins of Galen |
| V. cerebri magna | Vena magna Galeni |
| V. terminalis | Vein of the corpus striatum |
| V. basalis | Basilar vein |
| V. transversa scapulæ | Suprascapular vein |
| V. thoraco-acromialis | Acromio-thoracic vein |
| Vv. transversæ colli | Transversalis colli veins |
| V. thoracalis lateralis | Long thoracic vein |
| V. azygos | Vena azygos major |
| V. hemiazygos | Vena azygos minor inferior |
| V. hemiazygos accessoria | Vena azygos minor superior |
| V. hypogastrica | Internal iliac vein |
| V. epigastrica inferior | Deep epigastric vein |
| V. saphena magna | Internal saphenous vein |
| V. saphena parva | External saphenous vein |

### Lymphatics.

| B.N.A. Terminology. | Old Terminology. |
|---|---|
| Cisterna chyli | Receptaculum chyli |

## THE VISCERA.

### Digestive Apparatus.

| | |
|---|---|
| Arcus glosso-palatinus | Anterior pillar of fauces |
| Arcus pharyngo-palatinus | Posterior pillar of fauces |
| Gl. lingualis anterior | Gland of Nuhn |
| Ductus submaxillaris | Wharton's duct |
| Gl. parotis accessoria | Socia parotidis |
| Ductus parotideus (Stenonis) | Stenson's duct |
| Dentes præmolares | Bicuspid teeth |
| Dens serotinus | Wisdom tooth |
| Papillæ vallatæ | Circumvallate papillæ |
| Recessus pharyngeus | Lateral recess of pharynx |
| Tela submucosa | Pharyngeal aponeurosis |
| Plicæ circulares | Valvulæ conniventes |
| Gl. intestinales | Crypts of Lieberkuhn |
| Valvula coli | Ileo-cæcal valve |
| Columnæ rectales | Columns of Morgagni |
| Plicæ transversales recti | Valves of Houston |
| Valvula spiralis | Valves of Heister |
| Noduli lymphatici aggregati (Peyeri) | Peyer's patches |
| Intestinum jejunum | Jejunum |
| Intestinum ileum | Ileum |
| Noduli lymphatici lienales (Malpighii) | Malpighian corpuscles |

### Respiratory Apparatus.

**Larynx**

| | |
|---|---|
| Prominentia laryngea | Adam's apple |
| Incisura thyreoidea superior | Superior thyroid notch |
| M. ary-epiglotticus | Aryteno-epiglottidean muscle |
| M. vocalis | Internal thyro-arytenoid muscle |
| M. thyreo-epiglotticus | Thyro-epiglottidean muscle |
| Appendix ventriculi laryngis | Laryngeal sac |
| Plica vocalis | True vocal cord |
| Plica ventricularis | False vocal cord |
| Ligamentum ventriculare | Superior thyro-arytenoid ligament |
| Ligamentum vocale | Inferior thyro-arytenoid ligament |
| Glottis | Glottis vera |
| Rima vestibuli | Glottis spuria |
| Cartilago thyreoidea | Thyroid cartilage |

| B.N.A. Terminology. | Old Terminology. |
|---|---|
| Membrana hyo-thyreoidea | Thyro-hyoid membrane |
| Cartilago corniculata (Santorini) | Cartilage of Santorini |
| Tuberculum epiglotticum | Cushion of epiglottis |
| Pars intermembranacea (rimæ glottidis) | Glottis vocalis |
| Pars intercartilaginea (rimæ glottidis) | Glottis respiratoria |
| Conus elasticus (membranæ elasticæ larynges) | Crico-thyroid membrane |
| Glandula thyreoidea | Thyroid gland |
| Glomus caroticum | Intercarotid gland or body |
| **Nose** | |
| Concha nasalis suprema (Santorini) | Highest turbinate bone |
| Concha nasalis superior | Superior turbinate bone |
| Concha nasalis media | Middle turbinate bone |
| Concha nasalis inferior | Inferior turbinate bone |

## Urogenital Apparatus.

| | |
|---|---|
| Corpuscula renis | Malpighian corpuscles |
| Paradidymis | Organ of Giraldés |
| Appendix testis | Hydatid of Morgagni (male) |
| Ductus deferens | Vas deferens |
| Gl. urethrales | Glands of Littré |
| Glandula bulbo-urethralis (Cowperi) | Cowper's gland |
| Folliculi oophori vesiculosi | Graafian follicles |
| Cumulus oophorus | Discus proligerus |
| Tuba uterina | Fallopian tube |
| Epoophoron | Parovarium |
| Appendices vesiculosi | Hydatids of Morgagni (female) |
| Ductus epoophori longitudinalis | Gärtner's duct |
| Orificium internum uteri | Internal os (of uterus) |
| Orificium externum | External os |
| Processus vaginalis | Canal of Nuck |
| Glandula magna vestibuli | Bartholin's gland |

## Peritoneum.

| | |
|---|---|
| Bursa omentalis | Lesser peritoneal sac |
| Foramen epiploicum | Foramen of Winslow |
| Lig. phrenico-colicum | Costo-colic ligament |
| Excavatio recto-uterina (cavum Douglasi) | Pouch of Douglas |
| Lig. gastro-lienale | Gastro-splenic omentum |

# SENSE ORGANS.

## The Eye.

| | |
|---|---|
| Sclera | Sclerotic coat |
| Lamina elastica anterior (Bowmani) | Bowman's membrane |

| B.N.A. Terminology. | Old Terminology. |
|---|---|
| Lamina elastica posterior (Descemeti) | Descemet's membrane |
| Spatia anguli iridis | Spaces of Fontana |
| Angulus iridis | Irido-corneal junction |
| Zonula ciliaris | Zonule of Zinn |
| Septum orbitale | Palpebral ligament |
| Fascia bulbi | Capsule of Tenon |
| Commissura palpebrarum lateralis | External canthus |
| Commissura palpebrarum medialis | Internal canthus |
| Tarsus superior | Superior tarsal plate |
| Tarsus inferior | Inferior tarsal plate |
| Lig. palpebrale mediale | Internal tarsal ligament |
| Raphe palpebralis lateralis | External tarsal ligament |
| Tarsal glands | Meibomian glands |

## The Ear.

| | |
|---|---|
| Canalis semicircularis lateralis | External semicircular canal |
| Ductus reuniens | Canalis reuniens |
| Ductus cochlearis | Membranous cochlea |
| Recessus sphericus | Fovea hemispherica |
| Recessus ellipticus | Fovea hemi-elliptica |
| Paries jugularis | Floor of tympanum |
| Paries labyrinthica | Inner wall |
| Fenestra vestibuli | Fenestra ovalis |
| Fenestra cochleæ | Fenestra rotunda |
| Paries mastoidea | Posterior wall |
| Antrum tympanicum | Mastoid antrum |
| Paries carotica | Anterior wall |
| Processus lateralis | Processus brevis (of malleus) |
| Processus anterior | Processus gracilis |

# MANUAL

OF

# 'RACTICAL ANATOMY.

## THE SUPERIOR EXTREMITY.

IE dissector of the upper extremity begins work on the fourth day after the subject has been placed in the dis-ng-room. He will find the body lying upon its back. thorax is raised to a convenient height by means of blocks, a long board is placed under the shoulders for the ose of supporting the arms when they are abducted from ides.

dissecting the axilla and thorax it will be found advantageous if the tors of the arm and of the head and neck arrange to work at different The dissector of the head and neck, at this stage, is engaged on the ior triangle of the neck, and the dissection of the triangle cannot be lone unless the arm is placed close to the side and the shoulder ised. For the dissection of the axilla the arm should be stretched right angles to the thorax. A compromise between these two posi-ılways results in discomfort to both dissectors.

he upper extremity consists of the *brachium* or arm, the *rachium* or forearm, and the *manus* or hand. Connected it are the bones of the shoulder girdle, by means of ı it is articulated with the skeleton of the trunk; it is connected with the trunk by means of a number of les. The angle which lies between the arm and the · part of the trunk is the axilla or armpit. It contains ;e number of important blood vessels, nerves, and lymph s. All the structures mentioned above are to be examined

by the dissector of the upper extremity; and five days are allowed for the examination of the axilla and the muscles which pass to it from the anterior portion of the thoracic region of the body. The following table may be found useful in regulating the amount of work which should be carried out on each day:—

**First Day.**—(*a*) Surface anatomy; (*b*) reflection of the skin; (*c*) cutaneous vessels and nerves of the anterior and lateral aspects of the thorax; (*d*) examination of the fascia of the pectoralis major and the axillary fascia; (*e*) the cleaning of the pectoralis major; (*f*) the reflection of the pectoralis major.

**Second Day.**—(*a*) The examination of the costo-coracoid membrane and the structures piercing it; (*b*) the removal of the costo-coracoid membrane and the examination of the structures posterior to it.

**Third Day.**—(*a*) The cleaning of the pectoralis minor; (*b*) the cleaning of the contents of the axilla below the pectoralis minor.

**Fourth Day.**—(*a*) The reflection of the pectoralis minor; (*b*) the completion of the cleaning of the contents of the axilla; (*c*) the cleaning of the serratus anterior; (*d*) the cleaning of the posterior wall of the axilla; (*e*) the reflection of the subclavius; (*f*) the examination of the sterno-clavicular articulation and the disarticulation of the clavicle at the sterno-clavicular joint.

**Fifth Day.**—(*a*) The brachial plexus and a general review of the axilla and its contents.

**Surface Anatomy.**—Before proceeding to the actual dissection of any region, the student should make it an invariable practice to familiarise himself with the bony prominences within its area. It is by using these as landmarks that the surgeon is enabled to establish the positions of the component parts of the body in the living subject.

At the lower part of the neck the entire length of the clavicle can be felt under the skin (Fig. 1); and as the student follows its curves, with his finger, he can recognise the positions of the origins of the pectoralis major and deltoid muscles from its anterior border (Fig. 5). In a few instances these muscles may present an unbroken line of origin from the sternal to the acromial end of the bone, but in the vast majority of cases a triangular interval is left between them. This is marked on the surface by a shallow depression, termed the *delto-pectoral triangle* (infraclavicular fossa), and it is rendered all the more apparent by the prominence of the shoulder on its lateral side, and the sharp posterior curvature of the clavicle immediately above it. If the finger be placed in this triangle, and pressed posteriorly and laterally, it will abut against the medial side of the coracoid process of the scapula.

The articulations of the clavicle should also be examined.

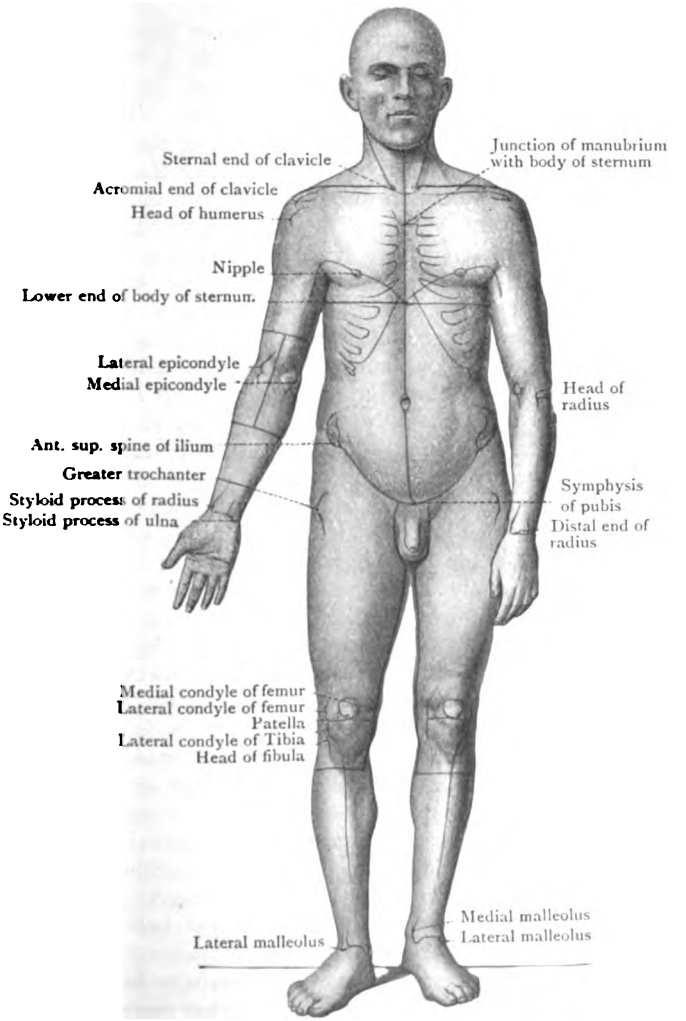


FIG. 1.—Surface View showing Incisions and Bony Points.

Little or no prominence is formed by the lateral extremity of the bone—its superior surface lies in the same plane as the

superior surface of the acromion of the scapula. When the limb is moved, however, the joint can easily be detected. In strong contrast to this is the sternoclavicular joint, where the medial end of the clavicle can be felt as a marked projection, although this is masked to the eye by the sternal part of the sterno-cleido-mastoid muscle. The jugular notch on the upper border of the manubrium sterni, between the clavicles, should next be felt, and then the finger can be carried downwards, in the median line, along the anterior aspect of the sternum. A prominent ridge, crossing the bone transversely at the level of the second costal cartilages, indicates the junction between the body of the sternum and the manubrium. The portion of the sternum uncovered by the two greater pectoral muscles is narrow above, but it widens out below, and suddenly, at the lower end of the body of the sternum, the finger sinks into a depression, between the cartilages of the seventh pair of ribs, and rests upon the xiphoid process. The depression is termed the *infrasternal fossa*, or pit of the stomach. The costal arches, below the first, are easily recognised, but the first rib lies deeply under the clavicle, and can be felt only in front, at its junction with the manubrium sterni. The arm should now be abducted (*i.e.* carried laterally from the trunk), when the hollow of the axilla will be brought into view, as well as the two rounded folds which bound it in front and behind. The anterior fold of the axilla is formed by the lower border of the pectoralis major, and to a small extent also by the lower border of the pectoralis minor. The posterior fold, which is formed by the latissimus dorsi, as it winds round the teres major muscle, is carried downwards to a lower level than the anterior fold. This, as will be seen later, is an important point in connection with the anatomy of the axilla. If the finger be pushed upwards into the axilla the globular head of the humerus can be felt, when the arm is rotated. One other point demands the attention of the student before the dissection is commenced, and that is the position of the nipple. As a rule it lies superficial to the interspace between the fourth and fifth ribs, and it is situated rather more than four inches from the median line.

The student should examine these various landmarks, not only upon the body but upon himself and his friends, until he is perfectly familiar with them, both by touch and sight, and

can at once put his finger on any given point, whatever the position of the limb may be.

**Reflection of Skin.**—Incisions—(1) Along the median line of the body from the upper margin of the manubrium sterni to the tip of the xiphoid process; (2) from the lower end of this vertical incision transversely round the lateral border of the body; (3) from the upper extremity of the primary incision laterally, along the clavicle, to the extremity of the acromion; (4) from the lower end of the vertical and median incision (*i.e.* tip of the xiphoid process) obliquely upwards and laterally, along the anterior fold of the axilla, to the point at which this joins the arm. Then distally along the arm for two and a half or three inches.

Two triangular flaps of skin are marked out by these incisions, and these are now to be raised from the panniculus adiposus. But, before this is done, encircle the areola around the nipple with the knife and leave the skin in the circle undisturbed.

**Panniculus Adiposus (Superficial Fascia).**—The fatty layer which is now exposed is termed the panniculus adiposus or superficial fascia. It constitutes the cushion upon which the skin rests, rounds off the angularities of the body, and varies in thickness according to the obesity of the subject. It also forms the bed in which the cutaneous vessels and nerves ramify before they enter the skin. It is separated from the muscles by a tough, but thin, layer of fibrous tissue, devoid of fat, which forms another investment for the body; this fibrous membrane receives the name of the *deep fascia*; it can be readily demonstrated by making an incision in the superficial fascia, and raising a small portion of it.

The superficial fascia presents here, as elsewhere, the usual characters, but, as a rule, the fat is not so plentiful. As it descends over the clavicle to the upper part of the thorax and the summit of the shoulder, it has, in most cases, a faintly ruddy, striated appearance. Should this not at first be apparent, the removal of some of the superficial fat will render it visible. This appearance is due to the presence of a number of sparse, scattered muscular fasciculi which pass down over the clavicle, to obtain attachment in the panniculus adiposus over the pectoralis major and deltoid muscles. In the neck they form a thin, cutaneous, fleshy stratum, called the *platysma*. The superficial fascia in this region is also specialised by the development of the mamma in its substance. It should now be dissected, with the view of exposing the mamma as well as the cutaneous vessels and nerves which pass through it before entering the skin.

*Dissection.*—When searching for a cutaneous nerve, cut boldly down through the superficial fascia in the direction in which the nerve runs, until the plane at which the superficial and deep fascia blend is reached. It is there that the main trunks are to be found; and in a well-injected subject the cutaneous arteries furnish the best guides.

**Nervi Cutanei, Arteriæ Cutaneæ (Cutaneous Nerves and Arteries).**—There are three distinct groups of cutaneous nerves for the supply of the skin on the anterior and lateral parts of the thorax. They are:—

1. The supraclavicular nerves—from the cervical plexus.
2. The anterior cutaneous, } from the anterior (intercostal) rami
3. The lateral cutaneous, } of the thoracic nerves.

The *supraclavicular nerves* arise in the neck, from the third and fourth cervical nerves, and, spreading out as they descend, they cross the clavicle under cover of the platysma. They are classified, according to their positions, into the anterior, the middle, and the posterior branches. The *anterior* are the smallest of the series; they cross the medial part of the clavicle to end in the skin immediately below. The *middle branches* pass over the middle of the clavicle and extend downwards, in the superficial fascia over the pectoralis major, as far as the third rib. The *posterior* cross the lateral third of the clavicle, and will be afterwards followed to the skin of the shoulder.

These nerves can readily be found by cutting down upon the clavicle through the platysma, and in the direction of its fibres.

The *anterior cutaneous nerves* are the minute terminal twigs of the anterior branches of the thoracic nerves. They become superficial, by piercing the pectoralis major muscle and the deep fascia, close to the margin of the sternum. One will be found in each intercostal interval except the first; and they are accompanied by the *cutaneous perforating branches* of the internal mammary artery, which serve as the best guides to the nerves. They give slender twigs to the skin over the sternum, and larger branches which are directed laterally, and may be traced as far as the anterior fold of the axilla.

The *lateral cutaneous nerves*, much larger than the preceding, arise from the anterior rami of the thoracic nerves, and appear, on the side of the thorax, along a line situated a little behind the anterior fold of the axilla. They pierce the wall of the thorax in the interspaces between the ribs, and divide into anterior and posterior branches under

er of the serratus anterior muscle. At a later stage se branches will be found appearing between the digitas of the serratus anterior. The *anterior branches* come as a rule, about an inch in front of the corresponding terior branches, and then proceed forwards over the lower der of the pectoralis major muscle, where they should be ght for at once. From the lower members of this series e minute twigs are given off, which enter the superficial

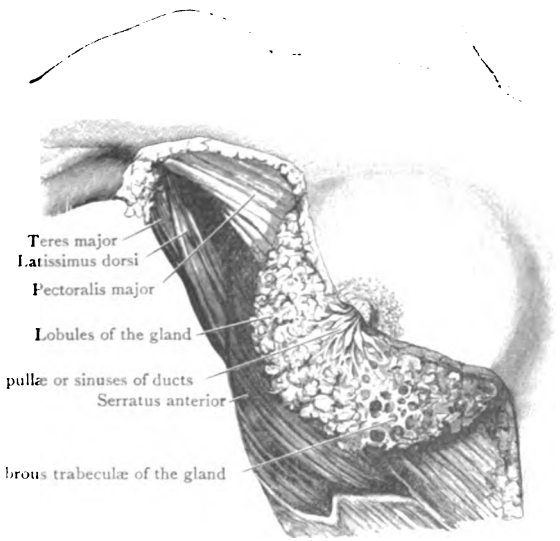


FIG. 2.—Dissection of the Mamma.

ce of the digitations of the external oblique muscle he abdomen. The *posterior branches* run backwards, e dorsal aspect of the trunk, over the anterior border e latissimus dorsi muscle.

s advisable not to attempt to secure the highest two lateral cutaneous (*i.e.* those issuing from the second and third intercostal spaces) in antime. They are best dissected along with the other contents of illa.

*section.*—If the subject is a female the dissector should endeavour ke out the connections, and also something of the structure, of the ıa. The small area of skin which has been left over the areola be raised towards the summit of the nipple, and bristles may roduced through the orifices of the ducts which may be seen on the

extremity of the nipple. Further, by removing the fat which surrounds the organ the true glandular tissue will be rendered more apparent. It is only in favourable circumstances that the milk-ducts in the nipple and their sinuses in the region of the areola can be isolated and rendered apparent.

**The Mamma (Mammary Gland or Breast).**—In the female the mamma forms a rounded prominence on the front and

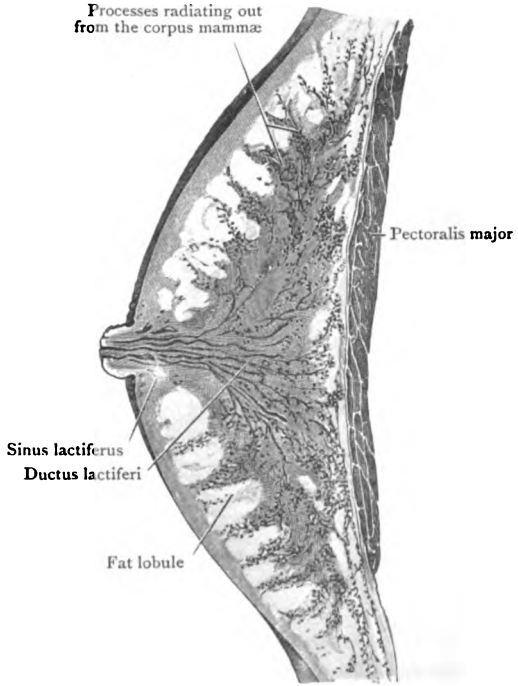


FIG. 3.—Section through a Mammary Gland prepared by the method recommended by Mr. Harold Stiles.

also, to some extent, on the lateral aspect, of the thorax. It lies in the superficial fascia, and its smooth contour is largely due to the invasion of its substance by the fatty tissue of this layer.

A little below its mid-point, and at a level which usually corresponds to the fourth intercostal space, the mamma is surmounted by a conical elevation termed the *papilla mammæ* or nipple. This stands in the middle of a circular

patch of coloured integument which is called the *areola mammæ*. Within the nipple, and also subjacent to the areola, there is no fat. A curious change of colour occurs in this region during the second month of pregnancy. At that time the delicate pink colour of the skin of the nipple and areola of the virgin becomes converted to brown, by the deposition of pigment, and it never again resumes its original appearance.

The mamma extends, in a horizontal direction, from the side of the sternum almost to the mid-axillary line on the side of the thorax, and, in a vertical direction, from the second costal arch above to the sixth costal cartilage below. About two-thirds of the gland are placed upon the pectoralis major muscle, whilst the remaining part, which corresponds to its inferior and lateral third, extends beyond the anterior fold of the axilla, and lies upon the serratus anterior muscle. From the part which lies in relation to the lower border of the pectoralis major a prolongation extends upwards into the axilla, and reaches as high as the third rib.

The mamma is not isolated by a capsule from the surrounding fatty tissue of the superficial fascia. Pervading it, and supporting the true glandular substance, there are strands or trabeculæ of connective tissue which constitute its stroma or framework, and these are directly continuous with the fibrous tissue which supports the fat of the superficial fascia. The stroma and gland-substance together constitute a conical mass termed the *corpus mammæ*. Processes project out from both the surface and margins of the corpus mammæ, and in the hollows between these projections is deposited the fat which gives the smooth contour to the organ. Many of the processes which extend from the superficial surface are attached to the deep surface of the skin. They form the so-called *ligaments of Cooper*.

The gland substance is arranged in lobes and lobules, and the ducts issuing from these converge towards the areola. Some fifteen or more lactiferous ducts pass towards the base of the nipple. Subjacent to the areola the ducts expand into fusiform dilatations termed the *sinus lactiferi*, and then, contracting, they traverse the substance of the nipple, upon the summit of which they open.

In a well-injected subject twigs from the *intercostal arteries*, and also from the *perforating branches* of the

*internal mammary artery*, may be traced into the mamma; and other vessels, called the *external mammary branches* of the *lateral thoracic artery*, may be seen winding round the edge of the pectoralis major, or piercing its lower fibres, to reach the gland.

By means of *lymph vessels* the mamma is brought into connection with the sternal lymph glands, the abdominal lymph vessels, and also, more directly, with the axillary lymph glands. All these connections are of much importance to the surgeon in cases where it is necessary to remove the organ for malignant disease.

In the male the mamma (mamma virilis) is extremely rudimentary. The nipple is small and pointed, and the areola is surrounded by sparse hairs.

**Deep Fascia.**—The deep fascia of the pectoral region is a thin membrane which closely invests the pectoralis major. It is attached above to the clavicle, and medially to the front of the sternum. Below, it is continuous with the deep fascia covering the abdominal muscles, and, at the lower border of the pectoralis major muscle, it is continuous with the axillary fascia. At the delto-pectoral triangle a process from its deep surface dips in between the deltoid and pectoralis major muscles to join the costo-coracoid membrane, whilst, further laterally, it becomes continuous with the fascia covering the deltoid muscle. The costo-coracoid membrane will be described later (p. 15).

**Fascia Axillaris.**—The axillary fascia is a dense felted membrane which extends across the base of the axilla. It is continuous anteriorly with the deep fascia over the pectoralis major, posteriorly with the fascial sheaths of the latissimus dorsi and the teres major muscles, medially with the deep fascia on the surface of the serratus anterior, whilst laterally it is continuous with the deep fascia on the medial surface of the proximal part of the arm. It is drawn up towards the hollow of the axilla, and the elevation is due chiefly to the connection of its deep surface with the fascial sheath of the pectoralis minor, and partly to its attachment to the areolar tissue which fills the axillary space. In a well-injected subject a small artery, from the distal part of the axillary trunk, may be seen ramifying on the surface of the fascia.

*Dissection.*—The pectoralis major muscle must now be cleaned, and its

sion into sternal and clavicular parts clearly made out. The muscular es are rendered tense by abducting the arm from the side. On the t side the dissector begins at the inferior border of the muscle, whilst he left side he commences at the superior border. He must also clean anterior margin of the deltoid. In the interval between the deltoid the clavicular portion of the pectoralis major the *cephalic vein* and, acent to it, the deltoid branches of the *thoraco-acromial artery*, and delto-pectoral glands will be found.

The "cleaning" of a muscle means the removal of the whole of the o fascia from its surface. To do this successfully the dissector must

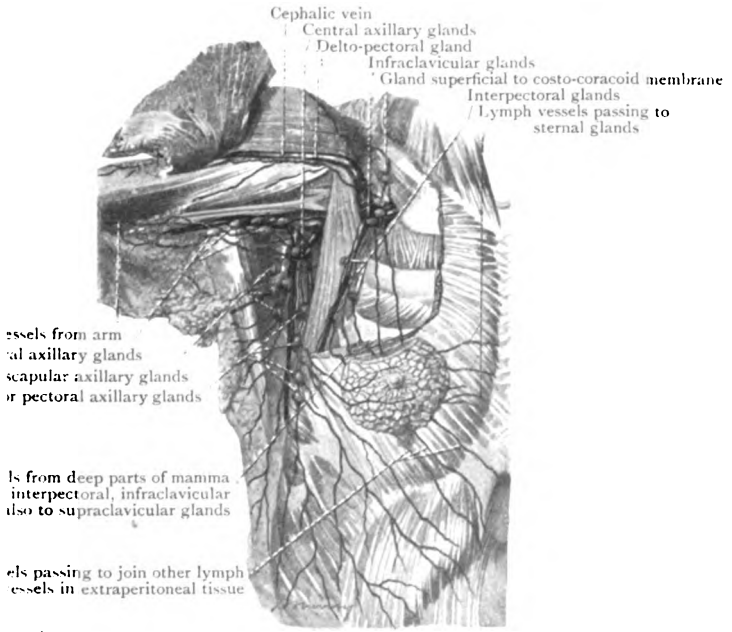


FIG. 4.—The Lymph Glands and Vessels of the Axilla and Mamma.

y three rules. (1) He must cut boldly down through the deep fascia e exposes the red fibres of the muscle. (2) As he removes the fascia ust keep the knife edge playing against the fibres of the muscle. as he makes his cuts he must carry the knife blade in the direction e fibres of the muscle. If he follows rules 1 and 2 he will not leave a film of fascia on the muscle, and as he follows rule 3 he will find the direction of his incisions change as the course of the fibres of the le changes. If the work is well done the deep fascia should be ved from the muscle as a continuous unperforated layer of fibrous , and the surface of the muscle will be clean.

**Delto-pectoral Lymph Glands,** sometimes represented by

a single gland only, lie in the interval between the adjacent margins of the pectoralis major and deltoid muscles, immediately below the clavicle, and subjacent to the deep fascia. They receive the lymph vessels which accompany the cephalic vein. These vessels convey the lymph from the lateral side of the arm and the shoulder.

**M. Pectoralis Major.**—This powerful muscle extends from the anterior aspect of the thorax to the humerus. It is divided by a deep fissure into a clavicular and a sternocostal portion. The fissure penetrates through the entire thickness of the muscle, the clavicular and sternocostal portions being thus distinct, except close to their insertion. The *clavicular portion* arises by short tendinous and muscular fibres from an impression on the medial half of the anterior surface of the

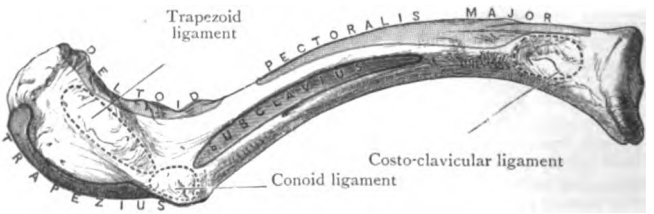


FIG. 5.—Inferior Surface of the Clavicle with the Attachments of the Muscles mapped out.

clavicle. The superficial part of the *sternocostal portion* takes origin by fleshy fibres from the anterior surface of the sternum, from the aponeurosis of the external oblique muscle, and, occasionally, from the sixth rib near its cartilage. The deeper part arises by a variable number of muscular slips from the cartilages of the upper six ribs.

The pectoralis major is inserted, by a flattened bilaminar tendon, into the lateral lip of the intertubercular groove of the humerus, and the fibres of the muscle undergo a rearrangement as they converge upon this tendon. The greater part of the clavicular portion joins the anterior lamina of the common tendon; some of the most medial clavicular fibres, however, are inserted directly into the humerus distal to the tendon, whilst a few gain attachment to the deep fascia of the arm, and others become adherent to the adjacent part of the deltoid.

The fibres of the sternocostal portion of the muscle take

different directions as they proceed to join both laminæ of the tendon of insertion; thus, the superior fibres descend slightly, the intermediate fibres pass horizontally, whilst the inferior fibres ascend, and, at the same time, gain the deep surface of the rest of the muscle. A smooth, full, and rounded lower border is in this way formed; it constitutes the anterior fold of the axilla. The precise manner in which the muscle is attached to the humerus will be more fully studied at a later stage of the dissection (p. 56).

The pectoralis major is supplied by the *medial* and *lateral anterior thoracic nerves.*

**Axilla.**—The axilla may be defined as the hollow or recess between the upper part of the side of the thorax and the proximal part of the arm. When the limb is abducted from the trunk, and the areolo-fatty tissue which occupies the axilla is removed, the space presents a pyramidal form. The apex, or narrow part of the space, placed immediately to the medial side of the coracoid process, is directed upwards towards the root of the neck, whilst the wider part or base looks downwards. The medial wall, formed by the thorax, is of greater extent than the lateral wall which is formed by the arm. It follows, therefore, that the anterior and posterior walls converge as they proceed laterally, and, because the posterior wall is longer than the anterior, the posterior border of the base is lower than the anterior.

Before engaging in the dissection of the space, it is necessary that the student should have some knowledge of its boundaries, and the manner in which its contents are disposed in relation to these.

**Boundaries of the Axilla.**—The *anterior wall* is formed by the two pectoral muscles and the costo-coracoid membrane. The pectoralis major constitutes the superficial stratum, and is spread out over the entire extent of the anterior wall. The pectoralis minor, which lies subjacent to the pectoralis major, constitutes a part of about one-third of the anterior boundary, whilst the interval or gap between this muscle and the clavicle is filled up by the costo-coracoid membrane. The lower border of this wall of the axilla is the *anterior fold* of the axilla. It is formed by the lower margin of the pectoralis major, strengthened, medially, by a small part of the lower border of the pectoralis minor, which comes into view near the side of the thorax.

The *posterior wall* of the axilla is somewhat longer than

the anterior wall. It is formed, from above downwards, by the subscapularis muscle, the tendon of the latissimus dorsi, and the teres major muscle. The subscapularis, covering the costal surface of the scapula, takes by far the largest share in the formation of this wall. The narrow tendon of the latissimus dorsi conceals the front of the teres major and only the lower border of the latter muscle is seen below it. The *posterior fold* of the axilla is formed by the lower border of this wall.

The *medial wall* is constituted by the upper four or five ribs with the intervening intercostal muscles; it is clothed by the corresponding digitations of the serratus anterior muscle.

The *lateral wall* is formed by the humerus and the conjoined

1. Proximal end of humerus.
2. Scapula.
3. Rib.
4. Pectoralis major.
5. Serratus anterior.
6. Subscapularis.
7. Axillary vein.

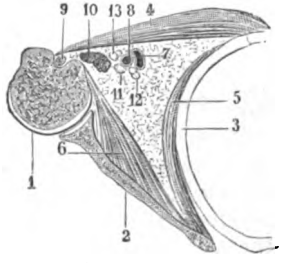


8. Axillary artery.
9. Long head of biceps.
10. Conjoined origin of short head of biceps and coraco-brachialis.
11, 12, 13. Brachial nerves.

FIG. 6.—Diagram of section through the Axilla of the Left Side.

proximal parts of the coraco-brachialis and short head of the biceps brachii muscles.

The *apex* of the space corresponds with the narrow communication between the axilla and the root of the neck. It is a triangular interval (which can readily be investigated by the finger when the space is dissected) bounded by the clavicle, first rib, and upper margin of the scapula, and through it pass the axillary vessels and brachial nerves on their way from the neck to the arm. The wide *base* of the axilla is closed by the vaulted axillary fascia.

**Contents of the Axilla.**—The axillary artery and vein, with the great brachial nerves and the axillary lymph vessels and lymph glands, constitute the most important contents of the axilla. Except at the summit of the space, they lie close to the lateral wall, and follow it in all the movements of the arm.

*Dissection.*—Cut through the clavicular fibres of the pectoralis major,

immediately below their attachment to the clavicle, and turn them distally towards their insertion. Whilst doing this, secure the branches of the lateral anterior thoracic nerve as they pass into the muscle. Follow the cephalic vein and the deltoid branch of the thoraco-acromial artery medially, under cover of the clavicular part of the pectoralis major and secure the acromial and pectoral branches of the latter artery. Clean these vessels, and, directly below the clavicle, display the *costo-coracoid membrane*, and, more inferiorly and laterally, the fascia on the proximal and lateral part of the pectoralis minor. Cut through the sternocostal part of the pectoralis major about two inches from the lateral border of the sternum. Turn the medial part towards the median plane, verifying its attachment to the costal cartilages and to the sternum and to the aponeurosis of the external oblique muscle of the abdomen. Turn the lateral part of the muscle towards the arm; whilst doing this, secure the medial anterior thoracic nerve, which perforates the pectoralis minor and ends in the pectoralis major. Examine the insertion of the pectoralis major. Note that the tendon of insertion consists of two lamina which are united together below; in other words, the tendon is folded on itself; and between the two lamina a *mucous bursa* is frequently interposed. The clavicular fibres and the upper sternocostal fibres are attached to the anterior lamina; the lower sternocostal fibres to the posterior lamina. Both lamina are attached to the lateral lip of the intertubercular sulcus of the humerus, but the deep lamina ascends to a more proximal level, and becomes continuous, proximally, with a layer of fascia which is attached to the lesser tubercle of the humerus. The inferior border of the tendon of insertion is continuous with the deep fascia of the arm.

When the pectoralis major is completely reflected a continuous sheet of fascia is exposed, which extends from the clavicle superiorly to the axillary fascia inferiorly, and from the wall of the thorax medially to the arm laterally; this is the so-called *clavipectoral fascia* or *suspensory ligament of the axilla*. It is because of the attachment of this fascial sheet to the clavicle superiorly and to the axillary fascia inferiorly that the floor of the axilla is raised as the arm is abducted from the side and the clavicle is elevated. The pectoralis minor muscle, passing obliquely from its origin on the thoracic wall to its insertion into the coracoid process of the scapula, runs through the substance of the clavipectoral fascia and divides it into three parts: (1) the part above the muscle, (2) the part which encloses the muscle, and (3) the part below the muscle. The uppermost part is the costocoracoid membrane, the intermediate part is the sheath of the pectoralis minor. No special term is applied to the lowest part, but it should be noted that it lies posterior to the lower part of the pectoralis major, and that it covers the distal portions of the axillary vessels and nerves.

**Membrana Costocoracoidea (Costo-coracoid Membrane).**—The costo-coracoid membrane occupies the gap between the clavicle above and the pectoralis minor below. It extends from the first rib medially to the coracoid process laterally, and from the clavicle above to the pectoralis minor below. Its upper part is split into two layers, an anterior and a posterior, which are attached to the corresponding borders of the clavicle. Enclosed between them is the subclavius muscle. The strongest part of the membrane is that which extends along the lower border of the subclavius, from the first rib to

the coracoid process; this portion is frequently called the *costo-coracoid ligament.* The membrane is continuous below with the fascial sheath of the pectoralis minor and posteriorly with the fascial sheath of the axillary vessels. It is perforated, above the upper border of the pectoralis minor, by the cephalic vein, the thoraco-acromial vessels, and the lateral anterior thoracic nerve. Note that the fibres of the membrane run medio-laterally, that they are put on the stretch when the arm is abducted, and that they are relaxed when the arm is by the side. The surgeon takes advantage of these facts when he is ligaturing the first part of the axillary artery.

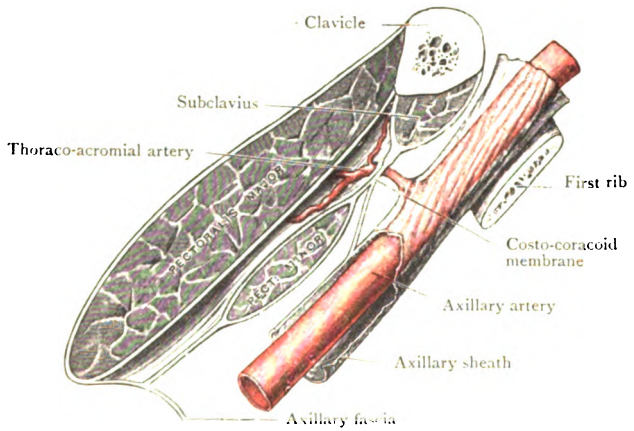


FIG. 7.—Diagram of the Costo-coracoid Membrane.

*Dissection.* Cut through the anterior layer of the upper part of the costo-coracoid membrane and expose the subclavius muscle. Pass the handle of a knife below the lower border of the subclavius and upwards behind the muscle and demonstrate the posterior layer of the upper part of the membrane. Clear away the remains of the membrane and follow the cephalic vein to its junction with the axillary vein, the thoraco-acromial artery to the axillary trunk, and the lateral anterior thoracic nerve to the lateral cord of the brachial plexus. Clean the proximal parts of the axillary artery and vein and the lateral cord of the brachial plexus. Note that the axillary vein lies to the medial side of the artery, on a somewhat anterior plane, and that as the arm is abducted from the side the vein passes more and more in front of the artery. The lateral cord of the plexus lies to the lateral side of the artery and on a posterior plane. Behind the upper border of the pectoralis minor find the medial anterior thoracic nerve, and note that a communication is formed between the medial and lateral anterior thoracic nerve, across the front of the artery and behind the costo-coracoid membrane.

Clean the pectoralis minor muscle without injuring the medial anterior thoracic nerve, which pierces it.

**M. Pectoralis Minor.**—The pectoralis minor is a triangular muscle which arises from the anterior ends of the third, fourth, and fifth ribs, close to their junctions with their cartilages, and from the fascia covering the intercostal muscles in the intervening spaces. Its fibres pass upwards and laterally, and its tendon of insertion is attached to the upper surface and the anterior border of the coracoid process, near its lateral extremity. When the muscle is in action it draws the scapula downwards and forwards, and depresses the shoulder. It is supplied by the *medial anterior thoracic nerve.* The greater portion of the pectoralis minor is concealed by the pectoralis major, but the medial part of its inferior border appears on the lateral wall of the thorax below the pectoralis major; its insertion is concealed by the anterior fibres of the deltoid.

*Dissection.*—Clear away the clavipectoral fascia below the level of the pectoralis minor and open up the lower part of the axilla; remove also the deep fascia of the arm in the region of the lateral boundary of the axilla.

Commence at the lateral part of the area below the pectoralis minor and clean the coraco-brachialis and the short head of the biceps, as they descend into the arm from the tip of the coracoid process. Find the distal part of the axillary artery at the medial border of the coraco-brachialis. The trunk of the median nerve lies between the artery and the muscle, and at the lower border of the pectoralis minor the medial head of the nerve crosses the front of the artery. Pull the coraco-brachialis laterally and find the musculo-cutaneous nerve entering its deep surface, just below the pectoralis minor. Above and to the lateral side of the trunk of the musculo-cutaneous nerve find the branch from it which supplies the coraco-brachialis. The axillary vein lies along the medial side of the artery, and in the angle between the artery and vein, anteriorly, is the medial cutaneous nerve of the forearm (O.T. internal cutaneous). Running along the medial side of the vein is the medial cutaneous nerve of the arm (O.T. lesser internal cutaneous nerve); secure this and follow it upwards to the communication which it receives from the intercosto-brachial nerve. At the same time identify and preserve the lateral group of axillary lymph glands which lie along the medial side of the axillary vein. Secure the intercosto-brachial nerve and follow it medially, to the point where it emerges from the second intercostal space, and laterally to the medial and posterior aspect of the arm, where it is distributed.

In order to display the distribution of the intercosto-brachial nerve, and to give better access to the medial and posterior walls of the axilla, the axillary fascia must be separated from the fascia of the arm. When this has been done the dissector should turn to the medial wall of the axilla and find the anterior and posterior divisions of the lateral branches of the intercostal nerves, as they emerge between the digitations of the serratus anterior, behind the inferior border of the pectoralis minor. These he must trace forwards and backwards respectively, and he may expect to find

an anastomosis between the posterior division of the third lateral branch and the intercostobrachial nerve. At the junction of the anterior and medial walls of the axilla and at the lower border of the pectoralis minor,

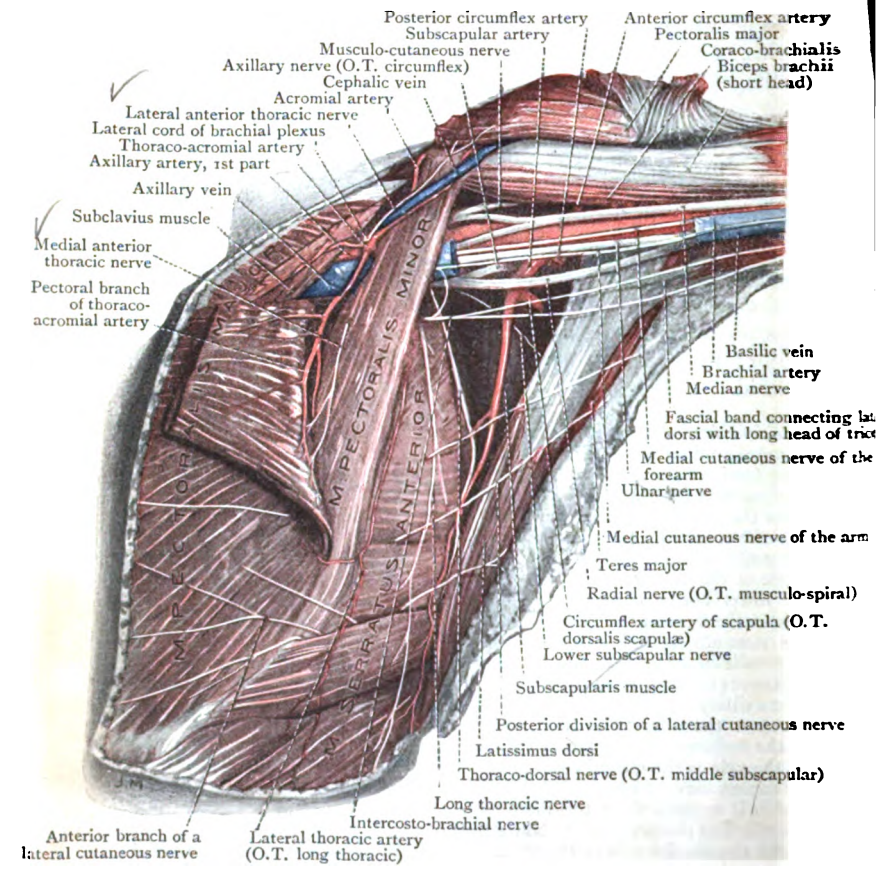


FIG. 8.—The contents of the Axillary Space exposed by the reflection of the Pectoralis Major and the subjacent fascia, and the removal of the fat and glands.

find the lateral thoracic artery ; clean the artery and the medial group of axillary lymph glands, which lie along its course.

At the junction of the posterior third and anterior two-thirds of the medial wall of the axilla find the long thoracic nerve, which supplies the serratus anterior and descends along its lateral surface, from the apex to the base of

the axilla. After the nerve has been secured the serratus anterior must be cleaned. When this has been done the dissector should clean the distal parts of the axillary vessels and nerves and their branches and tributaries. Commence at the lower border of the pectoralis minor and find the subscapular artery. It springs from the medial and posterior part of the axillary trunk and runs distally and medially along the lower border of the subscapularis muscle. Follow the artery and, whilst doing so, clean the posterior group of the axillary lymph glands which lie along its course, and secure the thoracodorsal nerve (O.T. long subscapular), which joins the artery near the junction of the lateral and posterior walls of the axilla and terminates in the latissimus dorsi, which it supplies. Arising from the upper part of the subscapular artery is its large circumflex scapular branch, which passes backwards through the posterior wall of the axilla. In the angle between this branch and the main trunk will be found the lower subscapular nerve, which supplies the teres major and the lower fibres of the subscapularis.

The dissector should now thoroughly clean the distal parts of the axillary artery and vein; the medial cutaneous nerve of the forearm, which lies in the angle between them anteriorly; and the median cutaneous nerve of the arm, which lies along the medial side of the vein; then he should pull the vein forwards and laterally, and in the angle between it and the artery, posteriorly, he will find the ulnar nerve; this also should be pulled forwards and laterally to display the axillary (O.T. circumflex) nerve, which turns backwards at the lower border of the subscapularis above the level of the circumflex scapular artery, and the radial (O.T. musculo-spiral) nerve, which descends behind the axillary artery to the lower border of the axilla.

Springing from the proximal part of the radial nerve are its *posterior brachial cutaneous* branch, and muscular branches to the long and medial heads of the triceps muscle; these branches may rise separately from the radial nerve or they spring from it by a common trunk which afterwards divides into the individual branches. Trace the posterior brachial cutaneous nerve to the back of the arm, behind the intercosto-brachial nerve; follow the nerve to the long head of the triceps till it enters the muscle. The nerve to the medial head of the triceps is usually a long slender branch which is known as the *ulnar collateral nerve*, because it accompanies the ulnar nerve to the distal part of the arm. It will be traced to its termination at a later period. The anterior and posterior humeral circumflex branches of the axillary artery will be found springing from the artery a short distance distal to the subscapular branch, the former arising from the anterior, and the latter from the posterior aspect of the axillary trunk.

When the lower part of the axilla has been thoroughly cleaned, the pectoralis minor must be divided, about midway between its origin and insertion, and the two parts must be turned aside. When this has been done the upper subscapular nerve must be found as it enters the upper part of the subscapularis, and then the remaining areolar tissue must be removed from the axillary space, the trunks and branches of the axillary vessels and nerves must be thoroughly cleaned, and the contents of the space must be studied in detail.

**Lymphoglandulæ Axillares (Axillary Lymph Glands).**—The lymph glands in the axillary region are spoken of, collectively, as the axillary glands, but for convenience of description, and to facilitate a more precise knowledge of their connections and associations, they are subdivided into

several subordinate groups. Some of the glands have been removed as the dissection proceeded, and others are so small that they may have escaped the attention of the dissector; but if he has followed the directions given above he will have noted at least four groups of glands. (1) A lateral or brachial group consisting of six or more glands, which extend along the axillary vessels. They receive the lymph vessels

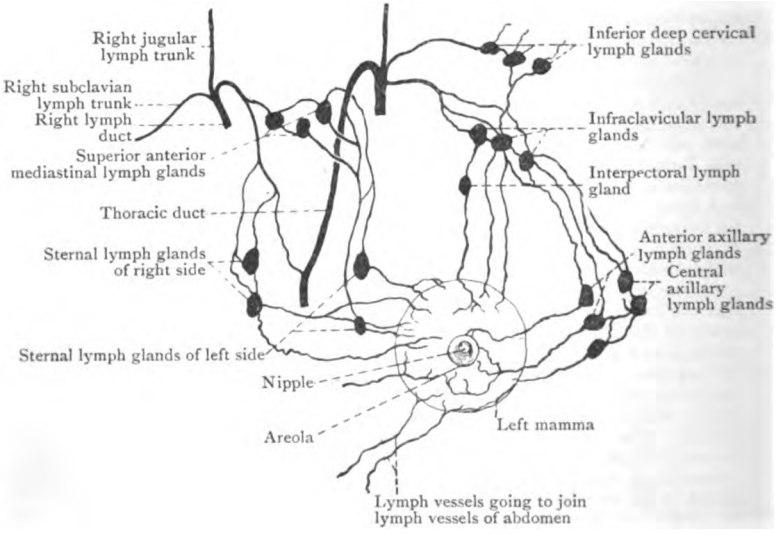


FIG. 9.—Diagram of the Connections of the Lymph Vessels of the Mamma.

from the greater part of the upper extremity, and those at the upper part of the chain also receive lymph from the deep part of the mamma. (2) A pectoral group, or anterior group, which lies in the angle between the anterior and medial walls of the axilla. This is subdivisible into two parts: (*a*) an upper group of two or three small glands which lie beneath the pectoralis major in the region of the second and third intercostal spaces—these receive lymph from the anterior wall of the thorax and from the lateral two-thirds of the mamma; (*b*) an inferior group which lies along the posterior border of

the lateral thoracic artery, and receives lymph from the lateral wall of the thorax. (3) A posterior or subscapular group, which lie along the subscapular artery on the posterior wall of the axilla, and receive lymph vessels from the back. (4) The delto-pectoral glands, a group of two or three small glands which lie in the delto-pectoral triangle and receive lymph from the proximal and lateral parts of the arm. In addition, a central and an infraclavicular group of glands are described. The central group lies either on the superficial aspect of the axillary fascia, in a pocket of its substance, or deep to the axillary fascia, embedded in the adipose tissue of the axilla. The infraclavicular glands, from one to eleven in number, lie in the apex of the axilla; they receive afferent vessels from all the lower groups, and their efferents unite together to form the *subclavian lymphatic trunk*. The student should note that although the various subgroups are more or less separate, and are particularly associated with definite regions from which they receive lymph, nevertheless they are linked together by lymph vessels; therefore micro-organisms which have gained entry into the lymph stream, and lymph-borne cancer cells, can readily pass from one subgroup to another.

**Rami Laterales** (O.T. **Lateral Cutaneous Branches**) **of the Anterior Branches of the Second and Third Thoracic Nerves.**—As a rule, the first thoracic nerve does not give off a lateral branch. That which springs from the second thoracic nerve is the largest of the series, and differs from the others in not dividing into an anterior and a posterior branch. It is termed the *intercosto-brachial nerve*, on account of its being distributed to the skin on the medial and dorsal aspects of the proximal part of the arm. To reach this destination it crosses the axilla and pierces the deep fascia. But before doing so it establishes communications and forms a plexiform arrangement in the axilla with the medial cutaneous nerve of the arm, and the lateral branch of the third thoracic nerve. This plexus may be joined by another twig, which is occasionally present, viz., the minute lateral cutaneous branch of the first thoracic nerve.

The *lateral branch* of the third thoracic nerve divides into an anterior and posterior part, which are distributed in the ordinary way. From the posterior branch twigs are given to the skin of the axilla, and the terminal twigs are distributed

to the integument on the proximal part of the medial aspect of the arm.

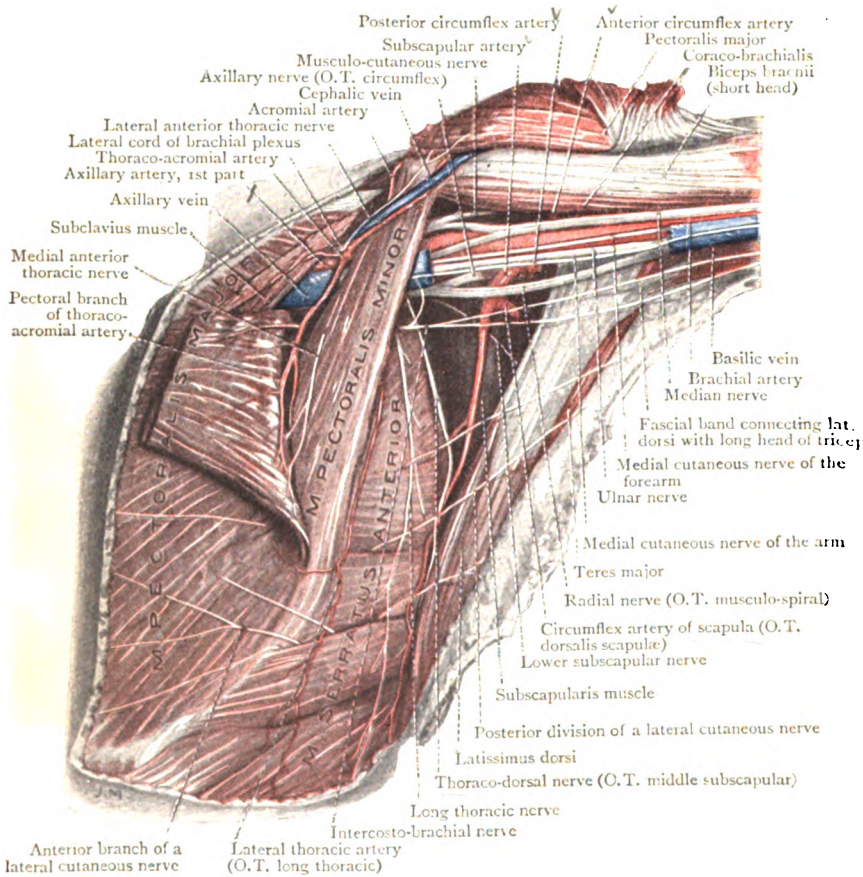


FIG. 10.—The contents of the Axillary Space exposed by the reflection of the Pectoralis Major and the subjacent fascia, and the removal of the fat and the lymph glands.

**Arteria Axillaris.**—The axillary artery is the chief artery of the upper limb. It commences as the continuation of the subclavian artery, and enters the axilla at its apex, at the outer border of the first rib. It lies, for a short distance,

on the medial wall of the axilla, crosses the interval between the medial and posterior walls, and then runs along the lateral wall, to the lower border of the teres major, where it leaves the axilla, and, passing into the arm, becomes the brachial artery. For convenience of description it is usually divided into three parts—the part above, the part behind, and the part below the pectoralis minor, which are known respectively as the first, second, and third parts. The direction of the course of the artery varies with the position of the limb. When the arm is at a right angle with the body, the direction is that of a straight line from the centre of the clavicle to the middle of the bend of the elbow. When the arm is by the side, the artery describes a curve with the convexity directed laterally; and if the arm is raised above the head the curve formed by the artery is convex in the reverse direction.

The *first part* of the axillary artery lies very deeply. It is covered by the skin, superficial fascia, deep fascia, clavicular part of the pectoralis major, the costo-coracoid membrane, and the vessels and nerves superficial to it. But, even when these are removed, the vessel is not completely exposed, because it is enveloped, along with the axillary vein and great nerves, by a funnel-shaped sheath, which is prolonged upon them from the deep cervical fascia, and is crossed by the loop of communication between the two anterior thoracic nerves, which lies in front of the sheath. *Posteriorly*, this part of the vessel is supported by the first intercostal space and the first digitation of the serratus anterior muscle; and the long thoracic nerve and the medial cord of the brachial plexus cross behind it. To its *medial side*, and somewhat overlapping it, is the axillary vein, whilst *above* and to its *lateral side* are the lateral and posterior cords of the brachial plexus.

The *second part* of the axillary artery is placed behind the two pectoral muscles, and has the three cords of the brachial plexus disposed around it. Thus, the medial cord lies upon its medial side, the lateral cord upon its lateral side, and the posterior cord behind it. The axillary vein is still upon its medial side, but is separated from the artery by the medial nerve-cord. Strictly speaking, it is not in apposition with any muscle posteriorly, being separated from the subscapularis muscle by areolo-fatty tissue.

The *third* and *longest part* of the axillary artery is superficial

in its distal half. This is due to the fact that the posterior wall of the axilla extends more distally than the anterior wall. Whilst, therefore, it is covered in its proximal half by the pectoralis major, below that it is covered only by the skin and fascia. Behind it, proximo-distally, are the subscapularis, the tendon of the latissimus dorsi, and the teres major; but it is separated from the subscapularis muscle by the axillary (O.T. circumflex) and radial (O.T. musculo-spiral) nerves, and from the latissimus dorsi and the

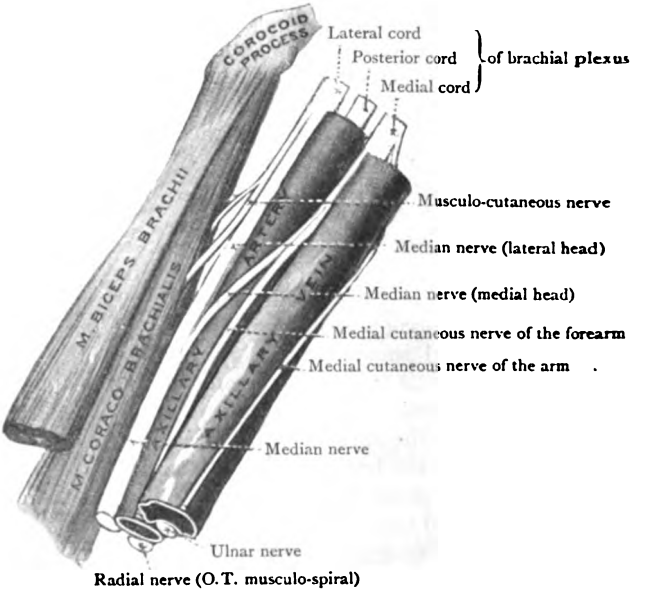


FIG. 11.—Diagram to show relation of Axillary Vessels and Nerves.

teres major by the radial nerve. To its lateral side is the coraco-brachialis muscle, but between the muscle and the artery are the musculo-cutaneous and the median nerves. To the medial side of the artery is the vein, with the medial cutaneous nerve of the forearm in the angle between the artery and vein anteriorly, and the ulnar nerve in the angle between the artery and vein posteriorly. The medial cutaneous nerve of the arm lies along the medial side of the vein.

The **branches of the axillary artery** have been seen at

different stages of the dissection. They may now be examined more fully. They are:—

| | | | |
|---|---|---|---|
| A. thoracalis suprema | from the first part. | A. subscapularis | from the third part. |
| A. thoraco-acromialis | from the second part. | A. circumflexa humeri anterior | |
| A. thoracalis lateralis | | A. circumflexa humeri posterior | |

**Supreme Thoracic Artery** (O.T. **Superior Thoracic**).—The supreme thoracic artery is a small branch which springs from the axillary at the lower border of the subclavius. It ramifies upon the upper part of the medial wall of the axilla and supplies twigs to adjacent structures.

**Thoracoacromial Artery** (O.T. **Acromio-thoracic or Thoracic Axis**).—The thoraco-acromial artery is a short, wide trunk, which takes origin under cover of the pectoralis minor. It winds round the upper border of that muscle, pierces the costo-coracoid membrane, and immediately divides into numerous branches, which diverge widely from each other. These receive different names, and are arranged as follows:—(*a*) The *clavicular branch*, a small twig, which runs upwards to the clavicle and then turns medially along that bone, between the clavicular part of the pectoralis major and the costo-coracoid membrane. (*b*) The *pectoral branches*, of larger size, proceed downwards between the two pectoral muscles, give branches to both, and they anastomose with the lateral thoracic and the lateral branches of the intercostal arteries. (*c*) The *acromial branch* runs laterally, upon the tendon of the pectoralis minor and the coracoid process. Some of its twigs supply the deltoid, whilst others pierce it to reach the superior surface of the acromion. It anastomoses with the transverse scapular (O.T. suprascapular) and posterior humeral circumflex arteries. (*d*) The *deltoid branch*, as a rule, takes origin from a trunk common to it and the preceding artery. It runs distally in the intermuscular interval between the pectoralis major and the deltoid, and supplies both muscles.

**Lateral Thoracic Artery** (O.T. **Long Thoracic**).—The lateral thoracic artery takes the lower border of the pectoralis minor as its guide, and proceeds downwards and medially to the side of the thorax. It gives branches to the neighbouring muscles, and it anastomoses with twigs from the intercostal arteries. It also supplies the mamma, giving off, as a rule, an *external mammary branch*, which winds round or pierces the lower border of the pectoralis major on its way to the gland.

**Alar Thoracic.**—This small artery supplies the fat and lymph glands in the axilla, but it is rarely present as a separate branch, and its place is usually taken by twigs from the subscapular and lateral thoracic arteries.

**Subscapular Artery.**—The subscapular artery is the largest branch of the axillary artery. It arises opposite the inferior border of the subscapularis muscle, and, following this, it runs downwards and backwards, to the inferior angle of the scapula, where its terminal twigs anastomose with the descending branch of the transverse cervical artery. In the lower part of its course it is accompanied by the thoraco-dorsal nerve. Not far from its origin the subscapular artery gives off a large branch, the *circumflex scapular artery*, which winds round the axillary border of the scapula, in close contact with the bone, to reach its dorsal aspect. Numerous smaller twigs are given to the neighbouring muscles.

**Humeral Circumflex Arteries** (O.T. **Anterior and Posterior Circumflex Arteries**).—These are two in number, and, as a rule, they both arise from the axillary at the same level, a short distance distal to the origin of the subscapular artery. The *posterior humeral circumflex artery* is much the larger of the two. Only a small portion of it can be seen at the present stage. It springs from the posterior aspect of the axillary, and at once proceeds backwards, with the axillary nerve, close to the medial and dorsal aspect of the head of the humerus, and in the interval between the subscapularis and teres major muscles. The small *anterior humeral circumflex artery* takes origin from the lateral aspect of the axillary, and runs laterally, in front of the surgical neck of the humerus, under cover of the coraco-brachialis and short head of the biceps brachii. Reaching the intertubercular sulcus, it divides into two branches. Of these, one is directed proximally, along the long head of the biceps brachii, to the shoulder-joint; the other passes laterally, to the deep surface of the deltoid, and finally anastomoses with some of the terminal twigs of the posterior circumflex artery of the humerus.

**Vena Axillaris.**—The axillary vein has the same extent as the artery. It begins at the lower border of the teres major, as the proximal continuation of the basilic vein of the arm, and it becomes the subclavian vein at the outer margin of the first rib. At the lower margin of the subscapularis it receives the two *venæ comites* of the brachial artery, and above the level of the pectoralis minor it is joined by the

cephalic vein. Its other tributaries correspond, more or less closely, to the branches of the axillary artery.

**M. Subclavius.**—The subclavius is a small muscle which lies immediately below the clavicle, enclosed between the two layers of the costo-coracoid membrane. It takes origin, by a short rounded tendon, from the superior surface of the first costal arch, at the junction of the bone with the cartilage, and the fleshy belly is inserted into the shallow groove on the inferior surface of the clavicle. The nerve of

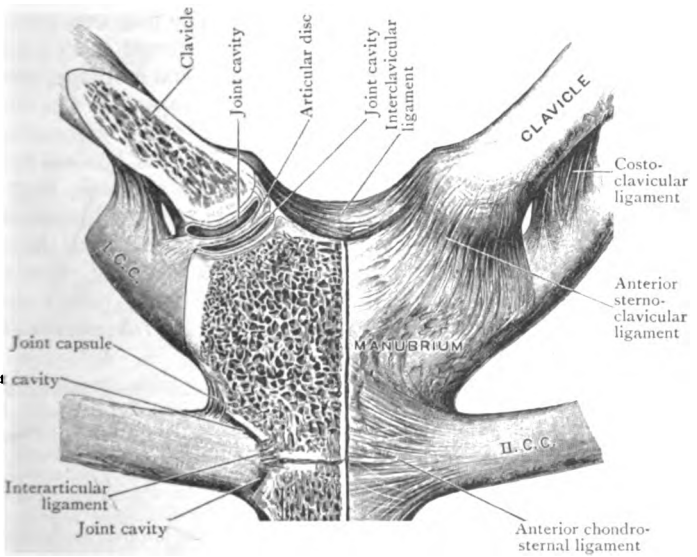


FIG. 12.—Sterno-clavicular and Costo-sternal Joints.

supply is derived from the fifth cervical nerve and enters the posterior surface of the muscle. When the muscle contracts it depresses the clavicle and draws it slightly forwards.

*Dissection.*—When the subclavius has been examined it must be divided horizontally, and when this has been done the costo-clavicular ligament will be found behind the medial end of the muscle.

The clavicle must now be detached from the sternum and the cartilage of the first rib, and turned laterally so that the brachial plexus may be properly examined, but before this is done the sterno-clavicular joint should be studied. With the assistance of the dissector of the head and neck the clavicular part of the sterno-cleido-mastoid muscle must be

detached from the superior border of the clavicle and the sternal part of the muscle must be pulled towards the median plane.

**Articulatio Sternoclavicularis.**—The sterno-clavicular joint is a diarthrodial joint, formed by the sternal end of the clavicle, the lateral part of the superior border of the manubrium sterni, and the superior surface of the sternal end of the cartilage of the first rib. It helps to increase the range of the forward, backward, and upward movements of the arm. The clavicle is attached to the sternum and the first rib by a strong fibrous capsule. Within the capsule is an articular disc which separates the joint cavity into two parts. It is attached to the superior border of the sternal end of the clavicle, to the superior surface of the first costal cartilage, and to the anterior and posterior parts of the capsule. On the lateral aspect of the capsule there is a strong accessory ligament, the *costo-clavicular ligament*, which lies behind the origin of the subclavius muscle and passes upwards, backwards, and laterally from the first rib to the costal tubercle on the lower surface of the clavicle. In the capsule itself there are three thickened bands, an anterior, a posterior, and a superior, and as some of the fibres of the latter pass from one clavicle to the other, it is called the *interclavicular ligament.*

*Dissection.*—Pull the sternal head of the sterno-cleido-mastoid muscle towards the median plane. Cut through the anterior part of the capsule of the joint close to the sternum. Pass the knife behind the capsule, avoiding the anterior jugular vein, which runs laterally behind the upper border of the joint, and detach the fibres of origin of the sterno-hyoid muscle which spring from the back of the capsule. Cut through the posterior ligament and pull the clavicle laterally. The articular disc is now exposed. Detach it from the first rib; then carry the knife laterally below the clavicle and cut through the lower part of the capsule and the costo-clavicular ligament. The clavicle can now be displaced sufficiently upwards and laterally to bring the whole of the brachial plexus into view. Before studying the plexus, the dissector should note that behind the sterno-clavicular joint there are the lower fibres of the sterno-hyoid and sterno-thyreoid muscles which intervene, on the right side, between the capsule of the joint and the bifurcation of the innominate artery into its right common carotid and subclavian branches, and, on the left side, between the joint and the left common carotid artery.

**Plexus Brachialis (Brachial Plexus).**—This important plexus is formed by the anterior rami of the lower four cervical nerves and the greater part of the large anterior branch of the first thoracic nerve. Above, the plexus is further reinforced by a small twig of communication which passes from the fourth to the fifth cervical nerve, whilst below,

a similar connecting twig not infrequently passes upwards, in front of the neck of the second rib, from the second to the first thoracic nerve. The manner in which these great nerves join to form the plexus is very constant. The *fifth* and *sixth*

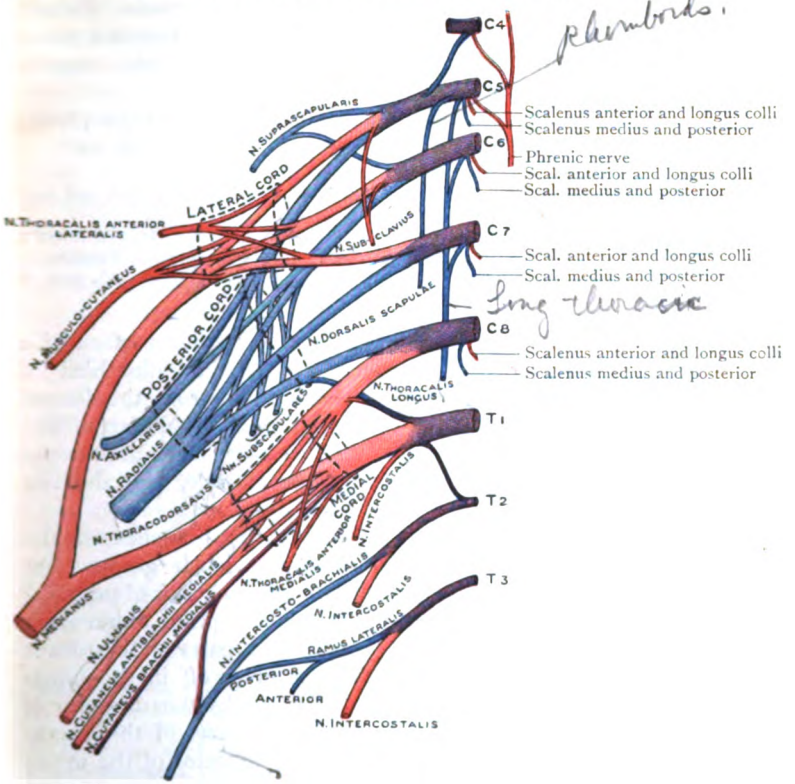


FIG. 13.—Diagram of the Brachial Plexus. (After Paterson.)

*cervical nerves* unite to form an *upper trunk*; the *seventh* remains single and proceeds distally as a *middle trunk*; whilst the *eighth* and *first thoracic nerves* join, close to the intervertebral foramina, to constitute a *third* or *lower trunk*. A short distance above the clavicle each of the three trunks splits into an *anterior* and a *posterior division*. Raise the three anterior divisions on the handle of the knife, and it will be

seen that all the three posterior divisions unite to form the *posterior cord* of the plexus, and, further, that the lowest or most medial of these divisions is much smaller than the other two. Of the three anterior divisions the *two lateral* join to constitute the *lateral cord*, whilst the *medial* passes distally by itself, as the *medial cord* of the plexus. From the three cords of the plexus are given off the branches which supply the upper extremity.

From the above description it will be seen that the plexus may be divided into four stages:—

| | |
|---|---|
| *First Stage*, . . | Five separate nerves (viz., lower four cervical and first thoracic). |
| *Second Stage*, . | Three nerve-trunks (viz., an upper, middle, and lower). |
| *Third Stage*, . | Three anterior divisions and three posterior divisions. |
| *Fourth Stage*, . | Three nerve-cords (viz., a lateral, a medial, and a posterior). |

The plexus lies in the lower and medial part of the posterior triangle of the neck, behind the middle third of the clavicle, and in the axilla; extending from the lateral border of the scalenus anterior to the lower border of the pectoralis minor. As a rule, the first two stages are in the neck, the third stage is behind the clavicle, and the last stage is in the axilla.

It has been customary to divide the branches of the plexus into supraclavicular and infraclavicular groups, but such a division is neither scientifically accurate nor of practical importance. The branches of the plexus spring either from its roots, or its trunks, or its cords. The parts of the plexus above the clavicle, and the branches given off in the supraclavicular region, are found and cleaned by the dissector of the head and neck, and the remaining parts of the plexus and its branches are displayed by the dissector of the upper extremity, but the two dissectors must combine to examine thoroughly the general relations and the branches of the plexus.

**The Relations of the Plexus.**—*Superficial to* the cervical part of the plexus lie the skin, the superficial fascia, the platysma, the deep fascia, the external jugular vein, the transverse cervical and transverse scapular veins, the posterior belly of the omo-hyoid muscle, and the transverse cervical artery. *Behind it* is the scalenus medius muscle.

In the interval between the neck and the axilla, the clavicle

and the transverse scapular artery and vein are in front of it; and the third part of the subclavian artery is anterior to its lowest trunk. The scalenus medius is still behind it.

In the axilla it has *in front of it* the integument, the fasciæ, the platysma, the pectoralis major, the pectoralis minor, the costo-coracoid membrane, the cephalic vein, and the axillary artery; *behind it* lie the upper serration of the serratus anterior, the fascia-filled interval between the medial and posterior walls of the axilla, and the subscapularis muscle.

**The Branches of the Plexus.**—The branches from the roots of the plexus are: (1) Branches to the scalenus anterior, the longus colli, the scalenus medius, and the scalenus posterior (from C. v., vi., vii., viii.). (2) A communication to the phrenic nerve (from C. v., or v. and vi.). (3) The dorsalis scapulæ nerve, which supplies the rhomboid muscles (from C. v.). (4) The long thoracic nerve, which supplies the serratus anterior (from C. v., vi., vii.).

The branches from the trunks of the plexus are: (1) The nerve to the subclavius, from the upper trunk (from C. v., vi.). It has already been seen piercing the posterior surface of the costo-coracoid membrane and entering the posterior aspect of the subclavius (p. 27). (2) The suprascapular nerve, from the upper trunk (from C. v., vi.). It will be found crossing the lower part of the posterior triangle, deep to the posterior belly of the omo-hyoid muscle, and disappearing through the scapular notch on its way to the dorsum scapulæ.

The branches from the cords are—

From the lateral cord:

**Nervus thoracalis anterior lateralis** (O.T. **External Anterior Thoracic**) (from C. v., vi., vii.).

**N. musculocutaneus** (from C. v., vi., vii.).

**N. medianus, caput lateralis** (O.T. **Outer Head of Median**) (from C. v., vi., vii.).

From the medial cord:

**N. thoracalis anterior medialis** (O.T. **Internal Anterior Thoracic**) (from C. viii., T. i.).

**N. cutaneus antibrachii medialis** (O.T. **Internal Cutaneous**) (from C. viii., T. i.).

**N. cutaneus brachii medialis** (O.T. **Lesser Internal Cutaneous**) (from T. i.).

**N. medianus, caput medialis** (O.T. **Inner Head of Median**) (from C. viii., T. i.).

**N. ulnaris** (from C. viii., T. i.).

From the posterior cord:

**Nn. subscapulares** (O.T. **Upper and Lower**) (from C. v., vi.).

**N. thoracodorsalis** (O.T. **Long Subscapular**) (from C. VI., VII., VIII.).
**N. axillaris** (O.T. **Circumflex**) (from C. V., VI.).
**N. radialis** (O.T. **Musculospiral**) (from C. V., VI., VII., VIII. T. 1).

In the above table the different spinal nerves from which the fibres of the several branches are derived are indicated.

**Anterior Thoracic Nerves.**—The anterior thoracic nerves supply the pectoral muscles. They are two in number, the lateral and the medial. The *lateral anterior thoracic nerve* springs from the lateral cord of the plexus, passes forwards across the lateral side of the first part of the axillary artery, communicates, in front of the artery, with the medial nerve, pierces the costo-coracoid membrane, and breaks up into branches which end in the pectoralis major. The *medial anterior thoracic nerve* is somewhat smaller than its lateral companion. It springs from the medial cord of the plexus, passes forwards between the axillary artery and vein, communicates, in front of the artery, with the lateral nerve, gives twigs of supply to the pectoralis minor, then pierces that muscle and ends in the pectoralis major, which it also supplies. The pectoralis major is, therefore, supplied by both anterior thoracic nerves, the pectoralis minor by the medial nerve alone.

**Subscapular Nerves.**—The subscapular nerves also are two in number—the *upper* and the *lower*. They both spring from the posterior cord of the plexus. After a very short course the upper nerve sinks into the upper and posterior part of the subscapularis, which it supplies. The lower subscapular nerve passes downwards and laterally, gives branches to supply the lower part of the subscapularis, then passes through the angle between the subscapular artery and its circumflex scapulæ branch and ends in the teres major, which it supplies.

**Thoraco-dorsal Nerve** (O.T. **Long Subscapular Nerve**).—The thoraco-dorsal nerve springs from the posterior cord of the plexus, passes obliquely downwards and laterally, through the axilla, and joins the subscapular artery near the lower part of the lateral border of the subscapularis muscle. After crossing in front of the artery it terminates in the latissimus dorsi, which it supplies.

**Long Thoracic Nerve** (O.T. **Posterior Thoracic or External Respiratory Nerve of Bell**).—The long thoracic nerve may now be studied in its whole length. It passes

downwards on the lateral surface of the serratus anterior, and is the nerve of supply to that muscle. It arises in the root of the neck, from the brachial plexus, by three roots. The upper two roots (one from the fifth cervical and the other from the sixth cervical nerve) pierce the scalenus medius, and, uniting

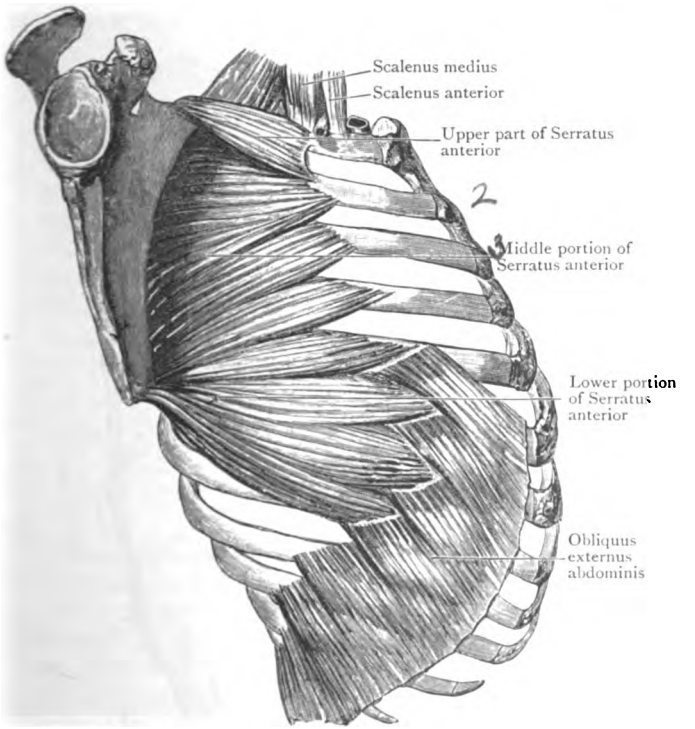


FIG. 14.—Serratus Anterior muscle and origin of the External Oblique muscle; the scapula is drawn away from the side of the chest.

into one stem, give off branches to the upper part of the serratus anterior. The third root takes origin from the seventh cervical nerve, passes in front of the scalenus medius, and runs downwards for a considerable distance on the surface of the serratus anterior, before it unites with the other part of the nerve. The entire nerve can be followed to the lower part of the serratus anterior, giving twigs to each of its digitations,

**M. Serratus Anterior** (O.T. **Serratus Magnus**).—The serratus anterior arises by fleshy digitations from the upper eight ribs, about midway between their angles and cartilages.

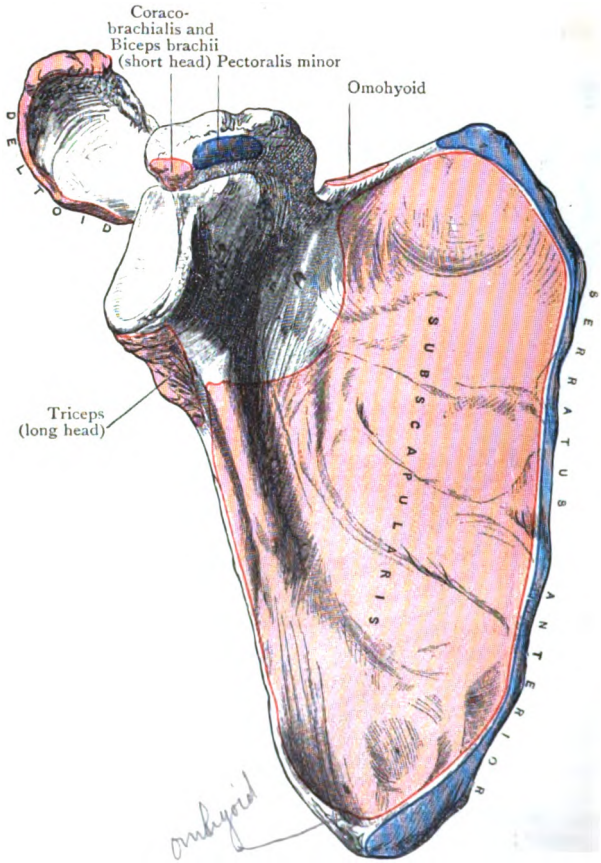


FIG. 15.—Costal aspect of the Scapula with the Attachments of Muscles mapped out.

The slips are arranged on the chest wall so as to present a gentle curve convex forwards. The lower three interdigitate with the external oblique muscle of the abdomen. The serratus anterior is inserted into the entire length of the anterior lip of the vertebral margin of the scapula, and it falls

naturally into three parts. (*a*) The *upper part*, composed of the large first digitation alone, arises from the first and second ribs, and from a tendinous arch between them. The fibres converge, to be inserted into a somewhat triangular surface on the costal aspect of the medial angle of the scapula. (*b*) The *middle part* consists of two digitations which take origin from the second and third ribs. The upper slip is very broad, and springs from the lower border of the second rib. The fibres diverge to form a thin muscular sheet, which is inserted into the anterior lip of the vertebral margin of the scapula, between the insertions of the upper and lower portions. (*c*) The *lower part* is formed by the remaining digitations of the muscle. These converge to form a thick mass, which is inserted into a rough surface upon the costal aspect of the inferior angle of the scapula. The deep surface of the serratus anterior is in contact with the chest wall. It is the most powerful protractor of the upper extremity.

*Dissection.*—At the end of the fifth day, after the dissector has examined the serratus anterior and carefully revised the contents of the axilla, he must replace the clavicle, pack the axilla with tow or rags steeped with preservative solution and fix the skin flaps to the wall of the thorax with a few stitches. When he returns on the sixth day he will find that the body has been placed upon its face, with blocks supporting the chest and the pelvis. It will remain in this position for five days, and during the first two of these the dissector of the upper extremity must examine the structures which connect the limb with the posterior aspect of the trunk.

**Surface Anatomy.**—In the median line of the back there is little difficulty in recognising the tips of the spinous processes of the vertebræ. These follow each other in consecutive order, and it may be noted, when the finger is passed over them, that all of them do not lie in the median plane; some may be deflected, in a slight degree, to one side or the other. The spines of the vertebræ are the only parts of the vertebral column which come to the surface; they alone yield direct information, by touch, to the surgeon as to the condition of the spine. At the lower end of the neck, the spine of the seventh cervical vertebra (*vertebra prominens*) makes a visible projection; and the spines of the first two thoracic vertebræ are likewise very prominent. As a rule, the most evident of the three is that of the first thoracic vertebra. At a lower level, in subjects of good muscular development, a median furrow is produced by the prominence of the sacrospinalis muscle on each side, and

the spines of the vertebræ may be felt at the bottom of

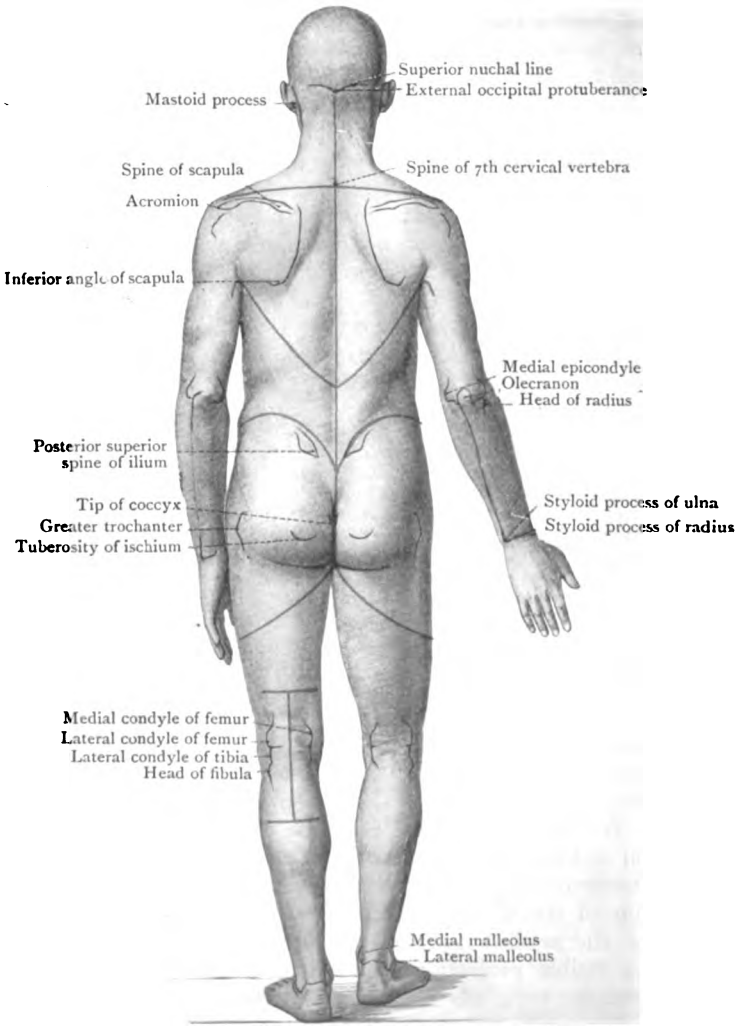


FIG. 16.—Surface View showing Incisions and Bony Points.

the groove. The furrow attains its greatest depth in the

upper part of the lumbar region, and it fades away, below, at the level of the spine of the third sacral vertebra. The finger should next be passed along the crest of the ilium as it pursues its sigmoid course laterally and forwards. The highest point of the iliac crest corresponds in level with the spine of the fourth lumbar vertebra, and the posterior superior spine of the ilium can be easily detected, seeing that its position is indicated by a small but distinct depression or dimple on a level with the second sacral spine.

The scapula, or shoulder blade, is for the most part thickly covered by muscles; but, in spite of this, its general outline can be made out. It covers a considerable area of the upper portion of the posterior aspect of the thorax. With the hand by the side its medial angle lies over the second rib, the root of its spine is placed opposite the spine of the third thoracic vertebra, whilst its inferior angle reaches down as far as the seventh, or even the eighth, rib. The scapula is very mobile, and moves to a greater or less degree with every movement of the limb. The spine and acromion of the scapula are subcutaneous throughout. Below the scapula the lower five ribs can be felt, and the tip of the last rib can be made out at a point about two inches above the iliac crest.

## DISSECTION OF THE BACK.

In this dissection the following are the parts which require to be examined:—

1. The cutaneous vessels and nerves of the back.
2. The trapezius muscle.
3. The latissimus dorsi muscle.

} 1st day.

4. The rhomboid muscles and their nerves.
5. The levator scapulæ muscle.
6. The accessory nerve and the nerves from the cervical plexus which supply the trapezius.
7. The transverse artery of the neck and its two terminal branches (viz., the descending and the ascending).
8. The posterior belly of the omo-hyoid muscle.
9. The transverse artery of the scapula and the suprascapular nerve.

} 2nd day.

This dissection must be completed *in two days*, in order that the dissector of the head and neck may be enabled to continue the deeper dissection of the back. The *first day's work*

should comprise—(1) the reflection of the skin; (2) the dissection of the cutaneous nerves and vessels; and (3) the cleaning of the latissimus dorsi and trapezius muscles. The remainder of the dissection can be undertaken on *the second day.*

**Reflection of the Skin.**—The following incisions are necessary:—1. From the tip of the coccyx, at the lower end of the vertebral column, upwards, along the median line of the body, to the spine of the seventh cervical vertebra. 2. From the upper end of 1 transversely, to the tip of the acromion of the scapula. 3. From the lower extremity of the median incision in a curved direction laterally and forwards, along the crest of the ilium, to within two inches of the anterior superior iliac spine. 4. An oblique incision from the spine of the first lumbar vertebra, upwards and laterally, to the posterior fold of the axilla, and along the latter to the arm. The two large flaps which are now mapped out upon the back must be carefully raised from the subjacent fatty tissue. Reflect the upper triangular flap first, and then the lower flap.

**Panniculus Adiposus (Superficial Fascia).**—In subjects which have been allowed to lie for some time on the back the superficial fascia is usually more or less infiltrated with fluid which has gravitated into its meshes; otherwise it has the ordinary characters of superficial fascia (p. 5).

*Dissection.*—In searching for the cutaneous nerves cut boldly down through the superficial fascia, in the direction in which the nerves run (Fig. 17), until the plane is reached at which the superficial and deep fascia blend. It is there that the main trunks are to be found, and in a well injected subject the cutaneous arteries will serve as guides. A more rapid way of finding the cutaneous nerves in this region is to reflect the superficial and deep fascia laterally, from the vertebral spines, in one layer; the nerves are then found as they issue from the muscles. This plan, however, should be adopted only by the senior student.

**Nervi Cutanei, Vasa Cutanea (Cutaneous Nerves and Vessels).**—The *cutaneous nerves* of the back are derived from the posterior branches of the spinal nerves. As the posterior branches pass backwards, they subdivide into medial and lateral divisions. Both of these supply twigs to the muscles amongst which they lie; but one or the other also contains some sensory fibres which come to the surface, in the shape of a cutaneous nerve, to supply the skin.

In the *thoracic region* the *upper six* or *seven* cutaneous nerves are the terminations of the medial branches of the posterior rami of the thoracic nerves. They become superficial close to the vertebral spines, and are to be sought for near the median plane. It is not uncommon to find one or more of them piercing the trapezius, one or two inches

lateral to the line of emergence of the others. The branch which comes from the second thoracic nerve is the largest of the series; and it may be traced laterally, across the spine of

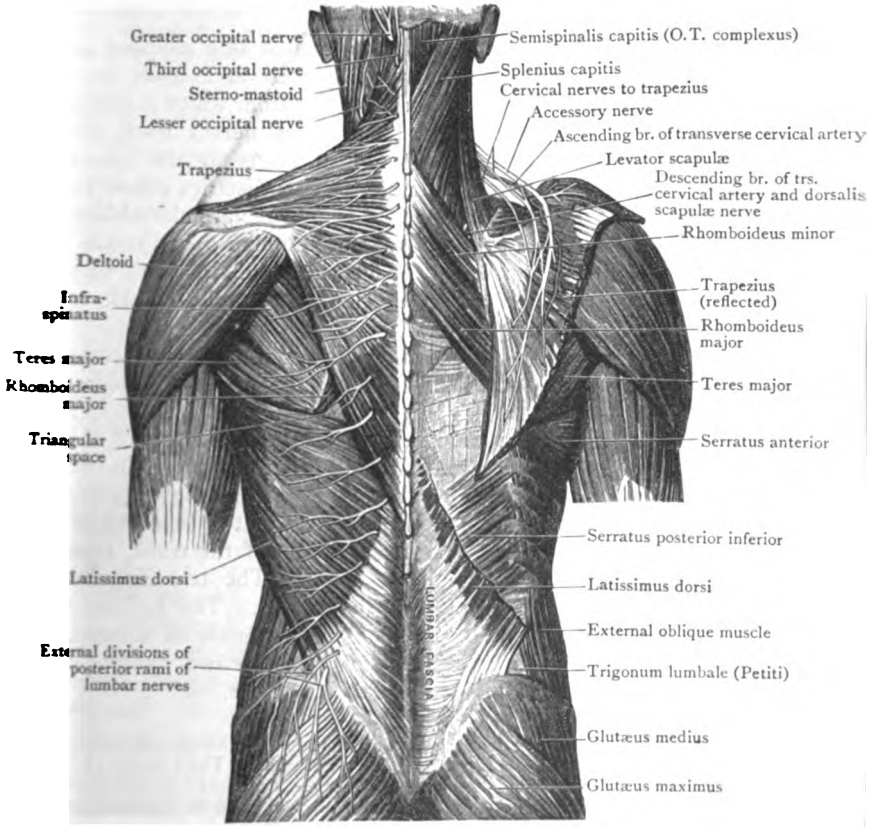


FIG. 17.—Dissection of the Superficial Muscles and Nerves of the Back.

the scapula, towards the shoulder. The *lower five* or *six* cutaneous nerves in the *thoracic region* are the terminal twigs of the lateral branches of the posterior rami of the thoracic nerves; and, consequently, they must be looked for at a short distance from the middle line of the back. They reach the surface by piercing the latissimus dorsi muscle on the

line of the angles of the ribs and the lateral margin of the sacrospinalis muscle. In every case the cutaneous branches derived from the thoracic nerves turn laterally, in the superficial fascia, and may be traced for a varying distance in that direction.

It is important to note that the area of skin supplied by each of these cutaneous nerves is placed at a lower level than the origin of the posterior branches from which it arises.

In the *lumbar region* three cutaneous nerves reach the surface by piercing the lumbo-dorsal fascia at the lateral margin of the sacrospinalis muscle, a short distance above the ilium. They are the terminal twigs of the lateral divisions of the posterior rami of the upper three lumbar spinal nerves; and they differ from those above, inasmuch as they turn downwards over the crest of the ilium to supply the skin of the gluteal region (Fig. 17).

The *cutaneous arteries* which accompany these nerves come from the posterior branches of the intercostal and lumbar arteries.

**Muscles connecting the Limb to the Dorsal Aspect of the Trunk.**—These are five in number, and are arranged in two strata. Two form the *superficial stratum*, viz., the trapezius and the latissimus dorsi. Both are broad, flat muscles which cover the greater part of the dorsal aspect of the trunk, from the occiput above to the ilium below. The trapezius lies over the back of the neck and the thorax. The latissimus dorsi is placed lower down. The *deeper stratum* of muscles, composed of the levator scapulæ and the two rhomboid muscles, is placed under cover of the trapezius.

*Dissection.*—The trapezius should now be cleaned. This muscle belongs only in part to the dissector of the upper extremity. The portion of it which lies above the prominent spine of the seventh cervical vertebra is the property of the dissector of the head and neck, and must be dissected by him. The two dissectors should work in conjunction with each other; and when the entire muscle is exposed, each should give the other an opportunity of studying it in its entirety.

In cleaning the trapezius the limb must be placed in such a position as will render the fibres of the muscle tense. If the dissection is being made on the *right side*, the arm must be placed close to the trunk, and drawn downwards, whilst the scapula is dragged well forwards over the end of the block which supports the thorax. A transverse cut is now to be made through the superficial and deep fasciæ, from the seventh cervical spine laterally. This incision will be found to coincide with the direction of the fibres of the muscle at this level. From this point work gradually downwards, raising both fasciæ in a continuous layer from the surface of

the muscle. The knife must always be carried in the direction of the muscular fibres: and care must be taken to leave none of the thin, filmy deep fascia behind. As the direction of the fibres changes, the position of the arm must also be changed to keep the fibres which are being cleaned on the stretch. In the case of the *left trapezius*, the student must make the incision through the fascia, along the lower margin of the muscle, and work upwards to the level of the seventh cervical vertebra. In removing the fascia from the trapezius, and indeed throughout the whole dissection of the back, the cutaneous nerves must be carefully preserved, in order that the dissector of the head and neck may have an opportunity of establishing their continuity with the trunks from which they arise.

**M. Trapezius.**—The trapezius is a flat, triangular muscle, which lies, in its entire extent, immediately subjacent to the deep fascia. It has a very long origin, which extends along the median plane, from the occiput above to the level of the last thoracic vertebra below. It arises from—(1) the medial

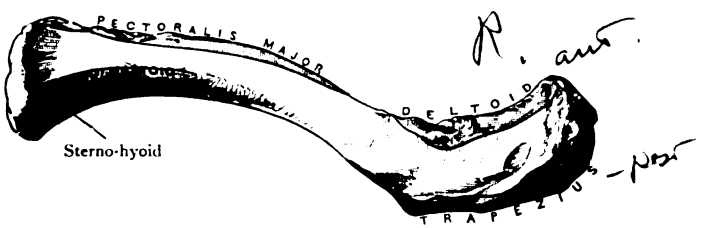


FIG. 18.—Upper Surface of the Right Clavicle.

third or less of the superior nuchal line of the occipital bone and the external occipital protuberance; (2) the ligamentum nuchæ and the spine of the seventh cervical vertebra; (3) the tips of the spines of all the thoracic vertebræ, as well as the supraspinous ligaments which bridge across the intervals between them (Fig. 17).

In the lower cervical and upper thoracic regions the tendinous fibres by which the muscle arises lengthen out so as to form a flat tendon, which, taken in conjunction with the corresponding aponeurosis of the opposite side, exhibits an oval outline.

As the fibres of the trapezius pass laterally they converge, to gain an insertion into the two bones of the shoulder-girdle. The *occipital* and *upper cervical fibres* incline downwards, and, turning forwards over the shoulder, are inserted into the lateral third of the posterior border of the clavicle (Fig. 18); the *lower cervical* and *upper thoracic fibres* pass more or less transversely to gain an insertion into the medial border of

the acromion and the upper margin of the spine of the scapula; while the *lower thoracic fibres* are directed upwards and, at the base of the scapula, end in a flat, triangular tendon, which plays over the smooth surface at the root of the scapular spine, and is inserted into a rough tubercle on the spine of the scapula immediately beyond this (Fig. 24, p. 55). To facilitate the movement of the tendon upon the bone a small bursa mucosa is interposed between them.

The trapezius is supplied by the *accessory nerve* and by twigs from the *third* and *fourth cervical nerves*. It is an elevator and depressor of the shoulder, and an adductor of the scapula.

*Dissection.*—The latissimus dorsi is now to be dissected. It is a difficult muscle to clean, not only on account of the varying direction of its fibres, but also because its upper part is generally very thin, and its upper border ill-defined. Near the spines of the vertebræ its upper portion is overlapped by the trapezius, but in the greater part of its extent it is subcutaneous. Both layers of fascia should be raised at the same time from its surface, and its fibres may be stretched by raising the arm and folding it under the neck. The origin of the latissimus dorsi in the lumbar region is effected through the medium of the superficial lamina of the lumbo-dorsal fascia, a dense tendinous aponeurosis, which covers the sacrospinalis in the loins (Fig. 19). Clean this structure thoroughly. The attachment of the muscle to the crest of the ilium, and its slips of origin from the lower ribs, must be carefully defined; at the same time, the posterior and lower part of the external oblique muscle of the abdomen should be cleaned, so that its relation to the latissimus dorsi may be studied. As the latissimus dorsi sweeps over the inferior angle of the scapula it receives an accession of fibres from that bone. This fleshy slip may be brought into view, when the muscle is cleaned, by relieving the tension of the muscular fibres, and then turning the upper margin of the muscle laterally. The slip in question is apt to be mistaken for a piece of the teres major muscle, upon which it lies.

**M. Latissimus Dorsi.**—The latissimus dorsi is a wide, flat muscle, which covers the back from the level of the sixth thoracic vertebra down to the crest of the ilium (Fig. 17, p. 39). It arises—(1) from the tips of the spinous processes of the lower six thoracic vertebræ and the supraspinous ligaments in connection with them; (2) from the superficial lamella of the lumbo-dorsal fascia (Fig. 19); (3) by a thin tendinous origin from a small extent of the outer lip of the crest of the ilium, in front of the lumbo-dorsal fascia (Fig. 143, p. 385); (4) by three or four digitations from the lower three or four ribs; and (5) by a fleshy slip from the dorsal aspect of the inferior angle of the scapula (Fig. 24, p. 55). By means of its origin from the posterior lamella of lumbo-dorsal fascia, it receives an indirect attachment to the spines of the lumbar and upper sacral

vertebræ, and also to the posterior part of the crest of the ilium. The costal slips of origin interdigitate with the lower digitations of the external oblique muscle of the abdominal wall.

The fibres of the latissimus dorsi converge rapidly as they approach the lower part of the scapula. The highest fibres pass almost horizontally towards this point; the lowest fibres ascend almost vertically; whilst the intermediate

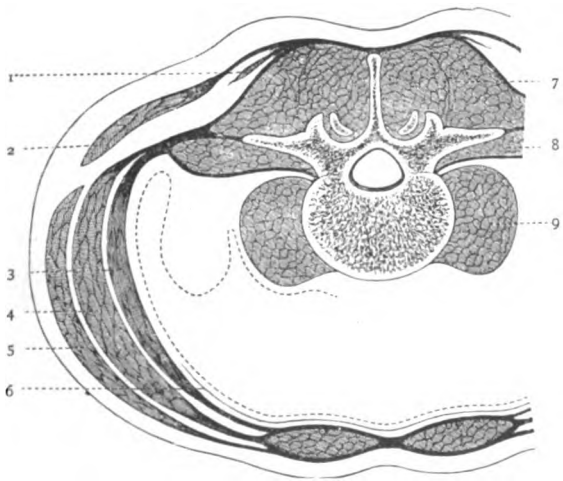


FIG. 19.—Diagram of the Lumbo-dorsal Fascia.

1. Serratus posterior inferior.
2. Latissimus dorsi.
3. Transversus abdominis.
4. Obliquus internus.
5. Obliquus externus.
6. Fascia transversalis.
7. Sacrospinalis.
8. Quadratus lumborum.
9. Psoas major.

fibres show varying degrees of obliquity. As a result of this convergence of fibres, the muscle is greatly reduced in width; and it sweeps over the inferior angle of the scapula in the form of a thick, fleshy band, which winds round the lower margin of the teres major muscle to gain insertion, by means of a narrow, flat tendon, into the floor of the intertubercular sulcus of the humerus (Fig. 33, p. 79). This insertion cannot be studied at present, but will be seen later. With the teres major muscle, the latissimus dorsi forms the posterior fold of the axilla. At first it is placed on the dorsal aspect of

the teres major, then it is folded round its lower border, and finally it is inserted in front of it. To this peculiar relationship of the two muscles is due the full, rounded appearance of the posterior axillary fold.

The latissimus dorsi is supplied by the *thoraco-dorsal nerve*. It is an adductor, retractor, and medial rotator of the upper extremity.

**Two Intermuscular Spaces.**—A triangular space mapped out by the inferior border of the trapezius, the superior border of the latissimus dorsi, and the base of the scapula, will now be noticed (Fig. 22, p. 53). Within these limits a small portion of the rhomboideus major can be seen, and also a varying amount of the wall of the thorax—a part corresponding to the sixth intercostal space and the borders of the ribs which bound it above and below. It is well to note that this is the only part of the thoracic parietes on the posterior aspect of the trunk which is uncovered by muscles. Further, between the last rib and the crest of the ilium the anterior border of the latissimus dorsi will generally be observed to overlap the posterior border of the external oblique muscle of the abdominal wall. Sometimes, however, a narrow triangular interval exists between the two muscles, in which is seen a small part of the internal oblique muscle. This space is termed the *trigonum lumbale* (*Petiti*) (Fig. 17, p. 39).

**Reflection of the Trapezius.**—On the *second day* the dissector should begin by reflecting the trapezius, working, if possible, in conjunction with the dissector of the head and neck. Divide the muscle about two inches from the spines of the vertebræ, and throw it laterally towards its insertion. The trapezius is very thin at its origin, and the greatest care must therefore be taken not to injure the subjacent rhomboid muscles. The small *bursa* between the tendon of insertion of the lower part of the trapezius and the triangular root of the spine of the scapula must not be overlooked.

**Nerves and Vessels of Supply to the Trapezius.**—A dissection of the deep surface of the reflected muscle will reveal the following structures:—

*a*. The accessory nerve.
*b*. Two or three nerves from the cervical plexus.
*c*. The ascending branch of the transverse cervical artery.

These constitute the nervous and vascular supply of the trapezius.

The nerves have already been displayed by the dissector of

the head and neck, as they cross the posterior triangle of the neck. The branches from the cervical plexus come from the *third* and *fourth cervical nerves.* On the deep surface of the trapezius they join with branches of the accessory nerve to form the *subtrapezial plexus*, from which twigs proceed into the substance of the muscle. The terminal twig of the *accessory nerve* can be traced nearly to the lower margin of the trapezius.

The *ascending branch of the transverse cervical artery*, which accompanies the accessory nerve, must be followed to the anterior border of the trapezius, where it will be seen to spring from the trunk of the artery.

*Dissection.* — The posterior belly of the omo-hyoid, the transverse scapular artery, and suprascapular nerve can now be displayed by dissecting towards the upper margin of the scapula and removing, carefully, the loose fatty tissue in this locality. The dissector of the head and neck must take part in this dissection.

**M. Omo-hyoideus.—Arteria Transversa Scapulæ** (O.T. **Suprascapular Artery) and N. Suprascapularis**—The slender *posterior belly of the omo-hyoid muscle* will be seen to arise from the upper margin of the scapula, immediately medial to the scapular notch. It derives fibres also from the ligament which bridges across this notch. It is supplied by a twig from the ansa hypoglossi. The *transverse scapular artery* will be noticed to enter the supraspinous fossa of the scapula by passing over the superior transverse scapular ligament, whilst the *suprascapular nerve* proceeds into the fossa under cover of that ligament.

*Dissection.*—Draw the scapula well over the edge of the block which supports the thorax of the subject. The two rhomboid muscles are thus rendered tense, and the cleaning of their fleshy fasciculi is greatly facilitated. The *dorsalis scapulæ nerve* should be secured at this stage, so that it may be preserved from injury in the further dissection of the region. It can be detected best by dissecting in the interval between the rhomboideus minor and the levator scapulæ, about one inch to the medial side of the medial angle of the scapula (Fig. 17, p. 39). It is accompanied by the descending branch of the transverse cervical artery ; and it will afterwards be traced upon the deep surface of the rhomboid muscles when they are reflected.

**Mm. Rhomboidei.**—The two rhomboid muscles constitute a thin quadrangular sheet of muscular fibres, which proceeds from the spinous processes of the vertebræ to the vertebral margin of the scapula.

The *rhomboideus minor* is a narrow, ribbon-like fleshy

band which runs parallel to the upper border of the major rhomboid. It springs from the lower part of the ligamentum nuchæ, the spine of the seventh cervical vertebra, and frequently also from the spine of the first thoracic vertebræ. It is inserted into the vertebral margin of the scapula opposite the triangular surface at the root of its spine (Fig. 24, p. 55). It is entirely covered by the trapezius.

The *rhomboideus major* arises from the upper four or five thoracic spines, and the corresponding parts of the supraspinous ligaments. Its fibres run obliquely downwards and laterally, and end in a tendinous cord, which is inserted into the vertebral margin of the scapula, close to the inferior angle. From this point, up to the commencement of the spine, the tendinous cord is firmly bound to the vertebral margin of the scapula by areolar tissue (Fig. 24, p. 55). The greater part of the rhomboideus major is covered by the trapezius; only a small portion near the inferior angle of the scapula lies immediately subjacent to the deep fascia.

**M. Levator Scapulæ.**—The levator scapulæ is an elongated muscle which arises by four more or less tendinous slips from the posterior tubercles of the transverse processes of the upper four cervical vertebræ, and passes downwards and backwards to be inserted into the vertebral margin of the scapula, from the medial angle to the spine. It is supplied by branches from the *third* and *fourth cervical nerves*.

*Dissection.*—In cleaning the levator scapulæ muscle care must be taken of the nerves which pass to it from the cervical plexus, and also of the dorsalis scapulæ nerve and the descending branch of the transverse cervical artery, which lie under cover of it near the vertebral margin of the scapula. The dissector of the head and neck has an interest in the levator scapulæ. When it has been studied by both dissectors it should be divided, midway between its origin and insertion, and the lower portion should be turned laterally. The dorsalis scapulæ nerve has already been secured in the interval between the rhomboideus minor and the levator scapulæ, and it has been exposed still further by the reflection of the latter muscle. It may now be displayed in its whole length, together with the descending branch of the transverse cervical artery, which it accompanies, by reflecting the rhomboidei muscles. These should be detached from the ligamentum nuchæ and the vertebral spines, and thrown towards the vertebral margin of the scapula. In doing this care must be taken of the serratus posterior superior, a thin muscle which lies subjacent, and is apt to be injured.

**Nervus Dorsalis Scapulæ** (O.T. **Nerve to the Rhomboids**).—This is a long slender twig which arises in the neck from the fifth cervical nerve, usually in common with the upper root

of the long thoracic nerve. It pierces the scalenus medius, and then proceeds downwards, under cover of the levator scapulæ, to the deep surface of the rhomboidei muscles, to which it is distributed. The dorsalis scapulæ nerve supplies one or two twigs to the levator scapulæ also.

The dorsalis scapulæ nerve sometimes pierces the levator scapulæ in two or more branches which unite in a plexiform manner.

**Ramus Descendens of the Art. Transversa Colli** (O.T. **Posterior Scapular Artery**).—The descending branch of the transverse cervical artery takes origin in the lower part of the neck close to the lateral margin of the levator scapulæ. At first it proceeds medially under cover of that muscle, but soon changing its direction it runs downwards along the base or vertebral border of the scapula, under cover of the rhomboid muscles (Fig. 17, p. 39). It gives numerous branches to both costal and dorsal aspects of the scapula, and its terminal twigs may enter the latissimus dorsi. One large branch usually passes backwards, in the interval between the rhomboid muscles or through the greater rhomboid, to reach the trapezius muscle; and another branch, the *supraspinal*, is given to the supraspinatus muscle, and the structures superficial to it.

**Reflection of Latissimus Dorsi.**—Divide the muscle by carrying the knife from its upper margin, about three inches from the vertebral spines, obliquely downwards to a point a little way behind its digitation from the last rib. In raising the medial portion of the muscle care must be taken of the subjacent serratus posterior inferior. The attachment of the latissimus dorsi to the crest of the ilium and to the lumbo-dorsal fascia can now be verified. The lateral part of the muscle is next to be thrown forwards, so that the three costal digitations may be seen from their deep aspect, and also for the purpose of displaying the termination of the *subscapular artery* and the *thoraco-dorsal nerve*. These are found upon the deep surface of the muscle at the inferior angle of the scapula.

**The Removal of the Upper Extremity.**—After the costal attachments of the latissimus dorsi have been displayed the upper extremity must be removed. Draw the extremity away from the body; detach the costal slips of the latissimus, cut through the serratus anterior about one inch from the vertebral border of the scapula; divide the dorsalis scapulæ nerve, the descending branch of the transverse cervical artery, the posterior belly of the omo-hyoid muscle, the transverse scapular artery and the suprascapular nerve. Cut through the axillary vessels and the cords of the brachial plexus at the outer border of the first rib; detach the anterior skin flap

from the anterior wall of the thorax and take the extremity to a separate table for further dissection.

## SHOULDER—SCAPULAR REGION.

In the dissection of this region the following parts must be studied:—

1. Cutaneous nerves of the shoulder.
2. Deep fascia.
3. Deltoid muscle.
4. Sub-acromial bursa.
5. Anterior and posterior circumflex vessels of the humerus.
6. Axillary (circumflex) nerve.
7. Circumflex scapular artery.
8. Subscapularis muscle.
9. Supraspinatus, infraspinatus, teres minor, and teres major muscles.
10. Bursæ in connection with the shoulder-joint.
11. Suprascapular nerve and transverse scapular artery.
12. Acromio-clavicular joint, and the coraco-acromial arch.

**Muscles inserted into the Clavicle and Scapula.**—The insertions of the muscles which have already been divided should first engage the attention of the student. They should be carefully defined and the precise extent of each studied. Begin with the *omo-hyoid*, which springs from the superior border of the scapula; then deal in the same way with the *levator scapulæ*, *rhomboideus minor* and *major*, which are attached to the vertebral border of the bone, and the *serratus anterior*, which is inserted into the costal aspect of the medial and inferior angles, and the intervening portion of the vertebral border of the scapula. The insertion of the *pectoralis minor* into the coracoid process, and of the *trapezius* into both clavicle and scapula, should also be thoroughly examined. When this has been done these divided muscles may be removed, with the exception of about half an inch of each, which it is advisable to leave attached to the bones for future reference.

*Dissection.*—A block should now be placed in the axilla, and the skin removed from the upper and lateral aspects of the shoulder as far as the insertion of the deltoid. Commence in front and proceed from before backwards, taking care to leave the fatty superficial fascia in its place.

**Nervi Cutanei (Cutaneous Nerves).**—In the superficial fascia, which is thus laid bare, cutaneous nerves from two different sources must be secured and traced, in order that the area of skin supplied by each may be recognised. They are:—

1. Posterior supraclavicular nerves from the third and fourth cervical nerves.
2. Cutaneous branches from the axillary nerve (circumflex).

The *posterior supraclavicular nerves* have already been observed crossing the lateral third of the clavicle and the insertion of the trapezius, under cover of the platysma. They have been divided in removing the limb. If the cut

ends be secured and followed, they will be found to spread out over the lateral and posterior part of the proximal portion of the deltoid region.

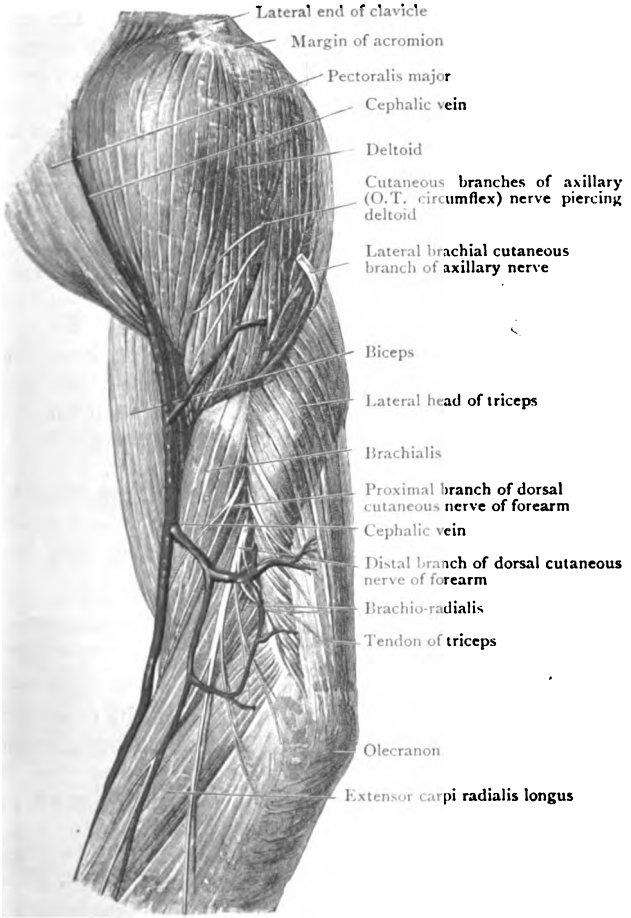


FIG. 20.—The Deltoid Muscle and the lateral aspect of the Arm.

The *cutaneous branches* of the *axillary nerve* consist—(*a*) of a large branch, the *lateral cutaneous nerve of the arm*, which turns round the posterior border of the deltoid muscle,

and (*b*) of several fine filaments which pierce the substance of the deltoid muscle, and appear at irregular intervals on its surface. The latter are difficult to secure, but the main branch can be easily found by carefully dividing the superficial fascia along the posterior border of the deltoid. On everting this border very little dissection is required to expose the nerve hooking round it, about two and a half inches proximal to the insertion of the deltoid (Fig. 22). It breaks up into branches which supply the skin over the distal portion of the deltoid region.

**Deep Fascia.**—A firm but thin fascia covers the subscapularis muscle. Into this some of the fibres of the serratus anterior are usually inserted, at the vertebral border of the scapula. The strongest and most conspicuous fascia in this region is that which covers the exposed part of the infraspinatus muscle, on the dorsal aspect of the scapula. It is firmly attached to the limits of the fossa in which that muscle lies, and presents other very apparent connections. Thus, a strong septum, proceeding from its deep surface, will be noticed to dip in between the infraspinatus and teres minor muscles, and then, as it proceeds forwards, it gives a thin covering to the teres minor, teres major, and the deltoid. Indeed, it may be said to split into two lamellæ—a superficial and a deep,—which, as they pass forwards, enclose between them the deltoid muscle.

*Dissection.*—Depress the scapula and retain it in this position by means of hooks. The fibres of the deltoid are thus rendered tense, and the coarse fasciculi of the muscle may be cleaned.

**M. Deltoideus.**—The deltoid muscle, as its name implies, is triangular in form. It is composed of coarse fasciculi, and covers the shoulder-joint. It arises from the anterior border of the lateral third, or half, of the clavicle (Fig. 18, p. 41), from the lateral border of the acromion and from the lower border of the spine of the scapula (Fig. 24, p. 55). Its origin closely corresponds with the insertion of the trapezius. The fasciculi of which the muscle is formed converge rapidly as they are traced distally, and finally they are attached, by a pointed tendinous insertion, to the *deltoid tuberosity* on the middle of the lateral surface of the body of the humerus (Fig. 33, p. 79). Its nerves of supply are branches of the *axillary* (*circumflex*) *nerve*.

*Dissection.*—The limb should now be placed on its posterior aspect, and the posterior circumflex artery of the humerus and the axillary nerve should be traced backwards through the quadrilateral space. The boundaries of the space should be defined and cleaned at the same time.

**Quadrilateral and Triangular Spaces.**—The quadrilateral space is wholly the result of dissection; it has no real

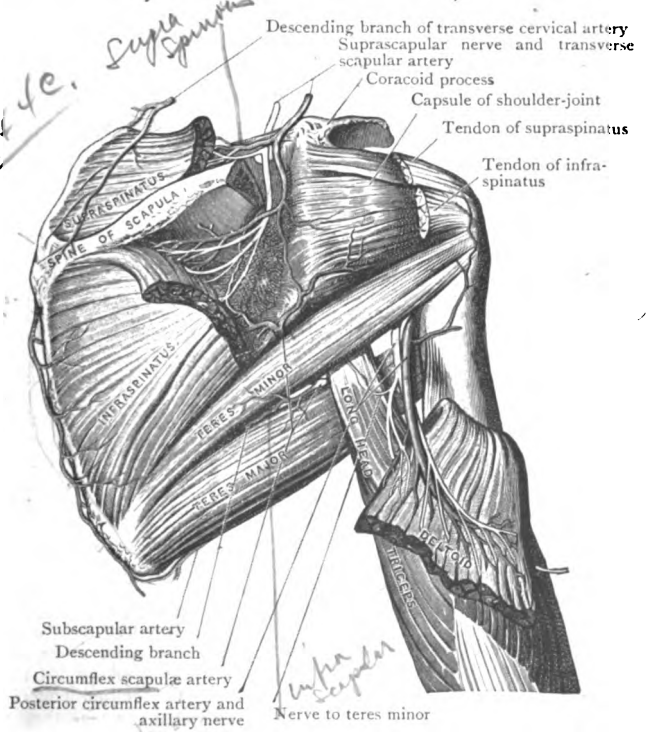


FIG. 21.—Dissection of the Posterior Scapular Region.

existence until the parts are artificially separated from each other. When viewed from the front, the boundaries will be seen to be formed—(*a*) *laterally*, by the proximal part of the body of the humerus; (*b*) *medially*, by the long head of the triceps; (*c*) *above*, by the lower margin of the subscapularis; (*d*) and *below*, by the upper border of the teres major. When viewed from behind, the *upper boundary* of the quadrilateral space will be seen to be formed by the teres minor; the

other boundaries are the same as those seen from the front.

The term *triangular space* is the name given to another intermuscular interval which becomes apparent when the muscles in this region are cleaned and separated. It is placed nearer the inferior angle of the scapula, and the long head of the triceps intervenes between it and the quadrilateral space. It is bounded *above* by the subscapularis; *below* by the teres major; and *laterally* by the long head of the triceps. The *circumflex scapular artery* should be followed into this space, and cleaned up to the point where it disappears round the axillary border of the scapula, under cover of the teres minor.

*Dissection.*—The posterior circumflex artery of the humerus and the axillary nerve having now been traced through the quadrilateral space as far as possible, the position of the limb should be reversed. Turn it so that its dorsal surface is uppermost, and, everting slightly the posterior border of the deltoid, define the boundaries of the space as they are seen from behind. At the same time clean the circumflex vessels and the axillary nerve as they issue from the space to reach the deep surface of the deltoid muscle. Care must be taken not to injure the branch which the axillary nerve gives to the teres minor.

The deltoid muscle may now be divided close to its origin and thrown distally; in doing this preserve the acromial branch of the thoraco-acromial artery, which runs in the line of incision, beneath the deltoid. A large bursa which lies between the deltoid and upper aspect of the shoulder-joint must also be kept intact.

**Parts under cover of the Deltoid.**—The deltoid covers the proximal part of the humerus, and portions of the muscles attached to it, and it is wrapped round the shoulder-joint so as to envelop it behind, laterally, and in front; indeed the full rounded appearance of the shoulder is due to the muscle passing over the expanded proximal end of the humerus. When the head of the bone is displaced the muscle passes more or less vertically distally from its origin, and the dislocation is recognised by the squareness or flatness of the shoulder. Behind, the deltoid covers the muscles which arise from the dorsal aspect of the scapula as they pass laterally to reach the greater tubercle of the humerus; in front, it covers the proximal part of the biceps muscle, and overlaps the coracoid process and the muscles attached to it. In relation also to the deep surface of the deltoid are the circumflex vessels of the humerus and the axillary nerve.

**Bursa Subacromialis.**—The subacromial bursa is a large bursal sac which intervenes between the acromion and deltoid above, and the muscles which immediately cover the upper aspect of the capsule of the shoulder-joint below. It facilitates the play of the proximal end of the humerus, and the attached muscles, on the under aspect of the acromion and

deltoid. Make an incision into it,[1] and introduce a finger into its interior to explore its extent and connections. In

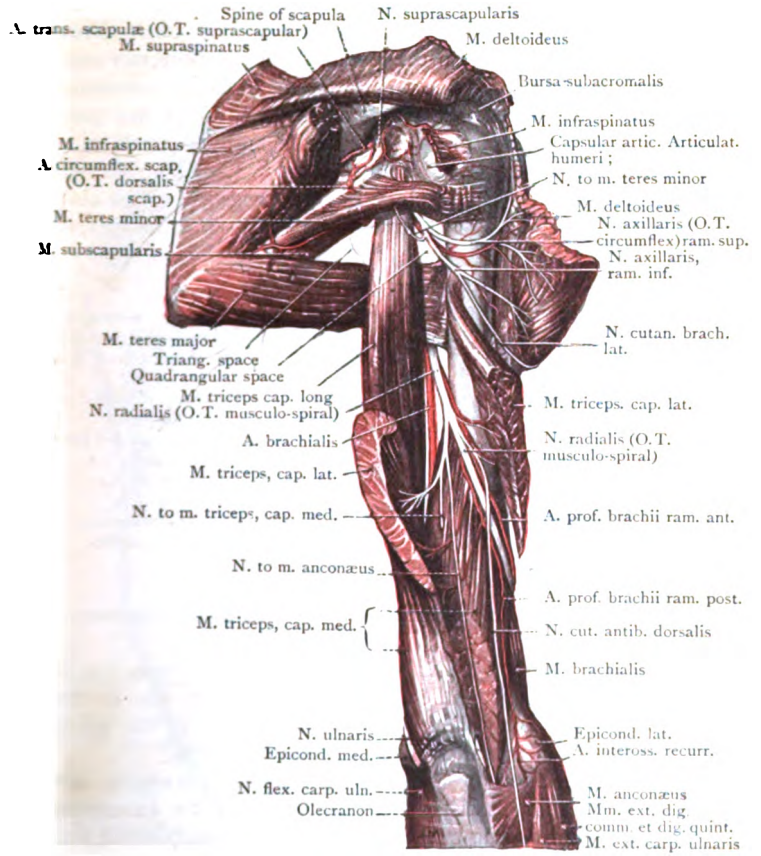


FIG. 22.—Back of the Arm.

some cases it is divided by internal partitions into two or more chambers or loculi.

[1] If the wall of the bursa is quite entire a blowpipe may be thrust into it. It can then be distended, and if unilocular it may be inflated to about the average size of a hen's egg. It varies much in size, however, in different individuals.

*Dissection.* — The branches of the posterior circumflex artery of the humerus and of the axillary nerve should now be dissected out on the deep surface of the deltoid muscle.

**Humeral Circumflex Arteries** (O.T. **Circumflex Arteries**).— The *posterior humeral circumflex artery* has been already observed to arise, within the axilla, from the posterior aspect of the axillary artery, a short distance distal to the subscapular branch. It at once proceeds backwards, through the quadrilateral space, and, winding round the surgical neck of the humerus, it is distributed in numerous branches to the deep surface of the deltoid muscle. Several twigs are given also to the shoulder-joint and the integument. It anastomoses with

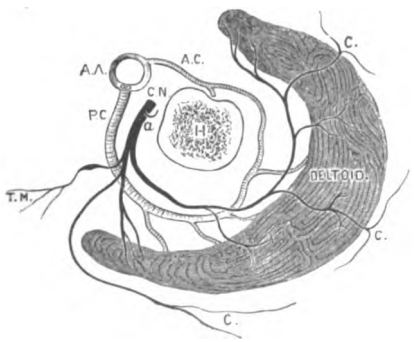


*H.* Transverse section of the humerus immediately distal to the tubercles.
*A.A.* Axillary artery.
*P.C.* Posterior circumflex artery of the humerus.
*A.C.* Anterior circumflex artery of the humerus.
*C.N.* Axillary nerve.
*a.* Articular branch.
*T.M.* Branch to teres minor.
*C.* Cutaneous branches.

FIG. 23.—Diagram of the Circumflex Vessels and the Axillary Nerve.

the acromial branch of the thoraco-acromial artery and the anterior humeral circumflex artery, and also, by one or more twigs, which it sends distally, to the long head of the triceps, with the profunda branch of the brachial artery.

The termination of the *anterior humeral circumflex artery* can now be more satisfactorily studied, and its anastomosis with the posterior humeral circumflex artery established, if the injection has flowed well. By this anastomosis the arterial ring which encircles the proximal part of the humerus is completed.

**Nervus Axillaris** (O.T. **Circumflex Nerve**).—This nerve accompanies the posterior circumflex artery, and supplies— (*a*) *muscular branches* to the deltoid and teres minor; (*b*) *cutaneous branches* to the skin over the distal part of the deltoid; and (*c*) an *articular twig* to the shoulder-joint. The

following is the manner in which it is distributed. It springs from the posterior cord of the brachial plexus, turns round the lower border of the subscapularis, and proceeds backwards, with the posterior circumflex artery of the

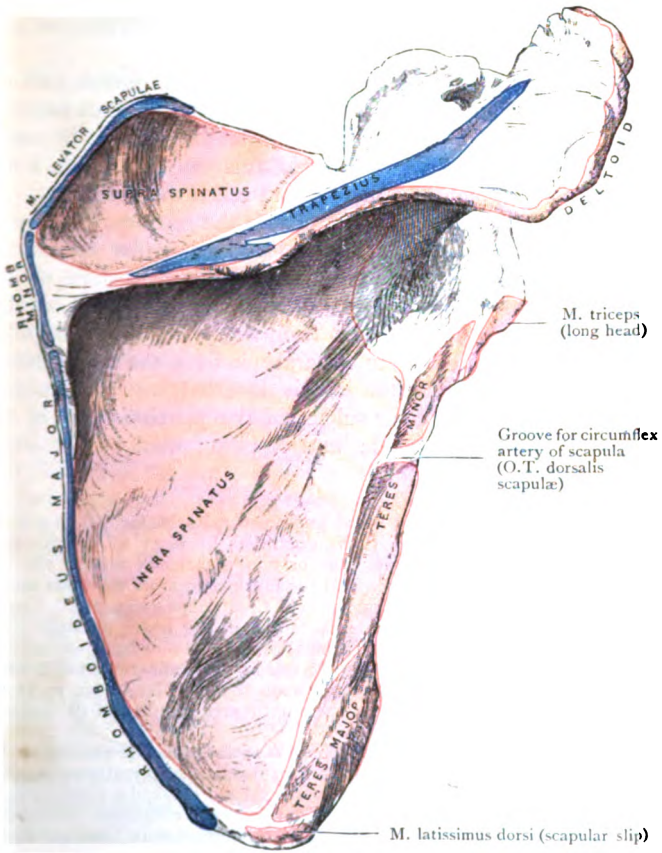


FIG. 24.—Dorsum of Scapula with the Attachments of the Muscles mapped out.

humerus, through the quadrilateral space. Reaching the posterior aspect of the limb, it divides into an anterior and a posterior division. The *articular branch* takes origin from the trunk of the nerve, and enters the joint below the subscapularis muscle. The *posterior division* gives off the

branch to the teres minor, and, after furnishing a few twigs to the posterior part of the deltoid, is continued onwards, as the *lateral cutaneous nerve of the arm*, which has already been dissected in the superficial fascia over the distal part of the deltoid (Fig. 22). The nerve to the teres minor is distinguished by the presence of an oval, gangliform swelling upon it.

The *anterior division* proceeds round the humerus with the posterior circumflex artery of the humerus, and ends near the anterior border of the deltoid. It is distributed, by many branches, to the deep surface of this muscle, whilst a few fine filaments pierce the deltoid and reach the skin.

**M. Teres Major.**—The part which the teres major plays in the formation of the quadrilateral and triangular spaces has already been seen. It arises from the oval surface on the dorsum of the scapula close to the inferior angle of the bone (Fig. 24, p. 55), and also from the septa which the infraspinous fascia sends in to separate it from the infraspinatus and teres minor muscles. It is inserted into the medial lip of the intertubercular sulcus on the proximal part of the humerus (Fig. 33, p. 79); and it is supplied by the lower subscapular nerve.

**Insertions of Latissimus Dorsi and Pectoralis Major.**—The narrow, band-like tendon of the latissimus dorsi lies in front of the insertion of the teres major. From its inferior margin a small fibrous slip will be observed passing distally, beyond the lower margin of the teres major, to find attachment to the long head of the triceps (Fig. 22). This is a rudiment of the dorsi-epitrochlearis muscle of the lower animals. The tendons of the teres major and latissimus dorsi should now be separated from each other. They will be found to be more or less adherent, but a small bursa mucosa will be discovered between them. The insertion of the latissimus dorsi into the bottom of the intertubercular sulcus of the humerus may now be satisfactorily studied.

The tendon of insertion of the *pectoralis major*, which is attached to the lateral lip of the intertubercular sulcus, may also be conveniently examined at this stage (p. 13). A separation of the sternal and clavicular portions of the muscle will bring into view the two laminæ which constitute the tendon, and the following points may be noted in connection with these:—(*a*) that they are continuous with each other below, or, in other words, that the tendon is simply folded upon itself; (*b*) that the posterior lamina extends to a more proximal level on the humerus than the anterior, and that a fibrous expansion proceeds proximally from its superior border, to seek attachment to the capsule of the shoulder-joint and the lesser tubercle of the humerus; (*c*) that the lower border is connected with the fascia of the arm.

**Articulatio Acromio-Clavicularis.**—The acromio-clavicular

joint is a diarthrodial joint; and the ligaments which bind the bones together are:—

Ligaments proper to the joint . . . { 1. Superior, 2. Inferior } capsular.
Accessory ligaments—Coraco-clavicular { trapezoid. conoid.

The *superior acromio-clavicular ligament* is a broad band, composed of stout fibres, which is placed on the upper aspect of the joint. The *inferior acromio-clavicular ligament*, which closes the joint below, is not so strongly developed. In front and behind, these ligaments are connected with each other so as to constitute a capsule. The joint should now be opened, when it will be seen to be lined by a synovial membrane. An imperfect articular disc also is usually present. It is wedge-shaped, and connected by its base to the superior ligament, whilst its free margin is directed downwards between the bones.

**Lig. Coracoclaviculare.**—The coraco-clavicular ligament is a powerful ligament which binds the inferior surface of the clavicle to the coracoid process. When thoroughly cleaned and defined it will be seen to consist of two parts, which are termed the conoid and the trapezoid ligaments.

The *ligamentum conoideum*, placed upon the posterior and medial aspect of the lig. trapezoideum, is broad above, where it is attached to the coracoid tubercle of the clavicle (Fig. 5, p. 12), and somewhat narrower below, at its attachment to the medial part of the coracoid process. The *ligamentum trapezoideum* is the anterior and lateral part. Above, it is attached along the trapezoid line of the clavicle (Fig. 5, p. 12), whilst below it is fixed to the upper aspect of the coracoid process. In the recess between these two ligaments a bursa mucosa will usually be found.

**Arcus Coracoacromialis.**—It is necessary to examine the coraco-acromial arch at the present stage, as the next step in the dissection will, in a great measure, destroy it. It is the arch which overhangs the shoulder-joint and protects it from above. It is formed by the coracoid process, the acromion, and a ligament—the coraco-acromial—which stretches between them.

The *coraco-acromial ligament* is a strong band of a somewhat triangular shape. By its base it is attached to the lateral

border of the coracoid process, whilst by its apex it is attached to the extremity of the acromion (Fig. 39, p. 91).

The coraco-acromial arch plays a very important part in the mechanism of the shoulder; it might almost be said to form a secondary socket for the humerus. The large bursa which intervenes between the acromion and the muscles immediately covering the capsule of the shoulder-joint, to facilitate the movements of the proximal end of the humerus on the inferior surface of the arch has already been noted.

*Dissection.*—The supraspinatus, infraspinatus, and teres minor muscles, which arise from the dorsal surface of the scapula, and the subscapularis, which takes origin from the costal surface of the scapula, may now be examined. In order to obtain an uninterrupted view of the supraspinatus muscle, the acromion must be divided, with the saw, close to its junction with the spine of the scapula (Fig. 21, p. 51).

Divide also the fascia which covers the teres minor muscle, and reflect it towards the infraspinatus. By this means the septum from the infraspinous fascia, which dips in between the two muscles, will be demonstrated, and their separation rendered easy. Care must be taken not to injure the circumflex artery of the scapula, which passes between the teres minor and the bone.

**M. Supraspinatus.**—The supraspinatus muscle arises from the medial two-thirds of the supraspinous fossa, and also to a slight degree from the supraspinous fascia, which covers it. From this origin the fibres converge, as they pass laterally, and, proceeding under the acromion, they end in a short, stout tendon, which is inserted into the uppermost of the three impressions on the greater tubercle of the humerus (Fig. 33, p. 79). This tendon is closely adherent to the capsule of the shoulder-joint. The supraspinatus is covered by the trapezius, and in the loose fat which intervenes between this muscle and the supraspinous fascia some twigs of the superficial cervical artery ramify. It is supplied by the *suprascapular nerve*; and it is an abductor of the upper extremity.

**M. Teres Minor.**—This is the small muscle which lies along the lower border of the infraspinatus. It arises from an elongated flat impression on the dorsal aspect of the axillary border of the scapula, and from the septa of the infraspinous fascia which intervene between it and the two muscles between which it lies, viz., the infraspinatus and teres major. It is inserted into the lowest of the three impressions on the greater tubercle of the humerus, and also, by fleshy fibres, into the body of the bone for about half an inch distal to this (Fig. 36, p. 84). Near its insertion it is

separated from the teres major by the long head of the triceps brachii. The teres minor is supplied by a branch from the *axillary nerve.* It is an adductor and lateral rotator of the upper extremity.

**M. Infraspinatus.**—The infraspinatus muscle arises from the whole of the infraspinous fossa, with the exception of a small part of it near the neck of the scapula. It derives fibres also from the fascia which covers it. Its tendon of insertion is closely adherent to the capsule of the shoulder-joint, and is attached to the middle impression on the greater tubercle of the humerus (Fig. 36, p. 84). It is supplied by the *suprascapular nerve*; and it is an adductor and lateral rotator of the upper extremity.

**M. Subscapularis.**—The subscapularis muscle arises from the whole of the subscapular fossa, with the exception of a small portion near the neck of the scapula; it takes origin also from the groove which is present on the costal aspect of the axillary border of the bone (Fig. 15, p. 34). Its origin is strengthened by tendinous intersections, which are attached to the ridges on the costal surface of the scapula. The fleshy fibres thus derived converge upon a stout tendon, which is inserted into the lesser tubercle of the humerus; a few of the lower fibres, however, gain independent insertion into the body of the humerus distal to the tubercle.

As the muscle proceeds laterally to its insertion, it passes under an arch formed by the coracoid process and the conjoined origin of the short head of the biceps brachii and the coraco-brachialis. By dissecting between the upper border of the muscle and the root of the coracoid process, a bursa of some size will be discovered. This bursa communicates with the cavity of the shoulder-joint through an aperture in the capsule: in other words, its walls are directly continuous with the synovial stratum of the capsule. This can readily be ascertained by making an incision into it. An instrument can then be passed into the joint. The subscapularis is supplied by the *upper* and *lower subscapular nerves.* It is an adductor and medial rotator of the upper extremity.

*Dissection.*—The transverse scapular artery and suprascapular nerve must now be followed to their distribution on the dorsum of the scapula. They have already been traced to the superior border of the scapula. Divide the infraspinatus muscle about an inch and a half from its insertion,

taking care not to injure the subjacent vessels. Pull the muscle cautiously backwards, and its nerve of supply, with the terminations of the transverse artery of the scapula and the circumflex artery of the scapula, will be exposed. Treat the supraspinatus muscle in a similar manner (Fig. 37, p. 86).

**Arteria Transversa Scapulæ** (O.T. **Suprascapular Artery**).—The transverse scapular artery enters the supraspinous fossa by passing over the ligament which bridges across the scapular notch. It divides, under cover of the supraspinatus muscle, into a *supraspinous* and an *infraspinous branch*. The former supplies the supraspinatus muscle, and gives off the chief nutrient artery to the scapula; the latter proceeds downwards through the great scapular notch, under cover of the inferior transverse scapular ligament, to reach the deep surface of the infraspinatus muscle, to which it is distributed.

At the superior border of the scapula the transverse artery of the scapula gives off a *subscapular branch*, which enters the subscapular fossa, under cover of the subscapularis muscle.

**Nervus Suprascapularis.** — The suprascapular nerve accompanies the transverse artery of the scapula, but it enters the supraspinous fossa by passing through the scapular notch, under cover of the upper transverse ligament of the scapula. It supplies the supraspinatus, and ends in the infraspinatus muscle. It usually sends *two articular twigs* to the posterior aspect of the shoulder-joint, viz., one while in the supraspinous fossa, and the second as it lies in the infraspinous fossa.

**Arteria Circumflexa Scapulæ** (O.T. **Dorsalis Scapulæ Artery**).—The scapular circumflex artery as already noted, arises from the subscapular branch of the axillary and enters the triangular space. While there it supplies one or two *ventral branches*, which pass, under cover of the subscapular muscle, to the subscapular fossa, and a larger *infrascapular branch*, which runs downwards in the interval between the teres major and teres minor to the inferior angle of the scapula (Fig. 21, p. 51). After these branches are given off, the circumflex scapular artery leaves the triangular space by turning round the axillary border of the scapula, under cover of the teres minor. It now enters the infraspinous fossa, where it ramifies, and supplies branches to the infraspinatus muscle.

**Anastomosis around the Scapula.**—An important and free anastomosis takes place around the scapula. Three main

blood-vessels take part in this, viz.—(*a*) the transverse scapular artery; (*b*) the descending branch of the transverse cervical artery ; and (*c*) the subscapular artery.

*The descending branch of the transverse cervical artery* (O.T. *posterior scapular*) runs downwards in relation to the vertebral border of the scapula, and dispenses branches upon both the dorsal and costal aspects of the bone. The *subscapular artery* runs downwards and medially along the axillary border of the scapula, and at the inferior angle some of its terminal branches anastomose with the terminal twigs of the descending branch of the transverse cervical artery. The *transverse scapular artery* is brought into communication with the descending branch of the transverse cervical artery at the upper margin, by an anastomosis in the neighbourhood of the medial angle of the bone.

Still more obvious anastomoses take place upon the dorsal and costal aspects of the bone. In the supraspinous fossa, branches of the *transverse scapular artery* inosculate with twigs from the *descending branch of the transverse cervical artery;* whilst, in the infraspinous fossa, free communications are established between the *circumflex artery of the scapula*, the *transverse artery of the scapula*, and the *descending branch of the transverse cervical artery*.

On the ventral aspect of the scapula, the ventral branch of the *transverse artery of the scapula*, the ventral branches of the *circumflex artery of the scapula*, and the ventral branches of the *descending branch of the transverse cervical artery* join to form a network.

The importance of this free communication between the blood-vessels in relation to the scapula will be manifest when it is remembered that two of the main arteries, viz., the descending branch of the transverse cervical artery and the transverse artery of the scapula spring indirectly from the first part of the subclavian; whilst the third, viz., the subscapular, arises from the third part of the axillary. When, therefore, a ligature is applied to any part of the great arterial trunk of the upper limb, between the first stage of the subclavian and the third part of the axillary, this anastomosis affords ample means of re-establishing the circulation.

*Dissection.*—Detach the subscapularis from the scapula and lift it laterally to its insertion. This will afford a better view of its relation to the capsule of the shoulder-joint, and also of the subscapular bursa. In a well-injected subject the ventral anastomosis also can be made out.

**Ligamentum Transversum Scapulæ Superius (O.T. Supra-scapular Ligament) and Lig. Transversum Scapulæ Inferius (O.T. Spino-glenoid Ligament).**—These are two ligamentous

bands which are placed in relation to the transverse artery of the scapula and the suprascapular nerve. The *upper transverse ligament of the scapula* bridges across the scapular notch and converts it into a foramen. It lies between the transverse artery of the scapula and the suprascapular nerve: the former being placed above it, and the latter below it. Not infrequently it is ossified. The *inferior transverse ligament of the scapula* is a weaker band; it bridges across the transverse artery of the scapula and the suprascapular nerve as they pass through the great scapular notch. On the one hand, it is attached to the lateral border of the spine of the scapula, and on the other, to the posterior aspect of the neck of the scapula.

## FRONT OF THE ARM.

In this dissection the following parts have to be studied:—

1. Cutaneous vessels and nerves.
2. Brachial fascia.
3. Brachial artery and its branches.
4. Median, ulnar, radial, and musculo-cutaneous nerves, and branches of the last two.
5. Biceps, coraco-brachialis, and brachialis muscles.

In conjunction with this dissection, it is convenient to study the triangular space in front of the elbow, and also to trace the cutaneous nerves to their ultimate distribution in the skin of the forearm.

**Surface Anatomy.**—In a muscular limb the prominence formed by the biceps muscle along the front of the arm is very apparent. Every one is familiar with the rounded swelling which the muscle produces when powerfully contracted in the living subject. On each side of the biceps there is a feebly marked furrow, and ascending in each of these there is a large superficial vein. In the lateral furrow is the cephalic vein; in the distal part of the medial furrow is the basilic vein. In the proximal part of the medial bicipital sulcus is an elongated bulging produced by the subjacent coraco-brachialis muscle. This is useful as a guide to the distal part of the axillary and the proximal part of the brachial arteries, which

lie immediately behind and to the medial side of it. The humerus is thickly clothed by muscles; but towards its distal part the two epicondylar ridges, leading to the epicondylar eminences, may be felt. The lateral ridge is the more salient of the two, and therefore the more evident to touch.

The bony points around the elbow require to be studied

FIG. 25.—Relation of Bones of Elbow to the surface. Dorsal view; elbow fully extended.

FIG. 26. — Relation of the Bones of the Elbow to the surface. Dorsal view; elbow bent.

with especial care. It is by a proper knowledge of the normal relative positions of these that the surgeon is able to distinguish between the different forms of fracture and dislocation which so frequently occur in this region. First note the medial epicondyle of the humerus. This constitutes a prominence appreciable to the eye; grasp it between the finger and thumb, and note that it inclines posteriorly as well as medially. In a well-developed, fully extended arm, the lateral epicondyle does not form a projection on the surface, but can be felt at the bottom of a slight depression

on the dorsal aspect of the limb. It becomes apparent to the eye as a prominence when the elbow is semi-flexed. The olecranon produces a marked projection on the dorsum of the elbow between the two epicondyles. It is placed slightly nearer to the medial than to the lateral epicondyle. The loose skin which covers the olecranon moves freely over its subcutaneous surface, owing to the interposition of a bursa. The different positions which are assumed by the olecranon, in relation to the epicondyles of the humerus in the movements of the forearm at the elbow-joint, must be carefully examined. This can be done best by placing the thumb on one epicondyle, the middle finger on the other, and the forefinger on the olecranon. The limb should then be alternately flexed and extended, so as to make clear the extent of the excursion performed by the olecranon. In full extension at the elbow-joint the three prominences lie in the same horizontal line; when the forearm is bent at a right angle the three bony points are placed at the angles of an equilateral triangle, of which one apex points distally.

When the forearm is extended a marked depression on the dorsal aspect of the elbow indicates the position of the articulation between the radius and the humerus. Immediately distal to this the head of the radius lies near to the surface, and can readily be felt, especially when it is made to roll under the finger by inducing alternately the movements of pronation and supination. The head of the radius is placed about an inch distal to the lateral epicondyle.

As the skin of the forearm must be reflected in the pursuit of the cutaneous nerves, it is well, at this stage, to study also the external anatomy of this segment of the limb. In its proximal half the radius is deeply imbedded in muscles, but in its distal half it can be felt, and its styloid process, on the lateral side of the carpus, can be readily distinguished. On the dorsal aspect of the distal end of the radius, immediately above the radiocarpal joint, and nearer the lateral than the medial border of the limb, a prominent bony tubercle may be felt. This is the high ridge which forms the lateral wall of the sharply cut groove on the dorsal aspect of the radius in which the tendon of the extensor pollicis longus muscle plays.

The sinuous dorsal border of the ulna is subcutaneous, and may be followed by the finger throughout its entire length; as the elbow is approached it leads directly on

to the subcutaneous surface on the dorsum of the olecranon. In cases of suspected fracture, therefore, this border affords valuable information. The styloid process of the ulna may be detected, immediately proximal to the wrist; and it should be noted that this does not extend so far distally as the corresponding process of the radius. The rounded distal end of the ulna makes a marked projection on the medial and dorsal aspect of the limb, immediately proximal to the wrist-joint, and, lying in the groove between it and the styloid process, the tendon of the extensor carpi ulnaris may be felt.

**Reflection of Skin.**—The skin should be removed from the limb as far as the radio-carpal joint. It is necessary to do this in order that a connected view may be obtained of the cutaneous nerves and the superficial veins. But at the same time the skin should not be cast aside, as it forms a most efficient protective wrapping for the part even after it has been detached. Make one long incision along the middle of the anterior aspect of the arm and the volar (or anterior) surface of the forearm as far as the radio-carpal articulation. A second incision, carried transversely round the distal end of the forearm, immediately proximal to the radio-carpal joint, will enable the dissector to reflect the skin in two large flaps, medially and laterally. In the fatty superficial fascia, which is then exposed, the superficial structures may be traced. It is well to begin with the nerves, as these are not so apparent and are, therefore, more liable to injury than the veins. But the dissection of the veins should be carried on concurrently with that of the nerves.

**Nervi Cutanei.**—The cutaneous nerves are very numerous, and are derived from several sources. In addition to the two medial cutaneous nerves, which spring from the brachial plexus, there are the terminal cutaneous part of the musculo-cutaneous nerve, three branches derived from the radial nerve and one—the intercosto-brachial nerve—form the second thoracic nerve. These seven nerves may be classified into a medial and a lateral group as follows:—

1. N. **cutaneus antibrachii dorsalis**, proximal branch,
2. N. **cutaneus antibrachii dorsalis**, distal branch,
3. N. **cutaneus antibrachii lateralis**,

} Distributed mainly upon the lateral part of the arm and forearm.

1. N. **intercostobrachialis**,
2. N. **cutaneus brachii posterior**,
3. N. **cutaneus brachii medialis**,
4. N. **cutaneus antibrachii medialis**,

} Distributed mainly upon the medial part of the arm and forearm.

The two *dorsal cutaneous nerves of the forearm* pierce the deep fascia about the middle of the lateral surface of the arm, immediately distal to the insertion of the deltoid, and

in close relation to the lateral intermuscular septum. The

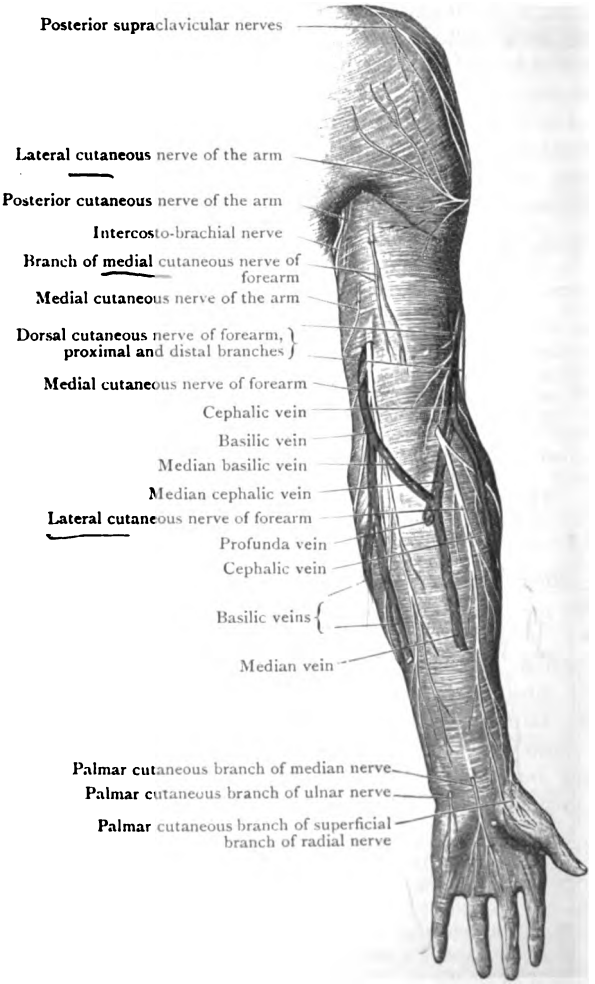
Posterior supraclavicular nerves
Lateral cutaneous nerve of the arm
Posterior cutaneous nerve of the arm
Intercosto-brachial nerve
Branch of medial cutaneous nerve of forearm
Medial cutaneous nerve of the arm
Dorsal cutaneous nerve of forearm, proximal and distal branches
Medial cutaneous nerve of forearm
Cephalic vein
Basilic vein
Median basilic vein
Median cephalic vein
Lateral cutaneous nerve of forearm
Profunda vein
Cephalic vein
Basilic veins
Median vein
Palmar cutaneous branch of median nerve
Palmar cutaneous branch of ulnar nerve
Palmar cutaneous branch of superficial branch of radial nerve

FIG. 27.—Cutaneous Nerves on the Front of the Upper Extremity.

smaller *proximal branch* appears a short distance proximal to the other. It follows the cephalic vein, and can be traced

distally as far as the elbow. Its filaments are distributed to the skin over the lateral and anterior part of the distal half of the arm. The larger *distal branch* can be followed as far as the wrist, and not infrequently its terminal filaments reach even the dorsum of the hand. It supplies the skin of the median part of the dorsal aspect of the forearm.

It should be borne in mind that the skin on the lateral aspect of the limb, proximal to these nerves and over the deltoid, is supplied by the cutaneous branches of the axillary nerve and the posterior supraclavicular nerves of the cervical plexus (p. 48).

The *lateral cutaneous nerve of the forearm* is the terminal part of the musculo-cutaneous nerve. It will be found in front of the elbow-joint, where it pierces the deep fascia on the lateral side of the tendon of the biceps brachii. It is a large nerve, and proceeds distally behind the median cephalic vein. The skin, both upon the volar and dorsal aspects of the lateral side of the forearm, is supplied by this nerve, and it is distributed by two main branches. The larger *volar branch* can be traced as far as the skin over the ball of the thumb. A few of its terminal twigs pierce the fascia near the wrist, and join the radial artery, by which they are conducted to the dorsal aspect of the carpus. The *dorsal branch* may be followed on the dorsal aspect of the limb as far as the wrist.

The *intercosto-brachial nerve* can usually be traced half-way along the arm; but the area of skin which it supplies is somewhat variable. The *posterior cutaneous nerve of the arm* is a branch of the radial (O.T. musculo-spiral) nerve. It proceeds distally and backwards on a deeper plane, and crosses posterior to the intercosto-brachial nerve. Its filaments extend upon the back of the arm as far as the elbow-joint.

The *medial cutaneous nerve of the arm* will be found piercing the deep fascia, to become superficial, about the middle of the medial side of the arm. Its twigs may be followed, in the superficial fascia, as far as the olecranon.

On the medial side of the arm, on its dorsal aspect, three nerves, therefore, have been traced. From the medial to the lateral side these are: the medial cutaneous nerve of the arm, the intercosto-brachial nerve, and the posterior cutaneous nerve of the arm (Fig. 28).

The *medial cutaneous nerve of the forearm* (O.T. internal

cutaneous nerve) is destined chiefly for the supply of the

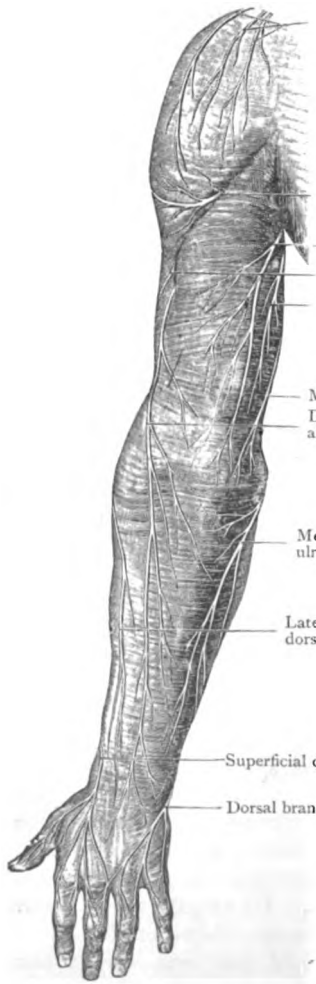
Posterior supraclavicular nerves
Lateral cutaneous nerve of arm
Posterior cutaneous nerve of arm
Dorsal cutaneous nerve of forearm, proximal branch
Intercosto-brachial nerve
Medial cutaneous nerve of arm
Dorsal cutaneous nerve of forearm, distal branch
Medial cutaneous nerve of forearm, ulnar branch
Lateral cutaneous nerve of forearm, dorsal branch
Superficial division of radial
Dorsal branch of ulnar nerve

FIG. 28.—Cutaneous Nerves on the Dorsal Aspect of the Upper Extremity.

skin of the forearm. It appears through the deep fascia about the middle of the medial side of the arm, close to the

basilic vein, and a short distance in front of the medial cutaneous nerve of the arm. It at once divides into a volar and an ulnar branch. The *volar branch* runs distally behind (but sometimes in front of) the median basilic vein, and it is distributed to the skin over the medial and volar aspect of the forearm. The *ulnar branch*, inclining medially, proceeds distally in front of the medial epicondyle of the humerus, to reach the skin on the dorso-medial aspect of the forearm.

A small twig is frequently given by the medial cutaneous nerve of the forearm to the skin over the biceps muscle. This pierces the deep fascia close to the axilla.

**Venæ Superficiales.**—The superficial veins of the anterior aspect of the arm and the volar aspect of the forearm may now be cleaned; but in all probability they are already, for the most part, exposed.

At least three veins are usually seen ascending along the volar aspect of the forearm, the *basilic vein* along the medial border, the *cephalic vein* along the lateral border, and, midway between the two former, the *median vein of the forearm*. When the median vein reaches the depression in front of the elbow it is joined by a short wide vein which pierces the deep fascia of the forearm and establishes an anastomosis between the deep and the superficial veins of the forearm. This connecting trunk is called the *profunda vein*. After receiving this tributary the median vein of the forearm divides into two branches which diverge from each other like the limbs of the letter V. The lateral of the two branches is the median cephalic vein; the medial branch is the median basilic vein.

The *median cephalic vein* passes obliquely, proximally and laterally, across the front of the lateral cutaneous nerve of the forearm, and joins the cephalic vein.

After it has received the median cephalic vein, the *cephalic vein* ascends along the lateral bicipital sulcus, continues proximally in the groove between the deltoid and the pectoralis major, crosses the deltopectoral triangle, dips beneath the clavicular part of the pectoralis major, crossing in front of the pectoralis minor, pierces the costo-coracoid membrane and terminates in the axillary vein.

The *median basilic vein* is a short wide vessel which passes proximally and medially towards the medial epicondyle. It is larger than the median cephalic vein and has a less oblique

course. As it approaches the medial epicondyle of the humerus it joins the basilic vein. The median basilic vein is the vessel commonly selected when the surgeon has recourse to venesection. Therefore the relations of the vein are of special importance. The dissector should note the following points regarding it:—(1) that it crosses a thickened band of deep fascia known as the lacertus fibrosus (O.T. bicipital fascia) of the biceps brachii; (2) that the lacertus fibrosus separates it from the brachial artery, which the vein crosses also; (3) that the volar branch of the medial cutaneous nerve of the forearm usually passes behind it, although in many cases it crosses in front of the vein.

The *basilic vein*, having received the median basilic vein, runs proximally, on the medial surface of the arm, in the medial bicipital sulcus; about the middle of the arm it pierces the deep fascia, close to the spot at which the median cutaneous nerve of the forearm emerges, and at the lower border of the posterior wall of the axilla it becomes the axillary vein. The arrangement of the veins of the forearm is extremely variable. In many cases the median vein is absent, and the cephalic and basilic are united, in the anti-cubital region, by a large, oblique, anastomosing channel which lies in the position of the median basilic vein and appears to be the main continuation of the cephalic trunk, the proximal part of the latter vessel being much reduced in size.

**Lymphoglandulæ (Lymph Glands).**—If the superficial fascia is searched, on the medial side of the limb and immediately proximal to the elbow, one or two minute lymph glands will be found in relation to the basilic vein. These are the superficial cubital glands, and they are of interest to dissectors as they are the first to enlarge and become painful in cases of dissection wounds which become septic.

**Fascia Brachii.**—The deep fascia of the arm should now be cleaned by the removal of the fatty superficial layer. It forms a continuous envelope around the arm, but at no point does it show a great density or strength. Proximally, it is continuous with the axillary fascia and the fascia covering the pectoralis major and the deltoid. The tendons of these two muscles are closely connected with it—a certain proportion of their tendinous fibres running directly into it. Distally, it is firmly fixed to the bony prominences around the elbow, and in front it receives an accession of fibres from the tendon

of the biceps brachii. The latter fibres constitute the *lacertus fibrosus*, and form a very distinct band (O.T. semilunar or bicipital fascia) which, continuous with the fascia proximally and distally, bridges across the brachial artery, and is lost upon the pronator teres muscle, on the medial side of the forearm.

The fascia of the arm may be reflected by making an incision through it along the median line of the front of the arm. In throwing the medial portion medially, the dissector must leave the lacertus fibrosus in position. This may be done by separating it artificially from the adjoining fascia by incisions along its proximal and distal margins.

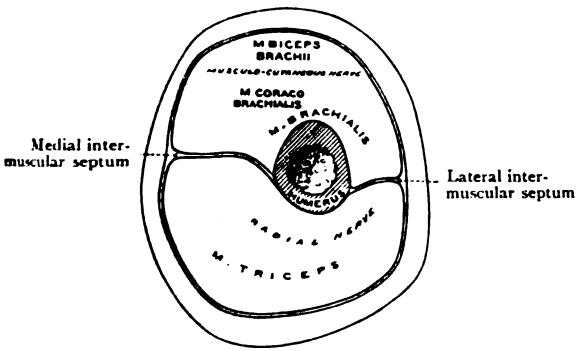


FIG. 29.—Diagram (after Turner) to show how the Arm is divided by the intermuscular septa and the bone into an anterior and a posterior compartment. These compartments are represented in transverse section.

As the foregoing dissection is proceeded with, it becomes evident that septa or partitions pass in between the muscles of the arm from the deep surface of the investing fascia. Two of these possess a superior strength, and obtain direct attachment to the humerus. They are the lateral and medial intermuscular septa. The connections of these cannot be fully studied at present, but it is important that the student should understand their relations at this stage. In the course of the dissection of the arm they will be gradually displayed.

The *medial intermuscular septum* is the stronger and more distinct of the two. It is attached to the medial epicondylar ridge, and may be followed proximally as far as the insertion of the coraco-brachialis muscle. The *lateral intermuscular septum* is fixed to the lateral epicondylar

ridge, and extends proximally as far as the insertion of the deltoid. The dissector should note that these septa divide the arm into an anterior and a posterior osteo-fascial compartment.

**Structures in the Anterior Compartment.**—The anterior osteo-fascial compartment of the arm has been opened into by the reflection of the anterior part of the deep fascia. The three muscles which specially belong to this region are the biceps brachii, brachialis, and the coraco-brachialis. The

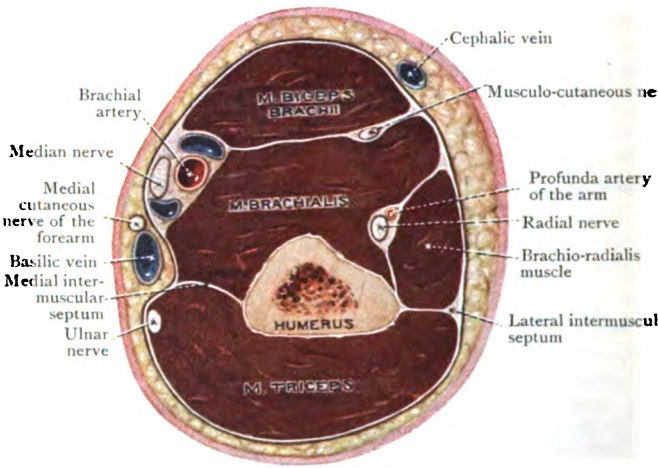


FIG. 30.—Transverse section through the Distal Third of the Right Arm.

biceps brachii is the most superficial muscle; under cover of it, and closely applied to the anterior aspect of the humerus, is the brachialis; whilst the coraco-brachialis is the slender muscular belly which lies along the medial side of the biceps in its proximal part. But, in addition, two muscles of the forearm will be observed to extend into this compartment of the arm, to seek origin from the lateral epicondylar ridge of the humerus: they are the brachio-radialis and the extensor carpi radialis longus. They are closely applied to the lateral side of the brachialis. The brachial artery, with its venæ comites, extends through the region in relation to the medial margin of the biceps brachii, and all the terminal branches of the

cords of the brachial plexus, with the exception of the axillary (O.T. circumflex), will be found for some part of their course in this region. The radial nerve (O.T. musculo-spiral), it is true, almost at once proceeds to the back of the limb, but it again comes to the front, and may be found, in the distal part of the lateral side of the arm, by separating the origins of the brachio-radialis and extensor carpi radialis longus from the brachialis, and dissecting deeply in the interval between them.

*Dissection.*—In carrying out this somewhat extensive dissection, the main object of the dissector should be to keep the brachial artery as undisturbed as possible, until he has satisfied himself as to its relations. He is therefore advised, in the first instance, to clean only those parts of the muscles which are in immediate relationship to the vessel and its branches. The divided brachial nerves, with the axillary artery and vein, should be arranged in proper order, and then tied to a small piece of wood about 1½ inches long (*e.g.*, a piece of a penholder), held transversely. By means of a loop of string this can then be fastened to the coracoid process. By this device the dissection of the arm will be greatly facilitated. The dissection of the entire length of the brachial artery should be carried out at one and the same time, and its termination in the radial and ulnar arteries should be defined.

**Arteria Brachialis.**—The brachial artery is the direct continuation of the axillary artery; it begins, therefore, at the lower border of the teres major, and it passes distally and slightly laterally to the cubital fossa, where, at the level of the neck of the radius, it divides into its two terminal branches—the radial and the ulnar arteries. In the proximal part of the arm it lies to the medial side of the humerus, but as it approaches the elbow it passes to the front of the humerus.

This change of position must be borne in mind when pressure is applied to the vessel with the view of controlling the flow of blood through it. In the proximal part of the arm the pressure must be directed laterally and backwards, and in the distal part directly backwards.

**Relations.**—The brachial artery is superficial in the whole of its length. To expose it, it is therefore necessary to reflect only the skin and the fascia; but it is overlapped, from the lateral side, by the medial margins of the coraco-brachialis and biceps brachii (see Figs. 30, 31). At the bend of the elbow it is crossed superficially by the lacertus fibrosus, which intervenes between it and the median basilic vein.

The basilic vein lies to the medial side of the artery and on a somewhat posterior plane. In the distal part of the arm it is separated from the artery by the deep fascia; but

in the proximal part, after the vein has pierced the fascia, it comes into closer relationship with the artery. The two venæ comites are closely applied to the sides of the artery, and the numerous connecting branches which pass between them, both in front of and behind the artery, make the relationship still more intimate.

Behind the brachial artery there are four muscles. Proximo-distally, they are—(1) the long head of the triceps, which is separated from the artery by the radial nerve and the

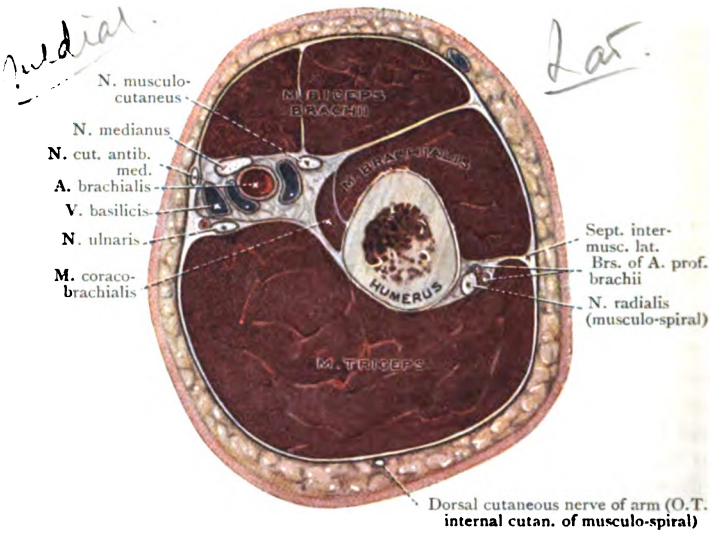


FIG. 31.—Transverse section through Middle of the Arm.

profunda vessels. (2) The medial head of the triceps. (3) The insertion of the coraco-brachialis. (4) In the remainder of its course the brachialis forms the posterior relation.

With the exception of the musculo-cutaneous nerve, all the terminal branches of the brachial plexus lie in relation to the brachial artery. The median nerve lies on the lateral side and somewhat anteriorly in the proximal half of the arm; it crosses anterior to the artery at the level of the insertion of the coraco-brachialis, and in the distal half of the arm and in the cubital fossa it is to the medial side of the artery. The ulnar nerve and the medial cutaneous nerve of the forearm lie close to the medial side of the artery as far as the

insertion of the coraco-brachialis; then they leave it. The ulnar nerve inclines backwards, pierces the medial intermuscular septum and, passing behind the medial epicondyle, enters the forearm. The medial cutaneous nerve of the forearm inclines forwards and medially, pierces the fascia brachii and becomes superficial. The radial nerve is behind the proximal part of the artery, but it soon leaves it by passing distally and laterally into the sulcus for the radial nerve, between the medial and the lateral heads of the triceps.

**Branches of the Brachial Artery.**—Several branches arise from the brachial artery. Those which arise from its lateral aspect are irregular in number, origin, and size. They are termed the *lateral branches*, and are distributed to the muscles and integument on the front of the arm. The series of *medial branches* which proceed from the medial and posterior aspect of the parent trunk are named as follows as we meet them proximo-distally:—

1. A. profunda brachii.
2. A. collateralis ulnaris superior.
3. A. nutricia humeri.
4. A. collateralis ulnaris inferior.

The *profunda artery* (O.T. superior profunda) is the largest of the branches which spring from the brachial trunk. It takes origin about an inch or so distal to the lower margin of the teres major, and associates itself with the radial (musculo-spiral) nerve, which it accompanies to the back of the arm. Consequently, only a short part of the vessel is seen in the present dissection. It soon disappears from view between the long and medial heads of the triceps.

The *superior ulnar collateral artery* (O.T. inferior profunda) is a long slender artery, which can be recognised from the fact that it follows closely the course pursued by the ulnar nerve. Its origin is somewhat variable. As a general rule, it issues from the brachial artery opposite the insertion of the coraco-brachialis, but very frequently it will be seen to arise in common with the profunda brachii. It pierces the medial intermuscular septum, with the ulnar nerve, and descends behind this fascial partition to the interval between the olecranon and the medial epicondyle of the humerus.

The *nutrient artery* may arise directly from the brachial trunk, or take origin from the superior ulnar collateral

artery. It should be sought for at the distal border of the insertion of the coraco-brachialis, and the dissector should not be satisfied until he has traced it into the nutrient foramen of the bone. When the nutrient artery

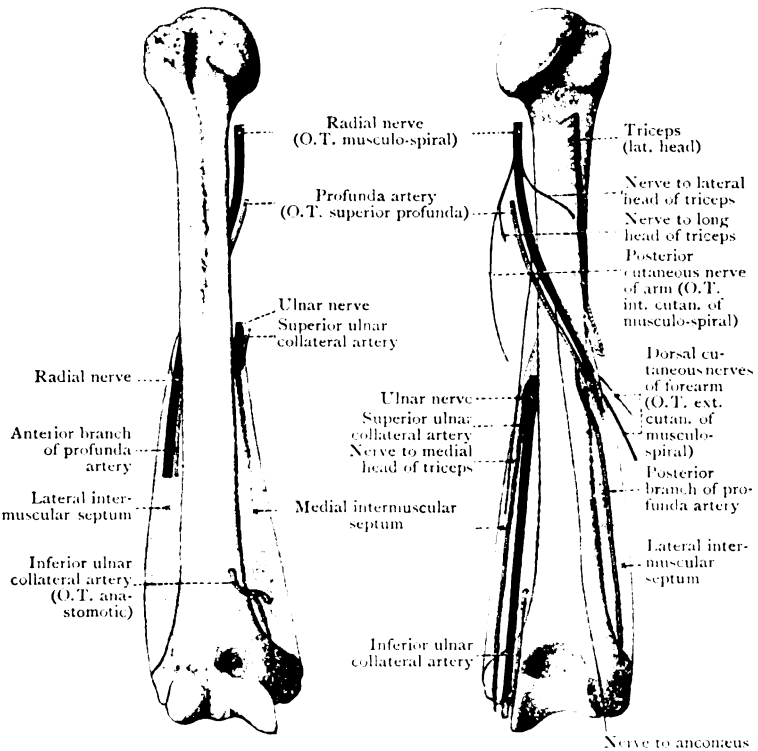
Radial nerve (O.T. musculo-spiral)
Profunda artery (O.T. superior profunda)
Ulnar nerve
Superior ulnar collateral artery
Radial nerve
Anterior branch of profunda artery
Lateral intermuscular septum
Inferior ulnar collateral artery (O.T. anastomotic)
Ulnar nerve
Superior ulnar collateral artery
Nerve to medial head of triceps
Medial intermuscular septum
Inferior ulnar collateral artery
Triceps (lat. head)
Nerve to lateral head of triceps
Nerve to long head of triceps
Posterior cutaneous nerve of arm (O.T. int. cutan. of musculo-spiral)
Dorsal cutaneous nerves of forearm (O.T. ext. cutan. of musculo-spiral)
Posterior branch of profunda artery
Lateral intermuscular septum
Nerve to anconeus

FIG. 32.—Diagram to show relation of Radial Nerve (O.T. Musculo-spiral) to the Humerus, and of Vessels and Nerves to the Intermuscular Septa.

is not seen in its usual position it will probably be found in the dissection of the back of the arm, taking origin from the profunda artery.

The *inferior ulnar collateral artery* (O.T. anastomotica) arises about two inches proximal to the bend of the elbow, and runs medially upon the brachialis. It soon divides into a small anterior and a larger posterior branch. The *anterior branch*

is carried distally in front of the medial epicondyle of the humerus, in the interval between the brachialis and the pronator teres. It anastomoses in this situation with the volar ulnar recurrent artery. The *posterior branch* pierces the medial intermuscular septum and will be seen, at a later stage, in the posterior compartment of the arm.

**Nervus Cutaneus Brachii Medialis et Nervus Cutaneus Antibrachii Medialis (O.T. Lesser Internal Cutaneous and Internal Cutaneous Nerves).**—Very little more requires to be said about these nerves. Their origin within the axilla has already been noted, and they have been traced to their distribution from the points where they pierce the investing fascia of the arm. It only remains for the dissector to examine them in that part of their course in which they lie under cover of the fascia of the arm. Note that they both lie along the medial side of the brachial artery. The *medial cutaneous nerve of the arm* gives off, as a rule, no branches in this situation, except one or more twigs of communication to the intercosto-brachial nerve. The *medial cutaneous nerve of the forearm* gives off branches which pierce the fascia to supply the skin over the biceps brachii.

**Nervus Medianus et Nervus Ulnaris.**—These large nerve trunks do not furnish any branches in the arm. The *median nerve* arises in the axilla, by two heads, from the lateral and medial cords of the brachial plexus. It proceeds distally, upon the lateral and superficial aspect of the axillary and brachial arteries, until it approaches the level of the insertion of the coraco-brachialis. Here it lies in front of the brachial artery. Finally, it reaches the medial side of the vessel, and maintains this position for the rest of its course in the arm.

—The *ulnar nerve* is the largest branch of the medial cord of the brachial plexus. It descends upon the medial side of the axillary and brachial arteries, and at the insertion of the coraco-brachialis it encounters the superior ulnar collateral artery. Accompanied by this vessel, it leaves the brachial artery, passes backwards through the medial intermuscular septum, and it is continued distally, upon the posterior aspect of this fascial partition, to the interval between the olecranon and medial epicondyle of the humerus.

*Dissection.*—The muscles should now be thoroughly cleaned, and the musculo-cutaneous nerve and its branches should be dissected out.

**Nervus Musculocutaneus.**—The musculo-cutaneous nerve arises from the lateral cord of the brachial plexus, at the lower border of the pectoralis minor. Inclining laterally, it perforates the coraco-brachialis, and passes between the biceps brachii and the brachialis. It proceeds obliquely distally between those muscles until it reaches the bend of the elbow, where it comes to the surface at the lateral border of the tendon of the biceps brachii. From that point onwards it has already been traced as the lateral cutaneous nerve of the forearm (p. 67).

In the arm the musculo-cutaneous nerve supplies branches to the three muscles of the region. The branch to the coraco-brachialis is given off before the parent trunk enters the substance of the muscle; the branches to the biceps brachii and brachialis issue from it as it lies between them.

**M. Coracobrachialis.**—This is an elongated muscle, which takes origin from the tip of the coracoid process, in conjunction with the short head of the biceps brachii. It proceeds distally, along the medial margin of the biceps brachii, and obtains insertion into a linear ridge situated upon the medial aspect of the body of the humerus, about its middle.

**M. Biceps Brachii.**—The biceps brachii muscle arises from the scapula by two distinct heads of origin. The *short* or *medial head* springs from the tip of the coracoid process in conjunction with the coraco-brachialis (Fig. 15, p. 34). The *long* or *lateral head* is a rounded tendon, which occupies the intertubercular sulcus of the humerus. Its origin cannot be studied at this stage of the dissection, because it is placed within the capsule of the shoulder-joint. Suffice it, for the present, to say that it arises from an impression on the scapula immediately above the glenoid cavity. Both heads swell out into elongated fleshy bellies, which, at first, are merely closely applied to each other, but afterwards are united in the distal third of the arm. Towards the bend of the elbow the fleshy fibres converge upon a stout, short tendon, which is inserted into the dorsal part of the tuberosity of the radius. This insertion will be more fully examined at a later period, but it may be noticed, in the meantime, that the tendon is twisted so as to present its margins to the front and dorsal aspect of the limb, and, further, that a bursa mucosa is interposed between it and the smooth, volar part of the radial tuberosity.

The dissector has already taken notice of the *lacertus fibrosus*, and has separated it artificially from the deep fascia of the arm, and of the forearm. Observe now that it springs from the anterior margin of the tendon of the biceps brachii, and also that it receives some muscular fibres from the short head of the muscle.

**M. Brachialis** (O.T. **Brachialis Anticus**).—The brachialis arises from the entire width of the anterior surface of the distal half of the body of the humerus, from the medial intermuscular septum, and from a small part of the lateral intermuscular septum proximal to the brachio-radialis. The origin from the bone is prolonged proximally in two slips which partially embrace the insertion of the deltoid. The fibres converge to be inserted into the base of the coronoid process of the ulna by a short, thick tendon. The muscle lies partly under cover of the biceps brachii, but projects beyond it on each side. It is overlapped on its medial side by the pronator teres, and on the lateral side by the brachio-radialis and

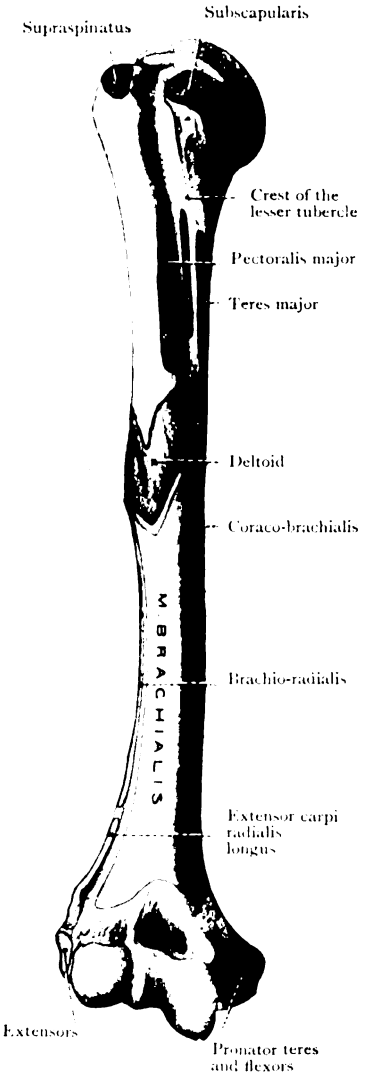


FIG. 33.—Anterior aspect of Humerus with Muscular Attachments mapped out.

extensor carpi radialis longus. Its deep surface is closely connected to the anterior part of the capsule of the elbow-joint. Its chief nerve of supply, from the *musculo-cutaneous*,

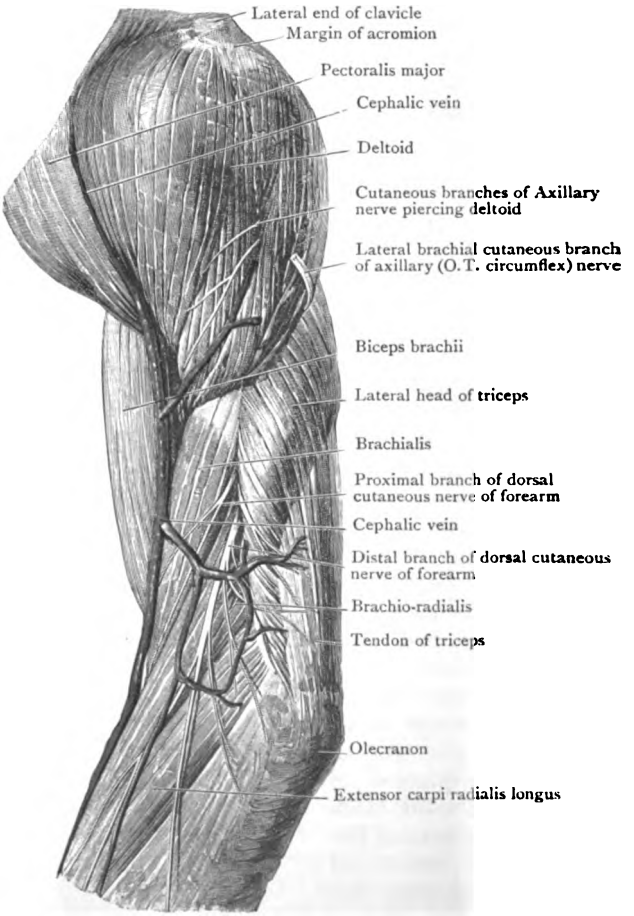


FIG. 34.—The Deltoid Muscle and the lateral aspect of the Arm.

has already been secured, but it receives also one or two small twigs from the radial (*musculo-spiral*) nerve which are given off under cover of the brachio-radialis.

*Dissection.*—Separate the brachio-radialis from the brachialis muscle,

and dissect out the radial nerve, with the anterior terminal branch of the profunda brachii artery, which lie deeply in the interval between them. There also, in a well-injected subject, the anastomosis between the profunda brachii artery and the radial recurrent arteries may be made out; and the twigs which are given by the radial nerve to the brachialis, the brachio-radialis, and the extensor carpi radialis longus, should be looked for.

**Fossa Cubitalis** (O.T. **Antecubital Fossa**).—The cubital fossa is a slight hollow in front of the elbow-joint. It corresponds to the fossa poplitea of the lower extremity, and within its area the brachial artery divides into its two terminal branches. In the first instance, consider the structures which form the coverings or roof of the fossa. Some of these have already been removed; they are the skin, superficial fascia, and deep fascia. In the superficial fascia are the median basilic and median cephalic veins, the lateral cutaneous nerve of the forearm, and the volar branch of the medial cutaneous nerve of the forearm.

The fossa is triangular. Its *base* is directed proximally, and is usually regarded as being formed by a line drawn between the two epicondyles of the humerus. The *medial boundary* is the pronator teres muscle, and the *lateral boundary* is the brachio-radialis. The meeting of the two muscles distally constitutes the *apex* of the fossa. The boundaries must first be cleaned, then the contents of the fossa may be dissected.

Within the fossa are the termination of the brachial artery and the proximal parts of the radial and ulnar arteries, into which it divides. To the lateral side of the main vessel is placed the tendon of the biceps brachii, and to its medial side, the median nerve. A quantity of loose fat also is present. The ulnar artery leaves the space by passing under cover of the pronator teres; the radial artery is continued distally beyond the apex of the fossa, overlapped by the brachio-radialis. The median nerve disappears between the two heads of the pronator teres, and the tendon of the biceps brachii inclines posteriorly, between the two bones of the forearm, to reach its insertion into the radial tuberosity.

When the fatty tissue has been thoroughly removed the *floor* of the space will be revealed. It is formed by the brachialis and the supinator muscles. The brachialis is closely applied to the anterior aspect of the capsule of the elbow-joint, whilst the supinator is wrapped round the proximal part of the radius.

Now divide the lacertus fibrosus, and separate the bounding muscles widely from each other. Other structures come into view, but they cannot, strictly speaking, be regarded as lying within the space proper. They are—(1) the radial nerve,

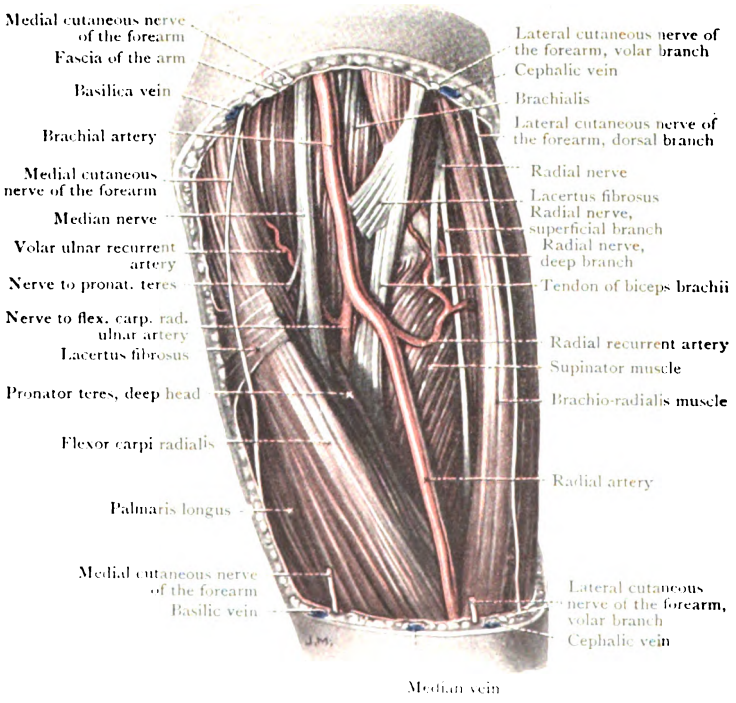


FIG. 35.—Dissection of the Left Cubital Fossa.

the anterior branch of the profunda brachii artery, and the recurrent branches of the radial artery, lying deeply in the interval between the brachio-radialis and the brachialis; (2) the anterior branch of the inferior ulnar collateral artery and the anterior recurrent branch of the ulnar artery, placed under cover of the pronator teres.

## DORSUM OF THE ARM.

In this region the following are the structures which require to be studied:—

1. The triceps muscle.
2. The profunda brachii artery, and the radial nerve.
3. The superior ulnar collateral artery, and the ulnar nerve.
4. The posterior branch of the inferior ulnar collateral nerve.
5. The subanconæus muscle.

*Dissection.*—The skin has already been removed from the dorsum of the arm. The deep fascia should now be raised from the surface of the triceps muscle, and its three heads should be cleaned and isolated from each other. To place the muscle on the stretch, the inferior angle of the scapula should be raised as high as possible, and the forearm flexed at the elbow-joint. The radial nerve, together with the profunda brachii artery, must at the same time receive the attention of the dissector. They should be followed backwards between the heads of the triceps, and all their branches should be carefully preserved.

**M. Triceps Brachii.**—The triceps muscle occupies the entire posterior osteo-fascial compartment of the arm. It arises by a *long* or *middle head* from the scapula, and by two shorter heads, *lateral* and *medial*, from the humerus. The fleshy fibres of these three heads join a common tendon, which is inserted into the proximal surface of the olecranon of the ulna. The superficial part of the muscle is, for the most part, formed by the long head and the lateral head of the muscle. The medial head is deeply placed; only a very small portion of it appears superficially, in the distal part of the arm, on each side of the common tendon of insertion.

The *long head* of the triceps arises, by a flattened tendon, from the rough triangular impression on the upper part of the axillary border and the lower aspect of the neck of the scapula (Fig. 15, p. 34). This tendon takes origin in the interval between the teres minor and subscapularis muscles.

The *two humeral heads* take origin from the posterior aspect of the humerus; and if it is borne in mind that no fibres arise from the sulcus for the radial nerve and that the groove intervenes between the origins of the two heads, their relations will be easily understood. The dissector should provide himself with a humerus, and, having first identified the sulcus for the radial nerve, proceed to map out the areas of attach-

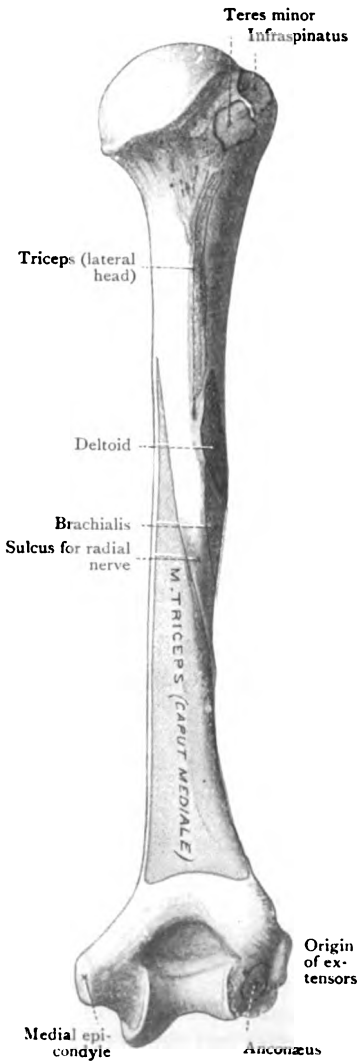


FIG. 36.—Dorsal aspect of the Humerus with Attachments of Muscles mapped out.

ment of the humeral heads of the triceps as they are exhibited in the dissected part.

The *lateral head* of the triceps arises from the lateral and posterior aspect of the body of the humerus, proximal to the sulcus for the radial nerve. It takes origin, by short tendinous fibres, along a line which passes distally from the insertion of the teres minor to the proximal border of the sulcus for the radial nerve. But it derives fibres also from a strong fascial bridge or arch, which is thrown over the groove, so as to give protection to the profunda brachii artery and the radial nerve. The strength and position of this arch can be tested by thrusting the handle of the knife distally and laterally in the sulcus for the radial nerve, and along the course of the nerve and artery, under the lateral head of the triceps. By its distal end the arch is connected with the lateral intermuscular septum.

The *medial head* of the triceps is placed distal to the sulcus for the radial nerve. Its proximal end, which is narrow and pointed, lies close to the distal end of the insertion of the

teres major. The origin gradually widens as the sulcus from the radial nerve passes towards the lateral borders of the humerus, and in the distal third of the arm it covers the posterior surface of the humerus from the lateral to the medial border (Fig. 36). It springs also from the posterior surface of the medial intermuscular septum, and from the distal part of the corresponding surface of the lateral intermuscular septum. The medial head of the triceps, therefore, has very much the same origin from the posterior surface of the bone that the brachialis has from the anterior aspect.

The dissector should now study the *common tendon of insertion* of the triceps. The long and the lateral heads end in a broad, flat tendon, which is inserted into the back part of the proximal surface of the olecranon, and at the same time gives off, on the lateral side, a strong expansion to the fascia of the forearm as it covers the anconæus muscle. The short fleshy fibres of the medial head are, for the most part, inserted into the deep surface of the common tendon, but a considerable number find direct attachment to the olecranon, whilst a few of the deepest fibres are inserted into the loose posterior part of the capsule of the elbow-joint. These latter fibres have been described as a separate muscle under the name of *subanconæus*. The triceps is supplied by branches from the *radial nerve*.

*Dissection.*—In order that the radial nerve and the profunda brachii artery may be fully exposed, the lateral head of the triceps must be divided. Thrust the handle of a knife along the sulcus for the radial nerve, and under the muscle. This will give the direction in which the lateral head of the triceps should be severed. Beyond cleaning the nerve and its branches, and the profunda brachii artery, as they lie in the groove, no further dissection is necessary.

**Nervus Radialis** (O.T. **Musculo-Spiral Nerve**).—The radial nerve is the direct continuation of the posterior cord of the brachial plexus after it has furnished, in the axilla, the two subscapular nerves, the thoraco-dorsal nerve, and the axillary nerve. In the first instance, the radial nerve proceeds distally, behind the distal part of the axillary artery and the proximal part of the brachial artery. It soon leaves the anterior aspect of the arm, however, and, inclining backwards, with the *profunda brachii artery*, enters the interval between the long and the medial heads of the triceps, and reaches the sulcus for the radial nerve. In this it passes round the back of the body

the humerus, under cover of the lateral head of the triceps, and on the lateral side of the limb it pierces the lateral intermuscular septum and appears in the anterior compartment of the arm.

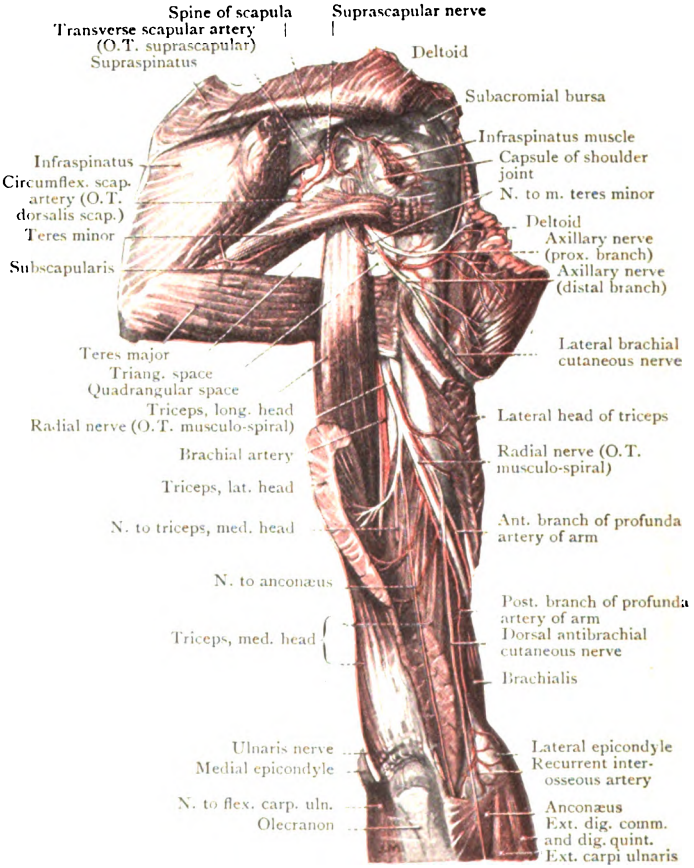


FIG. 37.—Dissection of the dorsal aspect of the Arm. The lateral head of the Triceps has been divided and turned aside to expose the sulcus on the Humerus for the radial nerve.

Here it has already been exposed. It lies deeply in the interval between the brachialis on the medial side, and the brachio-radialis and extensor carpi radialis longus on the lateral side. It ends at the level of the lateral epicondyle of

the humerus by dividing into two terminal branches, viz., the ramus superficialis (O.T. radial) and the ramus profundus (O.T. posterior interosseous). The radial nerve presents, therefore, very different relations as it is traced from its origin to its termination: (1) between the subscapularis, latissimus dorsi, teres major, and long head of the triceps, which support it behind, and the axillary and brachial arteries which are placed in front of it; (2) between the long and the medial heads of the triceps; (3) in the sulcus for the radial nerve, between the bone and the lateral head of the triceps; (4) in the interval between the brachialis on the medial side, and the brachio-radialis and extensor carpi radialis longus on the lateral side.

The branches which proceed from the radial nerve are *muscular*, *cutaneous*, and *terminal*.

The *cutaneous branches* are two in number, and have already been traced. They are—(1) the posterior cutaneous nerve of the arm, and (2) and (3) the dorsal cutaneous nerve of the forearm.

The *muscular branches* are distributed to the three heads of the triceps, to the anconæus, to the lateral fibres of the brachialis, to the brachio radialis, and to the extensor carpi radialis longus. The branches to the three last-named muscles spring from the trunk of the nerve after it has pierced the lateral intermuscular septum. The branch to the medial head of the triceps is a long slender nerve, termed the *ulnar collateral nerve*, on account of its association with the ulnar nerve in the arm. The branch to the anconæus is a long slender twig which passes through the substance of the medial head of the triceps on its way to the anconæus (Fig. 37).

The *terminal branches* are the *superficial ramus*, which is a purely cutaneous nerve, and the *deep ramus profundus*, which is continued into the dorsal part of the forearm as the dorsal interosseous nerve, and is distributed to the muscles on the dorsal aspect of the forearm, and to the radio-carpal joint. These nerves will be followed later.

**Arteria Profunda Brachii.**—The profunda brachii artery has been already seen taking origin from the brachial trunk, immediately distal to the lower margin of the teres major muscle. It accompanies the radial nerve, and its relations to the three heads of the triceps and the sulcus for the

radial nerve are exactly the same as those of the nerve. Before it reaches the lateral intermuscular septum, it ends by dividing into two terminal branches—an anterior and a posterior. The *anterior* and *smaller branch* accompanies the radial nerve through the septum, and follows it distally to the anterior aspect of the lateral epicondyle of the humerus, where it anastomoses with the radial recurrent arteries. The *posterior, larger branch* descends on the posterior surface of the lateral intermuscular septum, and anastomoses on the back of the lateral epicondyle of the humerus with the interosseous recurrent artery.

The branches which proceed from the *profunda brachii artery* are distributed chiefly to the three heads of the triceps muscle. One twig runs proximally between the long and lateral heads of the muscle, and anastomoses with the *posterior circumflex artery of the humerus.* In this way a link is established between the axillary and brachial systems of branches.

*Dissection.*—The ulnar nerve, with the superior ulnar collateral artery, and the slender ulnar collateral nerve, can now be satisfactorily followed, as they proceed distally upon the posterior aspect of the medial intermuscular septum. They are covered by a thin layer of fleshy fibres belonging to the medial head of the triceps. The posterior branch of the inferior ulnar collateral artery, after it has pierced the medial septum, should also be dissected out. As a rule, a transverse branch passes between this vessel and the posterior terminal part of the profunda brachii artery. It lies upon the posterior aspect of the humerus, immediately proximal to the elbow-joint, and can be exposed by dividing the triceps muscle a short distance from the olecranon. At the same time the fleshy fibres of the medial head of the triceps, which are inserted into the posterior part of the capsule of the elbow-joint, and constitute the *subanconæus muscle*, should be examined. Lastly, raise the distal piece of the triceps from the elbow-joint, and look for a small bursa mucosa between the deep surface of the triceps tendon and the proximal aspect of the olecranon.

## ARTICULATIO HUMERI (SHOULDER-JOINT).

Before proceeding to the dissection of the forearm it is advisable to study the shoulder-joint, because if this is deferred too long the ligaments are apt to become dry.

In no joint in the body are the movements so free and so varied in their character as in the shoulder-joint. This is rendered necessary by the many functions which are performed by the upper limb. Freedom of movement is provided for in two ways—(1) by the large size of the head of

the humerus, in comparison with the small dimensions and shallow character of the glenoid cavity—the socket in which it moves; (2) by the great laxity of the ligamentous structures which connect the humerus with the scapula. These provisions for allowing an extensive range of movement at this articulation might, at first sight, lead one to doubt the security of the joint. Its strength certainly does not lie in the adaptation of the bony surfaces to one another, nor in the strength of its ligaments. It lies—(1) in the powerful muscles by which it is closely surrounded; (2) in the overhanging coraco-acromial arch, which forms, as it were, a secondary socket for the head of the humerus, and effectually prevents any displacement in an upward

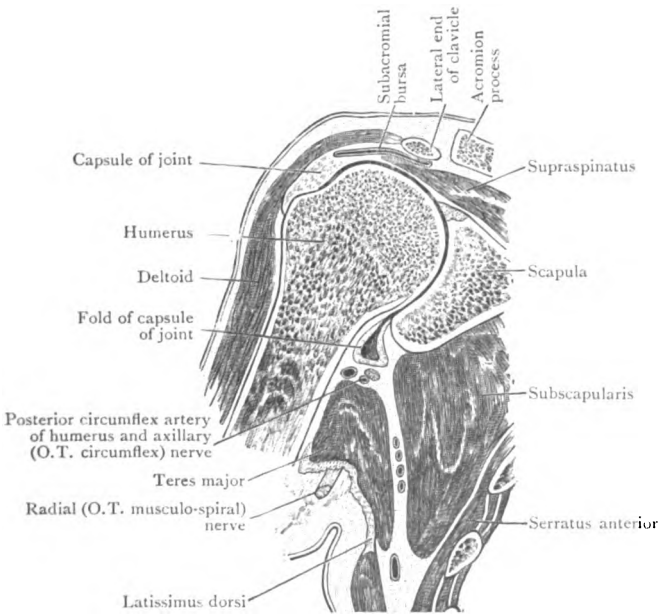


FIG. 38.—Frontal or vertical transverse section through the Left Shoulder-joint. (Viewed from behind.)

direction; and (3) in atmospheric pressure, which exercises a powerful influence in keeping the opposed surfaces in contact with each other.

On all aspects, except over a small area below, the loose, ligamentous capsule which envelops the shoulder-joint is supported by muscles, the tendons of which are more or less intimately connected with it. *Above*, it is covered by the supraspinatus; *behind*, the infraspinatus and teres minor are applied to it; *in front* is the subscapularis. *Below*, the capsule is to a certain extent unsupported by muscles, and here it is prolonged downwards, in the form of a fold, in the ordinary dependent position of the limb (Fig. 38). When, however, the arm is abducted, this fold is

obliterated, and the head of the bone rests upon the inferior part of the capsule, which now receives partial support from two muscles which are stretched under it, viz., the long head of the triceps and the teres major. Still, this must be regarded as the weakest part of the joint, and consequently dislocation of the head of the humerus downwards into the axilla, through the inferior part of the capsule, is an occurrence of considerable frequency.

*Dissection.*—Detach the axillary vessels and brachial nerves from the coracoid process, to which they have been tied, and throw them distally. Then proceed to remove the muscles. Divide the conjoined origin of the short head of the biceps brachii and the coraco-brachialis close to the coracoid process, the teres major about its middle, and the long head of the triceps about an inch or two distal to its origin, and turn them aside. Next, deal with the muscles more immediately in relation to the joint, viz., the supraspinatus, the infraspinatus, the teres minor, and the subscapularis. These must be removed with great care, because their tendons are closely connected with the subjacent ligamentous capsule. They are not incorporated with the capsule, however, although at first sight they appear to be so, and thus they can be dissected from it. In the case of the subscapularis a protrusion of the synovial membrane, forming a bursa mucosa, will be found near its upper border, close to the root of the coracoid process. The capsule of the shoulder-joint may now be cleaned, and its attachments defined.

The *ligaments* in connection with the shoulder-joint are :—

1. The capsula articularis.
2. The lig. coracohumerale.
3. The lig. glenohumerale.
4. The labrum glenoidale.

**Capsula Articularis.** — The articular capsule of the shoulder-joint is a dense and strong ligamentous structure, which envelops the articulation on all sides. The fibrous stratum is attached to the scapula around the glenoid cavity, but only above is it directly fixed to the bone. Elsewhere it springs from the fibrous ring, the *labrum glenoidale*, which serves to deepen the articular cavity; indeed, in its lower part it appears to be continuous with the border of the labrum glenoidale. Laterally, it is fixed to the anatomical neck of the humerus. The width of the capsule is not uniform throughout. It expands as it passes over the enclosed head of the humerus, and contracts as it reaches its scapular and humeral attachments. The great laxity of the capsule of the shoulder-joint will now be apparent. When the muscles are removed, and air is admitted into the joint, the bony surfaces fall away from each other—the head of the humerus sinking downwards, when the limb is held by the scapula, to the extent of an inch.

The fibrous stratum of the capsule of the shoulder-joint is not complete upon all aspects. Its continuity is broken by two, and sometimes three, apertures. The largest is an opening of

some size, which is placed upon its medial aspect, near the root of the coracoid process. Through this aperture an extensive protrusion of the synovial stratum takes place in the form of a bursa mucosa, which, from its position under the upper part of the subscapularis muscle, receives the name of the *bursa subscapularis*. It is important to note the position and character of this opening, seeing that in some cases the head of the bone may be driven through it, in dislocation of the joint. The *second aperture* is smaller and more distinctly

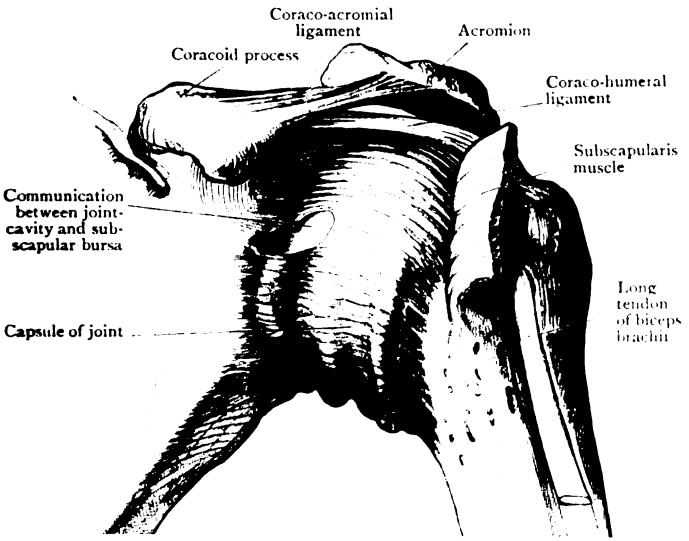


FIG. 39.—Shoulder-joint as seen from the front.

defined. It is placed between the two tubercles of the humerus, at the proximal part of the intertubercular sulcus, and it is through this that the long, tendinous head of the biceps brachii gains admission to the interior of the capsule. The synovial stratum protrudes from this opening also, and lines the intertubercular sulcus as far as the insertion of the pectoralis major. It is not often that the *third opening* is seen. It is situated, when present, on the lateral or posterior aspect of the capsule, and allows a pocket of synovial stratum to bulge out, in the form of a bursa, under cover of the infraspinatus muscle.

At certain points the capsule of the shoulder-joint is specially thickened by the addition of fibres, which pass from the scapula to the humerus. Two of these thickened portions receive the names of the *coraco-humeral* and the *gleno-humeral ligaments*. A third is placed on the inferior aspect of the capsule, where it is not supported by muscles, viz., between the long head of the triceps and the subscapularis. It is against this thickened portion of the capsule that the head of the humerus rests when the arm is abducted from the side, and it is sometimes spoken of as the *inferior gleno-humeral ligament*.

**Ligamentum Coracohumerale.**—The coraco-humeral ligament is placed upon the superior aspect of the joint. It is a broad band of great strength, which is more or less completely incorporated with the capsule. Proximally, it is fixed to the root and lateral border of the coracoid process of the scapula, and it passes from this, obliquely distally and laterally, to gain attachment to the two tubercles of the humerus. It forms a strong arch over the upper part of the intertubercular sulcus, under which the tendon of the biceps passes.

**Ligamentum Glenohumerale.**—The gleno-humeral ligament can be seen only when the joint is opened. The dissector should therefore, at this stage, remove the posterior part of the capsule, and, drawing the bones well apart from each other, look forwards into the cavity. The tendon of the biceps will be seen arching over the head of the humerus, from its attachment to the upper aspect of the glenoid cavity. Immediately medial to this, and parallel to it, will be noticed a ridge on the inner aspect of the capsule projecting into the joint. This band is the gleno-humeral ligament (of Flood). It is attached to a faintly-marked pit on the anatomical neck of the humerus, close to the proximal end of the intertubercular sulcus.

As already noted, the thickened band in the inferior part of the capsule is sometimes called the *inferior gleno-humeral ligament*. Another thickening of the anterior wall of the capsule between this and the gleno-humeral ligament proper has received the name of the *middle gleno-humeral ligament*.

*Dissection.*—Complete the division of the capsular ligament, and drawing the tendon of the biceps brachii through the intertubercular aperture in the capsule, separate the two bones from each other.

**Labrum Glenoidale** (O.T. **Glenoid Ligament**).—The labrum glenoidale is the dense fibro-cartilaginous band which

surrounds the margin of the glenoid cavity of the scapula, and is attached to its rim. It deepens, and at the same time serves to extend, the articular socket of the scapula. The intimate connection which it presents with the capsule of the joint can now be studied. Two tendons are also closely associated with it, viz., the long head of the triceps brachii below, and the long head of the biceps brachii above.

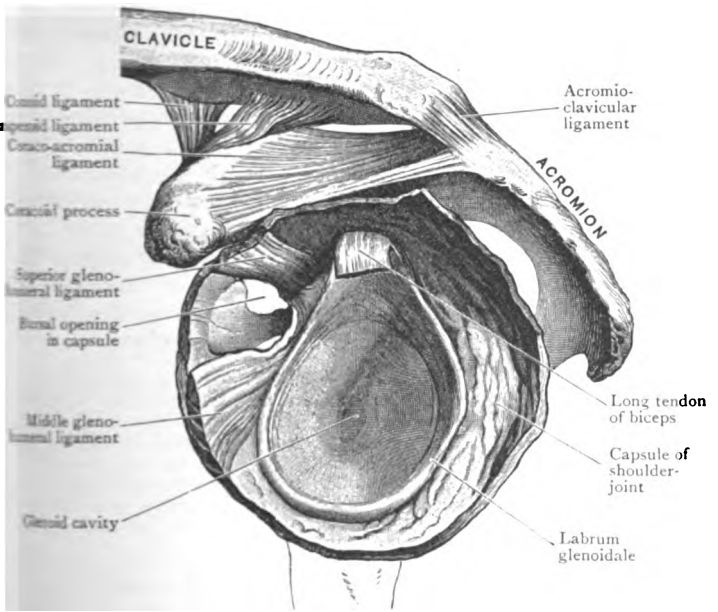


FIG. 40.—Shoulder-joint. The Articular Capsule has been cut across and the Humerus removed.

**Long Head of the Biceps.** — The long tendon which receives this name is an important factor in the construction of the shoulder-joint. Entering the capsule through the opening between the two tubercles of the humerus, it is prolonged over the head of the bone to the top of the glenoid cavity. Its origin should now be examined. It divides into three portions, viz., a large intermediate part, which obtains direct attachment to the scapula, and two smaller collateral parts, which diverge from each other and blend with the labrum glenoidale. The long head of the biceps brachii,

by its position within the capsule and in the deep sulcus between the tubercles of the humerus, serves to keep the head of the bone in place, and to steady it in the various movements at the shoulder-joint.

The synovial stratum lines the fibrous stratum of the capsule of the joint, and is reflected from it upon the anatomical neck of the humerus as far as the articular margin of the head of the bone. The bursal protrusion of the *bursa subscapularis*, under the tendon of the subscapularis muscle, has already been noticed. The tendon of the biceps, as it traverses the joint, is enveloped in a tubular sheath of the membrane; this sheath bulges out through the opening of the capsule in the form of a bursa, which lines the intertubercular sulcus, and receives the name of *bursa intertubercularis*.

**Articular Surfaces.**—The smooth, glistening articular cartilage which coats the head of the humerus is thickest in the centre, and thins as it passes towards the edges. In the case of the glenoid cavity the reverse of this will be noticed; the cartilaginous coating is thinnest in the centre, and becomes thicker as it is traced towards the circumference.

**Movements at the Shoulder-joint.**—The shoulder is a ball-and-socket joint (enarthrosis), and consequently movement in every direction is permitted, viz.—(1) *flexion*, or forward movement; (2) *extension*, or backward movement (checked in its extent by the coraco-humeral ligament); (3) *abduction*, or lateral movement (checked by the coraco-acromial arch); (4) *adduction*, or medial movement (limited by the coraco-humeral ligament). By combination the angular movements, in regular sequence, *circumduction* is produced, and *rotation* of the humerus, to the extent of quarter of a circle, occurs also.

The **muscles** chiefly concerned in producing these movements are:—*flexion*—the pectoralis major and the anterior part of the deltoid; *extension*—latissimus dorsi, posterior part of the deltoid, and the teres major; *abduction*—the deltoid and supraspinatus; *adduction*—pectoralis major, coraco-brachialis, teres major, and latissimus dorsi; *rotation medially*—subscapularis, pectoralis major, latissimus dorsi, teres major; *rotation laterally*—supraspinatus, infraspinatus, and teres minor; *circumduction* is produced by the action of different combinations of these muscles.

## FOREARM AND HAND.

*Dissection.*—The skin has already been removed from the volar and dorsal surfaces of the forearm. It should now be raised from the dorsum of the hand by making incisions along the radial and ulnar borders. This is done in order that the superficial structures in this region may be examined in connection with those of the forearm.

**Venæ Superficiales.**—On the dorsum of the hand a plexus

of superficial veins will be seen. In defining this, care must be taken of the fine cutaneous twigs from the *superficial* branch of the radial nerve and the dorsal branch of the ulnar nerve. From the lateral part of the venous plexus the large cephalic vein takes origin, whilst from its medial part springs the basilic vein. Both of these vessels have already been traced along the forearm to their terminations. While still upon the dorsum of the hand each communicates with the deep branches in the palm of the hand.

**Nervi Cutanei.**—Several cutaneous nerves have already been traced to the integument of the forearm, viz.—the volar and ulnar branches of the medial cutaneous nerve of the forearm, to the medial aspect; the lateral cutaneous nerve of the forearm, to the lateral region; and the dorsal cutaneous nerve of the forearm, from the radial nerve, on the dorsal aspect. Some additional twigs make their appearance by piercing the fascia in the distal third of the forearm :—

1. The n. cutaneus palmaris of the n. ulnaris,
2. The n. cutaneus palmaris of the n. medianus,
3. The n. cutaneus palmaris of the ramus superficialis of the n. radialis,

} on the volar aspect.

1. The ramus dorsalis manus of the n. ulnaris,
2. The ramus superficialis of the n. radialis,

} on the dorsal aspect.

**Palmar Cutaneous Nerves.**—The palmar cutaneous nerves are small twigs which supply the skin of the palm. The *twig from the ulnar nerve* takes origin about the middle of the forearm, but it does not at once pierce the fascia of the forearm. It proceeds distally on the ulnar artery, and becomes superficial immediately proximal to the transverse carpal ligament (O.T. anterior annular lig.), and close to the lateral side of the insertion of the flexor carpi ulnaris tendon into the pisiform bone. It is there, therefore, that it must be sought for (Fig. 27, p. 66).

The *palmar cutaneous branch of the median nerve* appears through the deep fascia in the interval between the tendons of the flexor carpi radialis and palmaris longus muscles, immediately proximal to the wrist. It is continued distally into the palm (Fig. 27, p. 66).

The *palmar branch of the superficial division of the radial nerve* runs close to the lateral border of the distal part of the forearm. It does not spring from the trunk of the

superficial division of the radial nerve, but from that branch of it which goes to the lateral margin of the thumb. It is joined by a twig from the lateral cutaneous nerve of the forearm, and proceeds distally, in front of the tendon of the abductor pollicis longus, to end in the skin covering the ball of the thumb (Fig. 27, p. 66).

*Dissection.*—In tracing the nerves which appear on the dorsum of the forearm, it will be necessary to remove the skin from the dorsal aspect of the thumb and fingers. The great flap of skin which is still attached at the roots of the fingers may be detached, and an incision can then be made along the middle of the dorsal aspect of each digit. The skin should be carefully raised from each finger in two flaps and thrown laterally and medially.

**Dorsal Cutaneous Nerves.**—The dorsal cutaneous nerves come from the ulnar and radial nerves.

The *dorsal branch of the ulnar nerve* winds round the medial margin of the wrist to reach the dorsum of the hand. It will be found immediately distal to the prominence formed by the distal end of the ulna, and it at once divides into three main terminal branches. Of these, one runs along the ulnar margin of the dorsum of the hand, and is continued onwards along the medial margin of the little finger. The *second branch* proceeds towards the cleft between the little finger and the ring finger, and divides into two twigs which supply the contiguous sides of these digits. The *third branch* joins a twig from the superficial branch of the radial nerve, and the nerve thus formed runs towards the interval between the ring finger and the middle finger, and divides to supply their adjacent margins. Each of these three main branches gives several minute filaments to the integument on the dorsum of the hand (Fig. 28, p. 68).

The *superficial branch of the radial nerve* will be found winding round the lateral margin of the forearm, about two inches proximal to the extremity of the styloid process of the radius. It at once gives off a long twig which proceeds along the radial margin of the hand and thumb. A little farther on it breaks up into four terminal branches, which are distributed as follows: the *first* supplies the medial side of the thumb; the *second* goes to the lateral side of the index finger; the *third* divides to supply the adjacent sides of the index and middle fingers; whilst the *fourth* joins with a twig from the dorsal branch of the ulnar (as already described) to supply the contiguous margins of the middle and ring fingers.

It should be noted that, except in the case of the thumb and little finger, the dorsal collateral nerves do not reach the extremities of the digits. The skin on the dorsum of the second and third phalanges of the digits is supplied chiefly by twigs which proceed dorsally from the palmar collateral branches of the median and ulnar nerves. As already stated, it is from the branch of the superficial division of the radial nerve which goes to the lateral side of the thumb that the *radial palmar cutaneous nerve* arises.

Numerous fine filaments are given to the skin on the dorsum of the hand, and a certain amount of crossing of the adjacent ulnar and radial twigs takes place in this locality; in other words, twigs from the one nerve invade the territory which is occupied by the other nerve.

**Fascia Antibrachii (Fascia of the Forearm).**—The deep fascia which envelops the forearm should now be cleaned by removing the subcutaneous adipose tissue. It is a fascia of great strength and density. More particularly is this the case on the dorsal aspect of the limb, and also in the distal third of the forearm, where the fleshy bellies of the subjacent muscles give place to the tendons. In its proximal part it receives an accession of fibres from the tendon of the biceps brachii, in the form of the lacertus fibrosus. Some fibres are given to it by the tendon of the triceps also. Near the elbow it serves as a surface of origin for the numerous muscles which spring from the epicondyles of the humerus, and from its deep aspect dense septa pass between the fleshy bellies. These partitions are indicated on the surface by a series of white lines. At the wrist it becomes continuous, anteriorly, with the *volar carpal ligament* and the *transverse carpal ligament* (O.T. ant. annular lig.), whilst posteriorly it forms an obliquely placed, thickened band, the *dorsal carpal ligament* (post. annular lig.). On the dorsum of the hand the deep fascia is thin.

### Volar Surface and Medial Border of the Forearm.

In this dissection the following structures will be brought under the notice of the student:—

1. The radial and ulnar arteries and their branches.
2. The median and ulnar nerves and their branches.
3. The deep branch and the superficial branch of the radial nerve.
4. The group of pronator and flexor muscles.

*Dissection.*—With the exception of the palmar cutaneous nerves, the superficial veins and nerves on the volar aspect of the forearm may now be turned aside. The deep fascia also should be removed, and when it is followed round the medial border of the forearm it will be found to be firmly attached to the dorsal border of the ulna. Near the elbow, as already stated, it gives origin by its deep surface to the group of muscles which spring from the medial epicondyle of the humerus. Where this is the case, it should be left *in situ*. Attempts to dissect it off will only result in laceration of the surface of the subjacent fleshy bellies. The radial artery should be followed out before the muscles are much disturbed, and, at the same time, the various muscles covering the volar surface of the radius, and upon which the vessel rests, should be cleaned.

**Arteria Radialis.**—The radial artery is the smaller of the two terminal branches of the brachial artery, but its direction gives it the appearance of being the continuation of the parent trunk into the forearm. It takes origin in the cubital fossa, opposite the neck of the radius, and it proceeds distally, along the lateral side of the volar aspect of the limb, until it reaches the distal end of the bone. There it turns round the lateral border of the wrist and leaves the present dissection. At first it lies between the pronator teres and the brachio-radialis, and is overlapped to some extent on the lateral side by the fleshy belly of the latter muscle (Fig. 41). At a more distal level it is placed between the brachio-radialis, on the lateral side, and the flexor carpi radialis, upon the medial side: and this position it maintains as far as the wrist. Where the muscles mentioned are fleshy the artery lies at some depth from the surface; but when their tendons appear it assumes a superficial position, and is covered merely by the integument and fasciæ. Throughout its whole length it is closely accompanied by the *venæ comites*, and the superficial division of the radial nerve lies along its lateral side in the middle third of the forearm. More proximally, the nerve is separated from the vessel by a slight interval; whilst distally, the nerve leaves the artery and turns round the lateral margin of the forearm, under cover of the tendon of the brachio-radialis.

*Posteriorly*, the radial artery is supported by the muscles which clothe and find attachment to the volar surface of the radius. At its origin it rests upon the tendon of the biceps brachii; next it lies in front of the supinator, with some adipose tissue intervening; thence distally it is in contact with the pronator teres, the thin radial head of the flexor digitorum sublimis, the flexor pollicis longus, the pronator quadratus, and, lastly, the distal end of the radius.

The radial artery is usually selected for the determination of the *pulse*. When the tips of the fingers are placed upon the distal part of the forearm, in the interval between the tendons of the brachio-radialis and flexor carpi radialis, the pulsations of the vessel, in the living person, can readily be felt.

**Branches of the Radial Artery.**—In the forearm the radial artery gives off the following branches, viz. :—

1. The a. recurrens radialis.
2. The a. volaris superficialis.
3. The a. carpea volaris radialis.
4. Rami musculares.

The *muscular branches* are very numerous, and proceed from the radial artery, at irregular points, throughout its whole course in the forearm.

The *radial recurrent artery* is a branch of some size. It takes origin close to the commencement of the radial artery, and, in the first instance, runs laterally between the brachio-radialis and the supinator. There it comes into relation with branches of the radial nerve, and gives off several twigs for the supply of the muscles arising from the lateral epicondyle of the humerus. Somewhat reduced in size, it now turns proximally in the interval between the brachio-radialis and brachialis, and ends, in front of the lateral epicondyle of the humerus, by anastomosing with the anterior terminal branch of the profunda brachii artery. It may be represented by two or more vessels.

The *superficial volar artery* is a small, variable branch, which arises a short distance proximal to the wrist, and runs distally to end in the muscles of the ball of the thumb. Sometimes, however, it attains a larger size and a special importance, from its being continued into the palm to complete the superficial volar arch, on the lateral side.

The *volar radial carpal artery* is a minute twig which springs from the radial at the distal border of the pronator quadratus muscle. It runs medially, under cover of the flexor tendons, and joins the corresponding branch of the ulnar artery to form the *volar carpal arch*.

**The Ramus Superficialis** and **the Ramus Profundus of the Nervus Radialis** (O.T. **Radial and Posterior Interosseous Nerves**).—It has already been noted that the radial nerve ends proximal to the elbow, under cover of the brachio-radialis muscle, by dividing into two terminal branches,

the superficial branch and the deep branch. These nerves may now be studied in so far as they lie on the volar aspect of the forearm. The *ramus profundus* soon disappears from view by passing backwards, on the lateral side of the radius, through the fibres of the supinator muscle.

The *superficial branch* proceeds distally, under cover of the fleshy belly of the brachio-radialis. In the middle

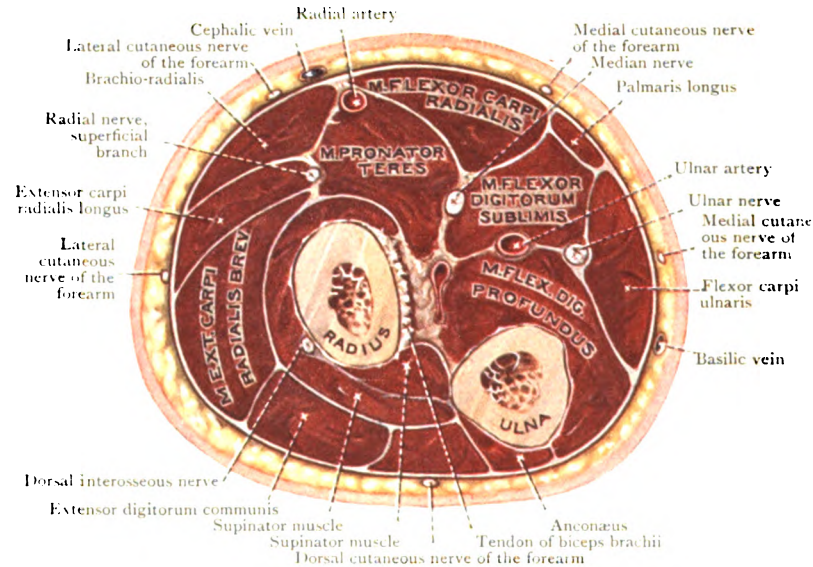


FIG. 41.—Transverse section through the Proximal Third of the left Forearm.

third of the forearm it lies along the lateral side of the radial artery, and then leaves it by winding round the lateral margin of the limb, under cover of the tendon of the brachio-radialis. It has been traced in the rest of its course (p. 96). The superficial branch is a purely cutaneous nerve; and it gives off no branches until it gains the dorsal aspect of the distal end of the forearm.

**Muscles.**—The muscles on the volar aspect and medial border of the forearm are arranged in a superficial and a deep group. They comprise the flexors of the wrist and fingers, and also the pronators. In the *superficial group*

are the pronator teres, the flexor carpi radialis, the palmaris longus, the flexor digitorum sublimis, and the flexor carpi ulnaris, in that order from the lateral to the medial side. The fleshy belly of the flexor sublimis only partially comes to the surface; the chief bulk of it is placed upon a deeper plane than the others. The *deep group* is composed of three muscles, placed in contact with the bones and interosseous membrane of the forearm, viz., the flexor digitorum profundus, in relation to the ulna, the flexor pollicis longus, in relation to the radius, and the pronator quadratus, closely applied to the distal ends of both bones.

*Dissection.*—The superficial group of muscles should now be dissected. The brachio-radialis, which lies along the lateral side of the forearm, may be cleaned at the same time. In the distal part of the forearm the dissector will note that the flexor tendons are enveloped by a loose bursa mucosa which accompanies them as they pass into the palm, under cover of the transverse carpal ligament. A good view of this may be obtained by pulling the tendons proximally. If possible, the sac should be retained uninjured, in order that its full extent may be studied when the palm of the hand is opened up. At this stage it is well to define also the transverse carpal ligament, which bridges across the front of the carpus. The tendon of the palmaris longus passes anterior to it, whilst close to the pisiform bone the ulnar artery and nerve are placed upon its volar surface, and give the dissector the key to its depth. This vessel, with its accompanying nerve, are bound down to the ligament by a more superficial band of fascia, the *volar carpal ligament*, which passes over them, and which the student is very apt to mistake for the transverse ligament itself. This band of fascia should not be disturbed in the meantime.

**Common Origin of the Superficial Muscles.**—The five muscles which constitute the superficial group are very closely associated with each other at the elbow—indeed, they may be said to arise by a common origin from the front of the medial epicondyle of the humerus. In addition to this they all derive fibres from the investing deep fascia of the limb, near the elbow, and from the strong fibrous septa which pass between the muscles from the deep surface of investing fascia. The pronator teres, the flexor sublimis, and the flexor carpi ulnaris, have additional heads of origin.

**M. Pronator Teres.**—The pronator teres muscle crosses the proximal half of the front of the forearm obliquely. It arises by two heads, viz., a humeral and an ulnar. The ***humeral head*** constitutes the chief bulk of the muscle. It springs from the proximal part of the medial epicondyle of the humerus, and also slightly, by fleshy fibres, from the distal part of the medial epicondylar ridge. The fascia covering it

and the fibrous septum on its medial side also contribute fibres. The *ulnar head* is placed deeply, and it may be recognised from the fact that it intervenes between the median nerve and the ulnar artery. To bring it into view the superficial humeral head must be drawn well to the medial side. The ulnar head is very variable in size. As a rule, it is a small fleshy slip, but sometimes it is chiefly fibrous. It arises from the medial border of the coronoid process of the ulna (Fig. 43, p. 108), and soon joins the deep surface of the humeral head. The muscle, thus formed, is carried obliquely distally and laterally, and ends in a tendon which gains insertion into a rough impression upon the middle of the lateral surface of the radius (Fig. 43, p. 108). This attachment is placed on the summit of the chief curve of the radius, an arrangement which enables the muscle to exercise its pronating action at a great advantage. Close to its insertion the pronator teres is crossed by the radial artery and is covered by the brachio-radialis muscle. It is supplied by the *median nerve*. It is a pronator of the forearm and hand and a flexor of the elbow.

**M. Flexor Carpi Radialis.**—The flexor carpi radialis arises from the common tendon, from the fascia of the forearm and the fibrous septa which intervene between it and the adjacent muscles. Its fleshy belly gives place, a short distance distal to the middle of the forearm, to a long flattened tendon, which, at the wrist, traverses the groove on the front of the os multangulum majus, in a special compartment of the transverse carpal ligament (Fig. 48, p. 122). It is inserted into the volar aspect of the base of the metacarpal bone of the index, and slightly also into the base of the metacarpal bone of the middle finger. Its relations to the transverse carpal ligament, and also its attachment to the metacarpus, will be exposed and studied at a later stage of the dissection. It is supplied by the *median nerve*.

**M. Palmaris Longus.**—This is a long slender muscle, which is not always present. It springs from the common origin, the fascial investment of the forearm and the fibrous septum on each side of it. Its tendon pierces the deep fascia immediately proximal to the wrist, and then proceeds distally, superficial to the transverse carpal ligament, to join the strong intermediate portion of the palmar aponeurosis. Very frequently it gives a slip to the abductor pollicis brevis. It is

supplied by the *median nerve*, and is a flexor of the radio-carpal and elbow joints.

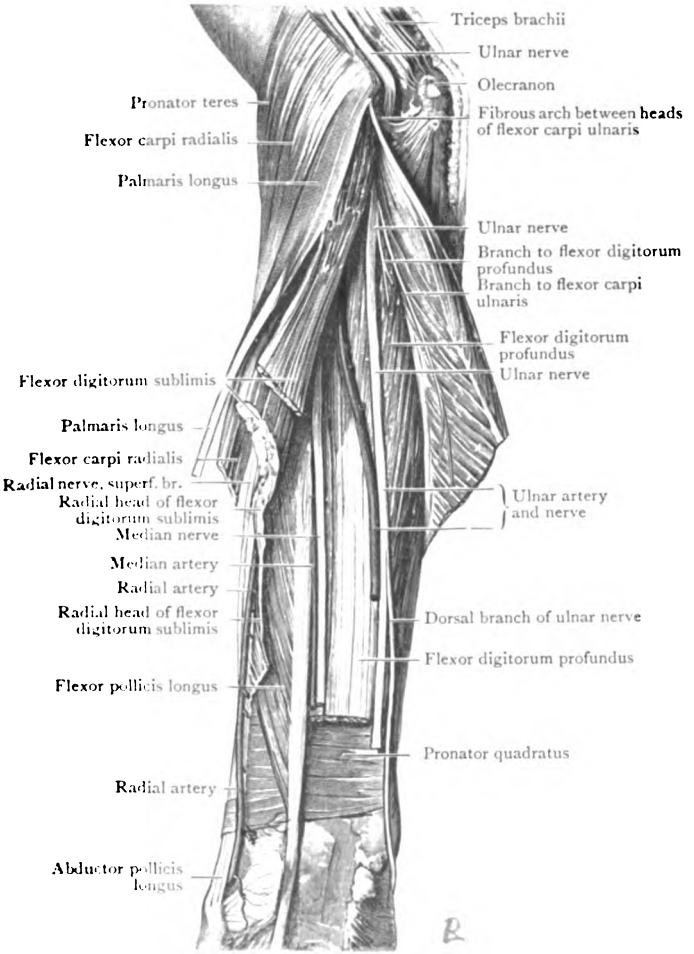


FIG. 42.—Dissection of the volar aspect of the Forearm; the superficial muscles are cut short and turned aside, and the deeper parts are still further displayed by separating the flexor digitorum sublimis from the flexor carpi ulnaris along the line of the intermuscular septum which intervenes between them.

**M. Flexor Carpi Ulnaris.**—This muscle arises by two heads.

One of these is incorporated with the common origin from the medial epicondyle; the other springs from the medial border of the olecranon of the ulna, and also by an aponeurotic attachment from the dorsal border of the same bone in its proximal two-thirds. Fibres are derived also from the investing fascia and the intermuscular septum on its lateral side. The two heads of origin of the flexor carpi ulnaris bridge across the interval between the medial epicondyle of the humerus and the olecranon, and between them the ulnar nerve is prolonged distally into the forearm. The tendon appears upon the volar border of the muscle, and is inserted into the pisiform bone. The flexor carpi ulnaris is supplied by the *ulnar nerve*. It is a flexor and adductor of the hand and a flexor of the elbow.

**M. Flexor Digitorum Sublimis.**—The flexor sublimis receives this name because it is placed upon the superficial aspect of the flexor profundus. For the most part it lies deeper than the other superficial muscles (Fig. 41). It is a powerful muscle which arises from the medial epicondyle of the humerus by the common tendon; it takes origin also from the ulnar collateral ligament of the elbow-joint, from the medial margin of the coronoid process of the ulna, the volar surface of the radius (Fig. 43, p. 108), and the fascial intermuscular septa in relation to it. The radial head of origin is a thin fleshy stratum which is attached to the volar border of the radius, from its proximal end to a variable distance beyond the insertion of the pronator teres muscle. Four tendons issue from the fleshy mass. These enter the palm by passing under cover of the transverse carpal ligament, and go to the medial four digits. Their insertions will be seen later, but, in the meantime, note that at the wrist, and for a short distance proximal to it, they are enveloped by the mucous sheath previously mentioned, and also that, as they pass behind the transverse carpal ligament, they lie in pairs—the tendons to the ring and middle fingers being placed on the volar aspect of those for the index and little fingers. The flexor digitorum sublimis is supplied by the *median nerve*.

*Dissection.*—The ulnar artery and, at the same time, the ulnar and median nerves should be followed as they pass through the forearm. The artery, in the proximal part of its course, lies very deeply; but its relations can be fully studied, and its branches traced, by simply slitting up the intermuscular septum between the flexor digitorum sublimis and the flexor carpi ulnaris.

**Arteria Ulnaris.**—The ulnar artery is the larger of the two terminal branches of the brachial trunk. It takes origin in the cubital fossa at the level of the neck of the radius. In the proximal third of the forearm it inclines obliquely distally and medially, and then it proceeds directly distally to the wrist. It enters the palm by passing anterior to the transverse carpal ligament. In the proximal oblique portion of its course the vessel is deeply placed, and is crossed by both heads of the pronator teres, the flexor carpi radialis, the palmaris longus, and the flexor digitorum sublimis. In its distal, vertical part it is overlapped on the medial side by the flexor carpi ulnaris, but a short distance proximal to the wrist it becomes superficial, and lies in the interval between the tendon of the flexor carpi ulnaris on the medial side and the tendons of the flexor sublimis on the lateral side. On the transverse carpal ligament it is placed close to the lateral side of the pisiform bone, and is covered by a strong band of fascia, the volar carpal ligament (pp. 101, 121), which lies superficial to the transverse ligament. Throughout its entire course it is accompanied by two *venæ comites*. It has important relationships with the median and ulnar nerves. The *median nerve*, which lies upon its medial side at its origin, soon crosses it, but as it does so it is separated from the artery by the deep head of the pronator teres. The *ulnar nerve* in the proximal third of the forearm is separated from the vessel by a wide interval, but in the distal two-thirds of the forearm it closely accompanies the artery, and lies on its medial side.

In the cubital fossa the ulnar artery rests upon the brachialis; more distally it is in contact posteriorly with the flexor digitorum profundus; whilst at the wrist the artery lies upon the superficial surface of the *transverse carpal ligament*.

**Branches of the Ulnar Artery.**—In the forearm the ulnar artery gives off the following branches:—

1. A. recurrens ulnaris volaris.
2. A. recurrens ulnaris dorsalis.
3. A. interossea communis.
4. A. carpea volaris.
5. A. carpea dorsalis.
6. Rami musculares.

The *muscular branches* are of small size, and come off at variable points for the supply of the neighbouring muscles.

The *volar ulnar recurrent artery* (O.T. *anterior ulnar recurrent*) is the smaller of the two recurrent branches. It runs proximally, anterior to the medial epicondyle of the humerus, in the interval between the pronator teres and the brachialis

muscles, and it anastomoses with the anterior terminal branch of the inferior ulnar collateral artery.

The *dorsal ulnar recurrent artery* (O.T. *posterior ulnar recurrent*) passes medially, under cover of the flexor digitorum sublimis, and then turns proximally, between the two heads of origin of the flexor carpi ulnaris, to gain the interval between the medial epicondyle of the humerus and the olecranon, on the dorsal aspect of the limb. There it becomes associated with the ulnar nerve, and anastomoses with the posterior terminal branch of the inferior ulnar collateral artery and with the superior ulnar collateral artery.

It is not uncommon to find the two recurrent arteries arising from the ulnar trunk by a short common stem.

The *common interosseous artery* is a short, wide trunk, which takes origin immediately distal to the recurrent branches, about an inch or so from the commencement of the ulnar artery. It proceeds dorsally, and at the proximal margin of the interosseous membrane it divides into two terminal branches, viz., the *volar* (O.T. *anterior*) and the *dorsal* (O.T. *posterior*) *interosseous arteries.*

The *ulnar carpal arteries* are two small arteries, which partially encircle the wrist. The *volar ulnar carpal artery* runs laterally, under cover of the tendons of the flexor digitorum profundus, and anastomoses with the volar carpal branch of the radial artery. From the arch, thus formed, small twigs are given to the volar aspect of the carpal bones and joints. The *dorsal ulnar carpal artery* gains the dorsal aspect of the carpus by winding round the medial margin of the limb immediately proximal to the pisiform bone, and under cover of the tendon of the flexor carpi ulnaris.

**Nervus Ulnaris.** — The ulnar nerve, which was traced in the dissection of the arm as far as the interval between the olecranon and medial epicondyle of the humerus, enters the forearm between the two heads of the flexor carpi ulnaris. It proceeds distally, upon the flexor digitorum profundus and under cover of the flexor carpi ulnaris, in the volar part of the medial side of the forearm. Close to the wrist it becomes superficial, upon the lateral side of the tendon of the flexor carpi ulnaris, and it reaches the palm by passing superficial to the transverse carpal ligament. In the proximal third of the forearm the ulnar nerve is separated from the ulnar artery by a considerable interval, but in the distal

two-thirds it is closely applied to the medial side of the vessel.

In the forearm the ulnar nerve gives off:—

1. Rami articulares.
2. Rami Musculares, { to the flexor carpi ulnaris and the medial part of the flexor profundus.
3. Rami cutanei, { ramus cutaneus palmaris. ramus dorsalis manus.

The *articular branches* come from the ulnar nerve as it lies in the interval between the olecranon and the medial epicondyle of the humerus, and pass to the elbow-joint.

The *muscular branches* are given off in the proximal part of the forearm, and supply the flexor carpi ulnaris and the medial part of the flexor digitorum profundus.

The *palmar cutaneous branch* is a minute twig which has already been seen piercing the fascia of the forearm, immediately proximal to the transverse carpal ligament. It arises about the middle of the forearm and proceeds distally upon the ulnar artery, to be distributed in the palm of the hand.

The *dorsal branch* is a nerve of some size which springs from the ulnar trunk about two and a half or three inches proximal to the wrist. It winds round the medial margin of the forearm, under cover of the flexor carpi ulnaris, and reaches the dorsum of the hand immediately distal to the prominence formed by the distal end of the ulna. From this point onwards it has been traced in the superficial dissection (p. 96).

**Nervus Medianus.**—As its name implies, the median nerve passes down the middle of the forearm; and to obtain an unbroken view of it, it is necessary to reflect the humeral head of the pronator teres and the radial head of the flexor digitorum sublimis.

In the proximal part of the forearm the median nerve lies in the cubital fossa upon the medial side of the ulnar artery. It leaves the fossa by passing between the two heads of the pronator teres, and as it does so it crosses the ulnar artery, but is separated from it by the ulnar head of the muscle. From that point the median nerve runs distally between the flexor sublimis and the flexor digitorum profundus. Near the wrist it becomes superficial, and lies in the interval between the tendons of the flexor digitorum sublimis, on the medial side, and the flexor carpi radialis, on the

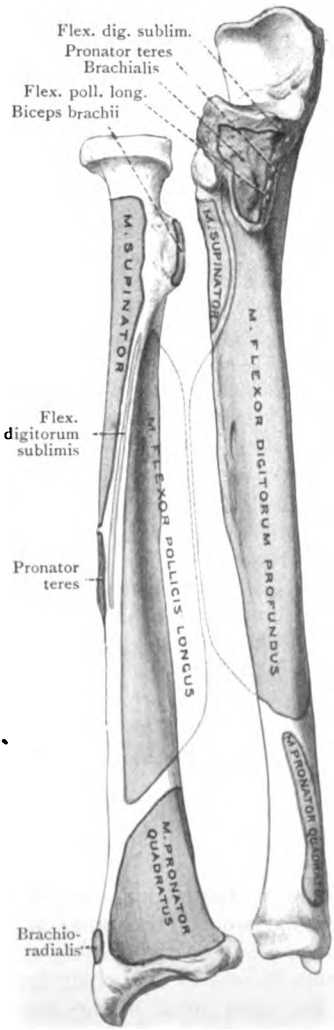


FIG. 43. — Volar aspect of Bones of Forearm with Muscular Attachments mapped out.

lateral side. Finally it leaves the forearm by passing deep to the transverse carpal ligament. A small artery, the *a. mediana*, a branch of the volar interosseous artery, accompanies the median nerve. Sometimes this vessel attains a considerable size.

As the median nerve enters the forearm it gives off numerous branches for the supply of muscles, and near the wrist it supplies a *palmar branch*, which has already been dissected (p. 95).

The *muscular branches* supply all the muscles of the superficial group, with the single exception of the flexor carpi ulnaris; viz., the pronator teres, the flexor carpi radialis, the palmaris longus, and the flexor digitorum sublimis.

It supplies also a long slender twig — *volar interosseous nerve* — which goes to the deep muscles on the volar aspect of the forearm.

**Deep Structures on the front of the Forearm.** — The connections of the deep muscles must now be studied, and, at the same time, the volar interosseous artery and volar interosseous nerve must be followed.

The flexor digitorum profundus is the large muscle which clothes the volar and

medial surfaces of the ulna; the flexor pollicis longus is placed upon the volar surface of the radius; while the pronator quadratus is a quadrate fleshy layer closely applied to both bones immediately proximal to the wrist. The artery and nerve proceed distally in the interval between the flexor profundus and flexor pollicis longus.

**M. Flexor Digitorum Profundus.**—The deep flexor of the fingers springs from the volar and medial surfaces of the ulna in its proximal three-fourths. It derives fibres also from the volar surface of the interosseous membrane and the aponeurosis by which the flexor carpi ulnaris takes origin from the dorsal border of the ulna. The fleshy mass gives place to four tendons for the medial four digits, but only one of them—that for the index finger—becomes separate and distinct in the forearm. They proceed distally, *deep to* the transverse carpal ligament, into the palm. The flexor digitorum profundus is supplied by the *volar interosseous branch of the median* and by the *ulnar nerve.*

**M. Flexor Pollicis Longus.**—The flexor pollicis longus arises from the volar surface of the radius, over an area which extends from the volar border proximally to the proximal border of the pronator quadratus distally. It takes origin also from the adjacent part of the volar surface of the interosseous membrane. A rounded tendon issues from the fleshy belly, and proceeds into the palm, under cover of the transverse carpal ligament.

In many cases the flexor pollicis longus will be observed to have an additional slender head of origin, from the medial border of the coronoid process of the ulna, or the medial epicondyle of the humerus. The flexor pollicis longus is supplied by the *volar interosseous nerve.*

**M. Pronator Quadratus.**—This is a quadrate muscle which takes origin from the volar surface of the ulna in its distal fourth, and is inserted into the volar surface of the distal fourth of the radius. It is supplied by the *volar interosseous nerve.*

**Arteria Interossea Volaris** (O.T. **Anterior Interosseous Artery**).—The volar interosseous artery has been seen to arise from the common interosseous artery. It runs distally, upon the volar surface of the interosseous membrane, in the interval between the flexor pollicis longus and the flexor digitorum profundus. At the proximal border of the pronator

quadratus it pierces the interosseous membrane, and gains the dorsal aspect of the limb.

It supplies *muscular branches* to the three deep muscles with which it is in contact. In addition to these it gives off the following branches:—

1. Median.
2. Nutrient.
3. Anterior communicating.

The *median artery* is a long delicate vessel which accompanies the median nerve. The *nutrient arteries* are two in number—one for the radius, the other for the ulna. They enter the nutrient foramina of those bones. The *anterior communicating* is a slender artery, which runs distally, to the pronator quadratus, to join the volar carpal arch.

**Nervus Interosseus Volaris.**—The volar interosseous nerve is a branch of the median, and accompanies the artery of the same name. It does not follow it, however, through the interosseous membrane, but is distributed entirely upon the volar aspect of the limb. It is the nerve of supply for the flexor pollicis longus, the lateral part of the flexor digitorum profundus, and the pronator quadratus, whilst its terminal filament proceeds distally, dorsal to the pronator quadratus, to help in the supply of the carpal joints.

The flexor digitorum profundus is therefore supplied by two nerves, viz., the ulnar and the median. The precise range of supply by each of these nerves is somewhat variable. As a general rule the division of the muscle which belongs to the index finger is supplied by the median and the part belonging to the little finger by the ulnar; whilst the portions belonging to the middle and ring digits receive filaments from both nerves.

### Wrist and Palm.

In this dissection we meet with the following structures:—

1. Palmaris brevis muscle and the palmar cutaneous nerves.
2. Palmar aponeurosis.
3. Superficial volar arch and its branches.
4. Median and ulnar nerves and their branches.
5. Volar carpal ligament, transverse carpal ligament, the flexor tendons, and their mucous sheaths.
6. The lumbrical muscles.
7. Short muscles of the thumb and little finger.
8. Deep volar arch and its branches.
9. Princeps pollicis artery and radial volar artery of the index finger.

**Surface Anatomy.**—In the centre of the palm the depression, known as the "hollow of the hand," may be noted. Along the medial border of the palm this is bounded by a

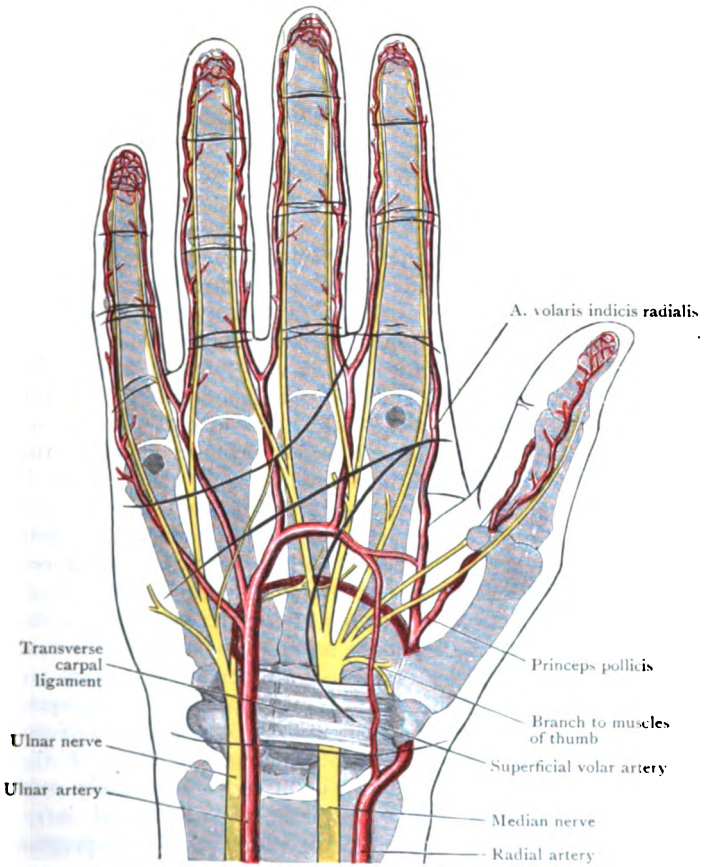


FIG. 44.—Diagram of Nerves and Vessels of Hand in relation to Bones and Skin Markings.

rounded elevation, called the *hypothenar eminence*, which is produced by the subjacent short, intrinsic muscles of the little finger. The *thenar eminence*, or ball of the thumb, formed by the short muscles of that digit, is the marked projection which limits the palmar hollow proximally and on the lateral side;

whilst the transverse elevation at the roots of the fingers, which corresponds to the metacarpo-phalangeal articulations, constitutes the distal boundary of the central palmar depression. Two pronounced bony projections on the anterior aspect of the wrist cannot fail to attract attention when the hand is bent dorsally. The more prominent of the two is situated at the proximal extremity of the thenar eminence, and is formed by the tubercle of the navicular bone and the vertical ridge on the volar surface of the os multangulum majus; the other is placed at the proximal end of the hypothenar eminence, and is somewhat obscured by the soft parts attached to it. It is caused by the pisiform bone, and when taken firmly between the finger and thumb a slight degree of gliding movement can be communicated to it. Traversing the thick integument of the palm, three strongly marked furrows are apparent. One begins at the elevation formed by the navicular and os multangulum majus and curves distally and laterally, round the base of the thenar eminence, to the lateral margin of the hand. A second crosses the palm transversely. Commencing at the middle of the lateral border of the hand, where the first furrow ends, it runs medially, but, as a general rule, it fades away upon the hypothenar eminence. The third furrow begins near the cleft between the index and middle fingers, and proceeds medially, with a gentle curve across the hypothenar eminence, to the medial margin of the hand. The transverse cutaneous furrows at the roots of the fingers, and on the palmar aspects of the interphalangeal joints, should also be noticed. The furrows at the roots of the fingers are placed over the palmar aspects of the proximal phalanges, very nearly one inch distal to the metacarpo-phalangeal joints. The proximal of the two furrows palmar to each of the proximal interphalangeal joints is placed immediately over the articulation, whilst in the case of the distal interphalangeal joints the single crease which is usually present is situated immediately proximal to the articulation. On the back of the hand the metacarpal bones can be readily felt, whilst their distal extremities, or heads, form the prominences known as the "knuckles."

**Reflection of Skin.**—In the first instance the skin should be raised only from the palm. Two incisions are required—viz., (1) a vertical incision along the middle line of the palm; (2) a transverse cut across the roots of the fingers from the medial to the lateral margin of the hand. The skin is tightly bound down to the subjacent palmar aponeurosis, and it must be

raised with care. More especially is it necessary to proceed with caution at the roots of the fingers in order that some transverse fibres, constituting a superficial cutaneous ligament, may be preserved. In reflecting the medial flap of integument it is well not to detach it from the subjacent tissues quite as far as the medial border of the hand, because it is into skin of that region that the palmaris brevis muscle is inserted.

**Superficial Structures.**—The *superficial fascia* over the central part of the palm is dense and thin, and the fat is subdivided into small lobules by fibrous septa which bind the skin to the subjacent palmar aponeurosis. Towards the medial and lateral margins of the hand the fat becomes softer, and the amount of fibrous tissue amongst it diminishes. In association with the superficial fascia of the palm, note—(1) the palmaris brevis; (2) the superficial transverse ligament; and (3) the palmar cutaneous nerves.

The *m. palmaris brevis* is a small cutaneous muscle embedded in the superficial fascia which covers the proximal part of the hypothenar eminence. If it has not already been exposed by the reflection of the skin, carry the knife transversely through the granular fat on the ulnar margin of the palm immediately distal to the transverse carpal ligament. The fleshy bundles of the muscle will come into view. When these have been cleaned, the muscle will be seen to consist of a series of distinct fasciculi, which, in its distal part, are frequently separated from each other by intervals of varying width. It constitutes a thin fleshy layer, which covers an inch and a half, or more, of the hypothenar eminence. Laterally it takes origin from the transverse carpal ligament and medial border of the intermediate part of the palmar aponeurosis, whilst medially its fasciculi are inserted into the skin over the medial margin of the hand.

The *volar (palmar) cutaneous nerves* are three in number, and they arise, as already noted, from the ulnar and median nerves and from the superficial branch of the radial nerve. They should now be traced to their ultimate distribution in the palm of the hand.

The *transverse superficial ligament* is a band of fibres which extends across the palm at the roots of the fingers. It is intimately connected with the skin, and is enclosed within the folds of integument in the clefts between the fingers.

*Dissection.*—The palmaris brevis should be reflected by detaching its fasciculi from their origin, and turning them medially. In raising the muscle care must be taken of the ulnar artery and nerve, which lie under

cover of it; and a little filament from the nerve should be traced into its substance. The granular fat should next be removed from the palm, and the dense palmar aponeurosis cleaned. Towards the roots of the fingers the

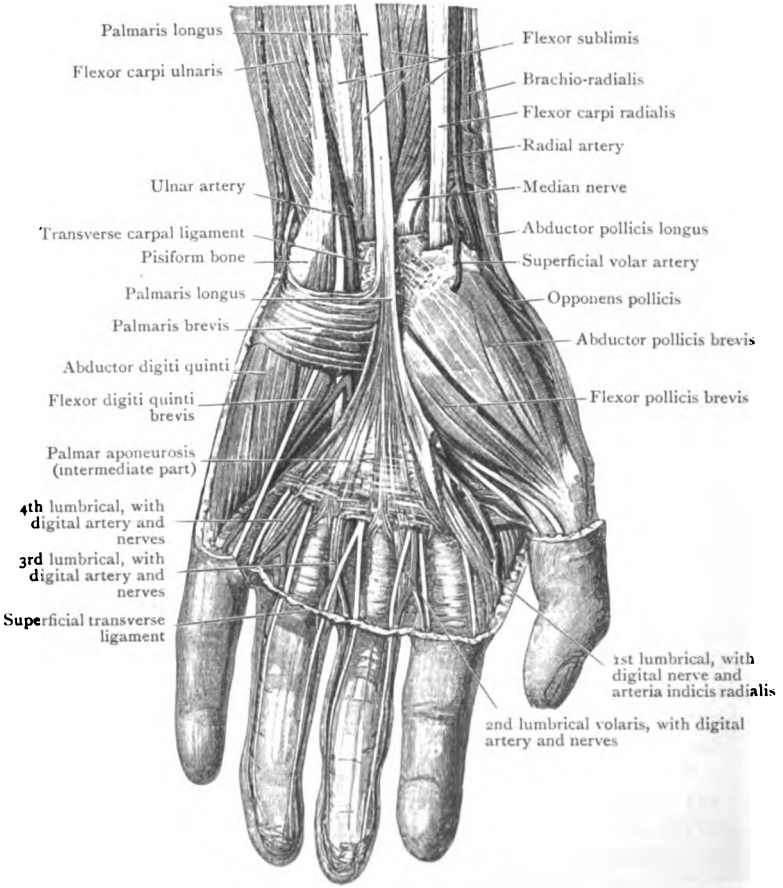


FIG. 45.—Superficial Dissection of the Palm. The intermediate part of the palmar aponeurosis has been left in position, whilst the lateral and medial portions have been removed to display the short muscles of the thumb and little finger.

digital vessels and nerves, together with the lumbrical muscles, appear in the intervals between the slips into which the palmar aponeurosis divides. These should be defined, and it will be seen that they pass distally under cover of the superficial transverse ligament. Having noted this point,

remove the ligament. The digital arteries and nerves for the medial side of the little finger and the lateral side of the index appear beyond the area of the intermediate part of the palmar aponeurosis, more proximal than the others, and are consequently liable to injury, unless the positions they occupy are kept in mind.

**Aponeurosis Palmaris** (O.T. **Palmar Fascia**).—The palmar aponeurosis is composed of three portions—an intermediate, a medial, and a lateral. The *lateral and medial* are thin and weak. They are spread over the muscles which constitute the thenar and hypothenar eminences, on the lateral and medial margins of the palm. The *intermediate portion* of the palmar aponeurosis, on the other hand, is exceedingly strong and dense, and it is spread out over the middle of the palm. It counteracts the effect of pressure in that region, and effectually protects the vessels, nerves, and tendons over which it is stretched. Its strength differs considerably in different hands, and it is seen to best advantage in the horny hand of a labourer, or of a mechanic who has been in the habit of handling heavy implements. In shape it is triangular. Proximally, it is narrow and pointed, and, at the wrist, it is attached to the transverse carpal ligament, and receives the insertion of the flattened tendon of the palmaris longus. As it approaches the heads of the metacarpal bones it expands, and finally divides into four slips, which separate slightly from each other and pass to the roots of the medial four digits. It gives no slip to the thumb. For the most part it is composed of longitudinal fibres, but, where it divides, a series of strong and very evident *transverse fibres* pass across it, in relation to its deep surface, and bind together its diverging slips.

In the three intervals between the digital slips of the palmar aponeurosis, the digital arteries and nerves, together with the corresponding lumbrical muscles, make their appearance.

The connections of the four digital slips of the palmar aponeurosis must be closely examined. Each slip lies anterior to the two flexor tendons proceeding to the finger with which it is connected, and it divides into two portions, which separate so as to form an arch under which the tendons pass. The arch is connected with the flexor sheaths, which binds the tendons to the front of the finger, and the two portions which form it are carried dorsally, to obtain attachment to the transverse ligament of the heads of the metacarpal

bones, which stretches transversely across the volar aspects of the metacarpo-phalangeal joints. These relations can be satisfactorily made out only by dividing the arch and slitting the slip of fascia in a proximal direction.

**Fascial Compartments of the Palm.**—Two weak septa proceed into the palm from the margins of the strong intermediate portion of the palmar aponeurosis. They join a layer of fascia, which is spread out over the interosseous muscles and the deep volar arch, and thus three fascial compartments are formed in the palm, viz., an *intermediate*, containing the flexor tendons, the lumbrical muscles, the superficial volar arch, and the terminal branches of the median nerve; a *medial*, enclosing the short muscles of the little finger; and a *lateral*, enclosing the short muscles of the thumb.

*Dissection.*—Raise the intermediate part of the palmar aponeurosis. Divide its narrow proximal part, throw it distally, and finally remove it completely. The *superficial volar arch* is the most superficial of the structures now exposed. Trace the ulnar artery into it, and follow the digital branches which it gives off. The volar carpal ligament, which binds the ulnar artery to the front of the transverse carpal ligament, may now be removed. The median and ulnar nerves also must be dissected. The muscular branches, which the median gives to the muscles of the thenar eminence, are especially liable to injury. They come off in a short, stout stem, almost in a line with the distal margin of the transverse carpal ligament, and at once turn laterally to reach the short muscles of the thumb, to some of which they are distributed. The nerve twigs to the lateral two lumbricals must also be looked for. They spring from the digital branches of the median which go to the lateral side of the index and to the cleft between the index and middle fingers.

In order that the digital vessels and nerves may be traced to their distribution, the skin must be reflected from the fingers. This can be done by making an incision along the middle of each digit, and turning the integument laterally and medially. As the skin is raised from the borders of the different digits the *cutaneous ligaments of the phalanges* (Cleland) will come into view. These are fibrous bands, which spring from the edges of the phalanges dorsal to the digital vessels and nerves. They are inserted into the skin so as to form a strong fibrous septum on each side of each finger. They retain the integument in proper position during the different movements of the digits.

**Arcus Volaris Superficialis** (O.T. **Superficial Palmar Arch**).—The ulnar artery, when traced into the palm, is found to form the superficial volar arch—an arterial arcade, which lies immediately subjacent to the palmar aponeurosis.

The *ulnar artery* enters the palm by passing superficial to the transverse carpal ligament, close to the lateral side of the pisiform bone. A short distance more distally it curves laterally across the palm, and, near the middle of the thenar emin-

ence, it is joined by the superficial volar branch of the radial, or, more frequently, by a twig from the art. volaris indicis radialis or art. princeps pollicis. The convexity of the arch is directed distally, towards the fingers, and its most

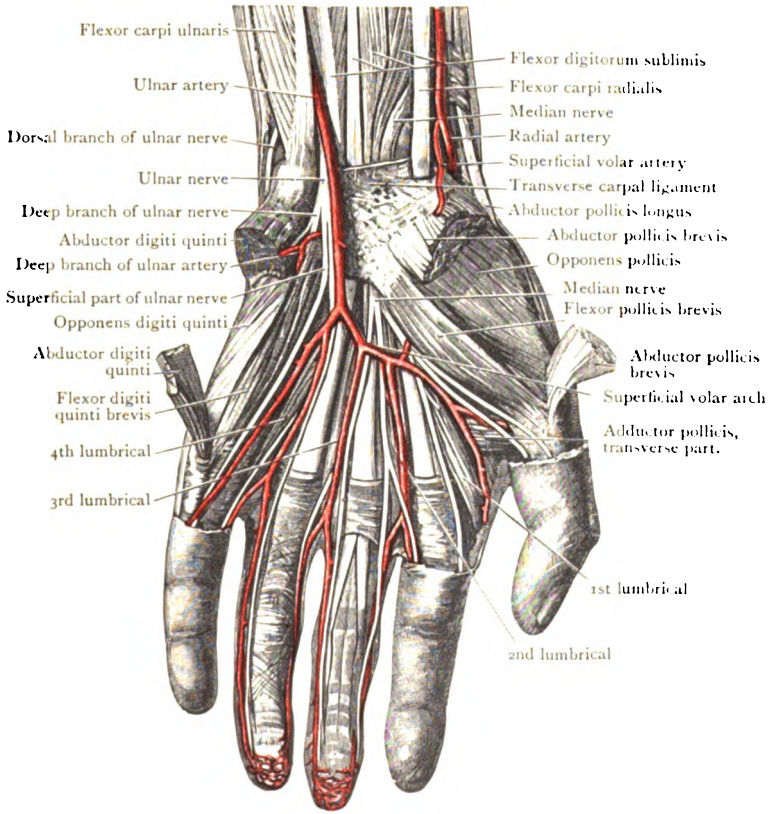


FIG. 46.—The parts in the Palm which are displayed by the removal of the Palmar Aponeurosis. In the specimen from which the drawing was taken the arteria volaris indicis radialis and the arteria princeps pollicis took origin from the superficial volar arch.

distal point corresponds with a line drawn across the palm in line with the distal border of the outstretched thumb.

Throughout its entire extent the superficial volar arch lies very near the surface. Its medial part is covered by the

palmaris brevis muscle; beyond this it is placed immediately under cover of the intermediate part of the palmar aponeurosis. As it is followed from the medial to the lateral side of the hand it will be seen to cross—(*a*) the transverse carpal ligament; (*b*) the short muscles of the little finger; (*c*) the flexor tendons, and the digital branches of the median nerve.

**Branches of the Superficial Volar Arch.**—Small branches proceed from the superficial volar arch for the supply of the integument and adjoining short muscles of the palm. As the ulnar artery leaves superficial the surface of the transverse carpal ligament it gives off its *deep branch*; whilst from the convexity of the arch proceed four *common volar digital branches.*

The *deep volar branch* is a small vessel, which at once disappears from view by passing dorsally in the interval between the abductor digiti quinti and the flexor digiti quinti brevis. It will be traced to its termination in the deep dissection of the palm.

The *four common volar digital arteries* supply both sides of the medial three digits and the medial side of the index finger. The *first common volar digital artery* runs distally upon the short muscles of the little finger, to which it gives twigs, and then it is carried along the medial side of the digit. The *second common volar digital artery* proceeds towards the interval between the roots of the little and ring fingers, and divides into two branches (*collateral* or *proper volar digital arteries*), which run along the contiguous sides of these digits. The *third common volar digital artery* supplies, in like manner, the adjacent sides of the ring and middle fingers; whilst the *fourth common volar digital artery* is distributed similarly to the contiguous margins of the middle and index fingers.

There are certain points in connection with these volar digital arteries, during their course in the palm and along the sides of the fingers, which must be noted. In the *palm* the undivided trunks lie in the intervals between the flexor tendons and volar to the digital nerves and the lumbrical muscles. Along the sides of the *fingers* they show a different relation to the nerves: the nerves are now on the volar side and the arteries lie dorsal to them. Upon the terminal phalanx the two collateral branches join to form an arch, from which proceed great numbers of fine twigs, to supply the pulp of the finger, and the bed upon which the nail rests.

Each common volar digital artery, at the point at which it divides, is joined by the corresponding volar metacarpal artery from the deep volar arch. The proper volar digital arteries give a liberal supply of twigs to the integument, the sheaths of the tendons, and the joints of the fingers.

**Nervus Medianus.**—The median nerve enters the palm by passing *deep* to the transverse carpal ligament, with the flexor tendons. In that part of its course it is overlapped by the mucous sheath which is wrapped round the tendons. Further, before it emerges it assumes a flattened form, and divides into two portions. Of these, the *lateral division* is slightly the smaller of the two, and gives off—(1) a stout short branch to some of the intrinsic muscles of the thumb; (2) three digital branches, which go to the two sides of the thumb and the lateral side of the index finger.

The *muscular branch* takes origin at the distal border of the transverse carpal ligament, and at once turns laterally to supply the abductor pollicis brevis, the superficial head of the flexor pollicis brevis, and the opponens pollicis.

The *proper volar digital nerves* which run along the medial side of the thumb, and the lateral side of the index, give several branches to the fold of integument which stretches between the roots of those digits; whilst the proper volar digital branch to the lateral border of the index gives a minute twig to the first or most lateral lumbrical muscle.

The larger *medial division* of the median nerve divides into two branches. Of these one runs towards the cleft between the index and middle fingers, and splits into the proper volar digital nerves for the adjacent sides of those digits; it gives a twig to the second lumbrical muscle also. The second common volar digital branch of the medial division of the median nerve proceeds towards the cleft between the middle and ring fingers, and divides into the proper volar digital branches for their contiguous margins. In some instances, but not invariably, it supplies a twig to the third lumbrical muscle.

In the palm the digital branches of the median nerve proceed distally deep to the superficial volar arch, but as they approach the fingers they become superficial to the common volar digital arteries, which in many cases may be observed to pass through, or perforate, the nerves. As the proper volar digital nerves lie upon the sides of the fingers, numerous

branches are given to the integument; and if the dissector exercises sufficient patience and care in the dissection, he will notice, attached to the nerve twigs, numerous minute, oval, seed-like bodies. These are the *Pacinian corpuscles.* At the extremity of the fingers each of the proper volar digital nerves divides into two terminal branches. Of these, one ramifies in the pulp, whilst the other inclines dorsally to reach the bed upon which the nail rests. Several twigs pass to the dorsal aspects of the fingers, and these are chiefly responsible for the supply of the integument on the dorsal aspects of the second and third phalanges.

**Nervus Ulnaris.**—The palmar continuation of the ulnar nerve enters the palm by passing *superficial to* the transverse carpal ligament. As it lies secure from the effects of pressure, under the shelter of the pisiform bone and upon the medial side of the ulnar artery, it divides into two terminal branches —a superficial and a deep.

The *deep branch* is continued distally, upon the transverse carpal ligament, and associates itself with the deep branch of the ulnar artery. It leaves the present dissection by passing dorsally between the abductor and the flexor brevis muscles of the little finger.

The *superficial branch* runs distally, under cover of the palmaris brevis to which it gives a branch of supply; then it divides into two common volar digital branches. One of these proceeds obliquely, over the short muscles of the little finger to gain the medial side of that digit; the other runs distally to the cleft between the little and ring fingers, and divides into the proper volar digital branches for the adjacent sides of those digits. A branch of communication passes from the second common volar digital branch of the ulnar nerve to the adjoining common volar digital branch of the median nerve.

The proper volar digital branches of the ulnar nerve are distributed on the sides of the fingers in precisely the same manner as those derived from the median nerve.

**Lig. Carpi Transversum** (O.T. **Anterior Annular Ligament**).—The transverse carpal ligament is a thick, dense, fibrous band, which stretches across the volar aspect of the concavity of the carpus, and converts it into an osteo-fibrous tunnel for the passage of the flexor tendons into the palm. On each side it is attached to the piers of the carpal arch, viz., on the *lateral side* to the tubercle

of the navicular bone and the ridge of the greater multangular bone, and on the *medial side* to the pisiform bone and the hook of the os hamatum. Its proximal margin is continuous with the deep fascia of the forearm, of which it may be considered to be a thickened part; whilst distally, it is connected with the palmar aponeurosis.

Upon the volar surface of the transverse carpal ligament the expanded tendon of the palmaris longus is prolonged distally to the intermediate part of the palmar aponeurosis, whilst on

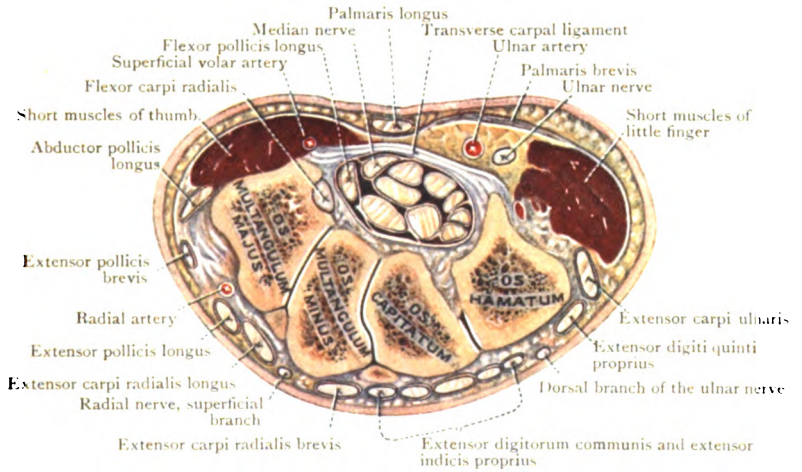


FIG. 47.—Transverse section through the Wrist at the level of the Distal Row of Carpal Bones to show the Carpal Tunnel. The Tendons of the Flexor Digitorum Sublimis, Flexor Digitorum Profundus, and Flexor Pollicis Longus are seen within the Tunnel.

each side some of the short muscles of the thumb and little finger take origin from it. Close to its medial attachment the ulnar artery and nerve find their way into the palm by passing superficial to it and deep to a more superficial fascial band, the *volar carpal ligament*, which is attached on the medial side to the pisiform and the hook of the os hamatum, and on the lateral side to the tubercle of the navicular and the ridge of the greater multangular bone.

The tunnel which the transverse carpal ligament forms with the volar concavity of the carpus is transversely oval in shape, and it opens distally into the intermediate compartment of the palm. Through it pass the tendons of the flexor

digitorum sublimis, the flexor digitorum profundus, the tendon of the flexor pollicis longus, and the median nerve. The relation of the tendon of the flexor carpi radialis to the transverse carpal ligament is peculiar. It pierces the lateral attachment of the ligament, and proceeds distally in the groove of the os multangulum majus, in a special compartment provided with a special mucous sheath.

**Mucous Sheaths of the Flexor Tendons.**—As the flexor tendons and the median nerve pass through the carpal tunnel they are enveloped in two mucous sheaths, which, at the same time, line the walls of the canal, and thus greatly facilitate the

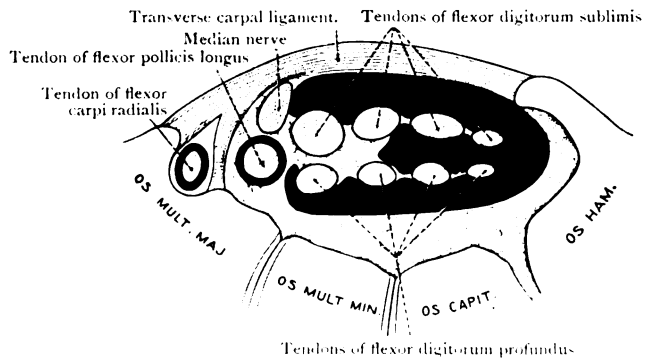


FIG. 48.—Diagram illustrating the relation of the Synovial Sheaths to the Flexor Tendons at the level of the transverse carpal ligament.

free play of the tendons between the transverse carpal ligament and the carpus. As already stated, these sheaths are two in number. One is wrapped around the tendon of the flexor pollicis longus, the other invests the tendons of the flexor digitorum profundus and flexor digitorum sublimis. Both are prolonged proximally into the forearm for an inch or more, and both are carried distally into the palm in the form of diverticula upon the diverging tendons. The diverticula in relation to the tendons which go to the index, middle, and ring fingers, end near the middle of the palm. Those upon the tendons of the thumb and little finger, however, are prolonged distally into the digits, and line the fibrous sheaths which confine the tendons upon the volar aspects of the phalanges.

It is not likely that these mucous sheaths have been preserved intact throughout the previous dissection of the forearm and palm; but should they

turn out to be uninjured, a very striking demonstration may be obtained by inflating them with air by means of the blowpipe. The apertures through which the air is introduced should be made at the proximal margin of the transverse carpal ligament.

It is said that the mucous sheath which invests the tendons of the flexor digitorum sublimis and flexor digitorum profundus is divided by a vertical partition into two compartments, and that the lateral of these communicates, by means of a small aperture near the proximal border of the transverse carpal ligament, with the mucous sheath of the tendon of the flexor pollicis longus.

**Flexor Tendons.**—Open the carpal tunnel by making a vertical incision through the transverse carpal ligament at its middle. The arrangement of the flexor tendons can now be studied, and the mucous sheath dissected from the surface of each. The tendon of the *flexor pollicis longus* occupies the lateral part of the canal, and, gaining the palm, turns laterally to reach the phalanges of the thumb. The four tendons of the *flexor sublimis* are arranged in pairs deep to the transverse carpal ligament; those for the little and the index fingers lying dorsal to those for the ring and middle fingers. Of the tendons of the *flexor profundus*, only that for the index finger is distinct and separate; the other three, as a rule, remain united until they emerge from under cover of the distal border of the transverse carpal ligament.

In the central compartment of the palm the flexor tendons diverge from each other, and two, viz., one from the flexor sublimis, and one from the flexor profundus, go to each of the four fingers. From the tendons of the flexor profundus the lumbrical muscles take origin, and these, with the common volar digital nerves and arteries, will be seen occupying the intervals between the tendons as they approach the roots of the fingers.

In the *fingers* the two flexor tendons run distally, upon the volar aspects of the phalanges, and are held in position by the flexor sheaths. The latter, therefore, must be studied before the insertions of the tendons can be examined.

**Flexor Sheaths.** — Immediately subjacent to the skin, the superficial fascia and the proper volar digital arteries and nerves, lie the fibrous sheaths which bind the flexor tendons to the volar surfaces of the phalanges, and to the volar accessory ligaments of the metacarpo-phalangeal and inter-

phalangeal joints. Each fibrous sheath consists of a number of parts of which the two strongest, the *digital vaginal ligaments*, lie opposite the bodies of, and are attached to the margins of, the first and second phalanges. Such strong bands placed opposite the metacarpo-phalangeal and interphalangeal joints would seriously interfere with their movements; therefore, in those regions, weaker transverse bands, the *annular ligaments*, are formed. In addition, cruciate bands—the *cruciate ligaments*—are often found intervening between the annular ligaments and the stronger portions of the sheaths. The fibrous sheath, together with the phalanges and the volar accessory ligaments of the metacarpo-phalangeal and interphalangeal joints, forms, in each finger, an osteo-fibrous canal, in which are enclosed the tendons of the flexor digitorum sublimis and of the flexor digitorum profundus together with their surrounding mucous sheath.

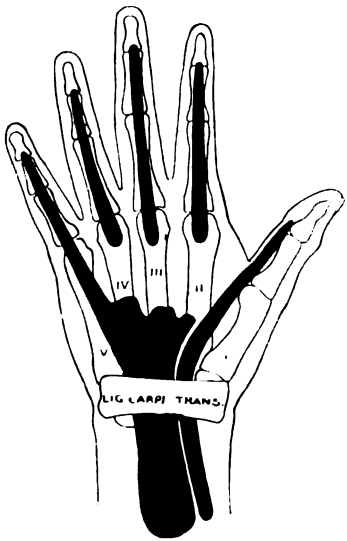


FIG. 49.—Diagram to illustrate the arrangement of the Mucous or Synovial Sheaths of the Flexor Tendons.

The fibrous sheaths of one or more of the fingers may now be opened. They will be seen to be lined with a mucous sheath which is reflected over the enclosed tendons so as to give each a separate investment. The mucous sheath of the little finger has been seen to be a direct prolongation from the common mucous sheath of the flexor tendons; the other three are distinct from that, and are carried proximally into the palm. They envelop the tendons of the ring, index, and middle fingers, as far as a line drawn across the palm immediately proximal to the heads of the metacarpal bones.

If the flexor tendons are raised from the phalanges, certain mucous folds will be noticed connecting them to the bones. These are termed the *vincula tendinum*. Two kinds of

them are distinguished, viz., vincula brevia and longa. In the accompanying illustration (Fig. 50) the connections of these may be seen. The *vincula brevia* are triangular folds, which connect the tendons, near their insertions, to the volar aspect of the adjacent phalanx. The *vincula longa* are not invariably present. They are placed more proximally, and are narrow, weak strands which pass between the tendons and the bones.

**Insertions of the Flexor Tendons.**—The insertions of the two flexor tendons can now be studied. On the volar side of the first phalanx the tendon of the flexor sublimis becomes flattened and folded round the subjacent cylindrical tendon of the flexor profundus. It then splits into two parts, which pass dorsal to the tendon of the flexor profundus, and allow

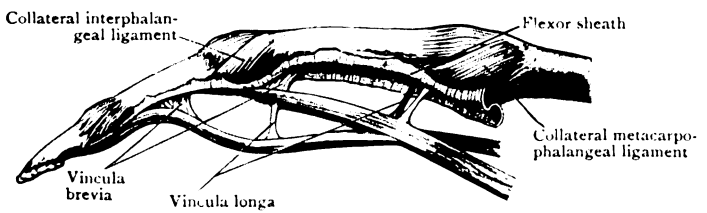


FIG. 50.—Flexor Tendons of the Finger with Vincula tendinum.

the latter to proceed onwards between them. Dorsal to the deep tendon the two portions of the tendon of the flexor sublimis become united by their margins, and then they diverge, to be inserted into the borders of the body of the second phalanx.[1] By this arrangement the flattened tendon of the flexor sublimis forms a ring, or short tubular passage, through which the tendon of the flexor profundus proceeds onwards to the base of the ungual phalanx, into which it is inserted. In each of the four fingers the same arrangement is found; the tendon of the flexor sublimis is inserted by two slips into the margins of the volar surface of the second phalanx, whilst the tendon of the flexor profundus is inserted into the volar aspect of the base of the terminal phalanx.

[1] Where the margins of the two slips of the tendon of the flexor sublimis are united behind the tendon of the flexor profundus, a decussation of fibres takes place between the two slips.

**Tendon of the Flexor Pollicis Longus.**—This tendon proceeds distally, in the interval between two of the short muscles of the thumb (viz., the superficial head of the flexor pollicis brevis, and the oblique part of the adductor pollicis), and also in the interval between the two sesamoid bones which play upon the head of the metacarpal bone. Reaching the proximal phalanx, it enters a fibrous flexor sheath constructed upon a similar plan to those of the fingers. When that is opened, it will be noted that the tendon inserted into the volar aspect of the base of the terminal phalanx of the thumb. The mucous sheath which surrounds the tendon during its passage through the carpal tunnel is continuous with the sheath which invests the tendon in front of the phalanges.

*Dissection.*—Throw distally the superficial volar arch. Divide it on the medial side distal to the origin of the deep branch of the ulnar artery and on the lateral side at the point where it is joined by the superficial volar artery. The median nerve also may be severed and its branches turned aside, but care should be taken to preserve the two branches given to the lumbrical muscles, and also the stout branch which enters the muscles of the thenar eminence. Lastly, cut through the fleshy belly of the flexor digitorum sublimis in the forearm, and, raising its tendons from the carpal hollow, throw them as far distally as possible. The tendons of the flexor digitorum profundus and the attached lumbrical muscles are now fully displayed.

**Mm. Lumbricales.**—The lumbrical muscles are four slender fleshy bellies which arise from the tendons of the flexor digitorum profundus as they traverse the palm. The *first lumbrical* arises from the lateral side of the tendon for the index finger; the *second lumbrical* springs from the lateral border of the tendon for the middle finger; whilst the *third* and *fourth lumbricals* take origin from the adjacent sides of the tendons between which they lie (viz., the tendons for the middle, ring, and little fingers). The little muscles pass distally, and end in delicate tendons on the lateral sides of the fingers. Each tendon is inserted into the lateral margin of the expansion of the extensor tendon, which lies upon the dorsal aspect of the proximal phalanx.

*Dissection.*—The flexor digitorum profundus may be divided in the forearm and thrown distally. Great care must be taken in raising the tendons and lumbrical muscles from the palm, because slender twigs from the deep branch of the ulnar nerve enter the medial two lumbrical muscles on their dorsal aspects. These can easily be secured if ordinary caution is observed. The deep volar arch and the deep branch of the palmar part of the ulnar nerve are now exposed, and a favourable opportunity is given for studying the short muscles of the thumb and little finger.

**Short Muscles of the Thumb.**—The *abductor pollicis brevis* forms the most prominent and lateral part of the ball of the thumb. The *superficial head* of the *flexor pollicis brevis* lies immediately to the medial side of the abductor; and by separating the one from the other, the dissector will expose *opponens pollicis*. These three muscles lie to the lateral side of the tendon of the flexor pollicis longus. To the medial side of that tendon, and placed deeply in the palm, is a fan-shaped muscular sheet, the *adductor pollicis*, imperfectly separated into a proximal and a distal part by the radial artery as it enters the palm. The proximal is the oblique part, and the distal is the transverse part of the muscle.

In dissecting these muscles the muscular branch of the median nerve must be traced to those which lie upon the lateral side of the long flexor tendon of the thumb, and the deep branch of the ulnar must be followed, and its branches to the adductor of the thumb secured.

The *abductor pollicis brevis* arises from the volar aspect of the transverse carpal ligament and the os multangulum majus. It is inserted into the lateral side of the base of the proximal phalanx of the thumb, and slightly into the extensor tendon on the dorsum of the proximal phalanx. Its nerve of supply comes from the *median nerve*.

The *superficial head of the flexor pollicis brevis*[1] takes origin from the transverse carpal ligament, and is inserted into the lateral side of the base of the proximal phalanx of the thumb. It is supplied by the *median nerve*.

The *opponens pollicis* springs from the transverse carpal ligament and the ridge on the front of the os multangulum majus. Its fibres spread out, and are inserted into the entire length of the lateral border and the adjacent part of the volar surface of the metacarpal bone of the thumb. Its nerve of supply is derived from the *median nerve*.

The *adductor pollicis* consists of two parts, an *oblique part* and a *transverse part*. The oblique part arises from the os multangulum minus, the os capitatum, and the bases of the second and third metacarpal bones. The transverse part springs from the distal two-thirds of the volar border of the third metacarpal bone. The two parts converge laterally, along the medial side of the tendon of the

[1] The term *superficial head*, applied to this muscle, suggests the presence of a *deep head*. Such a head is present. It is the *interosseus primus volaris* of Henle (*v.* p. 147).

flexor pollicis longus, and they are inserted together into the medial side of the base of the proximal phalanx of the thumb. A strong slip will generally be seen to deviate laterally from the lateral border of the muscle; it passes dorsal to the long flexor tendon, and joins the superficial head of the flexor pollicis brevis. Both parts of the adductor pollicis are supplied by the *deep branch* of the *ulnar nerve.*

Two sesamoid bones are developed in connection with

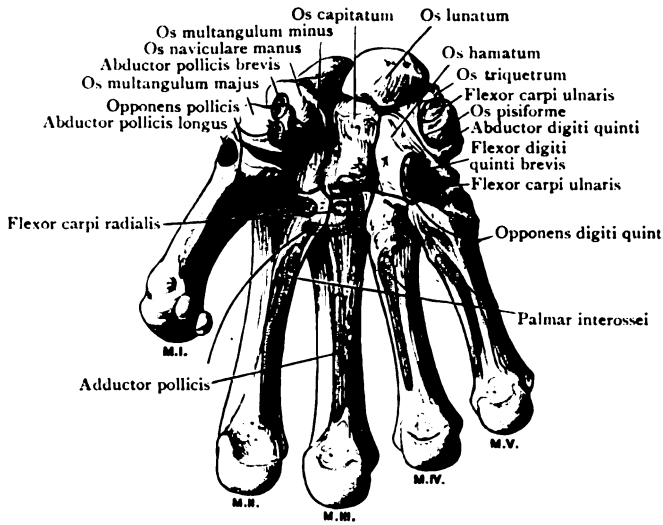


FIG. 51.—Volar aspect of the Bones of the Carpus and Metacarpus with Muscular Attachments mapped out.

the tendons of the short muscles of the thumb, one on each side of the base of the proximal phalanx.

**Short Muscles of the Little Finger.**—The *abductor digiti quinti* (O.T. *minimi digiti*) lies on the medial and volar aspect of the hypothenar eminence, and the *flexor digiti quinti brevis* (O.T. *minimi digiti*) lies upon its lateral side. When these are separated from each other, the *opponens digiti quinti* (O.T. *minimi digiti*) is seen on a deeper plane, and in the interval between them.

The *abductor digiti quinti* arises from the pisiform bone,

and is inserted into the medial side of the base of the proximal phalanx of the little finger. It is supplied by the *deep branch* of the *ulnar nerve.*

The *flexor digiti quinti brevis* is composed of a single fleshy belly which springs from the hook of the os hamatum and the transverse carpal ligament, and is inserted into the medial side of the proximal phalanx of the little finger, in common with the abductor. This muscle is sometimes much reduced in size, and frequently more or less completely incorporated with the opponens. Its nerve supply comes from the *deep branch* of the *ulnar nerve.*

The *opponens digiti quinti* arises from the transverse carpal ligament, and the hook of the os hamatum, and its fibres spread out to obtain insertion into the entire length of the medial margin of the metacarpal bone of the little finger. The *deep branch* of the *ulnar* nerve gives it its nerve of supply.

**Ramus Profundus Nervi Ulnaris.**—The deep branch of the ulnar nerve springs from the parent trunk on the volar aspect of the transverse carpal ligament, and gives off a branch which supplies the three short muscles of the little finger. Accompanied by the deep branch of the ulnar artery, it sinks into the interval between the abductor and flexor digiti quinti brevis, and turns laterally across the palm, deep to the flexor tendons. Near the lateral border of the palm the deep branch of the ulnar nerve breaks up into terminal twigs which supply the adductor pollicis, and the first dorsal interosseous muscle. In its course across the palm it lies along the concavity or proximal border of the deep volar arch, and sends three fine branches distally in front of the three interosseous spaces. They supply the interosseous muscles in the spaces, while the medial two give branches also to the dorsal surfaces of the medial two lumbrical muscles. The third lumbrical has frequently a double nerve supply, a branch from the deep part of the ulnar nerve, and, not uncommonly, a second twig from the median nerve enters its volar aspect.

The deep branch of the ulnar nerve may, therefore, be said to supply all the muscles of the palm which lie to the medial side of the tendon of the flexor pollicis longus, whilst the median supplies the three muscles which lie to the lateral side of that tendon. There are two exceptions to this generalisation, viz., the lateral two lumbrical muscles, which lie upon the medial

side of the tendon, and are yet supplied by the median nerve.

**Arcus Volaris Profundus** (O.T. **Deep Palmar Arch**).—The artery which takes the chief part in the formation of the deep volar arch is the radial. That vessel enters the palm by passing to the volar surface through the proximal part of the first interosseous space, between the two heads of the first dorsal interosseous muscle. In the present state of the dissection it makes its appearance between the contiguous margins of the oblique and transverse portions of the adductor pollicis. It runs medially upon the interossei muscles and the metacarpal bones, immediately distal to their bases. As it approaches the fifth metacarpal bone it is joined by the deep branch of the ulnar artery, and in this manner the deep volar arch is completed.

The deep volar arch does not show so strong a curve as the superficial volar arch, and it is placed at a more proximal level in the palm. It is closely accompanied by the deep branch of the ulnar nerve; and is separated from the superficial volar arch by the group of flexor tendons and their sheaths, the lumbrical muscles, the branches of the median nerve, which occupy the intermediate compartment of the palm, and also, at its medial end, by the short flexor of the fifth digit, dorsal to which the deep branch of the ulnar artery passes to join the radial artery.

The *branches* which spring from the deep volar arch are: (1) the *recurrent*—a few small twigs which run proximally, in front of the carpus, to anastomose with branches of the volar carpal arch; (2) *perforating branches*, which pass dorsally in the proximal parts of the interosseous spaces to anastomose with the dorsal metacarpal arteries; and (3) the *volar metacarpal branches*—three in number—which pass distally, volar to the interosseous spaces, and unite, near the roots of the fingers, with the corresponding common volar digital arteries from the superficial volar arch. Sometimes the volar metacarpal branches are large and take the place of the corresponding common volar digital arteries.

*Dissection.*—To bring the volar radial artery of the index and the princeps pollicis artery into view, the parts of the adductor pollicis must be detached from their origins and turned laterally. The radial artery will then be seen passing volarwards between the two heads of the first dorsal interosseous muscle.

**Arteria Volaris Indicis Radialis, and Arteria Pollicis (O.T. Radialis Indicis and Princeps Pollicis Ar**—These arteries spring from the radial, as it proceeds to the volar surface, between the first and second metacarpal bones.

The *volar radial artery of the index digit* runs distally between the transverse part of the adductor pollicis and the first dorsal interosseous muscle to the lateral border of the index, along which it proceeds as its lateral proper volar digital artery.

The *princeps pollicis artery* takes a course distally and laterally, under cover of the oblique part of the adductor pollicis, and gains the volar aspect of the metacarpal bone of the thumb. There it lies dorsal to the tendon of the flexor pollicis longus, and divides into the proper volar digital arteries of the thumb. These branches make their appearance in the interval between the adductor and the superficial head of the flexor pollicis brevis, and are carried distally, one on each side of the tendon of the long flexor.

**Surgical Anatomy of the Palm and Fingers.**—When an abscess forms in the intermediate compartment of the palm early surgical interference is urgently called for. The dense palmar aponeurosis effectually prevents the passage of the pus to the surface of the palm, whilst an easy route proximally, into the forearm, is offered to it by the open carpal tunnel, through which the flexor tendons enter the palm. It is necessary, therefore, that before this can occur the surgeon should make an opening in the palm by means of which the pus can escape.

In making such an incision it is important to bear in mind the position of the various vessels which occupy the intermediate compartment of the palm. As previously stated, the level of the superficial volar arch can be indicated by drawing a line transversely across the palm from the distal margin of the outstretched thumb. The deep volar arch lies half an inch more proximally. The common volar digital arteries, which spring from the convexity of the superficial volar arch, run in line with the clefts between the fingers. An incision, therefore, which is made distal to the superficial volar arch and in a direction corresponding to the central line of one of the fingers, may be considered free from danger in so far as the vessels are concerned.

The loose mucous sheath which envelops the flexor tendons as they pass deep to the transverse carpal ligament has been seen to extend proximally into the distal part of the forearm, and distally into the palm. When the sheath is attacked by inflammatory action it is apt to become distended with fluid (thecal ganglion), and the anatomical arrangement of the parts at once offers an explanation of the appearance which is presented. There is a bulging in the palm, and a bulging in the distal part of the forearm, but no swelling at all at the wrist. There the dense transverse carpal ligament resists the expansion of the mucous sheath, and an hour-glass constriction is evident at that level.

The fingers are subject to an inflammatory process, termed *whitlow*, and, in connection with this, it is essential to remember that the flexor fibrous sheath ends on the base of the distal phalanx in each digit.

When the whitlow occurs more distally, in the pulp of the finger, the vitality of the distal part of the ungual phalanx is endangered, but the flexor tendons may be regarded as being tolerably safe. When the inflammation occurs more proximally, and involves the flexor sheath, as it generally does, sloughing of the tendons is to be apprehended, unless an immediate opening is made. No slight superficial incision will suffice. The knife must be carried deep into the centre of the finger, so as to freely lay open the sheath containing the tendons. Early interference in cases of whitlow of the thumb and little finger is even more urgently required than in the case of the other three digits, because the digital mucous sheaths of the former are, as a rule, offshoots from the great common mucous sheath of the flexor tendons, and offer a ready means for the proximal extension of the inflammatory action.

Every amputation of the fingers proximal to the insertion of the tendons of the flexor profundus involves the opening of the flexor sheaths, and no doubt, explains the occasional occurrence of palmar trouble after operations of that kind. The open tubes offer a ready passage by means of which septic material may travel proximally into the palm, and, in the case of the thumb and little finger, into the carpal tunnel and distal part of the forearm.

## Dorsum and Lateral Border of the Forearm.

The cutaneous nerves and vessels in this region have already been studied (p. 65). The parts which still require to be examined are:—

1. The deep fascia.
2. The supinator and extensor muscles.
3. The dorsal interosseous artery.
4. The perforating or terminal branch of the volar interosseous artery.
5. The dorsal interosseous nerve.

**Deep Fascia.**—The deep fascia on the dorsal aspect of the forearm is stronger than that which clothes its volar surface. At the elbow it is firmly attached to the epicondyles of the humerus and the olecranon, and it receives a reinforcement of fibres from the tendon of the triceps muscle. There also it affords origin to the extensor muscles, and sends strong septa between them. At the wrist a thickened band—the *dorsal carpal ligament*—is developed in connection with it. It can readily be distinguished from the thinner portions of the fascia, with which it is continuous proximally and distally, and it will be observed to stretch obliquely, medially and distally, from the styloid process of the radius across the wrist to the medial side of the carpus.

*Dissection.*—The deep fascia should now be removed, but that portion of it near the elbow, which gives origin to the subjacent muscles, should be left in place. The dorsal carpal ligament also should be artificially separated and retained *in situ*.

**Superficial Muscles.**—The muscles in this region consist of a superficial and a deep group. The *superficial muscles*, proceeding from the lateral to the medial border of the forearm, are:—(1) the brachio-radialis; (2) the extensor carpi radialis longus; (3) the extensor carpi radialis brevis; (4) the extensor digitorum communis; (5) the extensor digiti quinti proprius; (6) the extensor carpi ulnaris; and (7) the anconæus. This group therefore comprises one flexor of the elbow, three extensors of the wrist, two extensors of the fingers, and a feeble extensor of the forearm at the elbow-joint, viz., the anconæus. In the distal part of the forearm the extensor digitorum communis is separated from the extensor carpi radialis brevis by a narrow interval, in which appear two muscles belonging to the deep group. These turn round the lateral margin of the forearm, upon the surface of the radial extensors of the wrist, and end in tendons which go to the thumb. The proximal muscle is the abductor pollicis longus, and the distal muscle is the extensor pollicis brevis. They are placed in close contact, and so intimately are their tendons connected that in many cases they appear, at first sight, to be blended together by their margins.

Four of the superficial muscles arise by a common origin from the anterior part of the lateral epicondyle of the humerus, and at the same time derive fibres from the investing fascia and the septa it sends in between them. These are the extensor carpi radialis brevis, the extensor digitorum communis, the extensor digiti quinti proprius, and the extensor carpi ulnaris. The superficial muscles should be cleaned, and isolated as far as possible from each other.

**M. Brachio-radialis** (O.T. **Supinator Longus**).—This muscle lies more on the volar than on the dorsal surface of the forearm. It takes origin, in the arm, from the proximal two-thirds of the lateral epicondylar ridge of the humerus and from the lateral intermuscular septum. Near the middle of the forearm a flat tendon emerges from its fleshy belly, and proceeds distally to gain insertion into the lateral aspect of the expanded distal extremity of the radius, at the base of the styloid process. The nerve of supply to this muscle is a branch of the *radial nerve* (O.T. *musculo-spiral*).

**M. Extensor Carpi Radialis Longus.**—The long radial extensor of the carpus is placed dorsal to the brachio-radialis.

It arises from the distal third of the lateral epicondylic ridge of the humerus, and from the lateral intermuscular septum. From the fleshy portion of the muscle a long tendon proceeds, which, under cover of the dorsal carpal ligament, is inserted into the dorsal aspect of the base of the metacarpal bone of the index finger. This muscle is supplied by a branch of the *radial nerve* (C.T. *musculo-spiral*).

**M. Extensor Carpi Radialis Brevis.**—The extensor carpi




Fig. [illegible] Dorsal aspect of the Bones of the Carpus and Metacarpus, [illegible] ligament stripped off.

radialis brevis is closely associated with the preceding muscle. It arises by the common extensor tendon, from the lateral epicondyle of the humerus; it derives fibres also from the radial collateral ligament of the elbow-joint, from the investing deep fascia, and the fibrous septa in connection with it. The tendon of the muscle accompanies that of the long radial extensor under cover of the dorsal carpal ligament, and is inserted into the dorsal aspect of the base of the third metacarpal bone, immediately beyond the root of its styloid process. This muscle is supplied by the *deep branch of the radial nerve*.

**M. Extensor Digitorum Communis.**—The extensor digitorum communis takes origin, by the common tendon, from the lateral epicondyle of the humerus. The deep fascia and the intermuscular septa in relation to it also contribute fibres. Its fleshy belly, in the distal part of the forearm, ends in four tendons, which pass under cover of the dorsal carpal ligament. On the dorsum of the hand they diverge and proceed onwards to the four fingers. Their arrangement and attachments on the dorsum of the hand and fingers will be afterwards considered (p. 145). This muscle is supplied by the *dorsal interosseous nerve.*

**M. Extensor Digiti Quinti Proprius** (O.T. **Extensor Minimi Digiti**).—The extensor digiti quinti proprius is a slender fleshy belly which at first sight appears to be a part of the preceding muscle, but its tendon passes through a special compartment in the dorsal carpal ligament. It arises in common with the extensor digitorum communis; and it is supplied by the *dorsal interosseous nerve.*

**M. Extensor Carpi Ulnaris.**—The extensor carpi ulnaris arises, by means of the common extensor tendon, from the lateral epicondyle of the humerus; from the fascia of the forearm, and from the intermuscular septum between it and the extensor digiti quinti proprius. In the middle third of the forearm it receives some fibres from the strong fascial layer which binds it to the dorsal border of the ulna. The tendon does not become free from the fleshy fibres until it approaches close to the wrist. It occupies the groove on the dorsal aspect of the distal end of the ulna, between the head and styloid process, and, passing under cover of the dorsal carpal ligament, is inserted into the tubercle on the base of the metacarpal bone of the little finger. This muscle is supplied by the *dorsal interosseous nerve.*

**M. Anconæus.** — The anconæus is a short triangular muscle placed on the dorsal aspect of the elbow-joint. It presents a narrow origin from the posterior aspect of the lateral epicondyle of the humerus. From this its fibres spread — the proximal fibres passing transversely medially, whilst the others proceed medially and distally, with an increasing degree of obliquity towards its distal end. It is inserted into the lateral surface of the olecranon, and into the proximal third of the dorsal surface of the body of the ulna.

The anconæus is frequently more or less directly continuous with the triceps, and this, together with the fact that it gets a special branch of supply from the radial nerve, has led some anatomists to regard it as a part of the triceps muscle. This is not the case, however; it belongs to, and is therefore properly classified with, the group of muscles on the extensor aspect of the forearm.

The nerve of supply to the anconæus has already been dissected. It is a long slender branch from the *radial nerve*, which descends in the substance of the medial head of the triceps to its destination. In addition, the distal part of the muscle sometimes receives a twig from the *dorsal interosseous nerve.*

*Dissection.*—Reflect the extensor digitorum communis and the extensor digiti quinti proprius. Divide the fleshy belly of each about its middle, and throw them proximally and distally. While this is being done care must be taken to secure and preserve the nerve twigs from the dorsal interosseous nerve which enter these muscles on their deep surfaces. The dorsal interosseous artery and nerve, together with the deep muscles, are now exposed, and may be fully dissected. In the distal part of the forearm the terminal part of the dorsal interosseous nerve dips under cover of the extensor pollicis longus, to reach the interosseous membrane and the dorsum of the carpus. As this part of the nerve is followed, the terminal or perforating branch of the volar interosseous artery will be seen appearing on the dorsum of the forearm, under cover of the extensor pollicis longus.

**Deep Muscles.**—These are—(1) the supinator; (2) the abductor pollicis longus; (3) the extensor pollicis brevis; (4) the extensor pollicis longus; and (5) the extensor indicis proprius.

The supinator will be recognised from the close manner in which it is applied to the proximal part of the body of the radius. The other muscles take origin proximo-distally in the order in which they have been named. The attachments of the supinator cannot be satisfactorily studied at present. They will be described at a later stage of the dissection.

**M. Abductor Pollicis Longus** (O.T. **Extensor Ossis Metacarpi Pollicis**).—This muscle arises from both bones of the forearm, and from the interosseous membrane, which stretches between them. Its *origin from the radius* corresponds to the middle third of its dorsal surface; its *origin from the ulna* is more proximal, from the lateral part of the dorsal surface of the body, immediately distal to the oblique line which marks the distal limit of the insertion of the anconæus. The muscle proceeds distally and laterally, and comes to the surface in the interval between the extensor digitorum com-

munis and the extensor carpi radialis brevis. Then it crosses the two radial extensors, closely accompanied by the extensor pollicis brevis. The tendon which issues from it, at that point, is continued distally, over the lateral side of the expanded distal end of the radius, and under cover of the dorsal carpal ligament, and is inserted into the lateral side of the base of the metacarpal bone of the thumb. The muscle is supplied by the *dorsal interosseous nerve.*

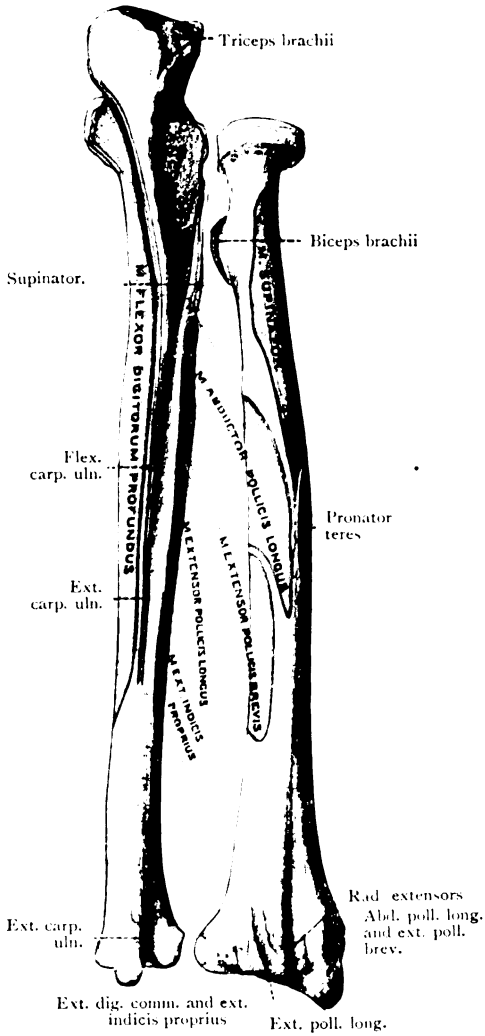


FIG. 53.—Dorsal aspect of the Bones of the Forearm, with Attachments of Muscles mapped out.

**M. Extensor Pollicis Brevis** (O.T. **Extensor Primi Internodii Pollicis**). — This muscle is placed along the distal border of the preceding muscle. It arises from a small portion of the dorsal surface of the radius, and also from the interosseous membrane. Its tendon is closely applied to that of the abductor

pollicis longus, and accompanies it beneath the dorsal carpal ligament. It must be traced, on the dorsal aspect of the metacarpal bone of the thumb, to the base of the proximal phalanx, into which it is inserted. This muscle is supplied by the *dorsal interosseous nerve.*

**M. Extensor Pollicis Longus** (O.T. **Extensor Secundi Internodii Pollicis**).—The extensor pollicis longus takes origin from the lateral part of the dorsal surface of the body of the ulna, in its middle third, and also from the interosseous membrane. It, to some extent, overlaps the preceding muscle, and it ends in a tendon which passes under cover of the dorsal carpal ligament, where it occupies a deep narrow groove on the dorsum of the distal end of the radius. On the carpus it takes an oblique course, and, crossing the tendons of the two radial extensors and the radial artery, it reaches the thumb. It is inserted into the base of the distal phalanx of the thumb and is supplied by a branch of the *dorsal interosseous nerve.*

When the thumb is powerfully extended, in the living person, the tendons of its three last-mentioned muscles become prominent on the lateral aspect of the wrist. The oblique course of the tendon of the extensor pollicis longus is rendered evident, and a distinct depression between it and the other two tendons is seen.

**M. Extensor Indicis Proprius.** — The extensor indicis proprius arises, distal to the preceding muscle, from a limited area on the dorsal surface of the ulna, and from the interosseous membrane. Its tendon accompanies the tendons of the extensor digitorum communis under cover of the dorsal carpal ligament, and will afterwards be traced to its insertion on the index finger. This muscle is supplied by the *dorsal interosseous nerve.*

**Arteria Interossea Dorsalis.** — The dorsal interosseous artery arises, in the volar part of the forearm, from the common interosseous branch of the ulnar artery. It at once proceeds dorsally, between the two bones of the forearm, in the interval between the proximal border of the interosseous membrane and the oblique cord. In the present dissection it makes its appearance between the contiguous borders of the supinator and the abductor pollicis longus, and then it extends distally between the superficial and deep muscles on the dorsum of the forearm. It gives branches to these, and by the time it has reached the

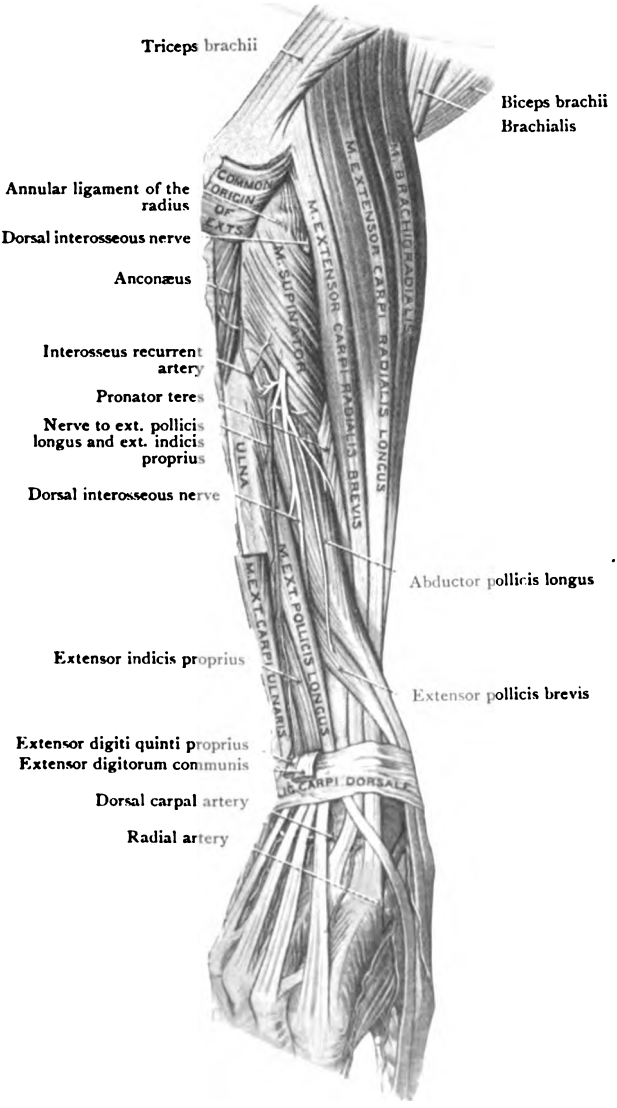


FIG. 54.—Dissection of the Dorsum of the Forearm and Hand.

distal end of the forearm it is greatly reduced in size. In a well-injected limb it will be seen to end on the dorsum of the carpus by anastomosing with the volar interosseous artery and the dorsal carpal arteries. In addition to the branches which it supplies to the muscles, it gives off one large branch called the *interosseous recurrent artery.*

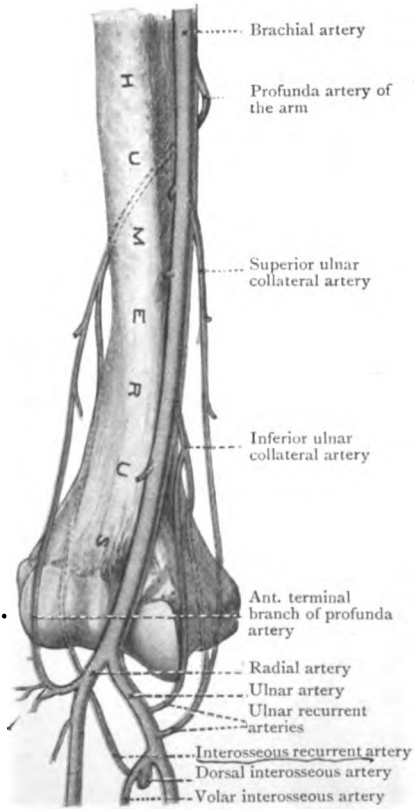


FIG. 55.—Diagram of Anastomosis around the Elbow-joint.

The *arteria interossea recurrens* takes origin from the parent trunk, as it appears between the supinator and the abductor pollicis longus, and turns proximally, under cover of the anconæus muscle, to reach the dorsal aspect of the lateral epicondyle of the humerus. The anconæus should be detached from its origin and thrown medially, in order that the artery may be traced to its termination. The interosseous recurrent artery will then be seen to end by anastomosing with the posterior terminal branch of the profunda artery of the arm.

**Anastomosis around the Elbow-joint.** — The series of inosculations around the elbow should now be reviewed as a whole. A distinct inosculation will be found to take place upon both the anterior and posterior aspect of each epicondyle of the humerus. Behind the lateral epicondyle the *interosseous recurrent artery* joins the *posterior branch* of the *profunda brachii artery:* anterior to the same epicondyle the *anterior branch* of the *profunda brachii artery* communicates

with the *radial recurrent*. On the medial side of the joint the *anterior* and *posterior ulnar recurrent arteries* ascend respectively in front of and behind the medial epicondyle; the former anastomoses with the *anterior branch* of the *inferior ulnar collateral artery*, and the latter with the *posterior* branch of the same artery and with the *superior ulnar collateral artery*.

In this sketch of the anastomosis around the elbow-joint only the leading inosculations are mentioned. Rich networks of fine vessels are formed over the olecranon and the two epicondyles of the humerus. One very distinct and fairly constant arch requires special mention. It is formed by a branch which crosses the posterior aspect of the humerus, immediately proximal to the olecranon fossa, and connects the posterior branch of the profunda brachii artery with the posterior branch of the inferior ulnar collateral artery.

**Nervus Interosseus Dorsalis.**—The dorsal interosseous nerve is the continuation of the deep terminal branch of the radial (musculo-spiral) nerve. It reaches the dorsum of the forearm by traversing the substance of the supinator, and at the same time winding round the lateral aspect of the body of the radius. It emerges from the supinator a short distance proximal to the distal border of the muscle, and is carried distally between the superficial and deep muscles on the back of the forearm. Reaching the proximal border of the extensor pollicis longus, it leaves the dorsal interosseous artery, dips anterior to the extensor pollicis longus, and joins the volar interosseous artery on the dorsal aspect of the interosseous membrane. It will afterwards be traced to the dorsum of the carpus, where it ends, under cover of the tendons of the extensor digitorum communis, in a gangliform enlargement.

The *branches* which spring from the dorsal interosseous nerve in the forearm are given entirely to muscles. Before the deep branch of the radial nerve pierces the supinator and becomes the dorsal interosseous nerve, it gives branches both to the supinator and to the extensor carpi radialis brevis. After it appears on the dorsum of the forearm, as the dorsal interosseous nerve, it supplies the extensor digitorum communis, the extensor digiti quinti proprius, the extensor carpi ulnaris, the abductor pollicis longus, two extensors of the thumb, and the extensor indicis proprius. It supplies, therefore, all the muscles on the lateral and dorsal aspects of the forearm, with the exception of the brachio-radialis and the extensor carpi radialis longus, which

derive their nerve-supply directly from the radial nerve (O.T. *musculo-spiral*). The anconæus also derives its main nerve of supply from the radial nerve, but not infrequently it also obtains a second twig from the dorsal interosseous nerve.

**Terminal Branch of the Arteria Interossea Volaris.**— The terminal or perforating branch of the volar interosseous artery is a vessel of some size. It appears through the interosseous membrane, about two inches or so proximal to the distal end of the forearm. Accompanied by the dorsal interosseous nerve it runs distally under cover of the extensor pollicis longus, and ends on the dorsum of the carpus by anastomosing with the dorsal carpal arch and the dorsal interosseous artery.

### Dorsal Aspect of the Wrist and Hand.

Upon the dorsal aspect of the wrist and hand the following structures have still to be examined:—

1. The radial artery and its branches.
2. The dorsal carpal ligament.
3. The extensor tendons of the fingers.

**Radial Artery.** — Only a small portion of the radial artery is seen in this dissection. At the distal end of the radius the vessel turns dorsally distal to the styloid process and upon the radial collateral ligament of the radio-carpal joint. Having gained the dorsal aspect of the carpus, it runs distally upon the navicular and os multangulum majus, and finally disappears from view by turning volarwards, through the proximal part of the first interosseous space and between the heads of origin of the first dorsal interosseous muscle (Fig. 54, p. 139). In the palm it takes the chief share in the formation of the deep volar arch.

While the radial artery rests on the radial collateral carpal ligament, it is deeply placed, and is crossed by the tendons of the abductor pollicis longus and the extensor pollicis brevis. On the carpus it lies nearer the surface, and is crossed obliquely by the extensor pollicis longus. It is accompanied by two *venæ comites* and some fine filaments from the lateral cutaneous nerve of the forearm which twine around it.

The *branches* which spring from the radial artery in this part of its course are of small size. They are:—

1. Ramus carpeus dorsalis.
2. Aa. metacarpeæ dorsales.
3. Aa. digitales dorsales. { Two dorsal arteries of the thumb. / One dorsal artery of the index digit.

The *dorsal radial carpal artery* takes origin on the lateral aspect of the wrist, and runs medially, upon the carpus, to join the corresponding carpal branch of the ulnar artery. The arch thus formed is placed under cover of the extensor tendons, and gives off two branches which run distally in the third and fourth inter-metacarpal intervals. They are termed the *second* and *third dorsal metacarpal arteries.*

The *first dorsal metacarpal artery* arises, as a rule, from the radial trunk, although not infrequently it may be seen to spring from the dorsal carpal arch. It extends distally in the second interosseous space.

The three dorsal metacarpal arteries are brought into connection with the arteries in the palm by communicating branches. They are joined by the three perforating twigs of the deep volar arch. These make their appearance on the dorsum of the hand between the heads of the medial three dorsal interosseous muscles. Further, at the distal ends of the interosseous spaces the dorsal metacarpal arteries usually send *distal perforating branches* to join the corresponding common volar digital arteries in the palm.

The *two dorsal arteries of the thumb* run distally one upon each side of that digit.

The *dorsal artery of the index* is distributed on the lateral side of the index finger.

**Ligamentum Carpi Dorsale.**—The dorsal carpal ligament is a fascial band which stretches obliquely across the wrist. It is merely a thickened portion of the deep fascia, and its attachments are so arranged that it does not interfere with the free movement of the radius and hand during pronation and supination. On the lateral side it is fixed to the lateral margin of the distal end of the radius, whilst on the medial side it is attached to the os triquetrum and os pisiforme, and also to the palmar aponeurosis. In the case of the transverse carpal ligament one large compartment, or tunnel, is formed for the flexor tendons; not so in the case of the dorsal carpal ligament. Partitions or processes proceed from its deep surface, and are attached to the ridges on the dorsal aspect of the distal end of the radius, so as to form a series of six bridges or compartments for the tendons. Each of these is lined by

a special mucous sheath, to facilitate the play of the tendons within it. The different compartments may now be successively opened up so that the arrangement of the tendons with reference to the dorsal carpal ligament may be studied.

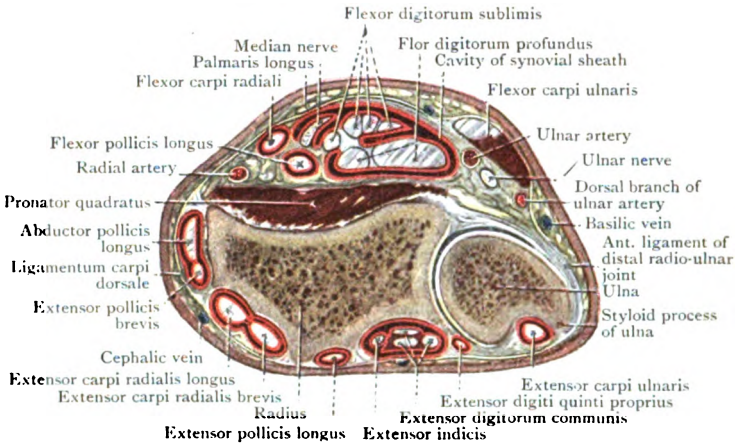


FIG. 56.—Transverse section through Forearm proximal to the Ligamentum Carpi Transversum. Showing the relation of the synovial sheaths to the tendons.

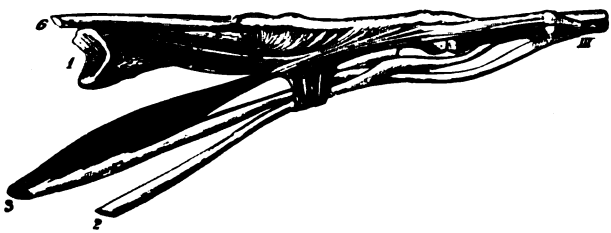


FIG. 57.—(From Luschka.)

1. Middle metacarpal bone.
2. Tendon of flexor digitorum sublimis.
3. Tendon of flexor digitorum profundus.
4. Second lumbrical muscle.
5. Second dorsal interosseous muscle.
6. Common extensor tendon.

I., II., and III. The three phalanges.

The *first compartment* is placed on the lateral side of the base of the styloid process of the radius, and corresponds with the broad oblique groove which is present in that part of the

bone. It contains two tendons, viz., the tendons of the abductor pollicis longus and the extensor pollicis brevis. The *second compartment* corresponds with the most lateral groove on the dorsal aspect of the radius. It is broad and shallow, and it holds the tendons of the extensor carpi radialis longus, and extensor carpi radialis brevis. The *third compartment* is formed over the narrow, deep, oblique intermediate groove on the dorsum of the distal end of the radius, and through it the tendon of the extensor pollicis longus passes. The *fourth compartment* is placed over the wide shallow groove which marks the medial part of the dorsal aspect of the distal end of the radius. It is traversed by five tendons, viz., the four tendons of the extensor digitorum communis and the tendon of the extensor indicis proprius. The *fifth compartment* is situated over the interval between the distal ends of the radius and ulna. It contains the slender tendon of the extensor digiti quinti proprius. The *sixth* and *most medial compartment*, which corresponds with the groove on the dorsum of the distal end of the ulna, encloses the tendon of the extensor carpi ulnaris (see Fig. 56).

**Extensor Tendons of the Fingers.**—The four tendons of the *extensor digitorum communis*, when they emerge from their compartment under the *dorsal carpal ligament*, diverge on the dorsum of the hand to reach the four fingers. The tendon of the ring finger will be seen to be connected by a tendinous slip with the tendon on each side of it. This explains the small degree of independent movement in a backward direction which the ring finger possesses. The arrangement of the tendons on the fingers is the same in each case. Upon the first phalanx the tendon expands so as to cover the dorsal aspect of the phalanx completely. Into the margins of this "*dorsal expansion*" the delicate tendons of a lumbrical and one or two interosseous muscles are inserted. Near the first interphalangeal joint the expansion divides into three portions—a central and two collateral. The *central part*, which is the weakest, is inserted into the dorsal aspect of the base of the second phalanx. The *stronger collateral portions* then unite into one piece which is inserted into the base of the ungual phalanx.

The tendon of the *extensor indicis proprius* joins the expansion of the extensor tendon on the dorsal aspect of the first phalanx of the index finger.

The tendon of the *extensor digiti quinti proprius* splits into two parts. Of these the *lateral* joins the tendon of the common extensor which goes to that digit, whilst the *medial* ends in the dorsal expansion.

**Nervus Interosseus Dorsalis.**—The terminal filament of the dorsal interosseous nerve can now be traced distally to the dorsal aspect of the carpus. It passes under cover of the extensor indicis proprius, the tendons of the extensor digitorum communis, and the dorsal carpal ligament. On the carpus it ends in a gangliform swelling, from which fine twigs proceed for the supply of the numerous joints in the vicinity.

*Dissection.*—The limb should now be turned round, so that the transverse metacarpal ligament which stretches across the volar aspects of the heads of the metacarpal bones may be examined previous to the dissection of the interosseous muscles.

**Ligamentum Capitulorum Transversa.**—The transverse ligament of the heads of the metacarpal bones is a strong band composed of transverse fibres, which crosses the volar aspects of the heads of the four metacarpal bones of the fingers. Commencing on the lateral side, upon the distal extremity of the index metacarpal, it ends at the medial margin of the hand, upon the head of the metacarpal bone of the little finger. It is not directly attached to the bones, but is fixed to the powerful volar accessory ligaments of the medial four metacarpophalangeal joints, and it effectually prevents excessive separation of the metacarpal bones from each other.

*Dissection.*—To obtain a satisfactory view of the interosseous muscles, the transverse part of the adductor pollicis, if not previously reflected, should be detached from its origin, and thrown laterally towards its insertion into the thumb. The transverse metacarpal ligament also must be divided in the intervals between the fingers.

**Mm. Interossei.**—The interosseous muscles occupy the intervals between the metacarpal bones. They are seven in number, and are arranged in two groups, viz., a dorsal and a volar.

The *dorsal interossei* are four in number, and are larger than the volar muscles. They are seen best on the dorsal aspect of the hand, but they are visible in the palm also. They act as abductors of the fingers from the central line of the middle digit, and their insertions are arranged in accordance with that action. Each

muscle arises by two heads from the contiguous surfaces of the two metacarpal bones between which it lies, and the fibres converge in a pennate manner upon a delicate tendon. In the case of the *first* or *most lateral dorsal interosseous muscle*, this tendon is inserted into the lateral side of the base of the first phalanx, and also into the lateral margin of the dorsal expansion of the extensor tendon of the index. The *second* and *third dorsal interosseous muscles* are inserted in a similar manner one on each side of the base of the first phalanx of the middle finger; whilst the *fourth* has a corresponding insertion upon the medial aspect of the base of the first phalanx of the ring finger.

The first dorsal interosseous muscle is frequently termed the *abductor indicis*; and between its two heads of origin the radial artery enters the palm. Between the heads of the other three muscles the small perforating arteries pass.

The three *volar interossei* can be seen only on the palmar aspect of the hand. They act as adductors of the index, ring, and little fingers towards the middle digit, and each muscle is placed upon the metacarpal bone of the finger upon which it acts. The *first volar interosseous muscle* therefore arises from the metacarpal bone of the index finger, and its delicate tendon is inserted upon the medial side of that digit, partly into the base of the first phalanx, and partly into the extensor expansion. The *second volar interosseous muscle* springs from the metacarpal bone of the ring finger, and has a similar insertion into the lateral side of that digit. The *third volar interosseous muscle* takes origin from the metacarpal bone, and presents a corresponding insertion into the lateral side of the first phalanx and extensor expansion of the little finger. The interosseous muscles are supplied by the *deep branch* of the *ulnar nerve*.

**Deep Head of M. Flexor Pollicis Brevis.** — This small muscle, which is known also as the *m. interosseus primus volaris* (Henle), can be displayed best from the dorsal aspect of the hand, by reflecting the ateral head of the first dorsal interosseous muscle. It arises from the base of the metacarpal bone of the thumb, and is inserted into the medial sesamoid bone of that digit. It is deeply placed, and is entirely covered, on its volar aspect, by the oblique part of the adductor pollicis.

**Tendon of the Flexor Carpi Radialis.**—The tendon of this muscle should now be traced through the groove on the volar aspect of the os multangulum majus to its insertion into the base of the metacarpal bone of the index finger. It presents also a minor attachment to the base of the middle metacarpal bone.

*Dissection.*—All the muscles around the elbow-joint should be removed. In raising the brachialis and the triceps from the anterior and posterior aspects of the articulation, some care is required to avoid injury to the anterior and posterior parts of the capsule. It is advisable to remove the supinator last, because it is only when this muscle is completely isolated that a proper idea of its attachments and mode of action can be obtained.

**M. Supinator (O.T. Supinator Brevis).**—The supinator muscle envelops the proximal part of the body and the neck of the radius, covering it completely, except on its medial side (Figs. 41, 54, pp. 100, 139). It arises from the deep depression distal to the radial notch of the ulna, and also from the radial collateral ligament of the elbow and the annular ligament of the radius. From their origin the fibres sweep round the dorsal, lateral, and volar surfaces of the radius, and clothe its body as far distally as the insertion of the pronator teres. The dorsal interosseous nerve supplies the muscle, traverses its substance, and separates it into two layers.

## ARTICULATIONS.

### Articulatio Cubiti (Elbow-joint).

This joint includes (1) the articulatio humero-ulnaris, (2) the articulatio humero-radialis, and (3) the articulatio radio-ulnaris proximalis. In the humero-ulnar articulation the trochlea of the humerus is grasped by the *semilunar notch* of the ulna. In the radio-humeral articulation the *capitulum of the humerus* rests in the shallow *fovea capituli* of the radius, and in the proximal radio-ulnar articulation the *articular circumference* of the head of the radius is held in apposition with the *radial notch* of the ulna by the *annular ligament.*

The joint is surrounded by a capsule which is reinforced at the sides by collateral ligaments; in addition, the interosseous membrane, which passes between the interosseous crests of the radius and ulna, and the oblique cord, which connects the tuberosity of the ulna with the proximal part of the interosseous crest of the radius, help to keep the radius and ulna in apposition, and are therefore included in the ligaments of the elbow-joint. The ligaments of the elbow-joint are therefore—

1. Capsula articularis.
2. Lig. collaterale ulnare.
3. Lig. collaterale radiale.
4. Lig. annulare radii.
5. Membrana interossea antibrachii.
6. Chorda obliqua.

The *articular capsule* is attached proximally to the antero-medial and antero-lateral surfaces of the humerus, proximal to the coronoid and radial fossæ, respectively. At the sides, it is attached to the epicondyles; and, posteriorly, to the posterior surface, on which the line of attachment passes through the proximal part of the olecranon fossa. Distally, the capsule is attached to the anterior margin of the proximal, medial, and lateral surfaces of the olecranon; to the medial and volar margins of the coronoid process of the ulna, and to the annular ligament of the radius. The anterior part of the capsule consists of fibres which take an irregular course over the anterior aspect of the joint. The posterior part of the capsule is weaker than the anterior and its attachment to the posterior surface of the humerus is comparatively loose.

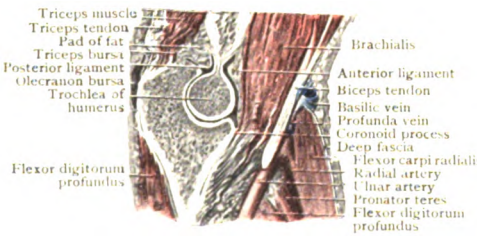


FIG. 58.—Sagittal section of Right Elbow-joint.

**Ligamentum Collaterale Radiale** (O.T. **External Lateral Ligament**).—The radial collateral ligament is a strong but short band which is attached proximally to the distal aspect of the lateral epicondyle of the humerus. Distally, it is fixed to the annular ligament of the radius, and also, more posteriorly, to the lateral side of the olecranon of the ulna. The annular ligament is a strong ligamentous collar which surrounds the head of the radius, and retains it in the radial notch of the ulna.

**Ligamentum Collaterale Ulnare** (O.T. **Internal Lateral Ligament**).—The ulnar collateral ligament, taken as a whole, is fan-shaped. By its proximal pointed part it is attached to the medial epicondyle of the humerus. Distally it spreads out to find insertion into the coronoid process and the olecranon. It consists of three very distinct portions, viz., an anterior, a posterior, and a transverse.

The *anterior part* springs from the distal and anterior part of the medial epicondyle, and is attached to the medial margin of the coronoid process of the ulna. The *posterior part* is

attached, proximally, to the distal and dorsal part of the medial epicondyle, whilst distally, it is fixed to the medial border of the olecranon. The *transverse part* consists of a band of fibres which bridges across the notch between the olecranon and the coronoid process, to both of which it is attached.

The annular ligament and the oblique cord will be described later (see pp. 155-157).

**Stratum Synoviale (Synovial Membrane).**—The joint should be opened by making a transverse incision through the

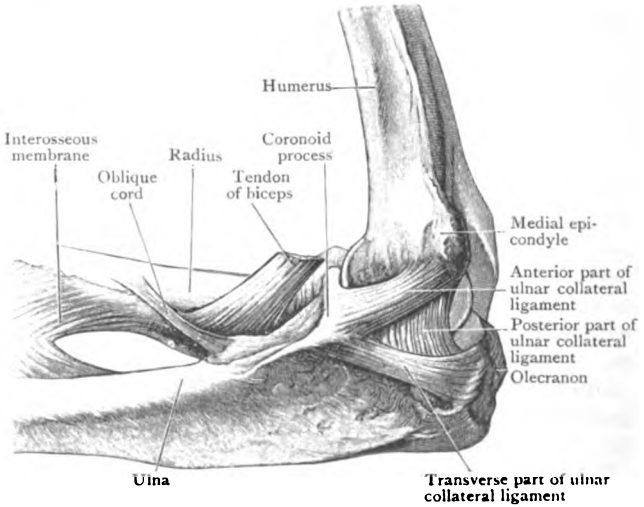


FIG. 59.—Medial aspect of Elbow-joint.

anterior part of the capsule. The synovial stratum will be seen lining the deep surface of the capsule, from which it is reflected upon the non-articular parts of the bones which are enclosed within the capsule. Anterior to the humerus it lines the radial and coronoid fossæ, and posteriorly it is prolonged proximally, in the form of a loose diverticulum, into the olecranon fossa. In these fossæ a quantity of soft oily fat is developed between the bone and the synovial stratum. In this way pliable pads are formed which occupy the recesses when the bony processes are withdrawn from them.

Distaliy, the synovial stratum of the elbow-joint is prolonged

into the proximal radio-ulnar joint, so that both articulations possess a single, continuous synovial cavity.

**Movements at the Elbow-joint.**—The movements at the elbow-joint must not be confounded with those that take place at the proximal radio-ulnar joint. At the elbow-joint two movements, viz., *flexion*, or forward movement of the forearm, and *extension*, or backward movement of the forearm, are permitted.

The *muscles* which are chiefly concerned in flexing the forearm upon the

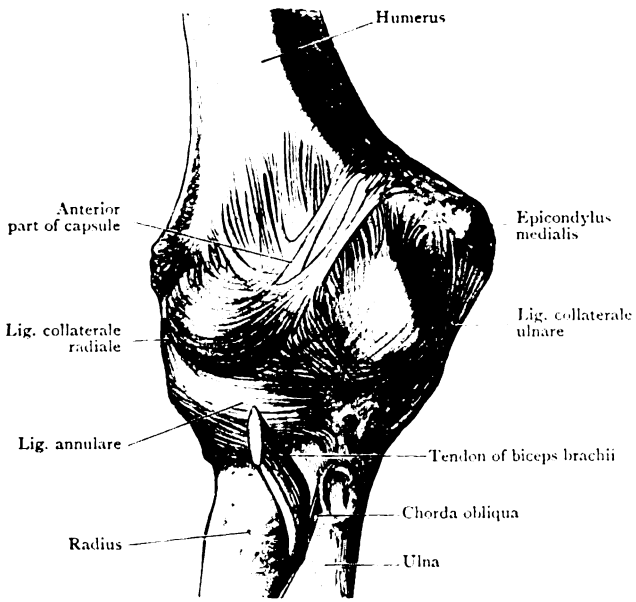


FIG. 60.—Anterior aspect of the Elbow-joint.

arm at the elbow-joint are the biceps, the brachialis, the muscles attached to the medial epicondyle, and the brachio-radialis. The muscles which extend the forearm are the triceps and anconæus and the muscles which spring from the lateral epicondyle.

*Dissection.*—It is advisable to study the radio-carpal, or wrist joint, before the articulations between the two bones of the forearm are examined. The transverse, volar and dorsal carpal ligaments, together with the extensor and flexor tendons, should be completely removed from the wrist. No attempt, however, should be made to detach the extensor tendons from the dorsal aspects of the fingers and thumb. The short muscles of the thenar and hypothenar eminences must also be taken away.

### Articulatio Radio-carpea (Wrist-Joint).

The radio-carpal or wrist joint is the joint between the forearm and the hand. The proximal face of the joint is formed by the distal articular surface of the radius and the discus articularis; and the distal surface consists of the navicular, lunate, and triquetral bones, and the interosseous ligaments which connect them together. The opposed surfaces are retained in apposition by an *articular capsule* in which at least four thickened bands can be recognised, they are:—

1. Lig. radiocarpeum volare.
2. Lig. radiocarpeum dorsale.
3. Lig. collaterale radiale.
4. Lig. collaterale ulnare.

The *capsule* is attached proximally to the borders of the distal ends of the radius and the ulna, and to the borders of the articular disc. Distally it is connected with the bones of the proximal row of the carpus, with the exception of the pisiform, and some of its fibres can be traced to the capitale bone.

The *volar radio-carpal ligament* springs from the anterior border of the styloid process of the radius and the adjacent part of the anterior border of the distal end of the radius. Distally it breaks up into flat bands which are attached to the navicular, lunate, and capitate bones. In many cases a volar *ulnar-carpal* ligament also is found. When present, it extends from the anterior aspect of the base of the styloid process and the adjacent anterior part of the head of the ulna to the triquetral, pisiform, and capitate bones.

The *dorsal radio-carpal band* springs from the posterior border of the distal end of the radius, and is attached distally to all the bones of the proximal row of the carpus, except the pisiform. Its fibres are often separable into a number of distinct bands.

The *radial collateral carpal ligament* passes from the tip of the styloid process of the radius to the lateral part of the navicular, and the *ulnar collateral carpal ligament* connects the styloid process of the ulna with the triquetral bone.

**Articular Surfaces.**—Divide the anterior and lateral parts of the capsule by a transverse incision carried across the front of the articulation. The hand can now be bent backwards, so as to expose fully the articular surfaces opposed to each other in this joint.

The *carpal surface* is composed of the proximal articular

facets of the navicular and lunate bones, and a very small articular facet on the extreme lateral part of the proximal surface of the triquetral bone. Two interosseous ligaments stretch across the narrow intervals between these bones—one on each side of the lunate bone—and complete the carpal surface. Formed of these factors, the carpal surface is convex in all directions. Further, it should be observed that the articular surface extends distally to a greater extent on the dorsal than on the volar aspect.

The *proximal surface* or *socket* (Fig. 61) is elongated from side to side, and concave in all directions. The greater part of it is formed by the distal end of the radius, but, to the medial side of this, the articular disc of the distal radio-

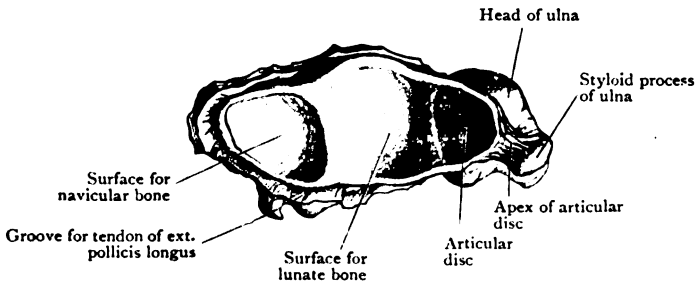
Head of ulna
Styloid process of ulna
Surface for navicular bone
Groove for tendon of ext. pollicis longus
Surface for lunate bone
Apex of articular disc
Articular disc

FIG. 61.—Carpal Articular Surfaces of the Radius and of the Articular Disc of the Wrist.

ulnar joint also enters into its construction. The distal articular surface of the radius is divided by a low ridge into a lateral triangular and a medial quadrilateral facet. The lateral facet, in the ordinary position of the hand, is in contact with the greater extent of the proximal articular surface of the navicular bone. The medial facet of the radius, together with the articular disc, forms a much larger surface, triangular in outline, which is opposed to the proximal articular surface of the lunate bone. When the hand is placed in line with the forearm no part of the proximal articular surface is allotted to the triquetral bone: its small articular facet rests against the medial part of the capsule of the joint. When the hand is moved medially (*i.e.* adducted), however, the triquetral bone travels laterally, and its articular surface comes into contact with the distal

surface of the articular disc. The lunate bone at the same time crosses the bounding ridge on the distal surface of the radius, and encroaches on the territory of the navicular bone, whilst a considerable part of the surface of the navicular bone leaves the radius and comes into contact with the lateral part of the capsule.

**Stratum Synoviale.**—The synovial stratum of the radio-carpal joint lines the capsule and it covers the proximal surfaces of the two interosseous ligaments which complete the carpal surface. Sometimes the articular disc is imperfect, and in these cases the synovial stratum of the radio-carpal joint becomes continuous with the synovial stratum of the distal radio-ulnar joint.

**Movements at the Radio-carpal Joint.**—The hand can be moved in four directions at the radio-carpal joint. Thus we have—(*a*) volar movement, or *flexion*; (*b*) dorsal movement, or *extension*; (*c*) ulnar movement, or *adduction*; (*d*) radial movement, or *abduction*. In estimating the extent of these movements in the living person the student is apt to be misled by the increase of range which is contributed by the carpal joints. Thus, flexion is in reality more limited than extension, although by the combined action of both carpal and radio-carpal joints the hand can be carried much more freely volarwards than dorsalwards. Adduction, or ulnar flexion, can be produced to a greater extent than abduction, or radial flexion. In both cases the extent of movement at the radio-carpal joint proper is very slight, but the range is extended by movements of the carpal bones. The styloid process of the radius interferes with abduction.

The *muscles* which are chiefly concerned in producing these different movements of the hand at this joint are the following:—(*a*) *flexors*—the flexor carpi radialis, the palmaris longus, and the flexor carpi ulnaris; (*b*) *extensors*—extensor carpi radialis longus, the extensor carpi radialis brevis, and the extensor carpi ulnaris; (*c*) *abductors*, or *radial flexors*—flexor carpi radialis, extensor carpi radialis longus, abductor pollicis longus, and the extensor pollicis brevis; (*d*) *adductors*, or *ulnar flexors*—extensor carpi ulnaris and flexor carpi ulnaris.

### Articulationes Radio-ulnares (Radio-Ulnar Joints).

At the two radio-ulnar joints, proximal and distal, the movements of pronation and supination take place. At the *proximal joint* the medial part of the head of the radius fits into the radial notch of the ulna; at the *distal joint* the small capitulum of the ulna is received into the ulnar notch on the medial side of the distal end of the radius. In connection with these joints there are special ligaments which retain the bones in apposition. These are—(1) for the proximal radio-ulnar joint, *the annular ligament*; and

(2) for the distal radio-ulnar joint, (*a*) a *capsule*, and (*b*) the *discus articularis*.

In addition there are other ligaments which pass between the bodies of the two bones of the forearm, and are therefore common to the two articulations, viz., the *oblique cord* and the *interosseous membrane*.

To expose these ligaments the volar and dorsal muscles of the forearm must be completely removed.

**Ligamentum Annulare Radii** (O.T. **Orbicular Ligament**). —The annular ligament is a strong fibrous collar which

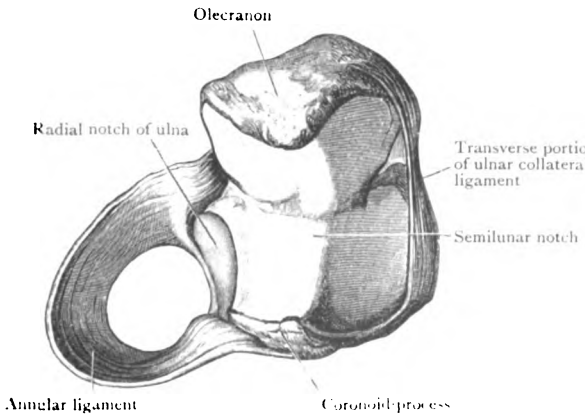


FIG. 62.—Annular Ligament of the Radius.

encircles the head of the radius and retains it in the radial notch of the ulna. It forms four-fifths of a circle, and is attached by its extremities to the volar and dorsal margins of the radial notch of the ulna. It is somewhat narrower distally than proximally, so that, under ordinary circumstances, the head of the radius cannot be withdrawn from it in a distal direction, and it is braced tightly towards the elbow, and greatly strengthened by the anterior and posterior portions of the capsule of the elbow-joint, and by the radial collateral ligament, which are attached to its proximal border. Its distal border is attached loosely to the neck of the radius by a prolongation of the synovial stratum, which is covered externally by a thin layer of fibrous tissue.

**The Capsule of the Distal Radio-ulnar Joint.**—This

capsule consists of lax fibres which can have little influence in retaining the distal extremities of the bones in apposition. The capsule is attached to the volar and dorsal surfaces of both bones of the forearm, to the most distal parts of the interosseous crests and to the volar and dorsal borders of the articular disc. A diverticulum of the capsule, which is prolonged from the joint area for some distance proximally, between the bones of the forearm, is called the *recessus sacciformis*.

**Discus Articularis** (O.T. **Triangular Fibro-Cartilage**).—The articular disc is the true bond of union at the distal radio-ulnar joint. It has already been noticed in connection with the radio-carpal joint, where it extends the radial articular surface in a medial direction, and is interposed between the distal end of the ulna and the lateral bone. It is a thick, firm plate, attached by its base to the distal margin of the ulnar notch of the radius. The apex of the disc is directed medially, and is fixed to the depression on the distal end of the ulna at the root of the styloid process. It intervenes between the distal radio-ulnar joint and the radio-carpal joint.

**Stratum Synoviale (Synovial Membrane).**—The synovial stratum of the proximal radio-ulnar joint is continuous with that of the elbow-joint. It is prolonged distally to line the annular ligament, and it protrudes beyond that for a short distance upon the neck of the radius.

The cavity of the distal radio-ulnar joint and the synovial stratum are prolonged between the head of the ulna and the articular disc.

Sometimes the articular disc is perforated ; when this is the case, the distal radio-ulnar joint-cavity communicates with the cavity of the radio-carpal joint.

**Membrana Interossea Antibrachii.**—The interosseous membrane is a fibrous membrane which stretches across the interval between the two bones of the forearm, and is attached to the crista interossea of each. Its proximal border is situated about an inch distal to the tuberosity of the radius. Distally, it blends with the capsule of the distal radio-ulnar joint. The fibres which compose it run for the most part obliquely distally and medially from the radius to the ulna, although several slips may be noticed taking an opposite direction. The dorsal interosseous vessels pass backwards,

above its proximal margin, between the two bones of the forearm; whilst the terminal branch of the volar interosseous artery pierces it about two inches from its distal end. This membrane braces the two bones together in such a manner that forces, passing proximally through the radius, are transmitted from the radius to the ulna; and it extends the surface of origin for the muscles of the forearm. By its volar surface it gives origin to the flexor digitorum profundus and the flexor pollicis longus muscles, whilst from its dorsal surface spring fibres of the two extensor muscles of the thumb, the abductor pollicis longus, and the extensor indicis proprius.

**Chorda Obliqua** (O.T. **Oblique Ligament**).—The oblique cord is a weak band of fibres which springs from the tuberosity of the ulna, and extends obliquely, distally and laterally, to find an attachment to the radius, immediately distal to its tuberosity. It crosses the open space between the bones of the forearm proximal to the proximal border of the interosseous membrane. The oblique cord is often absent; and unless the utmost care is taken in removing the adjacent muscles it is apt to be injured.

**Movements at the Radio-ulnar Joints.**—At these articulations the movements of pronation and supination take place. When the limb is in a condition of complete supination the thumb is directed laterally, the two bones of the forearm are parallel, the radius lying along the lateral side of the ulna. In the movement of pronation the radius is thrown across the ulna, so that its distal end comes to lie across the volar surface and on the medial side of the ulna. Further, the hand follows the radius in this movement, and the dorsal aspects of both are directed forwards, and the thumb is turned medially.

The dissector should analyse, as far as possible in the part upon which he is engaged, the movements at the two radio-ulnar joints which produce these effects. At the same time it should be remembered that results obtained from a limb, in which the dissection has proceeded so far, are apt to be deceptive.

In the case of the *proximal radio-ulnar joint* the movement is simple enough. The head of the radius merely rotates within the annular ligament, and accuracy of motion is obtained by the fovea capituli radii resting and moving upon the rounded capitulum of the humerus. But it should be noticed that the head of the radius does not fit accurately upon the capitulum in all positions of the elbow-joint. In extreme extension and extreme flexion of the elbow it is only partially in contact with it. Therefore the semi-flexed condition of the elbow-joint places the radius in the most favourable position for free and precise movement at the proximal radio-ulnar joint.

At the *distal radio-ulnar joint* the distal end of the radius revolves around the distal end of the ulna. It carries the hand with it, and describes the arc of a circle, the centre of which corresponds to the attachment of the

articular disc to the distal end of the ulna. In this movement the articular disc moves with the radius, and travels dorsally on the distal end of the ulna in supination, and towards the volar surface in pronation.

But the question may be asked, Does the ulna move during pronation and supination? When the elbow-joint is extended to its fullest extent the ulna remains almost immovable. When, however, pronation and supination are conducted in the semi-flexed limb, the ulna does move. A small degree of lateral movement at the elbow-joint is allowed, and the distal end of the ulna during pronation is carried slightly dorsally and laterally, and in the reverse direction during supination.

The *muscles* which are chiefly concerned in producing *supination* of the forearm are—the biceps brachii, the brachio-radialis, and the supinator. The biceps brachii, from its insertion into the dorsal part of the tuberosity of the radius, is placed in a very favourable position, in so far as its supinating action is concerned. The muscles which act as *pronators* of the limb are —the pronator teres, the pronator quadratus, and, to a certain extent, the flexor carpi radialis. The pronator teres, from its insertion into the point of maximum lateral curvature of radius, can exercise its pronating action to great advantage. The balance of power is in favour of the supinators, and this is due to the preponderating influence of the biceps.

*Dissection.*—The annular ligament should be cut through, and the oblique cord and the interosseous membrane should be divided proximo-distally. By drawing the radius laterally and opening the capsule of the distal radio-ulnar joint, the proximal surface of the discus articularis of the wrist will be displayed and its attachments more fully appreciated.

## Articulationes Carpeæ (Carpal Joints).

In the carpus two joints are recognised—

1. Articulatio ossis pisiformis.
2. Articulatio intercarpea.

**Pisiform Joint.**—The pisiform bone articulates with the volar surface of the triquetral bone to which it is attached by an articular capsule. The cavity of the pisiform joint is quite distinct from those of the adjacent joints.

The dissector has previously noted that the tendon of the flexor carpi ulnaris is inserted into the pisiform bone, and as the capsule would be quite incapable by itself of withstanding the strain to which this muscle subjects the articulation, certain accessory bands are provided which anchor the pisiform firmly in place—they are the piso-hamate and the piso-metacarpal bands. The former passes from the distal end of the pisiform to the hook of the hamate bone; and the latter attaches the pisiform to the proximal ends of the fourth and fifth metacarpal bones.

### Articulatio Intercarpea (Intercarpal Joint).

The intercarpal joint has one joint cavity, but it includes not only the articulations between the proximal and distal rows of carpal bones, which form the *transverse part* of the joint, but also the articulations between the bones of the proximal row and those between the bones of the distal row. The main part of the cavity of the joint lies between the bones of the proximal and distal rows; but two prolongations pass proximally, one between the lunate and navicular bones,

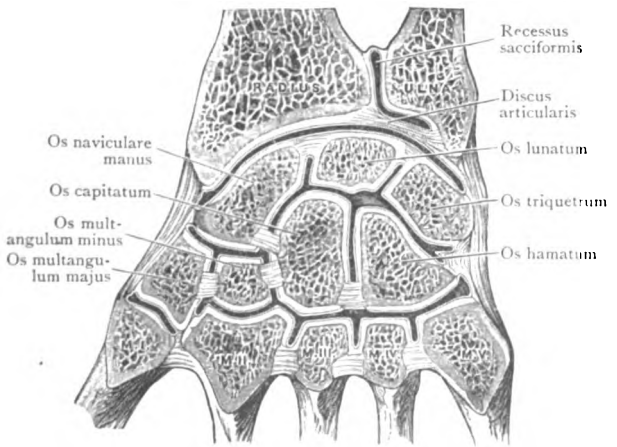


Fig. 63. — Frontal section through Radio-carpal, Carpal, and Carpo-metacarpal and Inter-metacarpal Joints to show Joint Cavities and Interosseous Ligaments (diagrammatic).

and the other between the lunate and triquetral bones, and three diverticula are prolonged between the bones of the distal row, beyond which they become continuous with the cavity of the carpo-metacarpal joint.

The bones of the proximal row are connected together by two dorsal, two volar, and two interosseous ligaments, which pass from the lunate to the navicular and triquetral bones which lie to either side of it. The two interosseous ligaments are composed of short, stout fibres which pass between the non-articular portions of the opposed surfaces of the bones. They are readily seen from the proximal aspect,

where they complete the distal surface of the radio-carpal joint.

The members of the distal row of carpal bones are bound together by three dorsal, three volar, and three interosseous ligaments which pass transversely between the adjacent bones. The interosseous ligament between the capitate and the hamate bones is very strong; that between the capitate bone and the lesser multangular bone is weak and not uncommonly absent.

At present the interosseous ligaments between the bones of the distal row are hidden from view, but they can be studied when the transverse part of the intercarpal joint is opened.

The transverse part of the intercarpal joint lies between the proximal and distal rows of carpal bones. The two rows of bones are bound together by an articular capsule which is attached to the volar and dorsal surfaces and the medial and lateral borders of each row. The lateral and medial parts of the capsule are sometimes spoken of as the lateral and medial ligaments of the transverse carpal joint. The volar and dorsal parts of the capsule are strengthened by numerous bands of fibres. The bands on the dorsal surface are irregular in number and strength, but those on the volar surface are better marked and, for the most part, they radiate from the capitate to the surrounding bones forming the *ligamentum carpi radiatum.* One of the bands of this ligament passes from the capitate bone to the styloid process of the radius and blends with the radial collateral ligament of the radio-carpal joint.

**Articular Surfaces.**—The individual bones of the proximal row and the individual bones of the distal row articulate with each other by flat surfaces. In the transverse part of the intercarpal articulation the proximal parts of the capitate bone and the hamate bone form a high convexity which fits into a concavity formed by the distal surfaces of the triquetral and lunate bones and the distal part of the medial surface of the navicular of the proximal row; and the convex distal surface of the navicular bone is received into a concavity formed by the proximal surfaces of the greater and lesser multangular bones. The two opposed surfaces of the transverse part of the joint are, therefore, concavo-convex from side to side, and adapted one to the other.

**Movements at the Carpal Joints.**—The movements at the carpal joints supplement those at the radio-carpal joint, and tend greatly to increase the range of movement at the wrist. Between the individual bones of each row the movement is of a gliding character, and very limited. At the transverse intercarpal joint volar and dorsal movements (flexion and extension) alone are allowed.

By the multiplicity of joints in this part of the limb, strength and elasticity is contributed to the wrist.

*Dissection.*—The interosseous muscles should now be removed from the metacarpal bones. At the same time the flexor tendons and lumbrical muscles may be detached from the fingers. The extensor tendons, however, should be left in position on the dorsal surfaces of the metacarpophalangeal and interphalangeal joints. The ligaments which connect the carpus and metacarpus, and those which pass between the bases of the medial four metacarpal bones, should be cleaned and defined.

## Articulationes Intermetacarpeæ (Intermetacarpal Joints).

The four metacarpal bones of the fingers articulate with each other by their basal or proximal extremities, and are united together by strong ligaments. The metacarpal bone of the thumb stands aloof from its neighbours, and enjoys a much greater freedom of movement.

The ligaments which bind the medial four metacarpal bones to each other are—

1. A series of *volar* and *dorsal* bands, which pass transversely and connect their basal extremities.

2. *Three* stout *interosseous ligaments*, which occupy the intervals between the basal ends of the bones.

3. The *transverse ligaments of the heads*, which connect the heads or distal extremities of the bones (p. 146). This ligament has been removed in the dissection of the interosseous muscles.

The *interosseous ligaments* cannot be seen at present, but can be studied later when the bases of the metacarpal bones are separated from each other.

## Articulationes Carpometacarpeæ (Carpo-metacarpal Joints).

The *metacarpal bone* of the *thumb* articulates with the greater multangular bone by a joint which is quite distinct from the other carpo-metacarpal articulations. An articular capsule surrounds the joint, and is sufficiently lax to allow a very con-

siderable range of movement. On the dorsal and lateral aspects of the articulation it is specially thickened. Its cavity is distinct from that of the adjacent articulations.

The *medial four metacarpal bones* are connected to the carpus by *volar* and *dorsal ligaments*, and by *one interosseous ligament.*

Each of these metacarpal bones, with the exception of the fifth, possesses, as a rule, two dorsal ligaments and one volar ligament. The articulation of the fifth metacarpal bone is also closed on the medial side by ligamentous fibres.

The *interosseous ligament* springs from the contiguous distal margins of the capitate and hamate bones, and passes to the medial side of the base of the third metacarpal bone.

*Dissection.*—To display this ligament, divide the bands which connect the bases of the third and fourth metacarpal bones, and sever the dorsal ligaments which bind the medial two metacarpal bones to the carpus. The metacarpal bones thus set free can then be forcibly bent volarwards, when the ligament in question will come into view.

**Synovial Membranes of the Carpal, Carpo-metacarpal, and Intermetacarpal Joints.**—The articulation between the pisiform and the triquetral bones and the carpo-metacarpal joint of the thumb both possess separate capsules; but the various ligaments of the intercarpal, carpo-metacarpal, and proximal intermetacarpal joints, though they are spoken of individually as separate ligaments, constitute collectively a single capsule, which surrounds a continuous joint cavity. The synovial stratum of the capsule is prolonged over all parts of the bones, enclosed within the capsule, which are not covered by articular cartilage, and it is continued proximally between the three bones of the proximal row of the carpus as far as the interosseous ligaments which connect the bones together. It covers the distal surfaces of these ligaments and is excluded by them from the radio-carpal joint. It passes also between the four bones of the distal row of the carpus and covers the inner surfaces of the ligaments of the carpo-metacarpal joints and the ligaments of the medial four intermetacarpal articulations.

In some cases the interosseous ligament which connects the base of the third metacarpal to the capitate and hamate bones shuts off the articulation of the hamate bone with the medial two metacarpal bones, and converts the articulation of the hamate bone with the medial two metacarpal bones into a separate segment of the carpo-metacarpal joint.

*Dissection.*—To display the articular surfaces of the carpo-metacarpal articulations, the metacarpus should be detached from the carpus. The interosseous ligaments between the carpal bones of the second row, and also between the bases of the medial four metacarpal bones, can likewise be demonstrated by carrying the knife between the bones, and dividing the ligaments.

**Articular Surfaces.**—The base of the metacarpal bone of the index will be seen to be hollowed out for the reception of the lesser multangular bone. On the lateral side it also articulates with the greater multangular bone, and on the medial side with the capitate bone. The base of the third metacarpal rests against the capitate bone alone. The base of the metacarpal bone of the ring finger rests upon the hamate bone, but articulates slightly with the capitate bone also. The fifth metacarpal bone articulates with the hamate bone.

**Movements of the Metacarpal Bones.**—The opposed saddle-shaped surfaces of the greater multangular bone and the metacarpal bone of the thumb allow free movement at this joint. Thus the metacarpal bone of the thumb can be moved—(1) dorso-laterally (extension); (2) volarwards and medially (flexion); (3) medially towards the index (adduction); (4) laterally (abduction); (5) medially across the palm towards the little finger (opposition); (6) a combination of the above-mentioned movements, occurring one after the other, constitutes circumduction. The muscles which operate on the thumb are—(1) the two special extensors, brevis and longus, and the abductor pollicis longus, producing extension; (2) the flexor pollicis brevis, the opponens pollicis, and the adductor pollicis, producing flexion and opposition, two movements which are similar in character; (3) the abductor pollicis longus and the abductor pollicis brevis, producing abduction; (4) the adductor pollicis and the first dorsal interosseous muscle, which give rise to adduction.

The metacarpal bones of the index and middle fingers possess very little power of independent movement. The metacarpal bone of the ring finger, and more especially the metacarpal bone of the little finger, are not so tightly bound to the carpus. When the hand is clenched they both move volarwards. The metacarpal bone of the little finger is provided with an opponens muscle, and has a feeble power of moving volarwards and laterally towards the thumb.

### Articulationes Metacarpophalangeæ (Metacarpo-phalangeal Joints).

The slightly cupped base of the first phalanx of each digit articulates with the rounded head of the corresponding metacarpal bone, and is held in position by (1) a capsule; (2) two collateral ligaments, and (3) by a volar accessory ligament.

**Lig. Accessorium Volare** (O.T. **Anterior Ligament**).—The *volar accessory ligament* is a dense fibrous plate placed on the volar aspect of the joint. It is firmly attached to the base

of the phalanx, but only slightly connected with the metacarpal bone. It occupies the interval between the two collateral ligaments and it is united to both by its margins, so that the three ligaments are more or less directly continuous.

The volar accessory ligament also exhibits a close connection with the transverse ligament of the heads of the metacarpal bones, which stretches transversely across the heads of the metacarpal bones; and its volar surface is grooved for the flexor tendons as they proceed distally over the joint. Further, the fibrous sheath, which bridges over the tendons, is fixed to its borders.

**Ligg. Collateralia** (O.T. **Lateral Ligaments**).—The *collateral ligaments* are placed one on each side of the joint. Each is a strong, thick, and short band, which is attached, on the one hand, to the tubercle and depression on the corresponding side of the head of the metacarpal bone, and, on the other hand, to the base of the phalanx and the border of the volar ligament.

*Dissection.*—The extensor tendon should now be raised from the dorsal aspect of the joint. By this proceeding the joint is opened, and a demonstration is afforded of the fact that the metacarpo-phalangeal joints are represented dorsally only by the synovial stratum.

**Stratum Synoviale (Synovial Membrane).**—A *synovial stratum* lines the deep surface of the articular capsule in each joint, and also the deep surface of the extensor tendon, as it passes over the articulation. The tendon therefore takes the place of the fibrous stratum of the capsule.

**Movements at the Metacarpo-phalangeal Joints.**—The movements of the first phalanx at each of these joints are—(*a*) *flexion*, or volar movement; (*b*) *extension*, or dorsal movement; (*c*) *abduction*; and (*d*) *adduction*.

During flexion of the fingers the first phalanx travels volarwards with the thick accessory volar ligament upon the head of the metacarpal bone. The *interosseous* and *lumbrical* muscles are chiefly instrumental in producing this movement.

The first phalanges of the fingers, in the movement of extension, can be carried dorsally only to a very slight degree beyond the line of the metacarpal bones. The *extensor communis* and the *special extensors* of the *index* and *little finger* are the muscles which operate in this case.

Abduction and adduction are movements of the first phalanx away from and towards a line prolonged distally through the middle finger, and are seen when the fingers are spread out and again drawn together. The *abductor digiti quinti* and the *dorsal interosseous muscles* act as abductors of the fingers at these joints, whilst the *volar interosseous muscles* operate as adductors of the little, ring, and index fingers. In the case of the middle digit, the *second* and *third dorsal interosseous muscles* act alternately as abductors and as adductors. In connection with the

movements of abduction and adduction, it should be noticed that in the extended position of the fingers they are very free; but if flexion is induced, the power of separating the fingers becomes more and more restricted, until it becomes lost when the hand is closed. An examination of the collateral ligaments will afford the explanation of this. These "are attached so far dorsally on the metacarpal bones, as to be much nearer to their distal ends than to their volar aspects" (Cleland). Consequently, while they are comparatively lax in the extended position of the fingers, the further flexion advances the tighter they become, and in this way they interfere with the lateral movements of the first phalanges.

The first phalanx of the thumb has only a limited range of movement at the metacarpo-phalangeal joint.

### Articulationes Digitorum (Joints of the Fingers).

The ligaments connecting the phalanges are arranged upon a plan identical with that already described in connection with the metacarpo-phalangeal joints. This should not be made an excuse, however, to slur them over.

**Movements.**—From the manner in which the articular surfaces are adapted to each other, flexion and extension are the only movements which can take place at the interphalangeal joints. Flexion of the second phalanges of the fingers is brought about by the flexor sublimis, and of the ungual phalanges by the flexor profundus. Extension of the phalanges at the interphalangeal joints is produced largely by the interosseous and lumbrical muscles acting through the extensor tendons, into which they are inserted. These muscles, therefore, whilst they flex the first phalanx at the metacarpo-phalangeal joints, extend the second and ungual phalanges at the interphalangeal joints.

In the case of the thumb, the flexor pollicis longus and the extensor pollicis longus operate at the interphalangeal joint.

For radiographic appearances of the joints of the upper extremity see Plates at the end of the volume.

# THE INFERIOR EXTREMITY.

## THE THIGH.

On the morning of the fourth day after the subject has been brought into the dissecting room, it is placed upon the table lying upon its back; the pelvis is supported by two blocks, and the inferior extremities are stretched out at full length. In this position it is allowed to remain for five days, and during that period the dissector of the inferior extremity has a very extensive dissection to perform. He has to dissect (1) the anterior region of the thigh, including the *trigonum femorale* and its contents, (2) the medial region of the thigh, including the adductor canal and its contents. With so much work to be completed, within a limited time, he must apportion the five days to the best advantage. During the first day he should dissect the superficial structures of the whole of the anterior and medial aspects of the thigh. During the second and third days he should complete the dissection of the *femoral triangle* and the anterior region of the thigh, and the remainder of the period should be devoted to the dissection of the medial region.

**Surface Anatomy.**—Before the skin is reflected the surface markings of the anterior, the lateral, and the medial region of the thigh must be examined.

A faint sulcus at the proximal extremity of the *anterior region* is the boundary line between the *inguinal region* of the abdomen and the *subinguinal region* of the thigh. The resistance felt deep to the sulcus is due to the *ligamentum inguinale* (O.T. *Poupart's Ligament*), which is attached, at the lateral and superior end of the sulcus, to the *anterior superior iliac spine*, and, at its inferior and medial end, to the *pubic tubercle*. From the anterior superior iliac spine the *iliac crest* can be traced laterally and posteriorly, and from the pubic tubercle the finger should be carried medially, along the pubic crest, to the superior end of the *symphysis pubis*. Next, the finger should be passed downwards, along the front of the *symphysis pubis*, to the superior margin of the *pubic arch* and thence downwards and posteriorly, along the *rami* of the *pubis* and *ischium*, which mark the superior boundary of the *medial femoral region*, to the *tuber*

*ischiadicum.* About four inches below the highest part

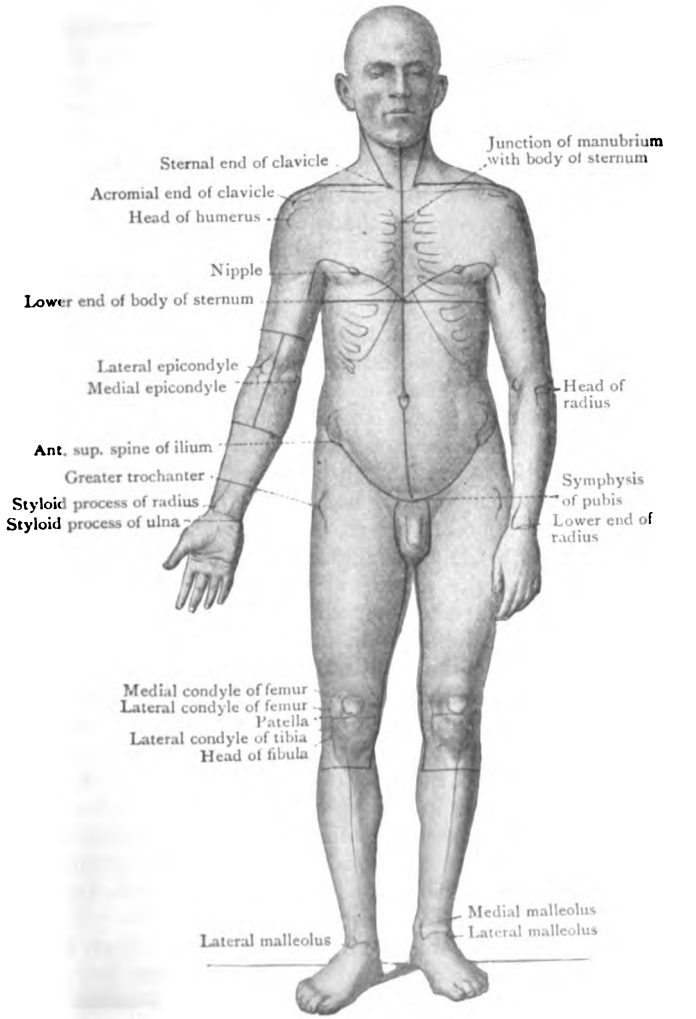


FIG. 64.—Anterior Surface of Body.

of the iliac crest, and on the plane of the pubic ridge, is the *trochanteric region*, indicated by an eminence due to the

prominence of the trochanter major of the femur. Above the trochanteric region, and between it and the iliac crest is the *region of the hip* (*regio coxæ*), and below the trochanteric region is the *lateral femoral region.* At the distal end of the anterior part of the thigh is the *regio genu anterior.* In the centre of the anterior part of the knee lies the *patella* or knee-cap, the outline of which can be seen as well as felt. When the limb is extended the extensor muscles in the anterior part of the thigh are relaxed and the patella is freely movable. As the *leg* is flexed on the *femur* at the knee the patella passes distally, till it lies anterior to the interval between the femur and the tibia, and the *patellar surface* of the femur can be felt beneath the skin. From the distal end of the patella the ligamentum patellæ should be followed to the tuberosity of the tibia.

At the distal end of the lateral region of the thigh the outline of the lateral condyle of the femur is easily recognised. Directly distal to it is the lateral condyle of the tibia, and at the distal and posterior part of the latter is the head of the fibula. The tendon which can be traced proximally from the head of the fibula, on the border line between the lateral and posterior femoral regions, is the tendon of the biceps femoris; and the dense, longitudinal band of fascia immediately anterior to the tendon of the biceps is the ilio-tibial tract of the fascia lata—a fascial band which is more easily distinguishable in the living than in the dead body.

At the distal end of the medial part of the thigh is the outline of the medial condyle of the femur, which should be palpated; and immediately distal to it the medial condyle of the tibia is easily recognised beneath the integument. The tendons posterior to the medial condyle of the femur, which are more easily felt in the living than the dead body, are the tendons of the semitendinosus and semimembranosus muscles, and the less easily palpated tendon of the adductor magnus should be distinguished as it descends to the proximal border of the medial femoral condyle.

The dissector should verify all these points of surface anatomy not only on the dead body but also on the bodies of himself and his friends, and he should examine them repeatedly until he is quite familiar with them both by sight and by touch.

## Superficial Dissection.

This dissection comprises the examination of the following parts:—

1. Superficial fascia.
2. The great saphenous vein and its tributaries.
3. The superficial external pudendal artery.
4. The superficial epigastric artery.
5. The superficial circumflex iliac artery.
6. Lymph glands and vessels.
7. The fossa ovalis.
8. Cutaneous nerves.
9. The fascia femoris (deep fascia of the thigh).
10. The bursæ patellæ.

**Reflection of the Skin.**—*Incisions.*—(1) From the anterior superior iliac spine along the line of the inguinal ligament to the symphysis pubis; (2) from the medial extremity of the first incision downwards along the margin of the scrotum, then along the junction of the medial with the posterior aspect of the thigh and across the medial aspect of the knee to the level of the tubercle of the tibia; (3) from the distal end of the vertical incision transversely across the anterior surface of the leg to its lateral border. The quadrilateral flap of integument, thus mapped out, must be raised carefully from the subjacent superficial fascia and turned laterally, particular care being taken in the region of the knee to avoid injury to the patellar plexus of cutaneous nerves.

**Panniculus Adiposus (Superficial Fascia).**—The fatty superficial fascia, which is now exposed, is continuous with the corresponding layer on the front of the abdomen, and it is regarded by some anatomists as being composed of two layers. This subdivision is needless and artificial. In the lower part of the abdominal wall, above the inguinal ligament, it is true that the superficial fascia presents two distinct strata—one, a fatty layer, continuous, over the inguinal ligament, with the superficial fascia of the anterior part of the thigh, and sometimes termed the *fascia of Camper*; the other, a deeper layer, firm and membranous and devoid of fat, called the *fascia of Scarpa.* As this latter fascial stratum is attached to the fascia lata (deep fascia of the thigh) immediately below the inguinal ligament, it is necessary that it should receive some attention.

To demonstrate the fascia of Scarpa the dissectors of the lower extremity and abdomen must work in conjunction with each other. A transverse incision should be made through the entire thickness of the superficial fascia on the front of the abdomen, from the anterior superior spine of the ilium to the median line of the body. On raising the lower edge of

the divided fascia the two layers can be easily distinguished. Insinuate the fingers between the fascia of Scarpa and the pearly-looking tendon of the external oblique muscle. Little resistance will be encountered, as it is bound down only by some lax areolar tissue. The fingers can be readily carried downwards deep to the fascia of Scarpa as far as the inguinal ligament. There it will be found that they can force their way no farther. The passage of the hand into the thigh is barred by the blending of the fascia of Scarpa with the fascia lata, along an oblique line immediately below the inguinal ligament. At that level, therefore, it ceases to exist. The fatty superficial layer of Camper, however, is continued onwards as the superficial fascia of the thigh.

When urine is effused under the superficial fascia of the anterior abdominal wall, the attachment of the fascia of Scarpa to the fascia lata prevents its passage distally into the front of the thigh.

*Dissection.*—In the superficial fascia, blood-vessels, glands, lymph vessels, and nerves are embedded, and must now be dissected out. First, look for the great saphenous vein. It will be found running proximally from the posterior border of the medial condyle of the femur to a point about one and a half inches distal and lateral to the pubic tubercle; there it passes through the fossa ovalis into the femoral triangle to join the femoral vein. It is not desirable to define the opening in the fascia lata through which it passes until a later stage of the dissection. Several tributaries join the great saphenous vein at this point, and they should be dissected along with the small superficial arteries of the groin which accompany them.

The large lymph glands of the groin also must be dissected out from the fatty tissue in which they lie. While this is being done care must be taken to preserve as many as possible of the minute thread-like lymph vessels which enter and leave the glands. A small artery and vein should also be traced to each gland.

**Superficial Inguinal Vessels.** — Three small arteries, termed the superficial epigastric, the superficial external pudendal and the superficial circumflex iliac, pierce the deep fascia of the thigh below the inguinal ligament, and radiate from each other for the supply of the lymph glands and integument of the subinguinal region. They all spring from the femoral artery immediately after it enters the thigh.

*Art. Pudenda externa superficialis.*—The *superficial external pudendal artery* passes forwards through the fascia cribrosa (a thin fascial layer, which is spread over the fossa ovalis), and runs medially and upwards across the spermatic funiculus. It supplies the skin of the scrotum and penis.

iliac portion of the fascia lata sud-
ng indicates the position of the
should be defined by the edge
medially into the superior horn.
s displayed the dissector should
fusion with the pectineal fascia;
fascia from the surface of the
e that, above the level of the
s across the front of the femoral
ep fascia, but, on the contrary,
to become continuous with the
herefore, the falciform edge forms
of the fascia lata (see Fig. 65).
cia is continued from this margin,
to join the pectineal fascia. This
he fossa is known as the *fascia*
the great saphenous vein and by
subinguinal lymph glands on their
h glands.
valis have been displayed, the sub-
a cribrosa should be removed, care
the latter, to avoid injury to the
to them.

nous Opening).—The fossa ovalis
fascia through which the great
s junction with the femoral vein.
*fascia cribrosa*, is spread over the
inion exists as to what the fascia
garded by some as being a part of
it is more correct to look upon it
ata carried over the opening, or, in
tion of fascia, medially, from the
ning.

special importance, because it is the
femoral hernia makes its way to the
shape and not more than half an
is at least one and a half inches long.
which is formed by the receding fascia
eeper plane than the lateral boundary.
, or margo falciformis, is crescentic. It
*ic portion* of the fascia lata. The *cornu*
form edge curves medially, distal to the
e great saphenous vein, to join the fascia
*rnu superius*, not so well defined, sweeps
to the proximal part of the femoral
he front of the ligamentum lacunare (O.T.
ient) (Fig. 65).

wards the *fossa ovalis* and join the *great saphenous vein* before it pierces the fascia.

**Lymph Glands and Vessels.**—The disposition of the superficial *subinguinal lymph glands* into two groups will now be evident—a proximal *subinguinal group* along the line of the inguinal ligament, immediately distal to the attachment of Scarpa's fascia to the fascia lata, and a distal group, which extends for a short distance distally along the line of the great saphenous vein. Both groups are separable into medial and lateral parts.

In a spare subject, or, better still, in a dropsical subject, the general arrangement of the lymph vessels may also be made out. To the subinguinal group of glands proceed the superficial lymph vessels of the lower extremity, and lymph vessels from the external genitals, the perineum, and the lower part of the abdominal wall. These are termed the *afferent vessels.* In addition to them, numerous other vessels connect the glands with each other. The lymph vessels which lead the lymph away from the glands are called the *efferent vessels.* A large number of these pass through the fossa ovalis, others pierce the fascia lata. They join the *deep subinguinal glands* and the external iliac glands, which lie in relation to the femoral and external iliac arteries.

*Dissection.*—It has already been noted that an opening in the fascia lata called the fossa ovalis (O.T. *saphenous opening*) is situated at the proximal and medial angle of the anterior part of the thigh. It is bounded proximally, laterally, and distally by a sharp crescentic margin, the *margo falciformis*, and through it pass the great saphenous vein, on its way to join the femoral vein, and the efferent lymph vessels which connect the superficial subinguinal lymph glands with the deep subinguinal lymph glands. The deep fascia on the lateral side of the fossa ovalis is called the *iliac portion of the fascia lata*, and that on its medial side is the *fascia pectinea*. It is difficult to display the opening satisfactorily, but the difficulty may be overcome by the exercise of a little care. The dissector should commence by raising the proximal part of the great saphenous vein from the fatty bed in which it lies; he should then carry the handle of his scalpel proximally, behind the vein, till he feels it dip over a sharp free margin, the *cornu inferius* of the opening. This cornu is always clearly defined. It blends medially with the fascia pectinea, which lies superficial to the pectineus and adductor longus muscles. Laterally it is continued into the lateral part of the falciform edge, and the proximal end of the latter, turning medially, becomes the *cornu superius*, which gains attachment to the distal and medial part of the ligamentum lacunare (O.T. Gimbernat's ligament). The falciform edge and the upper horn are not always easy to define, but if the dissector, after he has displayed the lower horn, will carefully remove the superficial fat from the surface of the fascia, on the lateral side of the great saphenous vein, he will find that,

at a short distance from the vein, the iliac portion of the fascia lata suddenly becomes thinner. The sudden thinning indicates the position of the lateral part of the falciform margin, which should be defined by the edge of the knife and then traced proximally and medially into the superior horn. When the lateral part of the falciform edge is displayed the dissector should return to the lower horn and trace it to its fusion with the pectineal fascia; then he should clear away the superficial fascia from the surface of the latter. As he does this he will recognise that, above the level of the lower horn, the pectineal fascia does not pass across the front of the femoral vessels to join the iliac portion of the deep fascia, but, on the contrary, it dips posterior to the femoral vessels to become continuous with the deep intermuscular septa. In a sense, therefore, the falciform edge forms the medial free margin of the iliac part of the fascia lata (see Fig. 65). In reality, however, a thinner layer of fascia is continued from this margin, across the sheath of the femoral vessels to join the pectineal fascia. This thinner layer of fascia which closes the fossa is known as the *fascia cribrosa*, because it is perforated by the great saphenous vein and by the efferent vessels of the inguinal and subinguinal lymph glands on their way to join the deep subinguinal lymph glands.

When the margins of the fossa ovalis have been displayed, the subinguinal lymph glands and the fascia cribrosa should be removed, care being taken, during the removal of the latter, to avoid injury to the femoral sheath, which lies subjacent to them.

**Fossa Ovalis** (O.T. **Saphenous Opening**).—The fossa ovalis is the aperture in the deep fascia through which the great saphenous vein passes to its junction with the femoral vein. A thin fascia, called the *fascia cribrosa*, is spread over the opening. Difference of opinion exists as to what the fascia cribrosa really is. It is regarded by some as being a part of the superficial fascia; but it is more correct to look upon it as a thin layer of fascia lata carried over the opening, or, in other words, a prolongation of fascia, medially, from the lateral margin of the opening.

The fossa ovalis is of special importance, because it is the opening through which femoral hernia makes its way to the surface. It is oval in shape and not more than half an inch in width; but it is at least one and a half inches long. Its medial boundary, which is formed by the receding fascia pectinea, lies on a deeper plane than the lateral boundary. The lateral boundary, or margo falciformis, is crescentic. It is formed by the *iliac portion* of the fascia lata. The *cornu inferius* of the falciform edge curves medially, distal to the proximal end of the great saphenous vein, to join the fascia pectinea. The *cornu superius*, not so well defined, sweeps medially, anterior to the proximal part of the femoral sheath, and joins the front of the ligamentum lacunare (O.T. Gimbernat's ligament) (Fig. 65).

*Dissection.*—Clean the great saphenous vein proximo-distally, taking care to avoid injuring any of the branches of the cutaneous nerves which lie close to it. In the proximal part of the thigh it is accompanied by branches of the medial cutaneous nerve of the thigh (O.T. internal cutaneous)—one of the cutaneous branches of the femoral nerve. In the distal part of the thigh the vein is accompanied by the anterior branch of the same nerve, and it passes across the posterior part of the medial aspect of the knee, where it is accompanied by the saphenous nerve. Clean also the tributaries of the vein, and avoid injury to adjacent cutaneous nerves.

**Vena Saphena Magna** (O.T. **Internal Saphenous Vein**).—The great saphenous vein is the largest superficial vein of the inferior extremity. It commences on the dorsum of the foot, passes proximally, anterior to the medial malleolus and across the medial surface of the distal third of the tibia, and then along the medial margin of the tibia. It enters the area of dissection at present under consideration at the level of the tuberosity of the tibia, passes proximally across the posterior part of the medial aspect of the knee, then further proximally, with an inclination anteriorly and laterally, through the medial region of the thigh, to the fossa ovalis, where it pierces the fascia cribrosa and the femoral sheath, and terminates in the femoral vein. In its course through the thigh it receives tributaries from the anterior and medial regions; the former constitute the lateral femoral circumflex veins and the latter the medial femoral circumflex veins; one of the latter not uncommonly connects the great saphenous vein with the small saphenous vein. Just before it pierces the fascia cribrosa the great saphenous vein is joined by the small veins which correspond with the three superficial arteries of the subinguinal region.

**Nervi Cutanei.**—The cutaneous nerves are now to be looked for in the superficial fascia. The main stems are six in number, and are derived from two sources. *Three* come directly from the *lumbar plexus*, and *three* are branches of the *femoral nerve*:—

From the lumbar plexus,
- Ilio-inguinal nerve.
- Lumbo-inguinal nerve.
- Lateral cutaneous nerve of the thigh.

From the femoral nerve,
- Intermediate cutaneous nerve of the thigh.
- Medial cutaneous nerve of the thigh.
- Saphenous nerve.

**N. Ilio-inguinalis.**—The ilio-inguinal nerve will be found as it escapes from the subcutaneous inguinal ring (O.T. ext. abdominal) in company with the spermatic funiculus. Most

of its branches go either to the scrotum or to the labium majus, but some are distributed to the skin of the adjacent part of the thigh.

**Nervus Lumboinguinalis** (O.T. **Crural branch of Genito-crural**).—The lumbo-inguinal nerve pierces the fascia lata a little way distal to the inguinal ligament, and to the lateral side of the femoral artery. It supplies a limited area of skin on the proximal part of the anterior aspect of the thigh. With a little care a communication between this nerve and the intermediate cutaneous nerve of the thigh may be made out.

**N. Femoris Lateralis** (O.T. **External Cutaneous**).—The lateral cutaneous nerve of the thigh is distributed on the lateral area of the thigh. It pierces the fascia lata in two parts. Of these, one—the *posterior division*—appears about two inches distal to the anterior superior spine of the ilium, and proceeds posteriorly and distally; some twigs of it may be followed to the lower part of the gluteal region. The *anterior division* comes to the surface about two inches more distally. It is the larger of the two, and has a wide area of distribution. It may extend to the knee. Previous to its division the lateral cutaneous nerve of the thigh lies in a prominent ridge of the fascia lata which descends vertically from the anterior superior spine of the ilium. This must be slit up to expose the nerve.

The intermediate and medial cutaneous nerves belong to the "anterior cutaneous branches of the femoral nerve," but for convenience and for the purposes of more precise description, they are defined by special names.

The **intermediate cutaneous nerve of the thigh** (O.T. *middle cutaneous nerve*), a branch of the femoral nerve, pierces the fascia lata in the middle line of the thigh about three or four inches distal to the inguinal ligament. It appears usually as two branches which perforate the fascia at two points a short distance from each other. Both branches extend distally to the knee, which they reach on its medial aspect.

The **medial cutaneous nerve of the thigh** (O.T. *internal cutaneous nerve*), a branch of the femoral nerve, like the lateral cutaneous nerve of the thigh and the intermediate cutaneous nerve, divides into two portions—an anterior and a posterior—which perforate the deep fascia on the medial aspect of the thigh, and at some distance from each other. The *anterior division* makes its appearance through the fascia lata in the distal third of the thigh anterior to the great saphenous vein. It descends toward

the knee, and its terminal branches turn anteriorly and laterally to the anterior aspect of the patella. The *posterior division* reaches the surface on the medial side of the knee, posterior to the great saphenous vein, and proceeds distally to supply the integument on the medial side of the proximal part of the leg. But the main stem of the medial cutaneous nerve, before it divides, also sends a few twigs through the fascia lata to reach the skin on the proximal and medial aspect of the thigh. These make their appearance along the line of the great saphenous vein.

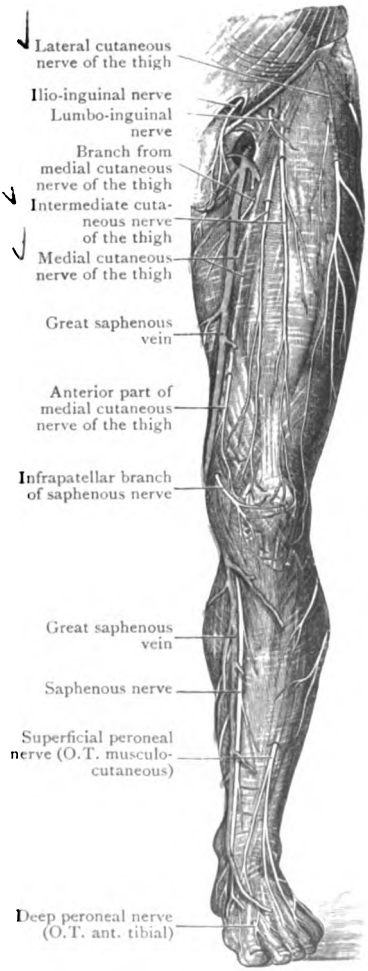
Lateral cutaneous nerve of the thigh
Ilio-inguinal nerve
Lumbo-inguinal nerve
Branch from medial cutaneous nerve of the thigh
Intermediate cutaneous nerve of the thigh
Medial cutaneous nerve of the thigh
Great saphenous vein
Anterior part of medial cutaneous nerve of the thigh
Infrapatellar branch of saphenous nerve
Great saphenous vein
Saphenous nerve
Superficial peroneal nerve (O.T. musculocutaneous)
Deep peroneal nerve (O.T. ant. tibial)

FIG. 66.—Cutaneous Nerves on the Front of the Inferior Extremity.

**N. Saphenus** (O.T. **Long Saphenous**).—The saphenous nerve becomes cutaneous on the medial side of the knee by perforating the fascia between the tendons of the sartorius and gracilis muscles. The guide to it is the saphenous branch of the *a. genu suprema*, which descends alongside of it. It follows the course of the great saphenous vein into the leg. Before it pierces the fascia it gives off an infrapatellar branch.

The *infrapatellar branch* pierces the sartorius muscle and the fascia lata on the medial side of the knee, and turns laterally towards the anterior aspect of the joint, distal to the level of the patella.

**Patellar Plexus.**—Twigs of four of the cutaneous nerves of the thigh have been traced to the skin of the knee, viz., the anterior division of the lateral cutaneous nerve of the thigh, the intermediate cutaneous, the anterior division of the medial cutaneous, and the saphenous nerve. These nerves communicate with each other and form an interlacement which is situated over the patella, the ligamentum patellæ, and proximal part of the tibia. The interlacement is termed the *patellar plexus.*

On the medial side of the thigh two minute cutaneous nerve twigs sometimes make their appearance which do not belong to any of the above main cutaneous trunks. One appears distal to the ilio-inguinal nerve, and is a twig from the perineal branch of the posterior cutaneous nerve of the thigh; the other pierces the deep fascia at the middle of the medial area of the thigh, and comes from the obturator nerve.

*Dissection.*—After the cutaneous nerves have been cleaned the remains of the superficial fascia must be removed in order that the fascia lata may be studied.

**Fascia Lata.**—This is the name which is given to that portion of the general fascial investment of the inferior extremity which clothes the thigh and preserves its figure. The dissector will be struck with the marked difference in strength which it shows on the lateral and medial aspects of the thigh. Laterally, it is so dense and strong that it appears to be more aponeurotic than fascial in its character. The reason of this is that the tensor fasciæ latæ muscle and the greater portion of the glutæus maximus are inserted into it upon this side of the limb. The strong band thus formed goes under the name of the *tractus iliotibialis*, because it is attached proximally to the crest of the ilium, and distally to the lateral condyle of the tibia and to the head of the fibula. It acts as a powerful brace, on the lateral aspect of the limb, which, in the erect posture, helps to steady the pelvis and at the same time keep the knee-joint firmly extended. Medially, the fascia lata is so exceedingly delicate and thin that the subjacent muscular fibres shine through it, and it is very apt to be removed with the superficial fascia unless care is exercised in the dissection.

Proximally, around the root of the limb, the fascia lata is attached to the inguinal ligament and the bones of the pelvis. Thus, *posteriorly*, it is continuous with the gluteal fascia, and through that it is fixed to the coccyx, sacrum, and crest of the ilium. On the *lateral side* it is attached to the crest of the ilium; and on the *medial side*, to the body of the pubis, the

margin of the pubic arch, and to the tuberosity of the ischium. *Anteriorly*, its proximal attachment is complicated by the presence of the fossa ovalis. That aperture separates the fascia lata into a lateral or iliac portion and a medial or pectineal portion, now known as the *fascia pectinea*. The subdivision extends distally only to the distal border of the fossa ovalis. The *iliac portion* is attached along the whole length of the inguinal ligament. Its medial crescentic margin bounds the fossa ovalis laterally and forms its falciform edge. The cornu superius of this edge blends with the lig. lacunare (O.T. Gimbernat's ligament), whilst its inferior cornu joins the pectineal portion of the fascia lata. The *fascia pectinea* clothes the proximal portions of the adductor longus and pectineus muscles. It recedes from the surface as it is traced laterally, passes posterior to the sheath of the femoral vessels, and blends with the pubocapsular ligament of the hip-joint, with the deep intermuscular septa, and with the fascia iliaca, which covers the ilio-psoas muscle. To the medial side of the femoral vessels the fascia pectinea is attached proximally to the ilio-pectineal line of the pubic bone. The *fascia cribrosa*, as previously stated, is to be regarded as a thin piece of the fascia lata, stretched across the fossa ovalis. Laterally, it is continuous with the falciform edge of the iliac portion of the fascia; medially, it blends with the front of the fascia pectinea.

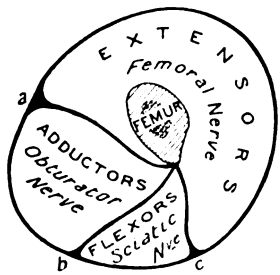


FIG. 67.—Diagram to show the arrangement of the three intermuscular septa and the three osteo-fascial compartments of the thigh. (After Turner.)

*a*. Medial intermuscular septum.
*b*. Posterior intermuscular septum.
*c*. Lateral intermuscular septum.

In the neighbourhood of the knee the fascia lata is continuous posteriorly with the popliteal fascia, whilst on the lateral and anterior aspects of the joint it is attached to the various bony prominences and to the different tendons in that locality, and it helps to strengthen and support the capsules of the knee-joint.

**Septa Intermuscularia (Intermuscular Septa).**—The fascia lata has other offices to perform besides that of forming a continuous investment for the thigh. From every part of

its deep surface processes pass off which penetrate the limb and constitute sheaths for the muscles and other structures which compose it. Three of the processes, which are especially strong, form distinct septa or partitions which reach the femur and are attached to the linea aspera on its posterior aspect. These partitions are termed the intermuscular septa, and are so disposed that they intervene between the three great groups of muscles in this region. The *lateral intermuscular septum* is placed between the extensor muscles in the anterior area of the thigh and the hamstring muscles in the posterior region; the *medial intermuscular septum* intervenes between the extensor muscles and the adductor muscles in the medial region; whilst the *posterior intermuscular septum*, weak and inconspicuous in comparison with the other two, is interposed between the adductor and the hamstring muscles. The three septa partitions will be disclosed in the subsequent dissection. In the meantime, merely note that the medial and the lateral septa show on the surface of the fascia, in the distal part of the thigh, as white lines. By means of the three septa the thigh is divided into three osteo-fascial compartments, viz., an *anterior*, containing the extensor muscles and the femoral nerve; a *posterior*, holding the hamstrings and the sciatic nerve; and a *medial*, for the adductors with the obturator nerve (Fig. 67).

**Bursæ Patellares (Patellar Bursæ).**—Several mucous bursæ are situated in the patellar region. Those which lie superficially may be investigated now, and the more deeply placed bursæ should be examined at later stages of the dissection, as opportunity occurs.

The bursæ are—(1) The *subcutaneous prepatellar bursa*, which lies immediately beneath the skin opposite the distal part of the patella. (2) The *subfascial prepatellar bursa*, situated between the fascia lata superficially and the proximal part of the patella and the adjacent part of the tendon of the quadriceps deeply; this bursa may be displayed by an incision made through the fascia lata in the area indicated. (3) The *subtendinous prepatellar bursa*, lying between the superficial fibres of the tendon of the quadriceps and the periosteum of the anterior surface of the patella. (4) The *suprapatellar bursa*. This lies proximal to the patella, posterior to the tendon of the quadriceps and anterior to the distal part of the anterior surface of the femur; it usually communicates with

the cavity of the knee-joint. (5) The *subcutaneous infrapatellar bursa*, placed directly beneath the skin, anterior to the proximal part of the ligamentum patellæ. (6) The *deep infrapatellar bursa*, which is placed between the ligamentum patellæ and the anterior surface of the proximal part of the tibia. The suprapatellar bursa and the deep infrapatellar bursæ are practically always present, but one or more of the subcutaneous and subfascial bursæ may be absent. Not uncommonly a subfascial and an adjacent subcutaneous bursa may communicate through an aperture in the deep fascia. The subcutaneous bursæ are often destroyed during the reflection of the skin, but the deeper bursæ can usually be found, if looked for carefully, in the situations mentioned above.

### Deep Dissection of the Thigh.

In this dissection the following parts require to be examined:—

1. The femoral sheath.
2. Nervus lumboinguinalis.
3. Nervus cutaneus femoris lateralis.
4. M. sartorius.
5. Nervus femoralis and its rami.
6. Arteria femoralis and its rami.
7. Vena femoralis.
8. M. ilio-psoas.
9. M. quadriceps femoris { M. rectus femoris. / M. vastus lateralis. / M. vastus intermedius. / M. vastus lateralis.
10. M. articularis genu.
11. Tensor fasciæ latæ.
12. Deep part of the tractus ilio-tibialis fasciæ latæ.
13. The intermuscular septa, lateral and medial.

**Ligament Inguinale** (O.T. **Poupart's Ligament) and Ligamentum Lacunare** (O.T. **Gimbernat's Ligament).**—Although, properly speaking, both of these ligaments belong more to the abdominal wall than the thigh, it is essential that the dissector of the inferior extremity should obtain some knowledge of their connections before he proceeds further with his dissection. The *inguinal ligament* is merely the thickened lower border of the aponeurosis of the external oblique muscle of the abdominal wall folded backwards upon itself. Therefore it presents a rounded surface towards the thigh, and a grooved

surface towards the abdomen. By its lateral extremity it is fixed to the anterior superior spine of the ilium. Medially, it has a double attachment, viz.—(1) to the pubic tubercle, (2) through the medium of the lacunar ligament to the medial part of the pecten pubis (O.T. ilio-pectineal line). The inguinal ligament pursues an oblique course between its iliac and pubic attachments, and at the same time describes a gentle curve, the

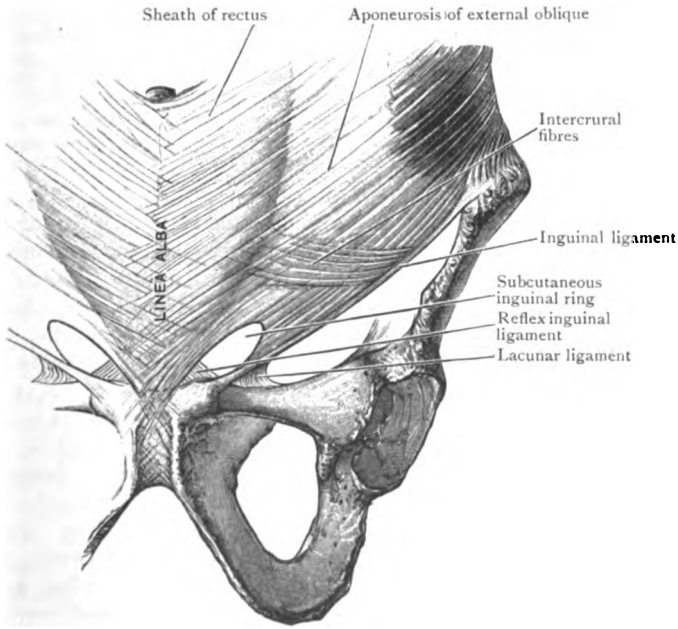


FIG. 68.—Dissection to show the Connections of the Inguinal ligament.

convexity of which is turned distally. By its distal border it affords attachment to the fascia lata, and when that is divided it loses its curved direction.

The *ligamentum lacunare* (O.T. Gimbernat's ligament) is a small triangular piece of aponeurosis which occupies the interval between the medial part of the inguinal ligament and the medial inch of the pecten pubis—being attached by its margins to both. Its base, which looks laterally, is sharp, crescentic, and free, and abuts against the femoral sheath. The lacunar ligament occupies a very oblique plane; its femoral surface

looks distally and laterally, whilst its abdominal surface is directed upwards and medially.

*Dissection.*—The exposure of the femoral sheath is the next step in the dissection of the thigh. To display it the *iliac portion* of the fascia lata must be partially reflected. Divide the superior horn of the lateral crescentic margin of the fossa ovalis, and then carry the knife laterally along the lower border of the inguinal ligament, so as to sever the attachment of the fascia lata to that thickened band. The incision should extend to within an inch of the anterior superior spine of the ilium. The piece of fascia marked out by the incision above, and by the lateral free margin of the fossa ovalis medially, must be carefully raised from the subjacent femoral sheath and thrown distally and laterally. On the removal of a little loose fat, the *femoral sheath* will be brought into view as it enters the thigh under the inguinal ligament. Isolate it carefully from adjacent and surrounding parts, by carrying the handle of the knife gently round it—insinuating the knife first between the sheath and the *inguinal ligament*, then between the sheath and the *lacunar ligament*, which lies medial to it.

**Femoral Sheath.**—The funnel-shaped appearance of the femoral sheath will now be apparent—the wide mouth of the membranous tube being directed upwards into the abdomen, and the narrow distal part gradually closing upon the vessels, and fusing with their coats about the level of the distal limit of the fossa ovalis. Whilst it presents this appearance, however, it should be noticed that its sides do not slope equally towards each other. The lateral border of the sheath is nearly vertical in its direction, whilst the medial wall proceeds very obliquely distally and laterally. If the dissection has been successfully performed, the *lumbo-inguinal nerve* should be seen piercing the lateral wall of the sheath, whilst the great saphenous vein, and some lymph vessels, perforate its anterior and medial walls. Further, if the subject is spare and the fasciæ well marked, the dissector will in all probability notice that the anterior wall of the sheath, in its proximal part, is strengthened by some transverse fibres which pursue an arched course across it. To these fibres the name of *deep femoral arch* is given, in contradistinction to the term *superficial femoral arch*, which is sometimes applied to the inguinal ligament. In favourable circumstances the deep femoral arch may be observed to spring from the deep surface of the inguinal ligament about its middle. After traversing the front of the sheath the band expands somewhat, and is attached by its medial extremity to the ilio-pectineal line or pecten of the pubic bone behind the lacunar ligament.

**Constitution of the Femoral Sheath.**—The source from which the femoral sheath is derived, and the manner in which it is formed, must next be considered. The consideration entails the study of some of the structures concerned in the construction of the abdominal wall, and it is possible that the dissection of the abdomen will not be in a sufficiently advanced state for their examination.

A small portion of the medial part of the interval between the inguinal ligament and the portion of the hip bone over which it stretches is filled up by the lacunar ligament. Immediately to the lateral side of this the femoral vessels, enclosed within the femoral sheath, enter the thigh from the abdominal cavity, whilst still more laterally the interval is occupied by the ilio-psoas muscle. Three nerves also find their way into the thigh through the interval, viz., the lumbo-inguinal nerve, which passes distally in the femoral sheath; the femoral (O.T. anterior crural) nerve, which occupies the interval between the psoas and iliacus muscles; and the lateral cutaneous nerve of the thigh, which runs behind the inguinal ligament, close to its iliac attachment.

The arrangement of the fascial lining of the abdominal cavity, with reference to this interval of communication between abdomen and thigh, also requires attention. The lower part of the posterior wall of the abdomen, immediately above the thigh, is formed by the iliacus and psoas muscles. These are covered by that part of the fascial lining of the abdomen which receives the name of the *fascia iliaca*.[1] The anterior wall of the abdomen is lined, in like manner, by a portion of the general lining, termed the *fascia transversalis*. To the lateral side of the femoral vessels these two fascial layers become continuous with each other, and at the same time are attached to the back of the inguinal ligament. It is behind this union that the ilio-psoas, the femoral nerve, and the lateral cutaneous nerve of the thigh are carried distally into the thigh. But the external iliac vessels (which become the femoral vessels in the thigh), with the lumbo-inguinal nerve, lie anterior to the fascia iliaca, or, in other words, within the fascial lining of the abdomen, and, as they proceed distally

[1] The dissector must bear in mind the distinction between the *fascia iliaca* and the *iliac portion* of the *fascia lata*. The former is a part of the general fascial lining of the abdomen, and the latter is a part of the fascial investment of the thigh.

behind the inguinal ligament, they carry with them a funnel-shaped prolongation of the lining, which is the femoral sheath.

The dissector will now readily understand that the *anterior wall* of the sheath is formed of *fascia transversalis* from the anterior wall of the abdomen above the inguinal ligament, while the *posterior wall* is formed of *fascia iliaca*, prolonged distally, from the posterior abdominal wall.

**Posterior Wall of the Femoral Sheath.**—There are still

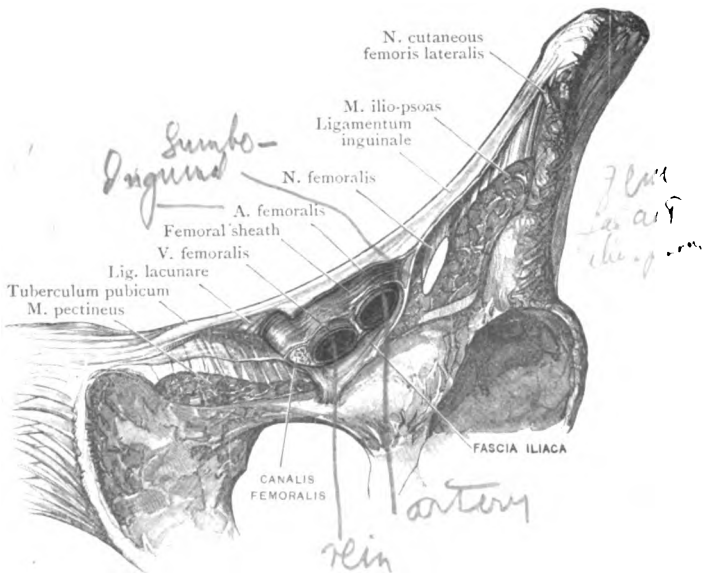


FIG. 69.—Dissection to show the Femoral Sheath and the other Structures which pass between the Inguinal Ligament and the Hip Bone.

some additional facts relating to the posterior wall of the femoral sheath which require to be mentioned. It is formed, as stated above, by the fascia iliaca; but as that enters the thigh it blends with the fascia pectinea, and further, it is firmly fixed in position by certain connections which it establishes in the thigh. Thus, beyond the femoral sheath, it is prolonged laterally over the ilio-psoas muscle; whilst from its posterior aspect a lamina is given off which passes posterior to that muscle and joins the capsule of the hip-joint.

*Dissection.*—The femoral sheath must be opened, in order that the arrangement of parts inside may be displayed. Make three vertical and parallel incisions through the anterior wall—one over the femoral artery, which occupies the lateral part of the sheath, another over the femoral vein, and the third about half an inch medial to the second. The first two should begin at the level of the inguinal ligament, and should extend distally for an inch and a half. The most medial of the three incisions should commence at the same level, but should be carried distally only for half an inch or less.

**Interior of the Femoral Sheath.**—A little dissection will show that the sheath is subdivided by two antero-posterior partitions into three compartments. The femoral artery and lumbo-inguinal nerve occupy the *most lateral compartment*; the femoral vein fills up the *intermediate compartment*; whilst in the *most medial compartment* are lodged a little loose areolar tissue, a small lymph gland, and some lymph vessels. This last compartment, from its relation to femoral hernia, has the special name of *femoral canal* applied to it.

**Canalis Femoralis.**—The boundaries and extent of the femoral canal must be very thoroughly studied. The best way to commence the study is to introduce the little finger into the canal and push it gently upwards. The length of the canal is not nearly so great as that of the other two compartments. Indeed it is not more than half an inch long. Distally it is closed, and it rapidly diminishes in width proximo-distally. Its proximal aperture lies on the lateral side of the base of the lacunar ligament, and is called the *femoral ring*. It is closed by the closely applied extra-peritoneal fatty tissue of the abdominal wall. The parts which immediately surround this opening can be readily detected with the finger: laterally the *femoral vein*, medially the sharp crescentic base of the *lacunar ligament*, anteriorly the *inguinal ligament*, and posteriorly the *pubic bone* covered by the *pectineus muscle*. The portion of the extra-peritoneal fatty tissue which closes the ring is called the *septum femorale*. On the abdominal surface of the septum femorale is the peritoneal lining of the abdominal cavity, and when examined from above both are seen to be slightly depressed into the opening so as to produce the appearance of a dimple.

**Femoral Hernia.**—Femoral hernia is the name applied to a pathological condition which consists in the protrusion of some of the contents of the abdominal cavity into the region of the thigh. In their descent they

pass behind the inguinal ligament into the *femoral canal* or *most medial compartment* of the femoral sheath. The arrangement of the parts which occupy the interval between the hip bone and the inguinal ligament has been carefully considered, and the dissector should therefore be in a position to understand how the occurrence of such a protrusion is possible. To the medial side of the femoral sheath the interval is closed by the lacunar ligament, which, by its strength and firm connections, constitutes an impassable barrier in that locality. To the lateral side of the femoral sheath a hernial protrusion is equally impossible. There the fascia transversalis on the anterior wall of the abdomen becomes continuous with the fascia iliaca on the posterior wall of the abdomen, and along the line of union both are firmly attached to the inguinal ligament.

It is in the region of the femoral sheath, then, that femoral hernia takes place. The three compartments of the sheath open above into the abdominal cavity, but there is an essential difference between the three openings. The two lateral, which hold the artery and the vein, are completely filled up by their contents. The femoral canal, or most medial compartment, is not; it is much wider than is necessary for the passage of the fine lymph vessels which traverse it. Further, its widest part is the upper opening or *femoral ring*. It has been noted that that is wide enough to admit the point of the little finger, and it forms a weak point in the parietes of the abdomen; a source of weakness which is greater in the female than in the male, seeing that in the former the distance between the iliac spine and the pubic tubercle is proportionally greater, and that, in consequence, the femoral ring is wider. Femoral hernia, therefore, is more common in the female.

When attempts are made to reduce a femoral hernia, it is necessary that the course which the protrusion has taken should be kept constantly before the mind of the operator. In the first instance it passes distally for a short distance in a perpendicular direction. It then turns anteriorly and bulges through the fossa ovalis. Should it still continue to enlarge, it bends proximally over the inguinal ligament, and pushes its way laterally towards the anterior superior spine of the ilium. The protrusion is thus bent upon itself, and if it is to be reduced successfully it must be made to retrace its steps. In other words, it must be drawn distally, and then pushed gently posteriorly and proximally. The position of the limb during this procedure must be attended to. When the thigh is fully extended and rotated laterally all the fascial structures in the neighbourhood of the femoral canal are rendered tight and tense. When, on the other hand, the limb is flexed at the hip-joint and rotated medially, the upper horn of the margin of the fossa ovalis, and even the lacunar ligament, are relaxed. That, then, is the position in which the limb should be placed during the reduction of the hernia.

As the hernia descends it carries before it, in the form of coverings, the various layers which it meets. First it pushes before it the peritoneum, and this forms the *hernial sac*. The other coverings from within outwards are—(1) the septum femorale; (2) the wall of the femoral sheath (if it does not burst through one of the apertures in that); (3) the fascia cribrosa; and lastly, (4) the superficial fascia and skin.

The femoral canal, as already noted, is surrounded by very unyielding structures. Strangulation in cases of femoral hernia is therefore of very common occurrence. The sharp base of the lacunar ligament and the superior cornu of the margin of the fossa ovalis are especially apt to bring about this condition.

**Abnormal Obturator Artery.**—The account of the surgical anatomy of femoral hernia cannot be complete without mention of the relation which the obturator artery frequently bears to the femoral ring. In

two out of every five subjects the obturator artery, on one or on both sides, takes origin from the inferior epigastric artery. In these cases it passes posterior to the pubic bone to gain the obturator sulcus in the upper part of the obturator foramen, and according to the point at which it arises from the epigastric trunk, it presents different relations to the femoral ring. In the majority of cases it lies in close contact with the external iliac vein and on the lateral side of the femoral ring. In that position it is in no danger of being wounded in operations undertaken for the relief of a strictured femoral hernia. In about thirty-seven per cent., however, of the

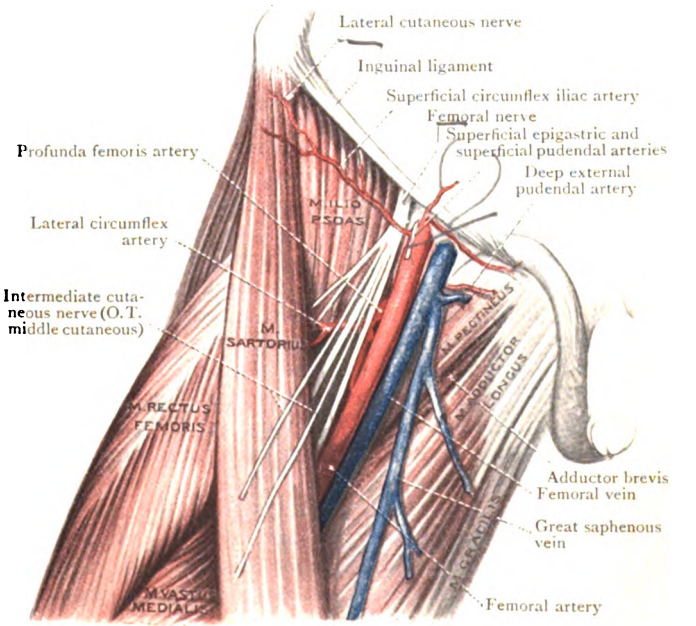


FIG. 70.—Dissection of the Femoral Triangle.

cases in which it exists, the artery is placed less favourably. In these, it either passes medially across the septum femorale, which closes the opening into the femoral canal, or it arches over it and turns posteriorly, on the medial side of the ring, upon the deep aspect of the base of the lacunar ligament. In the latter situation it is in a position of great danger, seeing that it is the base of the lacunar ligament against which the surgeon's knife is generally directed for the relief of strictured femoral hernia.

*Dissection.*—The femoral triangle may now be dissected. To bring its boundaries into view the deep fascia must be removed from the anterior aspect of the proximal third of the thigh; in the distal two-thirds, the

fascia lata should be left undisturbed, so as to maintain, as far as possible, the natural position of the parts.

**Trigonum Femorale** (O.T. **Scarpa's Triangle**).—The *femoral triangle* is the name given to the triangular hollow which lies in the proximal part of the thigh distal to *the inguinal ligament.*

The *lateral boundary* is formed by the *sartorius muscle*, as it runs distally and medially across the thigh from the anterior superior spine of the ilium; the *medial boundary* is constituted by the prominent medial margin of the *adductor longus muscle*, and the two muscles meet below to form the *apex* of the triangle. *The inguinal ligament* forms the *base* of the triangle.

The *contents* of the space must now be displayed by removing the fatty areolar tissue which surrounds them. The *femoral vessels* should first be cleaned. Remove the remains of the femoral sheath and define the various branches which proceed from the vessels in so far as they are seen within the limits of the triangular space. Be careful not to injure the small twig of the femoral nerve which supplies the pectineus; it passes medially, behind the vessels, a short distance distal to the inguinal ligament. Whilst it is in the femoral triangle the femoral artery gives off—(1) the *three superficial inguinal arteries*, which have already been noted ramifying in the superficial fascia of the subinguinal region; (2) the *deep external pudendal artery*, which runs medially over the pectineus; (3) the large *profunda femoris.*

The *profunda femoris artery* springs from the lateral side of the femoral artery, about one and a half inch distal to the inguinal ligament. It inclines distally and medially, behind the femoral trunk, and soon leaves the space by passing posterior to the adductor longus. The *lateral* and *medial circumflex arteries* of the thigh will be seen to arise from the profunda femoris within the femoral triangle.

The *lateral circumflex artery* (O.T. *external circumflex*) should be traced laterally as it passes amongst the branches of the femoral nerve, to disappear under cover of the lateral boundary of the space. The *medial circumflex artery* (O.T. *internal circumflex*) passes from view, shortly after its origin, by sinking posteriorly through the floor of the space, between the pectineus and psoas muscles. The veins corresponding to these arteries must be cleaned at the same time.

Certain nerves also are to be found in this space, viz.—(1)

the *lumbo-inguinal nerve*; (2) the *lateral cutaneous nerve* of the thigh; and (3) the *femoral nerve*. The *lumbo-inguinal nerve* descends in the lateral compartment of the femoral sheath, on the lateral side of the femoral artery. It pierces the lateral wall of the sheath and the fascia lata a short distance distal to the inguinal ligament, and has already been traced to its distribution (p. 175). The *lateral cutaneous nerve* of the thigh passes into the thigh behind the inguinal ligament, close to the anterior superior spine of the ilium. It soon leaves the femoral triangle by crossing the sartorius and piercing the fascia lata. It has already been traced in its ramifications in the superficial fascia on the lateral aspect of the thigh. The *femoral nerve* will be detected, lying deeply, in the interval between the psoas and iliacus muscles, about a quarter of an inch to the lateral side of the femoral artery. Insinuate the handle of a knife under the main trunk, so as to raise it above the level of the muscles between which it lies, and render it tense, and then follow the numerous branches, into which it breaks up, as far as the limits of the space will allow. The small twig to the pectineus muscle must be looked for first. It passes medially, posterior to the femoral vessels.

The *floor* of the femoral triangle slopes posteriorly both from the medial and the lateral boundaries of the space. To the medial side of the femoral artery it is formed by the *adductor longus* and the *pectineus*; in some cases a small portion of the *adductor brevis* may be seen in a narrow interval between those two muscles. To the lateral side of the artery are the *psoas* and *iliacus*. The adductor longus is placed in an oblique plane, the medial border being nearer the surface than the lateral border; and thus it is that that muscle not only forms the medial boundary of the triangle, but also takes part in the formation of the floor. The muscles mentioned should be cleaned in so far as they stand in relation to the femoral triangle.

When a transverse section is made through the frozen thigh, in the region of the femoral triangle, the space has the appearance of a deep intermuscular furrow, bounded on the medial side by the adductor longus and pectineus, and on the lateral side by the sartorius and rectus femoris, whilst posteriorly it is separated from the bone by the ilio-psoas. The femoral vessels and the femoral nerve pass distally in the furrow—the profunda femoris artery being placed very deeply, whilst the femoral artery lies nearer to the surface.

**Arteria Femoralis** (O.T. **Femoral Artery, Common and Superficial**).—The femoral artery, the great arterial trunk of the inferior extremity, is the direct continuation of the external iliac. It begins at the inguinal ligament, behind which it enters the thigh, and it extends distally to the opening in the adductor magnus, through which it gains the fossa poplitea and becomes the popliteal artery. The opening in the adductor magnus is situated in the distal third of the medial region of the thigh; and the course which the vessel pursues may be marked on the surface, when the thigh is slightly abducted, flexed and rotated laterally, by an oblique line drawn to the medial condyle of the femur from a point midway between the anterior superior spine of the ilium and the symphysis pubis.

The relations which the artery bears to the femur are important. As it enters the femoral triangle it leaves the brim of the pelvis and lies in front of the medial part of the head of the femur, from which it is separated by the psoas muscle. Although its relation to the head of the femur is fairly intimate, that situation should not be chosen for applying compression, for, on account of the mobility of the head of the bone, the vessel is apt to slip from under the fingers. It is much safer to compress it against the brim of the pelvis. Distal to the head of the femur, during the remainder of its course through the femoral triangle, the artery is not in direct relation to the bone. It crosses anterior to the angular interval between the neck and body of the femur. Towards the apex of the triangle, however, it comes into relation with the medial side of the body of the femur, and this position it holds to its termination.

In the present condition of the dissection it is only that part of the femoral artery which traverses the femoral triangle which comes under the notice of the dissector. The length of the part in question varies with the development of the sartorius muscle, and the degree of obliquity with which this crosses the front of the thigh. It measures, usually, from three to four inches in length, and is comparatively superficial. At the apex of the triangle the femoral artery disappears under cover of the sartorius and takes up a deeper position in the limb.

In the femoral triangle the femoral artery is enveloped, in its proximal part, by the femoral sheath, and is separated from the surface by the skin, superficial fascia, and deep fascia; whilst

more distally it is crossed by the medial cutaneous branch (O.T. internal cutaneous) of the femoral nerve, which runs along the medial border of the sartorius muscle. Posterior to the artery are the psoas and pectineus, but it is separated from the psoas by the femoral sheath and the nerve to the pectineus, and from the pectineus by fatty areolar tissue in which lie the profunda femoris artery and the femoral vein. Upon *the lateral side* of the femoral artery is the femoral nerve—but not in apposition with it, as a small portion of the psoas intervenes. The *femoral vein* changes its position with reference to the artery, as it is traced distally. In the proximal part of the space it lies on the same plane and to the medial side of the artery, but distally it becomes more deeply placed and gradually assumes a position posterior to the artery.

The *branches* which the femoral artery gives off in the femoral triangle have already been enumerated (p. 188). One of these, viz., the deep external pudendal, may now be traced to its destination.

**Arteria Pudenda Externa Profunda.** — The deep external pudendal artery is a small twig which arises from the medial side of the femoral, distal to the inguinal ligament. It extends medially, upon the pectineus and adductor longus muscles, and, piercing the fascia lata, ends, according to the sex, in the integument of the scrotum or of the labium pudendi.

*Dissection.*—The fascia lata may now be removed from the distal two-thirds of the anterior and medial parts of the thigh. This can best be effected by dividing it along the middle line of the limb, and throwing it laterally and medially. Preserve undisturbed the thickened band of fascia (tractus ilio-tibialis) on the lateral side of the thigh.

While the sartorius muscle is being cleaned several nerves of the thigh will be found intimately related to it, and must be carefully dissected. The intermediate cutaneous nerve of the thigh (O.T. middle cutaneous) frequently pierces its proximal border, and then proceeds distally anterior to it; the anterior branch of the medial cutaneous nerve of the thigh crosses it more distally, whilst the posterior branch of the same nerve is carried distally along its posterior border. Near the knee it lies superficial to the saphenous nerve, which ultimately comes to the surface between it and the gracilis. A short distance more proximally the sartorius is pierced by the infrapatellar branch of the saphenous nerve. Lastly, about the middle of the thigh, there is formed, under cover of the sartorius, an interlacement of fine nerve twigs derived from the posterior branch of the medial cutaneous nerve, the saphenous nerve, and the obturator nerve. When the sartorius is raised from subjacent parts this plexus must be looked for.

The different portions of the quadriceps extensor muscle also must be cleaned; and the branches which the femoral nerve gives to them, and

the descending branch of the lateral circumflex artery, must be traced to their terminations.

**M. Sartorius.** — The sartorius is a long slender muscle, which arises from the anterior superior spine of the ilium and

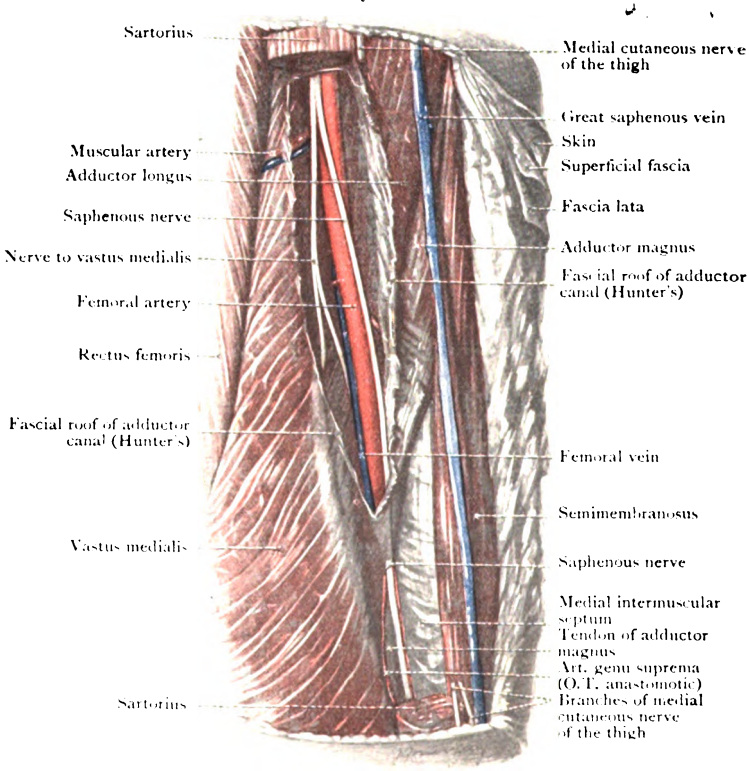


FIG. 71. — Dissection of the Adductor Canal (Hunter's) in the right lower limb. A portion of the Sartorius has been removed.

the upper part of the notch on the anterior border of the bone immediately below. It crosses the front of the proximal third of the thigh obliquely, and, gaining the medial side of the limb, it takes a nearly straight course distally to a point beyond the medial prominence of the knee. There it turns forwards, and ends in a thin, expanded aponeurotic tendon, which is

inserted into the medial surface of the body of the tibia, posterior to the tuberosity (Fig. 92, p. 248). By its distal border this tendon is connected with the fascia of the leg, whilst by its proximal border it is joined to the capsule of the knee-joint.

In its proximal, oblique part, the sartorius muscle forms the lateral boundary of the femoral triangle, and lies anterior to the iliacus, the rectus femoris, and the adductor longus muscles. More distally, it is placed anterior to the femoral vessels as far as the opening in the adductor magnus. At its insertion its expanded tendon lies anterior and superficial to the tendons of

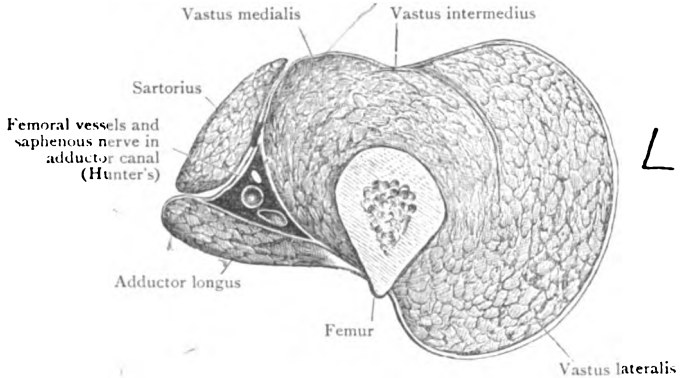


FIG. 72.—Transverse Section through the Adductor Canal.

insertion of the gracilis and semitendinosus, but is separated from them by a bursa. The sartorius is supplied by the anterior division of the *femoral nerve.*

**Canalis Adductorius Hunteri** (O.T. **Hunter's Canal**).—When the femoral artery leaves the femoral triangle it is continued distally, in the medial region of the thigh, in a deep furrow, which is bounded anteriorly by the vastus medialis muscle, and posteriorly by the adductor muscles. At its proximal end this furrow is continuous with the deeper, wider, and more apparent hollow, which has been described as the femoral triangle. Further, the furrow is converted into a canal, triangular on transverse section, by a strong fibrous membrane which stretches across it, and upon the surface of which the sartorius muscle is placed (Fig. 72). The tunnel

thus formed is called the *adductor canal* (O.T. Hunter's Canal). The fibrous expansion which roofs in the canal stretches from the adductor longus and the adductor magnus posteriorly to the vastus medialis anteriorly. When it is traced proximally, it is seen to become thin and ill-defined as it approaches the femoral triangle; when traced in the opposite direction, however, it becomes dense and strong, and opposite the opening in the adductor magnus, at the distal end of the canal, it presents a thick, sharply defined margin. In its distal part the

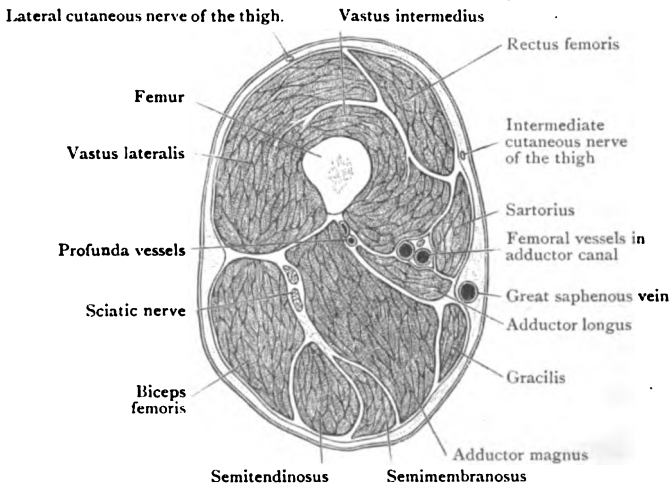


FIG. 73.—Transverse Section through the Middle of the Thigh. The relationship of the parts in Adductor Canal (Hunter's) is seen.

posterior wall of the canal, where it is formed by the adductor magnus, presents a deficiency or aperture which leads backwards into the popliteal fossa. The appearance and construction of this aperture will be studied at a later stage. It is called *the hiatus tendineus* or *opening in the adductor magnus.*

The femoral vessels and the saphenous nerve traverse the adductor canal. Whilst it is in the canal the femoral artery gives off some muscular twigs and the arteria genu suprema. The femoral vessels leave the canal at its distal end by inclining posteriorly through the opening in the adductor magnus and entering the popliteal fossa. The saphenous nerve, accompanied by the saphenous branch of the arteria genu

suprema, escape from the canal by passing under cover of the distal thickened margin of the fibrous expansion which forms the roof. They can be seen in the present stage of the dissection in that situation.

*Dissection.*—The fibrous expansion which is stretched across the adductor canal, under cover of the sartorius muscle, should now be divided, in order that the arrangement of the parts within the canal may be studied.

**Distal Portion of the Femoral Artery.**—The entire length of the femoral artery is now exposed. At the apex of the femoral triangle it enters the adductor canal, and is separated from the medial surface of the thigh by the fibrous expansion which closes the canal, the sartorius muscle, the fascia lata, and the integument. The saphenous nerve crosses anterior to the artery from the lateral to the medial side. Proximo-distally the artery rests upon the pectineus, the adductor brevis, the adductor longus, and the adductor magnus. Its proximal part, however, is separated from those muscles by the femoral vein, which lies posterior to it; more distally, the vein, which inclines laterally, comes to lie on its lateral side, on a posterior plane. The relation of parts in the adductor canal is seen in Figs. 71, 72, and 73.

From the femoral artery, as it traverses Hunter's canal, proceed muscular twigs and the arteria genu suprema.

The *muscular branches* are irregular in number and in their mode of origin. They supply the vastus medialis, the adductor longus, and the sartorius.

**Arteria Genu Suprema** (O.T. **Anastomotic**).—The arteria genu suprema springs from the femoral trunk a short distance proximal to the point where it enters the popliteal fossa by passing through the opening in the adductor magnus. The artery almost immediately divides into a saphenous and an articular branch: very frequently, indeed, these branches take separate origin from the femoral artery.

The *saphenous branch* accompanies the saphenous nerve, and leaves the adductor canal by passing under cover of the distal border of the fibrous expansion which is stretched over the canal. On the medial side of the knee it appears between the gracilis and sartorius, and it ends in branches to the integument on the medial aspect of the proximal part of the leg.

The *articular branch* enters the substance of the vastus

medialis and proceeds distally, anterior to the tendon of the adductor magnus. It gives some twigs to the vastus medialis and others which spread out over the proximal and medial aspects of the knee-joint, and it anastomoses with branches of the medial genicular arteries. One well-marked branch runs laterally, proximal to the patella, to anastomose with the lateral superior genicular artery.

**Vena Femoralis.**—The femoral vein is the direct proximal continuation of the popliteal vein. It begins at the opening in the adductor magnus, through which it enters the adductor canal, whilst proximally it passes behind the inguinal ligament and becomes continuous with the external iliac vein. It accompanies the femoral artery, but the relations of the two vessels to each other differ at different stages of their course. In the distal part of the adductor canal the vein lies posterior to the artery and on its lateral side, but it inclines medially as it ascends, and in the proximal part of the thigh it lies on its medial side of the artery and on the same plane. The crossing from one side to the other takes place posterior to the artery and is very gradual, so that for a considerable distance the femoral vein lies directly posterior to the femoral artery. For a distance of two inches distal to the inguinal ligament it is enclosed within the femoral sheath, of which it occupies the intermediate compartment.

As it ascends in the thigh the femoral vein receives tributaries which, for the most part, correspond with the branches of the femoral artery. At the fossa ovalis it is joined by the great saphenous vein. The dissector should slit the femoral vein open with the scissors. Several valves will then be seen. One is almost invariably found immediately proximal to the entrance of the vein which corresponds to the profunda artery.

**Nervus Femoralis** (O.T. **Anterior Crural**).—The femoral nerve is a large nerve which arises, within the abdomen, from the lumbar plexus. It enters the thigh by passing distally in the interval between the psoas and iliacus muscles, posterior to the inguinal ligament and the fascia iliaca. In the proximal part of the thigh it lies to the lateral side of the femoral artery, and is separated from it by a small portion of the psoas muscle and the femoral sheath. A short distance below the inguinal ligament it divides into an anterior and a posterior portion, which at once resolve themselves into a

large number of cutaneous and muscular branches. The following is a list of these:—

| | | |
|---|---|---|
| Anterior division, | Rami musculares, | To the pectineus. |
| | | ,, sartorius. |
| | Rami cutanei anteriores, | Intermediate cutaneous nerve of the thigh. |
| | | Medial cutaneous nerve of the thigh. |
| Posterior division, | Rami musculares, | To the rectus femoris. |
| | | ,, vastus medialis. |
| | | ,, vastus lateralis. |
| | | ,, vastus intermedius. |
| | | ,, m. articularis genu. |
| | Ramus cutaneus, | Saphenous nerve |
| | Rami articulares. | |

With the exception of the saphenous nerve, which is distributed upon the medial side of the leg and foot, the distribution of the cutaneous branches of the femoral nerve has been already examined (p. 175).

The *nerve to the pectineus* arises a short distance distal to the inguinal ligament and turns medially, posterior to the femoral vessels, to reach its destination. The *branches to the sartorius* are two or three in number. As a rule, they take origin by a common trunk with the intermediate cutaneous nerve.

The *intermediate cutaneous nerve* (O.T. *middle cutaneous*) sometimes pierces the proximal border of the sartorius. It divides into two branches which perforate the fascia lata about three or four inches distal to the inguinal ligament.

The *medial cutaneous nerve* (O.T. *internal cutaneous*) inclines distally and medially, crosses anterior to the femoral artery, and divides into an anterior and a posterior portion, which become superficial at different levels on the medial side of the limb. From the trunk of the nerve a few cutaneous twigs are given to the skin over the proximal and medial parts of the thigh. The *anterior branch* crosses the sartorius muscle and makes its appearance through the fascia lata in the distal part of the thigh, a short distance anterior to the great saphenous vein. The *posterior branch* runs distally, along the posterior border of the sartorius, and pierces the deep fascia on the medial side of the knee, behind the sartorius and the saphenous nerve.

A short distance distal to the middle of the thigh the posterior branch of

the medial cutaneous nerve forms, with filaments from the obturator nerve and the saphenous nerve, a plexiform interlacement, the *sartorial plexus*, which is placed deep to the sartorius muscle as it lies over the adductor canal (Hunter's). The twig from the obturator nerve appears at the medial border of the adductor longus.

The *saphenous nerve* (O.T. *internal saphenous nerve*) is the longest branch of the femoral nerve. It springs from the posterior division of that nerve and runs distally on the lateral side of the femoral artery. Entering the adductor canal, with the femoral vessels, it comes to lie anterior to the artery. At the distal end of the canal it emerges, by passing under cover of the thickened border of the fibrous expansion which stretches between the vastus medialis and the adductor muscles, and, accompanied by the saphenous branch of the arteria genu suprema, it escapes from under cover of the sartorius and pierces the deep fascia at the medial side of the knee. It gives off the *infrapatellar branch* after it quits the adductor canal. This branch pierces the sartorius and appears on the surface of the fascia lata on the medial side of the knee.

Several large branches of the posterior part of the femoral nerve enter the four segments which compose the great quadriceps extensor muscle of the thigh. From certain of these, articular filaments are given to the hip and knee-joints.

The *branch to the rectus femoris* sinks into the deep surface of that muscle. It supplies an articular twig to the hip-joint. The large *branch to the vastus medialis* accompanies the saphenous nerve and enters the proximal part of the adductor canal. It can readily be distinguished, because it sinks into the medial aspect of the vastus medialis, about the middle of the thigh. In the substance of the muscle it extends distally, and near the knee joins the articular branch of the arteria genu suprema. It gives an articular nerve to the synovial layer of the knee-joint. The *nerve to the vastus lateralis* is associated with the descending branch of the lateral circumflex artery. Very frequently it gives an articular twig to the knee-joint. The *nerves to the vastus intermedius* are two or three in number, and they sink into its anterior surface. The most medial of them is a long slender nerve, which can be traced distally, under the anterior border of the vastus medialis, to the articular muscle of the knee. Its terminal twigs are given to the synovial stratum of the knee-joint.

Thus, one filament from the femoral nerve goes to the

hip-joint; two, and frequently three, filaments go to the knee-joint.

**Tractus Ilio-tibialis of the Fascia Lata** (O.T. **Ilio-tibial Band**).—The thick band of fascia lata on the lateral aspect of the thigh which receives this name should now be examined, and its connections ascertained. It has been preserved for that purpose. Distally it is attached to the lateral condyle of the tibia and to the head of the fibula. On tracing it proximally, on the lateral surface of the vastus lateralis, it will be observed to split, at the junction of the middle and proximal thirds of the thigh, into two lamellæ —a superficial and a deep. The tensor fasciæ latæ is enclosed between these layers, and when they are disengaged from its surfaces the muscle will be seen to be inserted into the fascia at the angle of splitting. The *superficial lamina* of the ilio-tibial tract is attached above to the crest of the ilium, and is continuous posteriorly with the gluteal fascia, where this covers the glutæus medius. The *deep lamina* can be followed proximally, on the lateral surface of the rectus femoris, to the capsule of the hip-joint, with the proximal and lateral part of which it blends. It is also connected with the reflected tendon of the rectus femoris. This layer is perforated by the ascending twigs of the lateral circumflex artery of the thigh.

**M. Tensor Fasciæ Latæ** (O.T. **Tensor Fasciæ Femoris**).—This is a small muscle which is placed on the lateral and anterior aspect of the proximal third of the thigh. It lies between the two lamellæ of the ilio-tibial tract, in the interval between the sartorius muscle anteriorly and the glutæus medius muscle posteriorly. When the muscle is turned laterally so as to display its deep surface, a little dissection will bring into view its nerve of supply, which springs from the *superior gluteal nerve*. A few arterial twigs from the lateral circumflex artery also sink into its deep surface.

The *tensor fasciæ latæ* arises from a small portion of the anterior part of the outer lip of the crest of the ilium; from the upper part of the margin of the notch below the anterior superior spine of the ilium; and by some fibres from the fascia covering the glutæus medius. It extends distally, with a slight inclination posteriorly, and is inserted into the *ilio-tibial tract of the fascia lata* at its angle of splitting.

**Arteria Circumflexa Femoris Lateralis** (O.T. **External**

**Circumflex Artery**).—The lateral circumflex artery is the largest branch which proceeds from the profunda femoris artery. It arises near the origin of the latter, and runs laterally, between the divisions of the femoral nerve and under cover of the sartorius and rectus femoris muscles. It ends by dividing into ascending, transverse, and descending branches.

The *ascending branch* reaches the dorsum ilii by passing

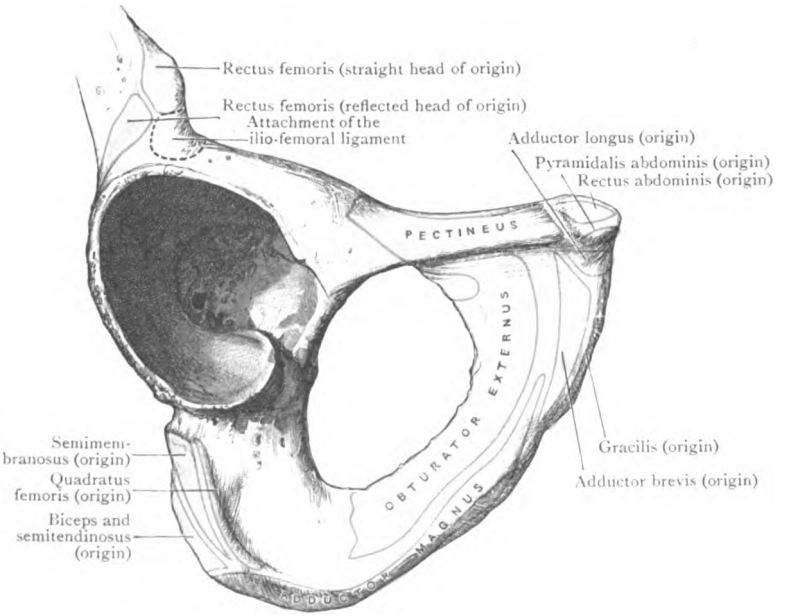


FIG. 74.—External Surface of the Pubis and Ischium, with the Attachments of Muscles mapped out.

proximally under cover of the tensor fasciæ latæ. Its terminal twigs anastomose with the superior gluteal artery. The *transverse branch* is of small size. It passes to the deep surface of the vastus lateralis, reaches the posterior part of the thigh, and inosculates with the medial circumflex artery and the first perforating artery. The *descending branch* gives twigs to the vastus intermedius and rectus femoris, and one long branch, which may be traced distally, amid the fibres of the vastus lateralis, to the knee, where it anastomoses with the lateral superior genicular artery.

**Intermuscular Septa.**—Divide the ilio-tibial tract of the fascia lata distal to the point at which it splits to enclose the tensor fasciæ latæ. This is done so as to obtain a better view of the vastus lateralis, and in order to demonstrate satisfactorily the lateral intermuscular septum. Take hold of the distal portion of the ilio-tibial tract and draw it forcibly laterally; at the same time push medially the vastus lateralis muscle, and a strong fibrous septum will be seen passing medially from the fascia lata towards the linea aspera. This is the *lateral intermuscular septum* of the thigh, a partition interposed between the vastus lateralis and the short head of the biceps femoris. Follow it proximally and distally with the finger. The fibres of the vastus lateralis are seen arising from it, but little difficulty will be experienced in making out its attachment to the linea aspera and lateral supracondylar ridge of the femur. It extends in a proximal direction as far as the insertion of the glutæus maximus, whilst distally it reaches the lateral condyle of the femur. Immediately proximal to the lateral condyle of the femur it is pierced by the *lateral superior genicular artery* and *nerve*. The *medial intermuscular septum* is interposed between the adductors and the vastus medialis, and should also be examined. It is thin in comparison with the lateral septum.

**M. Quadriceps Femoris.**—The quadriceps femoris muscle is composed of four portions: the rectus femoris, which is placed in the anterior part of the thigh, and is quite distinct from the others, except at its insertion; the vastus lateralis, the vastus intermedius, and the vastus medialis, which clothe the body of the femur on its lateral, anterior, and medial aspects, and are more or less blended with each other.

**M. Rectus Femoris.**—The rectus femoris muscle arises by two tendinous heads of origin, which may be exposed by dissecting deeply in the interval between the iliacus and tensor of the fascia lata. The *anterior* or *straight head* springs from the anterior inferior spine of the ilium (Fig. 74, p. 200); the *posterior* or *reflected head* arises, under cover of the glutæus minimus, from a marked impression on the lateral surface of the ilium, immediately above the upper part of the rim of the acetabulum (Fig. 74, p. 200). It is connected both with the capsule of the hip-joint and the deep lamina of the ilio-tibial tract of the fascia lata.

At the present stage of dissection it is possible to display only the

anterior part of this head; the posterior part will be seen in the dissection of the gluteal region.

The two heads of origin of the rectus femoris join at a right angle, immediately beyond the margin of the acetabulum, and form a strong, flattened tendon, which gives place to a fusiform, fleshy belly. The tendon of origin spreads out on the anterior surface of the proximal part of the muscle in the form of an aponeurosis. About three inches proximal to the knee-joint the rectus femoris ends in a strong tendon of insertion, which is prolonged for some distance proximally, on its deep surface, in the form of an aponeurosis. As it nears the patella this tendon is joined by the other tendons of the quadriceps, and through the medium of a common tendon finds insertion into the proximal border of that bone. The rectus femoris is supplied by the *femoral nerve*.

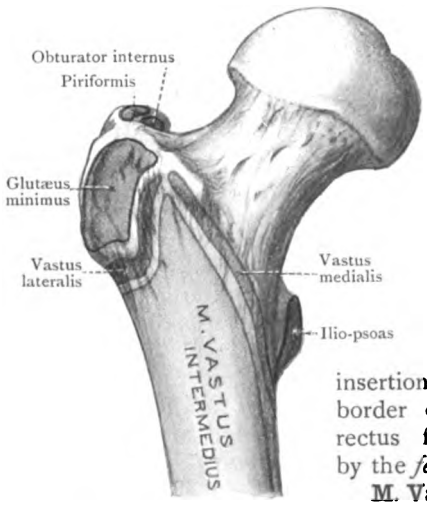


FIG. 75.—Anterior Aspect of Proximal Portion of Femur with Attachments of Muscles mapped out.

**M. Vastus Lateralis** (O.T. **Vastus Externus**) forms the prominent muscular mass on the lateral side of the thigh. Its surface is covered by a glistening aponeurosis. The descending branch of the lateral circumflex artery constitutes the best guide to its anterior border, and when this margin is raised it will be seen that the muscle lies upon, and is partially blended with, the vastus intermedius.

The vastus lateralis arises—(1) from the proximal part of the intertrochanteric line; (2) from the front of the trochanter major, distal to the insertion of the glutæus minimus; (3) from the root of the trochanter major distal to the insertion of the glutæus medius; (4) from the lateral part of the gluteal tuberosity, anterior to the insertion of the glutæus

maximus; (5) from the proximal part of the linea aspera; and (6) from the lateral intermuscular septum. The fleshy fibres are for the most part directed distally and anteriorly. By means of the common tendon of insertion the muscle gains attachment to the patella and, at the same time, gives an expansion to the capsule of the knee-joint. It is supplied by the *femoral nerve.*

**M. Vastus Medialis** (O.T. **Vastus Internus**).—The vastus medialis is intimately connected with the vastus intermedius, but not to such an extent as might be inferred from a superficial inspection. In its proximal part the anterior border, which is fleshy, is either contiguous to or blended with the intermedius; distally, the anterior border is tendinous and overlaps the intermedius, but it is not, as a rule, fused with it.

"A line drawn from the middle of the intertrochanteric line distally and slightly laterally to the middle of the proximal border of the patella will define accurately the thick anterior border of the vastus medialis."—(Williams.)

*Dissection.*—Divide the rectus femoris about its middle, and pull the distal part forcibly towards the foot. The narrow interval between the tendons of the vastus intermedius and vastus medialis will then become apparent, and may be followed in a proximal direction. Another guide is the long, slender nerve of supply to the articular muscle of the knee; it runs along the medial edge of the vastus intermedius. When the anterior border of the vastus medialis is raised from the vastus intermedius the medial surface of the body of the femur will be seen to be perfectly bare. No muscular fibres arise from this bony surface. The fleshy mass of the vastus medialis may now, with advantage, be divided transversely about two inches proximal to the patella. The muscle can then be thrown medially, and its origin studied.

The vastus medialis arises—(1) from the distal part of the intertrochanteric line; (2) from the line leading from that, distal to the trochanter minor, to the linea aspera; (3) from the medial lip of the linea aspera; (4) from the proximal part of the medial supracondylar line as far distally as the opening in the adductor magnus; (5) from the rounded tendon of the adductor magnus. The fleshy fibres are directed distally and anteriorly, and end in the common tendon of the quadriceps muscle, which is inserted into the patella, and becomes connected with the capsule of the knee-joint. It is supplied by the *femoral nerve.*

**M. Vastus Intermedius** (O.T. **Crureus**).—The vastus intermedius covers the anterior and lateral aspects of the body of the femur, from both of which, as well as from the distal

part of the lateral intermuscular septum, it takes origin. It is inserted into the patella through the medium of the common tendon. It is supplied by the *femoral nerve.*

**Common Tendon of the Quadriceps.**—It should now be noticed that the common tendon of the quadriceps muscle closes the knee-joint proximal to the patella. It is inserted into the proximal border of that bone, and is intimately connected with the capsule of the knee-joint. Some fibres are carried distally into the ligamentum patellæ across the surface of the patella. A pouch of the synovial stratum is prolonged proximally beyond the level of the patella, between the quadriceps and the bone. Into the wall of this pouch the articular muscle of the knee is inserted.

*Dissection.*—The vastus intermedius should be divided in a vertical direction, so as to bring the little articular muscle into view, and at the same time the long, slender nerve-filament which runs along the medial border of the vastus intermedius may be traced to the muscle and the synovial stratum of the knee-joint.

The *ligamentum patellæ*, which connects the patella with the tuberosity of the tibia, and through which the quadriceps is attached to that bone, will be studied in connection with the knee-joint.

The whole of the quadriceps femoris is an extensor of the knee, and the rectus portion is also a flexor of the hip-joint.

## MEDIAL SIDE OF THE THIGH.

The group of adductor muscles on the medial aspect of the thigh, together with the blood-vessels and nerves associated with them, must next be dissected. In this dissection the following are the structures which are displayed:—

| | |
|---|---|
| Muscles, | Pectineus.<br>Adductor longus.<br>Adductor brevis.<br>Adductor magnus.<br>Gracilis.<br>Obturator externus. |
| Arteries, | Profunda femoris (and its branches).<br>Obturator. |
| Nerves, | The two divisions of the obturator nerve.<br>The accessory obturator nerve, when present. |

The adductor muscles are disposed in three strata. The *anterior stratum* is formed by the adductor longus and the pectineus, which lie in the same plane. Proximally they are placed side by side, but distally, as they approach their insertions, they are separated from each other by a narrow interval. The *second stratum* is formed by the adductor brevis; and the *third*, or *posterior layer*, by the adductor magnus. The gracilis muscle, also an adductor, extends along the medial aspect of the thigh. It is a long, strap-like muscle, applied against the adductor brevis and adductor magnus. Interposed between these muscular layers, are the two divisions of the *obturator nerve*. The *anterior division* is placed between the anterior and middle layers, whilst the *posterior division* lies between the middle and posterior layers. In other words, the two divisions of the nerve are separated from each other by the adductor brevis, which intervenes between them. At the distal border of the adductor longus, a fine branch from the anterior division of the nerve makes its appearance to take part in the formation of the sub-sartorial nerve plexus already dissected. The profunda artery and its branches also are to be followed. For a part of its course this vessel is placed between the anterior and middle muscular strata.

**M. Adductor Longus.**—The adductor longus muscle is placed on the medial side of the pectineus. It is somewhat triangular in shape, being narrow at its origin and expanded at its insertion. It arises by a short, but strong, tendon from the anterior surface of the body of the pubis, immediately below the pubic crest (Fig. 74, p. 200), and it is inserted into the medial lip of the linea aspera of the femur by a thin, tendinous expansion. It is supplied by the *anterior division* of the *obturator nerve*.

*Dissection.*—The adductor longus may now be reflected. Divide it close to the tendon of origin, and throw it laterally. In doing this be careful of the anterior division of the obturator nerve, which lies posterior to it, and gives to it its nerve of supply. On approaching the linea aspera of the femur its aponeurotic tendon will be found intimately connected with the vastus medialis anteriorly and with the adductor magnus posteriorly. Separate it from these, as far as possible, in order that the profunda femoris vessels may be fully displayed as they proceed behind it.

**Art. Profunda Femoris.**—This large vessel is the chief artery of supply to the muscles of the thigh. It arises in the femoral triangle, from the lateral and posterior aspect of the femoral artery, about an inch and a half distal to the inguinal

ligament. At first it is placed on the iliacus, but, as it proceeds distally, it inclines medially, and thus it crosses posterior to the femoral artery, and comes to lie on the pectineus. Reaching the lateral border of the adductor longus, it passes posterior to that muscle, and is continued distally, close to the body of the femur, in front of the adductor brevis and adductor magnus. Numerous large branches spring from the profunda

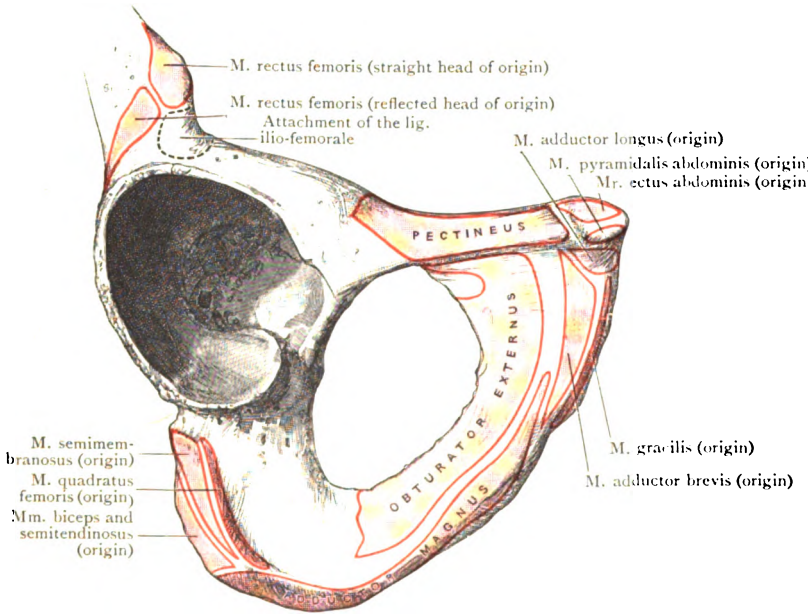


FIG. 76.—External Surface of the Os Pubis and Ischium, with Attachments of Muscles mapped out.

femoris, so that it rapidly diminishes in size. Ultimately it is reduced to a fine terminal twig, which turns posteriorly through the adductor magnus, and receives the name of the *fourth perforating artery*. The following are the relations of the profunda femoris:—(1) It lies anterior to the iliacus, on the lateral side of the femoral artery. (2) It is anterior to the pectineus and posterior to the femoral artery, but separated from it by the femoral vein and the profunda femoris vein. (3) It is anterior to the adductor brevis, and, more distally, to the adductor magnus, and it is posterior to the

adductor longus, which separates it from the femoral artery. (4) The terminal twig, called the fourth perforating artery, pierces the adductor magnus at the junction of the middle and distal thirds of the thigh.

The *branches* which spring from the profunda femoris are: — the two circumflex arteries, the four perforating arteries, and some muscular branches.

The *lateral circumflex artery* arises from the lateral aspect of the profunda, close to its origin. It has already been followed to its distribution (p. 199). The *medial circumflex artery*, which takes origin at the same level, but from the medial and posterior aspect of the profunda, will be studied when the pectineus muscle is reflected. The medial circumflex artery frequently arises from the femoral trunk. The *muscular branches* are irregular both in origin and size. They supply the adductor muscles, and give twigs which pierce the adductor magnus to reach the ham-string muscles.

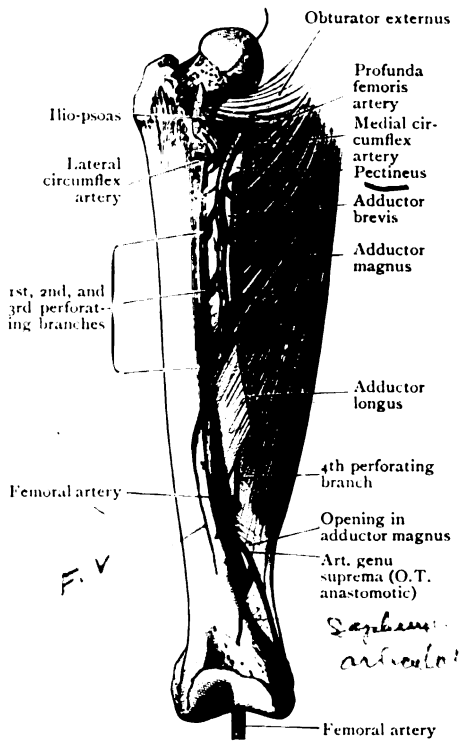


FIG. 77.—The Profunda Femoris Artery and its Branches.

**Arteriæ Perforantes.**—The perforating arteries arise in series from the profunda femoris, and pass posteriorly through the adductor muscles to the posterior region of the thigh. They may be recognised from the close relation which they bear to the linea aspera of the femur. The *first perforating artery* comes off at the level of the distal or medial border of

the pectineus. It proceeds posteriorly through the adductor brevis and adductor magnus. The *second perforating artery* takes origin a short distance distal to the first perforating, or perhaps by a common trunk with it. It pierces the same muscles, viz., the adductor brevis and adductor magnus. The *third perforating artery* springs from the profunda, distal to the adductor brevis, and passes posteriorly through the adductor magnus. The *fourth perforating artery*, as before noted, is the terminal branch of the profunda femoris; it pierces the adductor magnus alone.

The *superior nutrient artery* of the femur may spring from either the second or the third perforating branch. An *inferior nutrient artery* is frequently present; it is often derived from the fourth perforating artery.

When the adductor magnus is more fully exposed it will be seen that the perforating arteries, as they pierce its tendon, are protected by a series of fibrous arches.

**M. Pectineus.** — This muscle is placed between the adductor longus and the ilio-psoas. It is flat and somewhat broader at its origin from the brim of the pelvis than at its insertion into the femur. It has a fleshy origin, from the pecten pubis, and from the surface of the hip bone anterior to it (Fig. 74, p. 200). Some fibres are derived also from the lacunar ligament. It descends obliquely, laterally and posteriorly, and gains insertion into the femur, posterior to the lesser trochanter, and to a certain extent also into the line which leads from that prominence towards the linea aspera. It is supplied by the *femoral nerve.*

*Dissection.*—The pectineus may be detached from its origin, and thrown distally and laterally. In separating the muscle from the pubis the dissector must bear in mind that in some cases an *accessory obturator nerve* descends into the thigh, under cover of its lateral margin, and over the brim of the pelvis. Care must also be taken not to injure the anterior division of the obturator nerve which lies posterior to the muscle, or the medial circumflex artery which passes posteriorly in contact with its lateral border.

**Nervus Obturatorius Accessorius.**—The accessory obturator nerve, when present, arises within the abdomen either from the lumbar plexus or from the obturator trunk near its origin (Fig. 212). In the thigh it gives a branch to the hip-joint and joins the anterior division of the obturator nerve. It is very rare to find a twig given to the pectineus either by it or by the trunk of the obturator nerve itself.

**Art. Circumflexa Femoris Medialis.**—The medial circumflex artery springs from the medial and posterior aspect of the profunda femoris artery, at the same level as the lateral

circumflex branch. It passes posteriorly between the adjacent margins of the psoas and the pectineus, and then between the adductor brevis and the obturator externus, to the posterior region of the thigh, where, close to the lesser trochanter, it divides into an ascending and a transverse terminal branch. Before the main trunk divides it gives off (1) a superficial branch which passes medially across the front of the pectineus and between the adductors longus and brevis, and (2) an articular branch which enters the hip-joint through the acetabular notch. The terminal branches will be examined in the dissection of the gluteal region.

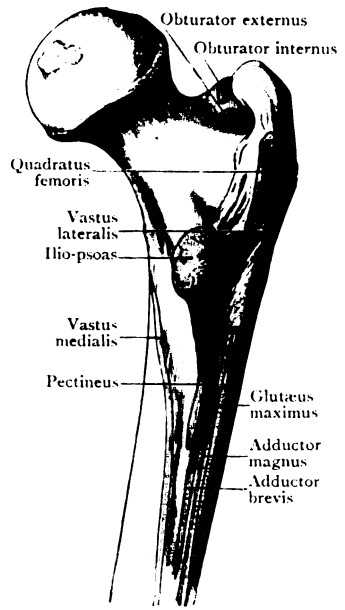


FIG. 78.—Posterior aspect of Proximal Portion of Femur, with the Attachments of Muscles mapped out.

**Branches of the Femoral Artery.**—In every region of the thigh the dissector has met with branches of the femoral artery. It is well now that he should revert to this vessel and study its branches in the order in which they arise. The following Table may aid him in doing this :—

A. femoralis.
- Aa. pudendæ externæ (superficial and deep).
- A. epigastrica superficialis.
- A. circumflexa ilium superficialis.

} Superficial inguinal.

- A. profunda.
  - A. circumflexa femoris lateralis.
  - A. circumflexa femoris medialis.
  - A. perforans prima.
  - A. perforans secunda.
  - A. perforans tertia.
  - A. perforans quarta (terminal).

} Aa. Nutritiæ.

- Rami Musculares.
- A. genu suprema.

**M. Adductor Brevis.**—This muscle lies posterior to the adductor longus and the pectineus. It arises, below the

origin of the adductor longus, from the anterior aspect of the body and the inferior ramus of the os pubis (Fig. 74, p. 200). As it descends it inclines posteriorly and laterally; and it is

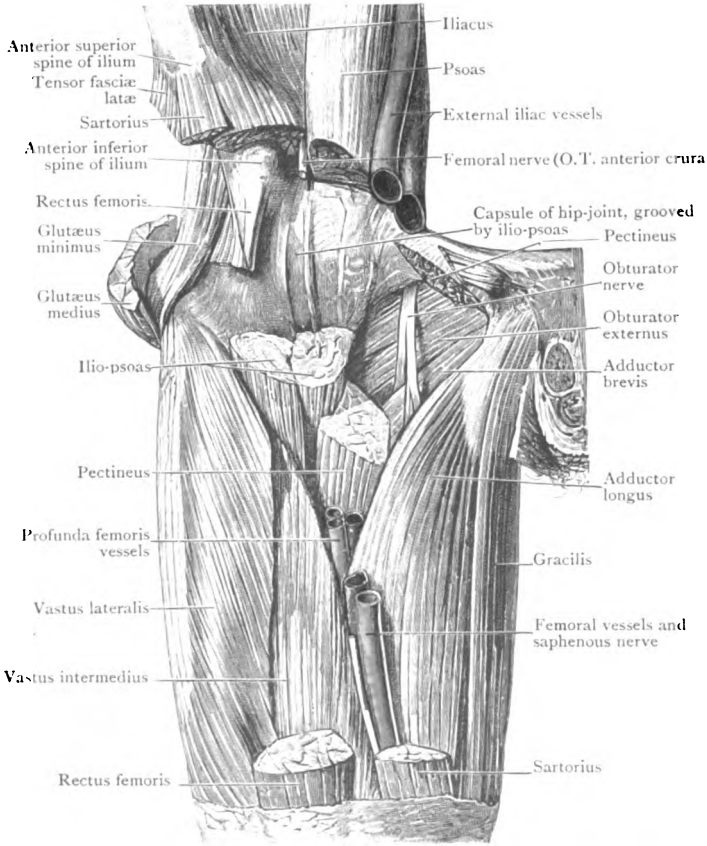


FIG. 79.—Dissection of the Front of the Thigh. The hip-joint has been exposed by removing portions of the muscles which lie anterior to it.

inserted, posterior to the pectineus, into the whole length of the line which extends from the lesser trochanter to the linea aspera (Fig. 78, p. 209). It is supplied by the *obturator nerve.*

*Dissection.*—Reflect the adductor brevis by cutting it close to its origin, and throwing it distally and laterally. The posterior division of the

obturator nerve is then exposed, and should be traced proximally to the obturator foramen, and distally to its distribution upon the adductor magnus.

**Nervus Obturatorius.**—The obturator nerve is a branch of the lumbar plexus (Fig. 212). It escapes from the pelvis

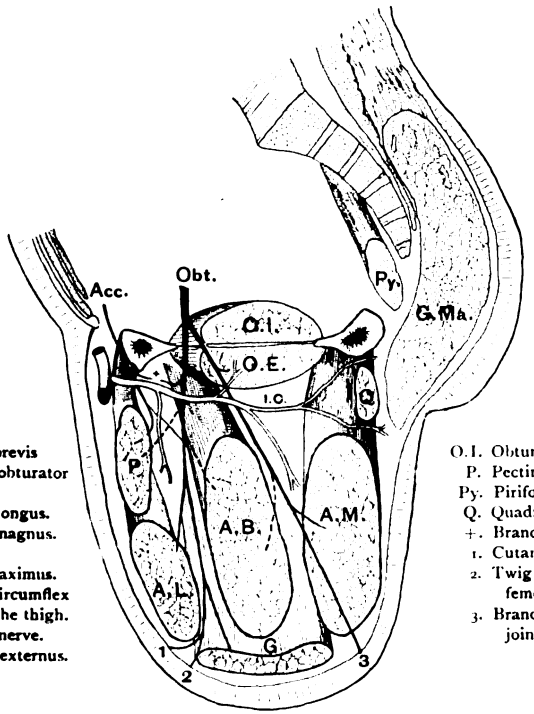


A.B. Adductor brevis
Acc. Accessory obturator nerve.
A.L. Adductor longus.
A.M. Adductor magnus.
G. Gracilis.
G.Ma. Glutæus maximus.
I.C. Medial circumflex artery of the thigh.
Obt. Obturator nerve.
O.E. Obturator externus.

O.I. Obturator internus.
P. Pectineus.
Py. Piriformis muscle.
Q. Quadratus femoris.
+. Branch to hip-joint.
1. Cutaneous branch.
2. Twig to walls of femoral artery.
3. Branch to knee-joint.

FIG. 80.—Diagram to illustrate the distribution of the Obturator Nerve and the general disposition of the Adductor Muscles of the Thigh (Paterson).

by passing, with its companion vessels, through the upper part of the obturator foramen of the hip bone. While still within the foramen it divides into an anterior and a posterior division.

The *anterior division* of the obturator nerve enters the thigh over the upper border of the obturator externus muscle, and proceeds distally upon the anterior surface of the adductor

brevis. Anterior to it are the pectineus and adductor longus muscles. It gives branches to three muscles, viz., the adductor longus, the adductor brevis, and the gracilis. Very rarely it will be observed to supply a twig to the pectineus. In addition to these branches it supplies—(1) an *articular branch* to the hip-joint (Fig. 80 +); (2) a fine twig, which appears at the distal

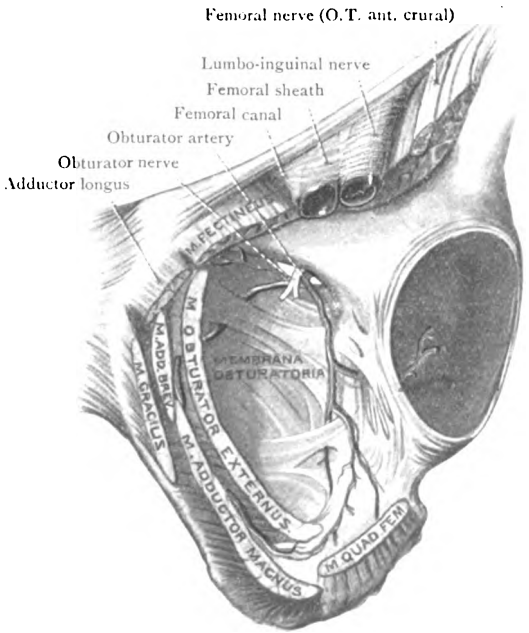


FIG. 81.—Dissection to show the Structures surrounding the Obturator Foramen of the Hip Bone.

border of the adductor longus, to join the sartorial plexus (Fig. 80); and (3) a *terminal twig*, which goes to the femoral artery —(Fig. 80)—and breaks up into fine filaments upon its walls.

The *posterior branch* of the obturator nerve, as it enters the thigh, pierces the upper border of the obturator externus. It extends distally, between the adductor brevis and the adductor magnus, and is expended chiefly in the supply of the latter muscle. It gives also, however, a branch to the obturator externus and an *articular branch* to the knee-

joint. The latter branch pierces the distal part of the adductor magnus, close to the linea aspera, and may be seen in the popliteal fossa, lying posterior to the popliteal artery.

**M. Gracilis.**—This is a long, strap-like muscle, which lies along the medial aspect of the thigh and knee. It springs, by a thin tendon, from the lower half of the body of the pubis, close to the symphysis, and also from the upper half of the pubic arch (Fig. 81, p. 212). It ends in a slender, rounded tendon which inclines anteriorly, distal to the knee, and then expands and is inserted into the proximal part of the medial surface of the tibia, under cover of the tendon of the sartorius, and at a more proximal level than the insertion of the semitendinosus (Fig. 92, p. 248). A mucous bursa separates the expanded tendon of the gracilis from the tibial collateral ligament of the knee-joint, and is prolonged proximally, so as to intervene between it and the tendon of the sartorius. The gracilis is supplied by the *anterior division* of the *obturator nerve.*

**M. Adductor Magnus.**—This is one of the most powerful muscles of the thigh. It forms a flat, fleshy mass, which springs from the anterior surface of the entire length of the pubic arch of the corresponding side, and from the lower part of the ischial tuberosity (Fig. 81, p. 212). The fibres which arise from the pubic arch spread out as they approach the posterior aspect of the femur; the more medial in origin are the more horizontal in direction; the more lateral in origin are the more oblique in direction. They are inserted into the posterior part of the femur, just medial to the gluteal tuberosity, into the linea aspera, and into a small portion of the proximal part of the medial supracondylar ridge (Fig. 77, p. 207). The fibres which take origin from the ischial tuberosity descend almost vertically and form the thick medial border of the muscle. In the distal third of the thigh they end in a strong, rounded tendon, which is inserted into the adductor tubercle on the medial condyle of the femur (Fig. 102, p. 279). This tendon is further attached to the femur by the medial intermuscular septum which stretches between it and the medial supracondylar line. Close to the linea aspera are the fibrous arches, formed in connection with the insertion of the adductor magnus, for the passage of the perforating arteries, and in series with them is the opening through which the femoral artery enters the popliteal fossa. The latter

is a gap between two portions of the muscle, and is situated in the distal third of the thigh (Fig. 77).

The adductor magnus has a double nerve supply. The fibres which spring from the pubic arch are supplied by the posterior branch of the *obturator nerve.* Those which arise from the ischial tuberosity are supplied by the *sciatic nerve.*

*Dissection.*—The adductor magnus should now be detached from its origin, in order that the obturator externus muscle and the obturator artery may be more fully examined.

**M. Obturator Externus.** — The obturator externus is a flat, fan-shaped muscle, which is placed over the anterior aspect of the obturator foramen of the hip bone. It springs from the medial half of the membrane which closes the foramen, and also from the medial and lower part of its bony margin (Fig. 81, p. 212). It proceeds posteriorly and laterally, below the neck of the femur and the capsule of the hip-joint, and ends in a stout tendon which obtains insertion into the trochanteric fossa (Fig. 78, p. 209). This tendon will be examined in the dissection of the gluteal region. The obturator externus is supplied by the *posterior division* of the *obturator nerve.*

**Art. Obturatoria.**—The obturator artery appears in the thigh through the upper part of the obturator foramen of the hip bone. It at once divides into two terminal branches, which diverge from each other and form an arterial circle upon the obturator membrane, under cover of the obturator externus. The muscle must therefore be detached in order that the vessels may be followed. Both branches give twigs to the neighbouring muscles, whilst the *posterior branch* sends an *articular twig* through the acetabular notch into the hip-joint. When the joint is opened this twig may be followed, in a well-injected subject, along the ligamentum teres into the head of the femur.

**Mm. Psoas Major and Iliacus.**—These muscles arise within the abdomen and enter the thigh posterior to the inguinal ligament. A tendon appears on the lateral side of the psoas major, and into this the fibres of the iliacus are for the most part inserted. The conjoined tendon of the ilio-psoas is implanted into the lesser trochanter of the femur, but a certain proportion of the fleshy fibres of the iliacus obtain direct insertion into the body of the femur, distal to that prominence (Fig. 78, p. 209).

*Dissection.*—Divide the femoral vessels, and the femoral nerve, about an inch distal to the inguinal ligament, and having tied them together with twine throw them distally. Now cut through the sartorius and the rectus femoris, about two inches from their origins, and turn them aside. The tendon of the ilio-psoas must next be detached from its insertion and, with the muscle, turned upwards. This will expose the anterior surface of the capsule of the hip-joint. An intervening mucous bursa will also be displayed. Open this and ascertain its extent by introducing the finger. It facilitates the play of the ilio-psoas upon the front of the hip-joint, and in some cases its cavity will be found to be directly continuous with the cavity of the joint, through an aperture in the capsule. The intimate connection which exists between the capsule of the hip-joint and the tendon of the glutæus minimus, the reflected head of the rectus femoris, and the deep layer of the ilio-tibial tract, should be noticed. Lastly, turn aside the tensor fasciæ latæ, and carefully clean the anterior aspect of the capsule of the hip-joint.

At the end of the fifth day the dissector must paint the various parts of the anterior and medial regions of the thigh with preservative solution, replace them in position and fix the skin flaps over them with a few points of suture.

On the morning of the sixth day after the dissection of the lower limb has been begun, the subject is placed upon the table with its face downwards and its thorax and pelvis supported by blocks. In that position it is allowed to remain for *five* days, and during the time the dissector of the lower extremity has a very extensive dissection to perform. He has to dissect—(1) the gluteal region; (2) the proximal part of the popliteal fossa; and (3) the posterior region of the thigh. With so much work before him, and being limited as to the time in which it must be done, it is necessary that he should apportion the five days at his disposal so as to complete the dissection before the body is turned again. The *first two days* he should devote to the study of the gluteal region; the *third* and *fourth days* may be given to the popliteal fossa; and on the *fifth day* he should undertake the dissection of the back of the thigh, and revise the work of the four preceding days.

## GLUTEAL REGION.

In this region the following are the parts which will be displayed in the course of the dissection:—

1. Superficial fascia.
2. Cutaneous nerves and blood-vessels.
3. Deep fascia.

4. Glutæus maximus ; (and after this has been reflected),
Three mucous bursæ.
The glutæus medius and minimus.
The two gemelli muscles and the tendon of the obturator internus.
Tendon of the obturator externus.
Proximal border of the adductor magnus.
The origin of the hamstrings from the ischial tuberosity.
The proximal part of the vastus lateralis.

5. The sacro-tuberous ligament. (O.T. great sciatic lig.)

6. The superior gluteal artery.
The inferior gluteal artery (O.T. sciatic).
The internal pudendal artery.
The medial circumflex artery.

7. Nerves . . Superior gluteal.
Sciatic.
Posterior cutaneous of the thigh.
Pudendal.
Nerve to obturator internus.
Nerve to quadratus femoris.
Inferior gluteal.

Supposing that *two days* are allowed for the above dissection, the **first day's work** should consist of—(1) the dissection of the parts superficial to the glutæus maximus ; (2) the cleaning and reflecting of this muscle ; (3) the tracing and defining the various nerves and blood-vessels which enter its deep surface. **On the second day** the parts which are exposed by the reflection of the glutæus maximus should be dissected.

**Surface Anatomy.**—Before the skin is reflected the surface markings of the gluteal region require examination. On each side the prominence of the nates forms a round, smooth elevation. Inferiorly the nates are separated, in the middle line, by a deep fissure—the *natal cleft.* This cleft, if traced upwards, almost disappears over the prominence formed by the coccyx and lower part of the sacrum. The crest of the ilium can be felt along its whole length, and in the well-formed male its position is indicated by a groove—the *iliac furrow.* Traced anteriorly the crest terminates in the anterior superior spine of the ilium; traced posteriorly it ends in the posterior superior spine of the ilium. The position of the latter is indicated by a faint depression or dimple which lies on a level with the second spine of the sacrum, and it corresponds with the middle of the sacro-iliac articulation. The prominence of the nates is formed chiefly by the glutæus maximus muscle, covered by a thick layer of fat. A deep transverse groove, produced by a fold of skin and fascia, limits the gluteal elevation below. This is called the gluteal sulcus, and is sometimes said to correspond with the distal border of the glutæus maximus muscle. It

can easily be shown that this is not the case. Its medial

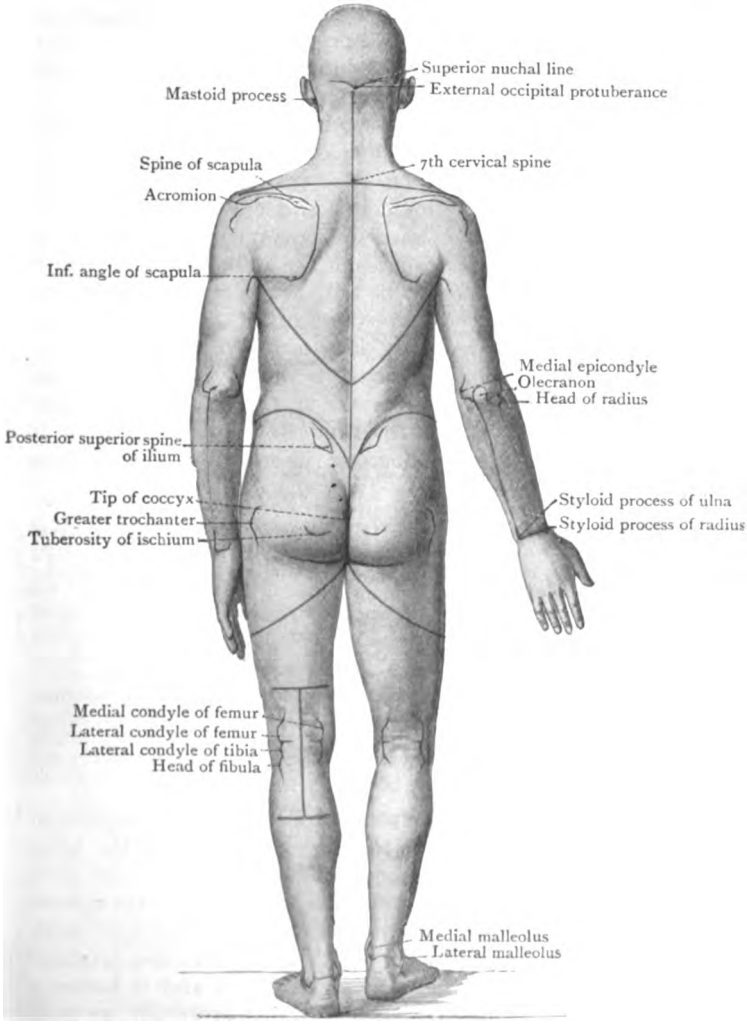


FIG. 82.— Surface view, showing incisions and bony points.

end lies distal to the inferior margin of the muscle, but as it

proceeds transversely it crosses the border of the muscle, and finally comes to lie on the surface of the muscle. In disease of the hip-joint, the buttock loses its prominence, whilst the gluteal sulcus becomes faint. The tuberosity of the ischium may be felt, deep to the lower border of the glutæus maximus, by placing the fingers in the medial part of the gluteal sulcus and pressing upwards. A line drawn from the most prominent part of this tuberosity to the anterior superior spine of the ilium is called *Nelaton's line*; it passes over the top of the greater trochanter and crosses the centre of the acetabulum; and it is used by the surgeon in the diagnosis of dislocations and other injuries of the hip-joint. The greater trochanter of the femur may be felt at a point about six inches below the highest part of the crest of the ilium. It can be seen in thin subjects, but it does not form so projecting a feature of this region as might be expected from an inspection of the skeleton, because the thick tendon of the glutæus medius is inserted into its lateral surface, and it is covered also by the aponeurotic insertion of the glutæus maximus.

**Reflection of Skin.**—*Incisions.*—(1) From the posterior superior spine of the ilium in a curved direction along the crest of the ilium, as far forwards as the position of the body will permit; (2) from the posterior extremity of this curved incision obliquely downwards and medially to the middle line of the sacral region, and then perpendicularly to the tip of the coccyx; (3) from the tip of the coccyx obliquely distally and laterally over the back of the thigh, to the junction of the proximal third with the middle third of the posterior border of the lateral area of the thigh.

A large flap of skin is thus marked out, and this must be raised from the subjacent superficial fascia and thrown laterally. On the right side of the body the dissector begins at the crest of the ilium and works distally and anteriorly; whilst on the left side he commences over the coccyx and works upwards and anteriorly.

**Panniculus Adiposus (Superficial Fascia).**—The superficial fascia is now exposed, and it is seen to partake of the same characters as the corresponding layer of fascia in other parts of the body (p. 5). It presents, however, certain special peculiarities. It is much more heavily laden with fat—more particularly so in the female; it thickens over the proximal and distal margins of the glutæus maximus, and it becomes tough, elastic, and stringy over the ischial tuberosity, so as to form a most efficient cushion upon which this bony prominence rests while the body is in the sitting posture.

**Cutaneous Nerves** (Fig. 83).—The superficial fascia forms

a bed in which the cutaneous nerves ramify before they enter the skin. In this region the cutaneous nerves are very numerous, and they are derived from a great variety of sources. Some proceed from the *posterior branches* of the spinal nerves, whilst others are given off from the *anterior branches* of the spinal nerves.

From the *posterior branches* there are usually *six*—three from the sacral nerves, and three from the lumbar nerves. The *three sacral nerves* reach the surface by piercing the glutæus maximus muscle close to its origin from the sacrum and coccyx. They are usually of small size and pierce the muscle in a line drawn from the posterior superior spine of the ilium to the tip of the coccyx. The largest is found opposite the lowest piece of the sacrum, the highest about an inch above that, and the lowest about the same distance below it.

Owing to the coarseness of the muscular fasciculi of the glutæus maximus between which they appear, they are somewhat difficult to find. In looking for them, it is best to cut right down through both superficial and deep fasciæ, so as to secure them as they emerge from the muscle.

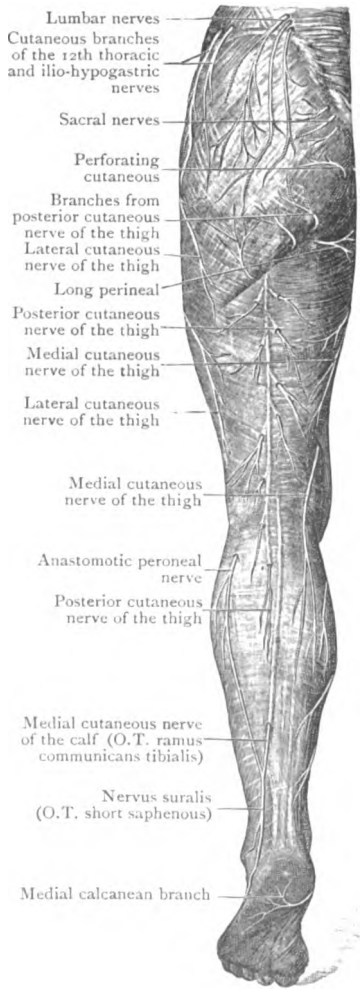
Lumbar nerves
Cutaneous branches of the 12th thoracic and ilio-hypogastric nerves
Sacral nerves
Perforating cutaneous
Branches from posterior cutaneous nerve of the thigh
Lateral cutaneous nerve of the thigh
Long perineal
Posterior cutaneous nerve of the thigh
Medial cutaneous nerve of the thigh
Lateral cutaneous nerve of the thigh
Medial cutaneous nerve of the thigh
Anastomotic peroneal nerve
Posterior cutaneous nerve of the thigh
Medial cutaneous nerve of the calf (O.T. ramus communicans tibialis)
Nervus suralis (O.T. short saphenous)
Medial calcanean branch

FIG. 83.—Cutaneous Nerves on the posterior aspect of the Inferior Extremity.

The *three lumbar nerves* are easily found. They cross

the crest of the ilium at a point corresponding to the lateral limit of the attachment of the sacro-spinalis to the hip bone. They pass distally and slightly anteriorly in the superficial fascia, and run in different planes, the larger trunks being placed deeper than the smaller branches. They communicate with one another and with the sacral nerves. A few twigs may be followed as far as the greater trochanter.

The cutaneous twigs which come from the *anterior branches* of the spinal nerves may be classified under three headings —(1) those which pass distally over the crest of the ilium; (2) those which pass dorsally over the insertion of the glutæus maximus into the fascia lata; (3) those which turn proximally round the distal margin of the glutæus maximus.

The nerves which cross the crest of the ilium are—(1) *lateral cutaneous branch* of the *ilio-hypogastric nerve*; and (2) the *lateral cutaneous branch* of the *last thoracic nerve.*

The *lateral cutaneous branch* of the *ilio-hypogastric nerve* pierces the external oblique muscle close to its insertion into the ilium. It crosses the iliac crest usually opposite a tubercle which projects from the outer lip of the crest, about two and a half inches from the anterior superior spine, but it may emerge at any point between this tubercle and the anterior border of the iliac origin of the latissimus dorsi. The *lateral cutaneous branch* of the *last thoracic nerve* pierces the external oblique muscle of the abdominal wall, a short distance anterior to the branch of the ilio-hypogastric, at a point situated from one to two inches above the iliac crest. Both nerves, after crossing the iliac crest, run distally in the thick superficial fascia over the upper part of the glutæus medius, and spread out into a great number of fine twigs, which ramify over the insertion of the glutæus maximus. Some of them reach distally as far as the level of the greater trochanter.

The nerves which pass dorsally over the insertion of the glutæus maximus are a few small twigs from the posterior branches of the *lateral cutaneous nerve* of the thigh. They are found above the level of the greater trochanter.

The cutaneous twigs which hook round the distal margin of the glutæus maximus muscle, to reach the skin over this region, are a few offsets from the *posterior cutaneous nerve* of the thigh and the *perforating cutaneous branch* of the *second and third sacral nerves.* The former appear lateral to the tuberosity of the ischium, and are accompanied, in some cases, by twigs

from the inferior gluteal artery. The latter comes into view medial to the ischial tuberosity, and is accompanied by small branches of the inferior hæmorrhoidal artery.

These nerves can most readily be found by everting the lower border of the glutæus maximus; but in doing this, care must be taken not to injure the trunk of the posterior cutaneous nerve of the thigh, as it passes from under cover of the glutæus maximus and runs vertically into the thigh.

**Deep Fascia.**—The deep fascia of the gluteal region is brought into view by removing what remains of the superficial fascia. The fatty tissue should be cleared away not only from the deep fascia as it is spread over the glutæus maximus, but also from the more anteriorly situated area. In the latter situation a dense, opaque, pearly white fascia is by this means exposed. This covers the anterior part of the glutæus medius, and is firmly attached above to the crest of the ilium. It stands in marked contrast with the deep fascia over the glutæus maximus, which is thin and transparent. Subsequent dissection will show that the dense fascia over the anterior part of the glutæus medius, when it reaches the anterior border of the glutæus maximus, splits into two lamellæ which enclose the glutæus maximus between them.

*Dissection.*—Now proceed to clean the glutæus maximus muscle. If it is the right limb, begin at the anterior or upper margin of the muscle; but if it is the left, commence the dissection at the posterior or distal border. In undertaking this dissection, the dissector must keep clearly before him the rules which have already been laid down regarding the cleaning of a muscle:—(1) render the fibres as tense as possible by rotating the limb medially; (2) remove the fascia in one continuous layer; (3) always cut in the direction of the muscular fibres; (4) define very carefully the borders of the muscle.

The glutæus maximus is a difficult muscle to clean, as the fasciculi are exceedingly coarse. To do it well it is not sufficient to remove the fascia which covers the muscle but it is necessary, at the same time, to follow, for a short distance, the septa which penetrate between the fasciculi and to remove them also. Do not remove the thick opaque fascia which covers the insertion of the muscle.

The dissector of the left limb, on reaching the anterior margin of the muscle, will observe that the fascia which he holds in his hand is continuous with the strong fascia which covers the glutæus medius; and further, if he now frees the anterior border of the muscle from subjacent parts, he will notice that the layer of fascia upon which the glutæus maximus rests is also continuous with it. In other words, he will, in this manner, be able to satisfy himself that the strong aponeurotic fascia which covers the anterior part of the glutæus medius splits into two layers to enclose the glutæus maximus. The posterior cutaneous nerve of the thigh should be secured at once by everting the distal border of the glutæus maximus. Otherwise it is very liable to be injured in the subsequent stage of

dissection owing to its close relationship to the deep surface of the muscle.

**M. Glutæus Maximus.**—This powerful muscle arises—(1) from a narrow, rough area on the dorsum ilii, which is included

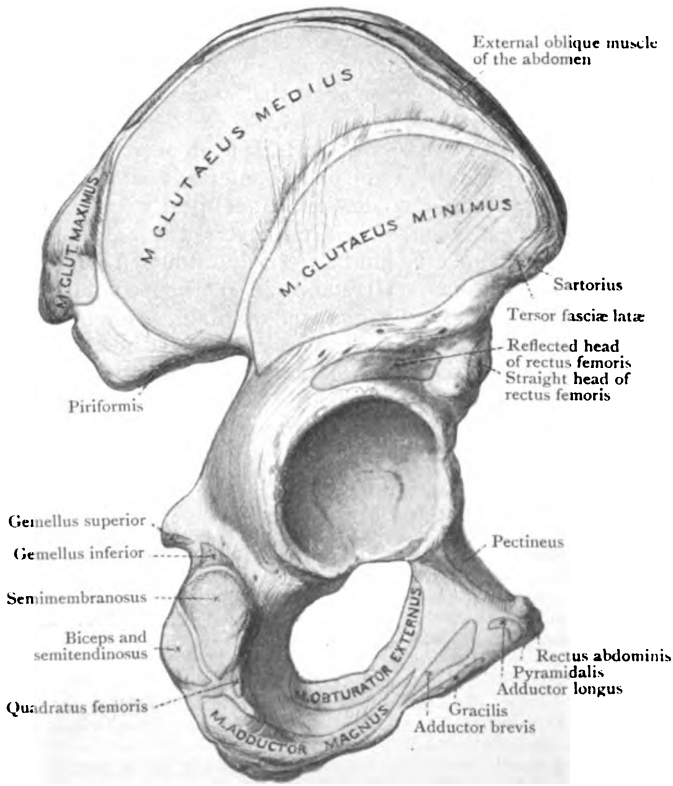


FIG. 84.—External aspect of the Hip Bone, with the Attachments of the Muscles mapped out.

between the posterior curved line and the outer lip of the crest; (2) from the sides of the lower two pieces of the sacrum and the upper three pieces of the coccyx; (3) from the entire posterior surface of the sacro-tuberous ligament (O.T. great sciatic); and (4) slightly from the posterior layer

of the lumbo-dorsal fascia, at the attachment of the latter to the crest of the ilium.

From this extensive origin the coarse fasciculi of the muscle proceed obliquely distally and anteriorly towards the proximal portion of the femur; but only a comparatively small proportion of them receive direct insertion into that bone. The greater part of the muscle is inserted into the fascia lata. To be more precise, it may be said that the whole of the fibres belonging to the proximal half of the muscle, and the superficial stratum of fibres of the distal half of the muscle, are inserted into the fascia lata. The deeper fibres of the distal half of the muscle, however, are directly attached to the gluteal tuberosity on the back of the femur (*i.e.* the ridge which extends from the greater trochanter to the linea aspera). (Fig. 78, p. 209.) The glutæus maximus is supplied by the *inferior gluteal nerve.*

**Reflection of the Glutæus Maximus.**—This is by no means an easy dissection. It is best to detach the muscle from its origin and throw it distally towards its insertion. It should be dissected completely away from the various surfaces from which it arises. When that is done the general outline of the pelvis becomes more apparent, and the dissector obtains distinct bony landmarks which are most useful in enabling him to localise the various structures he is expected to expose. Let us suppose we are dealing with the left lower limb. As a preliminary step, the two borders of the muscle should be freed and the left hand gently insinuated under the fleshy mass. The muscle must, in the first instance, be detached from the ilium. When the surface on the dorsum ilii from which it springs is cleared the upper margin of the greater sciatic notch is reached. There the dissector must proceed with caution, because through the notch pass the gluteal vessels, and their branches enter the deep surface of the glutæus maximus muscle. When these are secured the muscle must be detached from the side of the sacrum; then the piriformis muscle, emerging from under cover of the sacrum, comes into sight. The muscular fibres may now be raised from the surface of the sacro-tuberous ligament and separated from the side of the coccyx. In doing this, care should be taken to preserve the three sacral cutaneous nerves intact, in order that they may be subsequently traced to their origins. As the surface of the sacro-tuberous ligament is gradually laid bare, a number of small arteries (the coccygeal branches of the inferior gluteal artery) will be seen piercing it and immediately sinking into the substance of the glutæus maximus. These cannot be retained. It is necessary to sever them in order that the muscle may be freed. The perforating branch of the second and third sacral nerves, which winds round the distal border of the glutæus maximus near the coccyx, must also be remembered and traced to the sacro-tuberous ligament which it will be seen to pierce.

The glutæus maximus is now completely separated from the parts from which it arises, but it cannot be thrown distally towards its insertion. It is still tied to its place by the blood-vessels and nerves which enter its deep surface. These are (1) the branches of the *superficial division* of the ***superior gluteal artery*** which appear at the upper border of the piriformis;

(2) branches of the *inferior gluteal artery* and the *inferior gluteal nerve*, below the level of the piriformis. The veins may at once be removed, but the arteries and nerves must be systematically cleaned as they come into view, and traced into the substance of the glutæus maximus. Finally, to allow of the complete reflection of the glutæus maximus, these vessels and nerves must be cut, and it is advisable to leave in connection with the cut end of each a small portion of muscle-substance, in order that they may be readily recognised in the further steps of the dissection. The whole muscle may now be thrown distally and laterally, and after a little dissection an admirable view is obtained of its insertion. Piercing the distal part of the insertion there will be seen a few small twigs of the first perforating artery—a branch of the profunda femoris.

In the case of the right limb the procedure adopted in reflecting the glutæus maximus is the same as detailed above, with this exception, that the dissector should begin by detaching it from the coccyx and sacro-tuberous ligament and work upwards towards the ilium.

Although it is recommended that the glutæus maximus should be reflected proximo-distally, it is right to mention that an equally-instructive view of the subjacent parts may be obtained by detaching it from its insertion and throwing it upwards towards its origin. The senior student would do well to adopt this method.

**Bursæ Mucosæ under cover of the Glutæus Maximus.**—Two *mucous bursæ* are found in relation to the insertion of the glutæus maximus. The *one*—a large loose sac—is interposed between the aponeurosis, into which the proximal part of the muscle is inserted, and the greater trochanter of the femur. It allows the aponeurosis to play freely on the bone. The *second bursa* lies immediately distal and anterior to the part of the muscle which is inserted into the gluteal tuberosity of the femur. A slight touch of the knife is sufficient to open it, and then the glistening tendon of the vastus lateralis comes into view. The bursal sac intervenes between that tendon and the aponeurotic insertion of the glutæus maximus.

A *third bursa* is situated between the glutæus maximus and the tuberosity of the ischium. In all probability this has already been explored by the dissector of the perineum. It lies over the lower aspect of the bony prominence, and is interposed more between the tough superficial fascia and the bone, than between the muscle and the bone.

*Dissection.*—On the *second day* the dissector undertakes the dissection of the remaining structures which are displayed by the reflection of the glutæus maximus. The vessels and nerves which have been partially exposed in the previous day's dissection must now be followed towards the pelvis, and the remaining vessels and nerves, together with the muscles, must be defined and cleaned by removing the loose areolar tissue which covers and passes between them.

**Parts under cover of the Glutæus Maximus.**— Proceeding distally from the dorsum ilii, towards the ischial

tuberosity and the posterior area of the thigh, the following muscles may be recognised:—(1) The glutæus medius, lying over the greater part of the dorsum ilii; (2) the piriformis, issuing from the pelvis through the greater sciatic foramen;

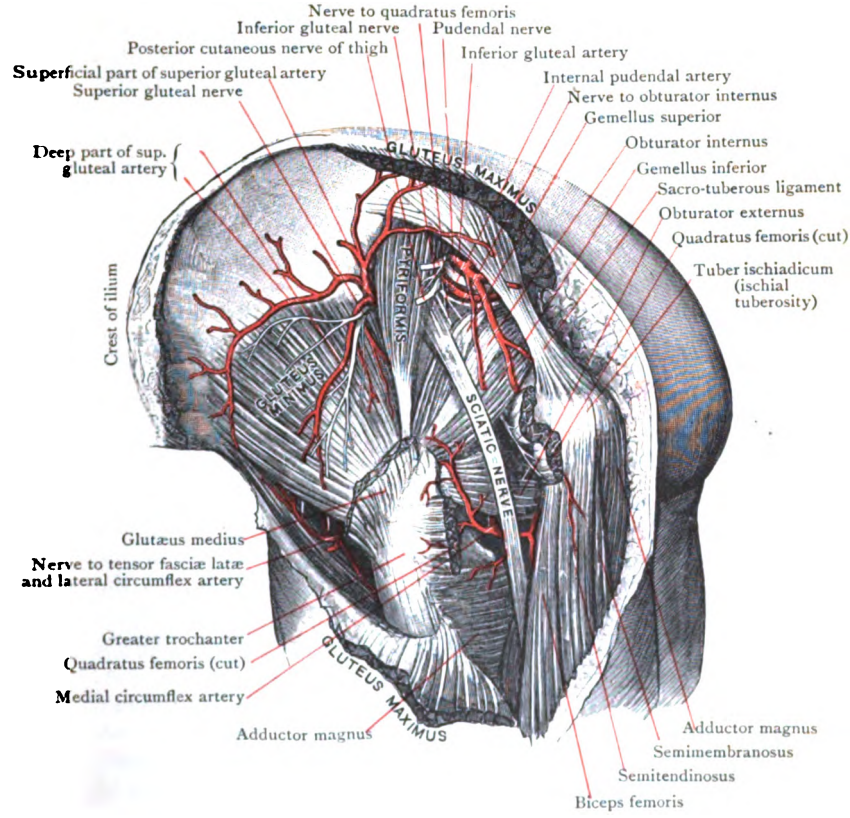


FIG. 85.—Dissection of the Gluteal Region. The Glutæus Maximus, Glutæus Medius, and the Quadratus Femoris have been reflected.

(3) the tendon of the obturator internus, passing through the lesser sciatic foramen, with the gemellus superior attached to its superior border and the gemellus inferior to its lower border; (4) the quadratus femoris, passing from the ischial tuberosity to the proximal end of the femur; (5) the proximal

border of the adductor magnus. By separating the contiguous margins of the gemellus inferior and quadratus femoris from each other, and looking into the interval between them, the dissector will see the tendon of the obturator externus, as it passes round the neck of the femur to reach the trochanteric fossa. If the adjacent margins of the quadratus femoris and the adductor magnus are similarly dealt with, the lesser trochanter of the femur will be exposed. Lastly, the origin of the hamstring muscles, from the ischial tuberosity, and the proximal part of the vastus lateralis, arising from the root of the greater trochanter of the femur on its lateral aspect, should be noted.

In each interval formed by the adjacent margins of the muscles exposed, blood-vessels and nerves, or blood-vessels alone, are to be found.

Before proceeding to the dissection of these, however, it is well that the student should renew his acquaintance with the skeletal peculiarities of this region. Let him obtain a dried pelvis with the ligaments *in situ*, and study carefully the position and boundaries of the greater and lesser sciatic notches, and the manner in which they are converted into foramina by the sacro-tuberous ligament (O.T. great sciatic) and sacro-spinous ligament (O.T. small sciatic). Through these foramina important structures issue from the interior of the pelvis into the gluteal region.

In the interval between the contiguous margins of the glutæus medius and the piriformis muscles, the *superior gluteal artery and nerve* issue from the pelvis through the greater sciatic foramen. In the interval between the piriformis and the gemellus superior two arteries and six nerves must be looked for, as they emerge through the lower part of the greater sciatic foramen, viz. :—

| | |
|---|---|
| Arteries, | 1. A. glutæa inferior.<br>2. A. pudenda interna. |
| Nerves, | 1. N. ischiadicus.<br>2. N. cutaneus femoris posterior.<br>3. N. pudendus.<br>4. N. glutæus inferior.<br>5. Nerve to the obturator internus.<br>6. Nerve to the quadratus femoris. |

The huge sciatic nerve, together with the inferior gluteal artery and posterior cutaneous nerve of the thigh, proceed towards the thigh in the hollow between the greater trochanter of the femur and the tuberosity of the ischium.

In the interval between the gemellus inferior and the quadratus femoris, the small *ascending terminal branch* of the

*medial circumflex artery* will be seen; whilst between the contiguous margins of the quadratus femoris and the adductor magnus the larger *transverse terminal branch* of the same artery makes its appearance.

**Inferior Gluteal Nerve.**—The inferior gluteal nerve is the nerve of supply to the glutæus maximus. It springs from the sacral plexus, and enters the gluteal region through the lower part of the greater sciatic foramen. During the reflection of the glutæus maximus it has been seen to break up into numerous twigs which enter the deep surface of the muscle.

**Inferior Gluteal Artery** (O.T. **Sciatic**).—The inferior gluteal artery, a branch of the hypogastric artery (O.T. internal iliac), issues from the pelvis, through the greater sciatic foramen below the piriformis muscle, and proceeds distally, with the sciatic nerve, under cover of the glutæus maximus. Finally, reaching the distal border of that muscle, it is continued, as a fine cutaneous twig, to the posterior aspect of the thigh, in company with the posterior cutaneous nerve. It gives off numerous branches in the gluteal region. Of these the large muscular offsets to the glutæus maximus, and the cutaneous twigs that accompany the branches of the posterior cutaneous nerve of the thigh which turn round the distal border of that muscle, have been already studied. The following three branches remain to be examined:—(1) the *coccygeal branch*, which passes medially between the sacro-tuberous and sacro-spinous ligaments to reach the integument and fascia in the region of the coccyx; a number of twigs derived from this branch have been previously noticed piercing the sacro-tuberous ligament and ending in the glutæus maximus; (2) *arteria comitans nervi ischiadici*, a minute artery, which runs distally on the sciatic nerve and finally penetrates into its substance; (3) the *artery to the quadratus femoris*, which accompanies the nerve to that muscle; it will be found lying on the hip bone under cover of the sciatic nerve.

In a well-injected body the anastomosis between the inferior gluteal artery, the two terminal branches of the medial circumflex artery, and the first perforating artery, may be made out.

**The Posterior Cutaneous Nerve of the Thigh** (O.T. **Small Sciatic Nerve**).—The posterior cutaneous nerve of the thigh arises, within the pelvis, from the sacral plexus. After escaping

through the greater sciatic foramen it extends distally, with the inferior gluteal artery, under cover of the glutæus maximus. Leaving the muscle, it proceeds distally, on the back of the thigh, immediately subjacent to the deep fascia. It will afterwards be traced to the posterior aspect of the calf of the leg.

In the gluteal region it gives off several cutaneous

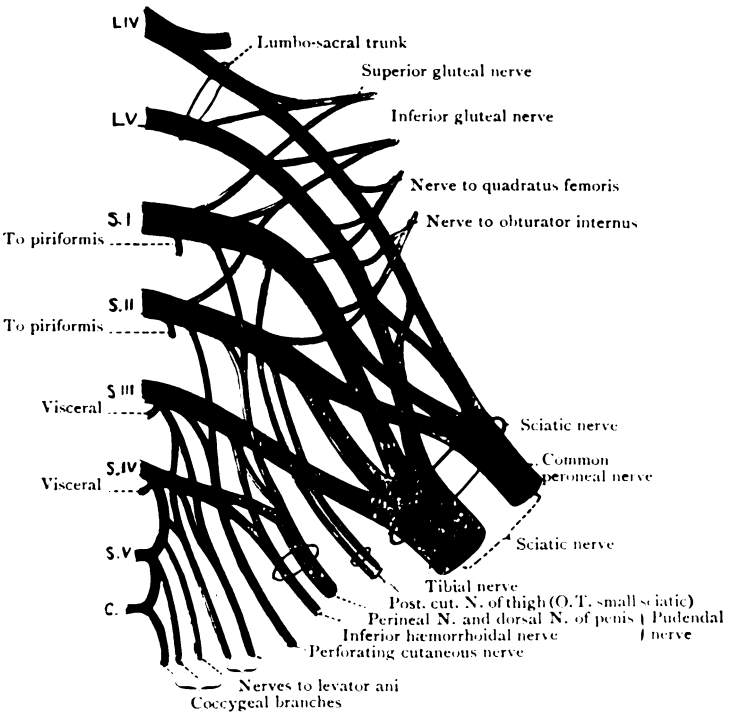


FIG. 86.—Diagram of Sacral Plexus.

branches, viz.—(1) inferior nerves of the buttock, which wind round the distal border of the glutæus maximus to supply a limited area of the skin of the buttock; (2) a few twigs to the skin to the medial region of the thigh; and (3) the perineal branches, of which one is known as the *long perineal nerve* (O.T. long pudendal).

This branch turns medially, round the origin of the hamstring muscles, to reach the perineum.

**Nervus Ischiadicus** (O.T. **Great Sciatic Nerve**).—The sciatic nerve, the largest nerve in the body, comes from the sacral plexus, and enters the gluteal region through the lower part of the greater sciatic foramen. At first it has the form of a flattened band, but soon it becomes oval or round, as seen in section. Covered by the glutæus maximus, the sciatic nerve traverses the gluteal region in the interval between the greater trochanter of the femur and the tuberosity of the ischium. Proximo-distally it lies on the body of the ischium (at the lower margin of the greater sciatic notch), the tendon of the obturator internus with the two gemelli muscles, the quadratus femoris, and the adductor magnus. In this region it does not, as a rule, give off any branch, but occasionally the nerves to one or more of the hamstring muscles issue from the main trunk as high as the level of the quadratus femoris.

The sciatic nerve frequently escapes from the pelvis in the form of two trunks (the two divisions into which it divides lower down, viz., the tibial and the common peroneal) which enclose between them a portion of the piriformis muscle.

*Dissection.*—The student should flex the knee and raise it on a block in order to relax the sciatic nerve. By pulling this great nerve-trunk laterally, the dissector will expose the nerve to the quadratus femoris, lying directly upon the hip bone. Medial to this he will find the pudendal vessels and nerve, with the nerve to the obturator internus crossing the spine of the ischium. These structures require to be cleaned carefully. The twig from the nerve to the obturator internus to the gemellus superior is especially liable to injury. The dissection will be improved by scraping off the periosteum from the small area of bone which is in relation to the above-mentioned vessels and nerves.

**Internal Pudendal Vessels and Pudendal Nerve** (O.T. **Internal Pudic), and the Nerve to the Obturator Internus.**—These structures emerge from the greater sciatic foramen, below the piriformis, and are exposed in the present dissection only for a very short part of their course. They pass out of view by entering the lesser sciatic foramen. The *nerve to the obturator internus* is placed most laterally. It lies on the base of the ischial spine, and furnishes a twig to the gemellus superior. The *internal pudendal artery*, with a companion vein on each side, crosses the tip of the spine. The *pudendal nerve* is placed most medially, and lies on the sacro-spinous ligament, close to its attachment to the spine. In some cases, however, the pudendal nerve unites in a plexiform manner with the nerve to the obturator internus, so that the whole, or a part, of it may lie lateral to the pudendal vessels.

**Small Lateral Rotator Muscles of the Thigh.**—Under this heading are included the piriformis, obturator internus, gemelli, the obturator externus, and the quadratus femoris. They are all inserted into, or in the neighbourhood of, the greater trochanter of the femur, and they are applied to the posterior surface of the capsule of the hip-joint.

**M. Piriformis.**—The piriformis arises within the pelvis from the three middle pieces of the sacrum, and slightly from the upper margin of the greater sciatic notch of the hip bone. The sacral origin cannot be seen at present, but the iliac origin should be made out. After passing through the greater sciatic foramen, the muscle is directed distally, laterally, and anteriorly. Its fleshy belly rapidly tapers and ends in a rounded tendon, which crosses superficial to the common tendon of the obturator internus and gemelli, and is inserted into a small impression on the highest part of the greater trochanter of the femur (Fig. 75, p. 202). It is closely adherent to the subjacent obturator tendon for some distance. The piriformis is supplied by branches from the *first* and *second sacral nerves.*

**Mm. Obturator Internus et Gemelli.**—These muscles, together, constitute a tricipital muscle with one large intra-pelvic belly (obturator internus), and two small extra-pelvic bellies (gemellus superior and inferior). The common tendon of this tricipital muscle is inserted into an impression on the upper part of the greater trochanter of the femur, immediately anterior and medial to the insertion of the piriformis (Fig. 75, p. 202).

The *gemellus superior* arises from the spine of the ischium, at the upper margin of the lesser sciatic notch. Its fibres pass laterally along the superior border of the tendon of the obturator internus, and are inserted obliquely into that tendon.

The *gemellus inferior* arises from the tuberosity of the ischium, at the lower margin of the lesser sciatic notch, and is inserted into the distal border of the obturator tendon, in a similar manner to the gemellus superior. Close to their origins the gemelli meet under cover of the obturator tendon, and form a fleshy bed, on which it lies; near the trochanter the fibres of the gemelli overlap the obturator tendon, and tend to cover its superficial surface.

The *tendon of the obturator internus* should be freed from the gemelli for some little distance from its point of exit from the lesser sciatic foramen. It may then be divided and

raised from the bed in which it lies. Its deep surface will be seen to consist of four or five rounded slips separated by deep grooves or furrows. The surface of the lesser sciatic notch on which this tendon glides is coated with smooth cartilage, raised into ridges corresponding to the grooves on the surface of the tendon. A large mucous bursa is interposed, which still further facilitates the play of the tendon round the notch.

**M. Quadratus Femoris.**—The quadratus femoris lies between the gemellus inferior and the adductor magnus. It arises from the lateral border of the ischial tuberosity, and proceeds horizontally to gain insertion into the quadrate tubercle, and into a line which extends distally from it, on the back of the femur, for two inches (Fig. 78, p. 209).

*Dissection.*—The nerve to the quadratus femoris should now be traced to its termination. This can be done by reflecting the two gemelli muscles, anterior to which it runs. When followed as far as the inferior gemellus, care should be taken to secure the little twig it gives to that muscle. Lastly, reflect the flat quadratus femoris by detaching it from the femur and throwing it towards the ischial tuberosity. By this dissection not only is the whole length of the nerve to the quadratus femoris exposed, but also a considerable portion of the posterior aspect of the capsule of the hip-joint is laid bare; further, the obturator externus muscle, the termination of the medial circumflex artery, and the insertion of the ilio-psoas are brought into view. The posterior part of the capsule of the hip-joint, which is exposed, consists largely of circularly arranged fibres.

**Nerve to the Quadratus Femoris.**—This small nerve runs distally on the hip bone and passes successively anterior to the following structures: the sciatic nerve, the gemellus superior, the tendon of the obturator internus, the gemellus inferior. It gives the nerve of supply to the gemellus inferior and a twig to the hip-joint, and ends by sinking into the deep surface of the quadratus femoris.

**M. Obturator Externus.**—The obturator externus muscle can now be seen winding round the neck of the femur and finally ending in a rounded tendon which is implanted into the fossa trochanterica of the femur (Fig. 78, p. 209). Its origin has already been examined.

**Arteria Circumflexa Femoris Medialis.**—The medial circumflex artery comes to an end at the proximal border of the adductor magnus by dividing into its ascending and transverse terminal branches. The *ascending branch* runs obliquely proximally and laterally, anterior to the quadratus femoris and upon the posterior surface of the obturator

externus. Its terminal branches ramify in the neighbourhood of the trochanteric fossa, where they anastomose with twigs from the inferior and superior gluteal arteries. The *transverse branch* passes posteriorly, between the quadratus femoris and the adductor magnus, and enters the hamstring muscles. It anastomoses with the terminal twig of the middle division of the lateral circumflex artery, which in a well-injected subject will be noticed appearing from amidst the fibres of the proximal part of the vastus lateralis. An arterial circle is thus completed, around the proximal part of the femur, which communicates proximally with the inferior gluteal artery and distally with the first perforating artery. This series of inosculations is sometimes spoken of as the *crucial anastomosis* of the thigh.

*Dissection.*—The dissector has now examined all the structures in the gluteal region which lie distal to the level of the piriformis. He should, in the next place, turn his attention to that portion of the dissection which lies proximal to the level of that muscle. There are found several structures which lie in close relation to the dorsum ilii. These are the glutæus medius, the glutæus minimus, and the tensor fasciæ latæ, together with the blood-vessels and nerve which supply them, viz., the superior gluteal artery and vein, and the superior gluteal nerve.

The posterior part of the glutæus medius muscle is covered by the glutæus maximus. Its anterior border is overlapped by the tensor fasciæ latæ, and the intermediate area is invested by the dense fascial layer already referred to. This fascia must be removed in order that a satisfactory view of the muscle may be obtained. It will then become evident that numerous fleshy fibres arise from the deep surface of the fascia.

**M. Glutæus Medius.**—The glutæus medius arises from that part of the dorsum ilii which is bounded above by the posterior curved line and the anterior four-fifths of the crest of the ilium, and below by the anterior curved line (Fig. 84, p. 222); it derives fibres also from the strong fascia which covers it. The fibres converge to form a flattened band, partly fleshy and partly tendinous, which is inserted into an oblique line on the lateral aspect of the greater trochanter of the femur, and into the surface immediately above it. The glutæus medius muscle is supplied by the *superior gluteal nerve.*

*Dissection.*—The glutæus medius must now be reflected. This dissection is complicated by the fact that in its proximal and anterior part the glutæus medius is partially blended with the subjacent glutæus minimus and the tensor fasciæ latæ. Begin by rotating the limb medially. Then, seizing the glutæus maximus with the left hand, pull it laterally, and divide the glistening aponeurosis into which it is inserted for two or three

inches in a distal direction. This will bring very conspicuously into view the proximal part of the vastus lateralis. Next, grasp the cut edge of the fascia lata from which the glutæus maximus has been separated, and, dragging it forcibly laterally, dissect in the interval between it and the glutæus medius. The tensor fasciæ latæ, which is intimately associated with this portion of the fascia lata, is pulled laterally with it, and the deep surface of that muscle, clothed by a strong deep lamella of fascia, comes into view. Very little dissection is required to expose its nerve of supply—a branch from the superior gluteal—which emerges from the anterior border of the glutæus minimus, and sinks into its deep surface. An artery will also be noticed ramifying on the deep surface of the tensor fasciæ latæ; this is the ascending branch of the lateral circumflex artery. Seeing that the anterior borders of the glutæus medius and glutæus minimus are adherent, it is well to separate them, from behind forwards, by introducing the fingers between their posterior borders. When the glutæus medius is completely isolated, it may be divided about two inches above the greater trochanter of the femur, and the two portions thrown respectively proximally and distally. A small bursa, between the muscle and the upper part of the greater trochanter, will thus be brought into view, and the exact insertion of the tendon will be rendered evident. As the proximal part of the muscle is raised, a number of vessels and nerves between it and the glutæus minimus will be exposed. These must be carefully cleaned and followed to their destinations. They are derived from the superior gluteal artery and nerve.

**Arteria Glutæa Superior.**—The superior gluteal artery is a large vessel which springs from the hypogastric artery and escapes from the pelvis, through the upper part of the greater sciatic foramen, above the level of the piriformis.

Immediately after its exit, it divides into a superficial and a deep division. The *superficial division* has been already seen during the reflection of the glutæus maximus. It is distributed to the deep surface of that muscle, and is placed between it and the glutæus medius.

The *deep division* bifurcates, close to its origin, into a superior and an inferior branch; both of these lie between the glutæus medius and minimus. The *superior branch* follows accurately the anterior curved line on the dorsum ilii, and, at the anterior superior spine, terminates by anastomosing with the superficial and deep circumflex iliac arteries, and with the ascending branch of the lateral circumflex artery. The latter has already been noticed passing proximally under cover of the tensor fasciæ latæ. The *inferior branch* runs distally and anteriorly towards the greater trochanter. It gives twigs to the two gluteal muscles between which it lies, and some terminal offsets to the hip-joint.

**Nervus Glutæus Superior.**—The superior gluteal nerve emerges from the pelvis in company with the superior gluteal artery, and passing anteriorly, between the glutæus medius and

minimus, gives branches to both these muscles. Its terminal branch pierces the anterior fibres of the glutæus minimus, and ends in the tensor fasciæ latæ.

**M. Glutæus Minimus.**—The glutæus minimus muscle arises from the broad area on the dorsum ilii, which is included between the anterior and inferior curved lines (Fig. 84, p. 222). The muscular fibres pass gradually into an aponeurotic tendon, which covers the superficial surface of the distal part of the muscle. This tendon, as it passes distally, narrows into a flattened band, which is inserted into a special impression on the anterior aspect of the greater trochanter of the femur (Fig. 75, p. 202). It is intimately connected, near its insertion, with the capsule of the hip-joint. The glutæus minimus is supplied by the *superior gluteal nerve*.

**Parts under cover of the Glutæus Minimus.**—The last step in the dissection of the gluteal region consists in the reflection of the glutæus minimus muscle. It must be detached from its origin and thrown distally. Three objects are revealed by this dissection—(1) the capsule of the hip-joint; (2) a bursa which intervenes between the tendon of the muscle and the greater trochanter; (3) the reflected tendon of the rectus femoris.

The *capsule* will be seen to be only loosely attached to the posterior aspect of the neck of the femur, but very firmly to the acetabular brim. The *bursa mucosa* should be opened and examined. The *reflected tendon* of the *rectus femoris* occupies a groove situated just above the upper margin of the acetabulum. It is partially concealed by some fibres of the capsule, which are prolonged upwards over it. It should be cleaned by repeatedly drawing the point of the knife over it in a direction parallel to its fibres.

## FOSSA POPLITEA (POPLITEAL SPACE).

It is well to dissect the popliteal fossa before the muscles of the posterior region of the thigh are disturbed. In this way the boundaries of the space are maintained in position during the examination of the structures which lie within it.

During the dissection of the popliteal fossa the following structures are brought into view:—

1. Superficial fascia.
2. The small saphenous vein.
3. The posterior cutaneous nerve of the thigh.
4. Popliteal fascia.
5. Muscles which bound the fossa.
   - Biceps femoris.
   - Semitendinosus.
   - Semimembranosus.
   - Gastrocnemius.
   - Plantaris.
6. The tibial and common peroneal nerves and their branches.
7. The popliteal artery and vein and their branches.
8. A few lymph glands.
9. A slender branch from the obturator nerve.
10. The popliteus muscle.

**Surface Anatomy.** — The space which lies immediately posterior to the knee-joint, and between the hamstring muscles and the two heads of the gastrocnemius, is termed *the ham.* It is depressed when the knee is flexed, but forms a slight prominence when the joint is fully extended. By flexing the knee and pressing deeply into the interval between the hamstrings, the (injected) popliteal artery may be distinguished, and its pulsations can usually be felt in this situation in the living subject. With the limb in the same position, the tendon of the biceps femoris, on the lateral side of the space, is distinctly seen, as it passes distally to its insertion into the head of the fibula. The head of the fibula lies posterior and a little distal to the most projecting part of the lateral condyle of the tibia, and by pressing deeply between the fibula and the lateral condyle of the femur, the cord-like fibular collateral ligament can be distinguished. When the knee-joint is flexed and the limb is abducted, the rounded tendon of the adductor magnus may be detected on the medial side. It should be traced distally to the adductor tubercle. That bony projection is placed on the femur at the point where the medial supracondylar ridge joins the proximal and posterior part of the medial condyle, and is an important landmark, inasmuch as it indicates the plane of junction between the distal epiphysis and the body of the femur. The common peroneal nerve (O.T. external popliteal) may be felt as it crosses the lateral side of the neck of the fibula, just before it pierces the peronæus longus muscle. In muscular subjects, on the proximal part of the back of the leg, the two heads of the gastrocnemius form prominent objects.

The posterior region of the thigh presents a smooth,

rounded surface. In thin subjects indications of the bellies of the hamstring muscles may be seen.

**Reflection of Skin.**—Before beginning the dissection a good-sized block should be placed under the knee so as to support the limb and render the muscles which bound the fossa tense. *Incisions*—(1) a vertical incision along the median line of the limb, beginning about five inches proximal to, and terminating about four inches distal to, the bend of the knee; (2) a transverse incision at the proximal end of the vertical incision; (3) a transverse incision at the distal extremity of the vertical incision. The two transverse incisions should extend almost half-way round the limb.

Two flaps of skin are thus mapped out, and these must be raised and thrown, the one medially and the other laterally.

**Superficial Fascia—Vena Saphena Parva** (O.T. **External Saphenous Vein**)**—Branches of the Posterior Cutaneous Nerve of the Thigh** (O.T. **Small Sciatic**).—The fatty layer upon which the skin rests is now brought into view, and the cutaneous nerves and vessels must be secured. First look for a small nerve—*a branch of the posterior cutaneous nerve of the thigh*—which passes distally over the space near the middle line, and, when this is found, dissect out the *small saphenous vein.* The vein ascends in the middle line of the leg, and when traced proximally it will be found to disappear from view by piercing the deep fascia, and entering the distal part of the popliteal fossa. The *terminal branch* of the *posterior cutaneous nerve of the thigh* pierces the popliteal fascia at the distal part of the fossa, where it will be seen lying close to the small saphenous vein.

In removing the superficial fascia care must be taken of the deep popliteal fascia, which is somewhat thin.

**Fascia Poplitea (Popliteal Fascia).**—Although thin, the deep fascia possesses considerable strength owing to the transverse fibres which are interwoven amidst its longitudinal fibres. As he removes the fascia the dissector will notice that it is firmly attached on each side to the tendons of the muscles which bound the fossa poplitea. Proximally, it is continuous with the fascia lata of the thigh.

Before opening up the fossa poplitea the dissector is recommended to read the two following paragraphs, which deal generally with its contents and boundaries.

**Contents of the Fossa.**—The principal objects within the popliteal fossa are the *popliteal artery* and *vein*, with their branches and tributaries, and the *tibial* and *common peroneal*

*nerves.* The artery and vein are placed deeply in the space, and in close contact with each other—the vein being superficial to the artery throughout. The *tibial nerve* and *the common peroneal nerve* lie more superficially. With the exception of the posterior cutaneous nerve of the thigh, which descends immediately subjacent to the deep fascia, the *tibial nerve* is the most superficial structure in the popliteal fossa. It lies superficial to the popliteal vessels, and is readily found by separating the adipose tissue in the middle line of the fossa. The *common peroneal nerve* will be exposed by dissecting along the proximo-lateral boundary of the space. It lies under shelter of the biceps femoris muscle. Both of these large nerves give off branches, of which the majority are easily secured and readily followed. The articular twigs, however, are very delicate, and great care is required in their dissection.

In intimate relation to the popliteal artery is the *geniculate branch of the obturator nerve.* It descends in close apposition with the coats of the artery. As the fat is being cleared out from the fossa the dissector should not fail to observe some small *lymph glands* in relation to the great vessels.

**Boundaries.** — The popliteal fossa is diamond-shaped. Proximally and laterally it is bounded by the *biceps femoris muscle*; whilst proximally and medially are the *semitendinosus* and the *semimembranosus muscles*, the former lying upon the posterior surface of the latter. On the medial side of the knee, anterior to the semimembranosus, the *gracilis*, the *sartorius*, and the tendon of the *adductor magnus*, can be exposed. The fossa is bounded, distally, by the converging heads of the *gastrocnemius*. In the formation of the distal and lateral boundary, the lateral head of the gastrocnemius will be seen to be assisted by the small *plantaris muscle.*

*Dissection.*—In cleaning the muscles which bound the popliteal fossa there are certain points to be attended to. In the case of the lateral head of the gastrocnemius, care must be taken not to remove the *anastomotic peroneal nerve*, which passes distally and medially upon its surface. In the groove between the heads of the muscle will be seen the *medial cutaneous nerve of the calf.* Further, the dissector must not overlook the mucous bursa which intervenes between the tendon of the semimembranosus and the medial head of the gastrocnemius. This bursa sometimes communicates with a second bursa, which will be brought into view by lifting the medial head of the gastrocnemius from the medial condyle of the femur.

The dissection may be carried in an anterior direction on the medial aspect of the limb a little beyond the medial boundary of the fossa, in order to expose the saphenous branch of the arteria genu suprema, the

saphenous nerve, great saphenous vein, and the posterior division of the medial cutaneous branch of the femoral nerve. The *saphenous nerve*, accompanied by the *saphenous branch of the arteria genu suprema*, will be found under cover of the sartorius. They afterwards come to the surface at its posterior border. The *great saphenous vein* ascends on the surface

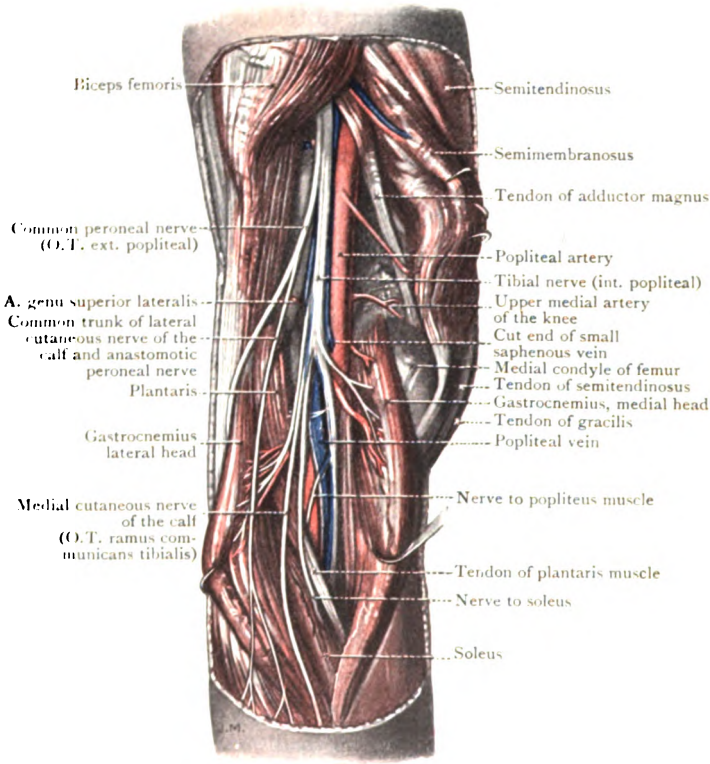


FIG. 87.—Dissection of the Left Popliteal Fossa. The proximal boundaries have been pulled apart and the aponeurosis into which the two heads of the gastrocnemius is attached has been split and the heads have been displaced to their respective sides.

of that muscle, whilst the *posterior division* of the *medial cutaneous nerve of the thigh* (O.T. *internal cutaneous*) courses distally along the posterior border of the same muscle, and comes to the surface a short distance posterior to the saphenous nerve. Properly speaking, these structures belong to the thigh and they have already been seen in the dissection of its medial region (p. 1083). When the boundaries of the fossa are thoroughly

defined and cleaned, the contents should be dissected by removing the soft fat which surrounds them.

The dissection of the fossa should be carried out over the entire area at the same time. The heads of the gastrocnemius muscle, therefore, should be well separated from each other. It is here that the dissection becomes tedious, because the numerous branches of the nerves and vessels to the muscles on the back of the leg require time and care for their dissection.

The floor of the fossa must now be cleaned. Scrape the fatty tissue from the popliteal surface of the femur with the handle of the knife.

It is during this stage of the dissection that the genicular branches of the popliteal artery are liable to injury, as they lie in close contact with the floor. Be especially careful not to injure the middle genicular artery which pierces the posterior part of the capsule of the joint, and the superior genicular arteries which wind round the femur, immediately proximal to the condyles. The fascia covering the popliteus muscle should be left in position.

**The Fossa Poplitea as seen in a Section through the Frozen Knee.**—The diamond-shaped space on the back of the knee-joint which is brought into view by dissection, differs widely from the condition which is observed when transverse sections are made through this part of the frozen limb (Fig. 88). Before the integuments and fasciæ are removed all the parts are tightly braced together, and the fossa poplitea is represented merely by a small intermuscular interval between the distal parts of the hamstring muscles. The fossa in this condition is rather under an inch wide at its broadest part. The popliteal artery, therefore, as it traverses the space, is covered by muscles throughout its whole course, with the exception of a very small part immediately proximal to the knee-joint.

**Floor of the Fossa.**—The floor is formed proximo-distally by—(1) the popliteal surface of the femur; (2) the oblique popliteal ligament of the knee-joint; and (3) by the strong fascia which covers the popliteus muscle.

**Nervus Cutaneus Femoris Posterior** (O.T. **Small Sciatic**).—The posterior cutaneous nerve of the thigh enters the popliteal fossa at its proximal angle, and proceeds distally, immediately subjacent to the deep fascia. It gives one or two twigs through the fascia to the skin, and finally pierces the fascia in the distal part of the fossa. Its terminal twigs are distributed to the skin over the proximal part of the calf of the leg.

**Nervus Tibialis** (O.T. **Internal Popliteal Nerve**).—The tibial nerve enters the popliteal fossa, by emerging from under cover of the biceps femoris, and runs distally so as to bisect the fossa longitudinally. It is the larger of the two terminal branches of the sciatic nerve, and it arises about the middle of the thigh. At the distal border of the popliteus muscle it leaves the popliteal fossa and passes into the posterior region of the leg. The superficial position of the tibial nerve has already been referred to. At first upon the lateral side of the popliteal vessels, it crosses them superficially, and in the distal part of

the fossa it is placed medial to them. Its *branches* may be classified into cutaneous, muscular, and articular.

The *medial cutaneous nerve of the calf* is its cutaneous branch, which arises about the middle of the fossa, and proceeds distally in the furrow between the two heads of the gastrocnemius. It will afterwards be seen to unite with the peroneal anastomotic nerve, a little distal to the middle of the calf of the leg, to form the nervus suralis.

The *muscular branches* supply both heads of the gastrocnemius, the plantaris, the soleus, and the popliteus: they

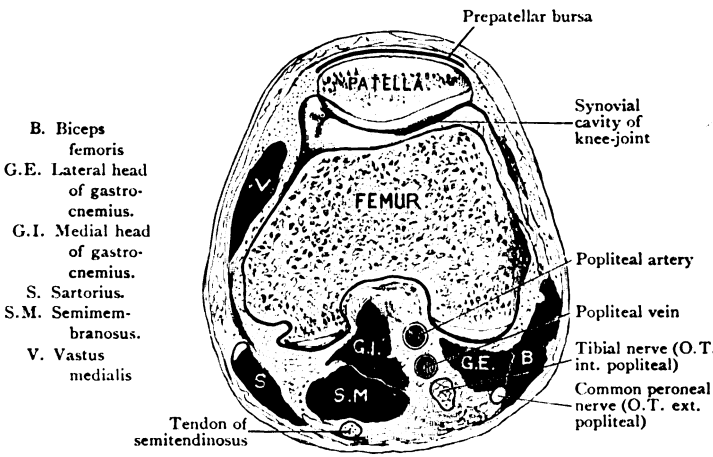


FIG. 88.—Transverse section through the Popliteal Fossa of the Right Inferior Extremity.

come off in the distal part of the fossa. The branch to the popliteus requires special notice. It arises more distally than the others, and crosses the superficial surface of the popliteal artery to reach the lateral side of that vessel. It then runs distally on the posterior surface of the popliteus muscle, and gains the anterior surface by winding round the distal border. This will be better seen when the muscle itself is dissected.

The *articular branches* are three in number. They are given off by the tibial nerve in the proximal part of the fossa, and they accompany the middle genicular artery and the two medial genicular arteries. That which accompanies the inferior medial artery is larger than the other two, and can

be easily discovered as it runs along the proximal border of the popliteus muscle.

**Nervus Peronæus Communis** (O.T. **External Popliteal**).—The common peroneal nerve is the smaller of the two terminal

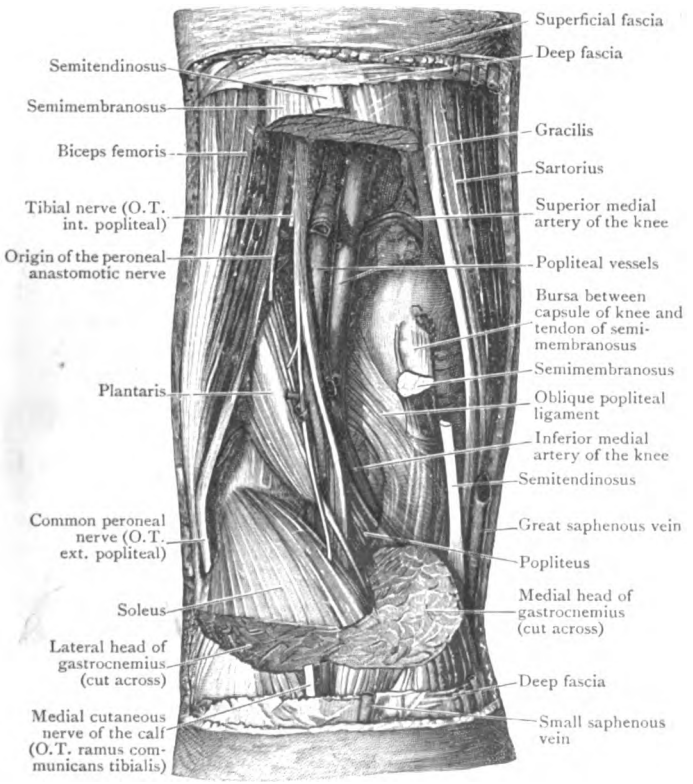


FIG. 89.—Popliteal Fossa. The two heads of the gastrocnemius and portions of the semimembranosus and semitendinosus have been removed so as to display more fully the contents of the fossa.

branches of the sciatic nerve, and it ends on the lateral side of the neck of the fibula by dividing into the deep and the superficial peroneal nerves. It does not traverse the entire length of the popliteal fossa, for it runs distally and laterally along the medial side of the biceps femoris, and leaves the fossa

by following closely the tendon of that muscle. It next lies in the interval between the lateral head of the gastrocnemius and the biceps femoris, and finally turning anteriorly, round the neck of the fibula, it ends under cover of the proximal part of the peronæus longus. It gives off cutaneous and articular branches.

The *cutaneous branches* are two in number, viz., the anastomotic peroneal nerve, and the lateral cutaneous nerve of the calf, which supplies the skin on the anterior and lateral aspect of the proximal part of the leg. They frequently take origin by a common trunk. The *anastomotic peroneal nerve* arises from the common peroneal trunk in the popliteal fossa, and is continued distally over the lateral head of the gastrocnemius. It ultimately unites with the medial cutaneous nerve of the calf to form the nervus suralis.

The *articular branches* are three in number. They accompany the lateral genicular branches of the popliteal artery, and the anterior recurrent tibial branch of the anterior tibial artery. They are of small size and difficult to dissect. The *recurrent articular nerve* springs from the termination of the common peroneal nerve, and will be dissected at a later stage.

**Arteria Poplitea.**—The popliteal artery is the terminal part of the great arterial trunk of the lower limb. It begins at the opening in the adductor magnus, where it is continuous with the femoral artery; and it ends, at the distal border of the popliteus muscle, by dividing into the anterior and posterior tibial arteries. This division is at present hidden from view by the proximal border of the soleus muscle, but it will be exposed in the dissection of the leg.

The course which the popliteal artery takes through the popliteal fossa is not straight. In the first instance it inclines obliquely distally and laterally, so as to gain the middle of the fossa between the two condyles of the femur. From this point to its termination it takes a vertical course. Throughout the greater part of its length it is placed deeply. In the proximal part of the fossa it is covered by the semimembranosus, but when it gains the interval between the two condyles, although it lies deeply in the fat of the fossa, it is covered merely by the integuments and fasciæ. This part of the vessel is very short, however,—not more than about an inch,—because it at once passes onwards between and anterior to the two heads of the gastrocnemius, is crossed by

the plantaris, and finally at its termination it sinks under cover of the proximal border of the soleus. Throughout its whole course the popliteal artery rests upon the floor of the popliteal fossa. In its proximal part it is separated from the femur by some fatty tissue; then it crosses the oblique ligament of the knee-joint; and lastly it comes into contact with the fascia covering the popliteus muscle.

The *popliteal vein* is placed upon a more superficial plane, and crosses the artery. In the proximal part of the fossa it is placed upon the lateral side of the artery, whereas in the distal part it is situated upon its medial side. The two vessels, however, are in close association throughout, and are bound together by a dense fibrous sheath.

The *tibial nerve* is superficial to both vessels, and crosses both from the lateral to the medial side; in the proximal part of the fossa it lies lateral to the vein, but in the distal part it lies on the medial side. Figs. 87, 89, 117.

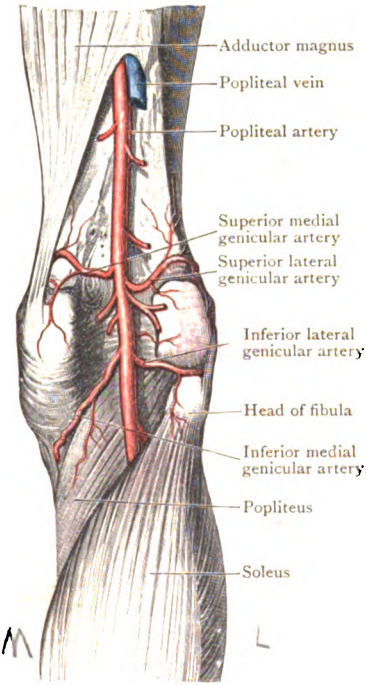


FIG. 90.—Popliteal Artery and its Branches.

The *branches of the popliteal artery* are:—

1. Muscular.
2. Cutaneous.
3. Genicular.

The *muscular branches* consist of a proximal and a distal set. The *proximal branches* are distributed to the hamstring muscles near their insertions. The *distal branches*, termed the *sural arteries*, end chiefly in the two heads of the gastrocnemius; but twigs go also to the soleus and plantaris.

The *cutaneous branch*, called the *superficial sural*, usually

arises from one of the sural muscular branches, and supplies the integument over the proximal part of the calf of the leg. It lies in the groove between the two heads of the gastrocnemius, with the medial cutaneous nerve of the calf.

The *genicular arteries* are five in number, viz., two superior, two inferior, and one middle or azygos.

**Arteriæ Genu Superiores (Superior Articular Arteries).**—The two superior genicular arteries spring from the main trunk as it passes between the condyles of the femur. One proceeds from each side of the popliteal, and they are called *medial* and *lateral*, according to the direction which they take. They will be found resting directly upon the popliteal surface of the femur, and will be observed to incline slightly proximally, and then to wind round the bone immediately proximal to the condyles. The lateral artery is the larger of the two. The student is apt to mistake a muscular branch for one or other of these yessels; but their close apposition to the femur should in all cases be sufficient to distinguish them.

The *superior lateral genicular artery* runs laterally under cover of the biceps femoris, and disappears from the popliteal fossa by piercing the lateral intermuscular septum and entering the substance of the vastus intermedius. The *superior medial genicular artery* proceeds medially under cover of the semimembranosus, and leaves the popliteal fossa by passing forwards, under cover of the tendon of the adductor magnus, to reach the deep surface of the vastus medialis.

**Arteriæ Genu Inferiores (Inferior Articular Arteries).**—The two inferior genicular arteries arise from the popliteal as it lies on the distal part of the oblique popliteal ligament. The *lateral inferior genicular artery* takes a transverse course laterally, under cover of the plantaris and lateral head of the gastrocnemius, to gain a point on the lateral side of the knee, immediately proximal to the head of the fibula. It proceeds onwards under cover of the fibular collateral ligament of the knee-joint. The *medial inferior genicular artery* takes an oblique course distally and medially, under cover of the medial head of the gastrocnemius, and along the proximal border of the popliteus muscle, to gain the medial side of the tibia distal to the medial condyle. There it turns forwards under cover of the tibial collateral ligament of the knee.

**Arteria Genu Media** (O.T. **Azygos Articular Artery**).—The middle genicular artery springs from the popliteal as it lies

upon the oblique popliteal ligament of the knee-joint. It pierces this ligament to reach the synovial layer.

**Vena Poplitea.**—The popliteal vein is formed, near the distal border of the popliteus muscle, by the union of the venæ comites of the anterior and posterior tibial arteries. It runs proximally through the popliteal fossa, and, entering the adductor canal through the opening in the adductor magnus, it becomes the femoral vein. The relations which it presents to the popliteal artery have already been detailed. In addition to tributaries corresponding to branches of the artery, it receives the small saphenous vein, which has been seen piercing the popliteal fascia to join it. By slitting it open with the scissors the dissector will see that it possesses three (sometimes four) valves in its interior.

The *Genicular Branch of the Obturator Nerve.*—This slender nerve may be found lying upon the postero-medial side of the popliteal artery. Trace it proximally and it will be seen to enter the space by piercing the distal fibres of the adductor magnus; follow it distally, and it will be observed to enter the knee-joint by penetrating the oblique popliteal ligament.

## BACK OF THE THIGH.

The dissection of the back of the thigh must be completed on the fifth day. The following are the structures which are brought into view:—

1. Superficial fascia.
2. Cutaneous nerves.
3. Deep fascia.
4. Muscles, { Biceps femoris. / Semitendinosus. / Semimembranosus. / Adductor magnus.
5. Nerves, { Posterior cutaneous of thigh. / Sciatic.
6. Arteries, Four perforating.

**Reflection of Skin.**—A vertical incision must be made in the median line of the thigh through the belt of skin which still encircles the limb posteriorly. The two flaps can then be reflected, the one laterally and the other medially.

**Superficial Fascia—Cutaneous Nerves.**—In the fatty superficial fascia thus brought into view cutaneous twigs from four sources must be looked for—(1) along the *median line* of the

limb a few minute branches from the *posterior cutaneous nerve of the thigh* may be discovered; (2) towards the *lateral side* of the thigh some twigs from the *lateral cutaneous nerve of the thigh* may be detected; (3) lastly, towards the *medial aspect* of the limb endeavour to find some offsets from the *medial cutaneous* (O.T. *internal cutaneous*) branch of the femoral nerve, and twigs of the *obturator nerve*.

**Deep Fascia.**—When the superficial fascia is removed the deep fascia will be observed to be exceedingly thin. It must now be turned aside; and in doing this be careful of the trunk of the posterior cutaneous nerve of the thigh, which passes distally, in the middle line of the limb, immediately subjacent to the fascia.

**Hamstring Muscles.**—The hamstring muscles are three in number, viz., the biceps femoris, the semitendinosus, and the semimembranosus. They stretch from the tuberosity of the ischium to the proximal ends of the tibia and fibula. The *biceps femoris* is recognised from its diverging laterally to form the lateral and proximal boundary of the popliteal fossa. The *semitendinosus* and *semimembranosus* extend distally on the medial side of the posterior aspect of the thigh, the former on the superficial aspect of the latter.

In cleaning these muscles the dissector should proceed cautiously to work; otherwise he will injure the arterial and nerve twigs which enter them. The latter may be easily secured by pulling proximally the proximal part of the sciatic nerve, and at the same time gently separating the muscles with the fingers.

**M. Biceps Femoris.**—The biceps femoris arises by two heads—a *long*, or *ischial*, and a *short*, or *femoral*,—and is inserted, chiefly, into the head of the fibula. The *long head* arises from the ischium by a tendon which is common to it and the semitendinosus (Fig. 74, p. 200). This tendon is implanted into the medial of the two impressions which mark the upper part of the tuber ischiadicum. Some fibres from the sacro-tuberous ligament are continued into it. The *short head* arises from the back of the femur distal to the insertion of the glutæus maximus, viz., from the lateral lip of the linea aspera, from the proximal half of the lateral supracondylar ridge, and from the lateral intermuscular septum. Its parallel fibres run obliquely distally and laterally, and join the anterior and medial surface of the tendon of insertion. This tendon, on the lateral

aspect of the knee-joint, is split into an anterior and a

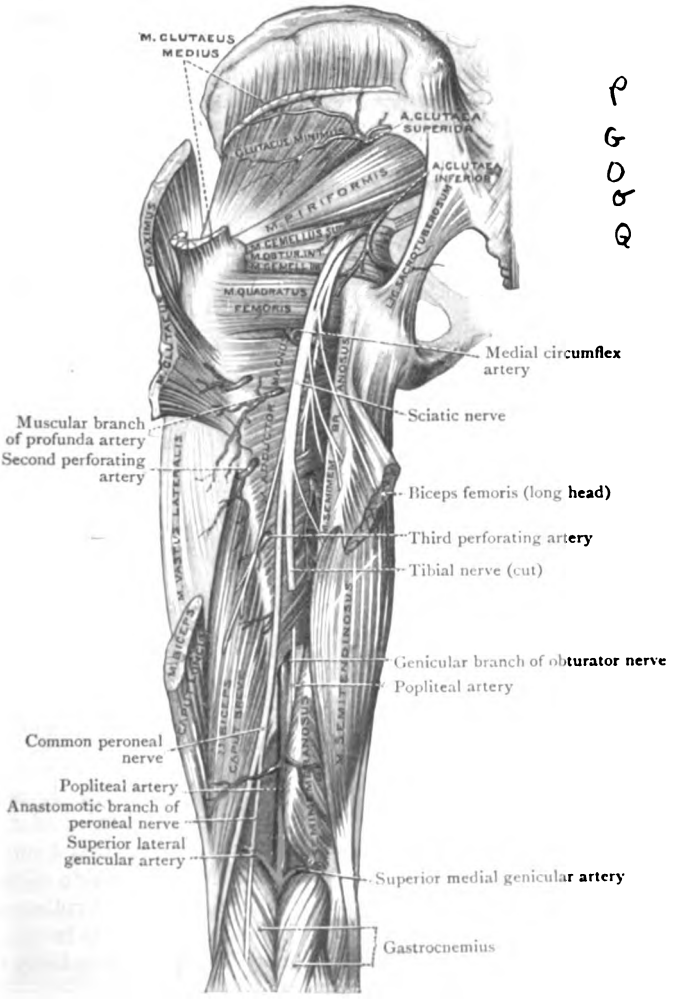


FIG. 91.—Dissection of the Posterior Region of the Thigh.

posterior part by the fibular collateral ligament. Both are inserted into the head of the fibula, anterior to the apex of

the head, but the posterior slip gives an aponeurotic extension to the fascia of the leg, whilst the anterior part gives off a slip (in some cases strong, but generally feeble) to the adjacent part of the lateral condyle of the tibia.

**M. Semitendinosus.**—This muscle arises from the medial impression on the superior part of the tuberosity of the ischium by a tendon common to it and the long head of the biceps femoris, and also by fleshy fibres directly from the bone (Fig. 74, p. 200). A narrow, tendinous intersection appears on the posterior surface of the muscle about the

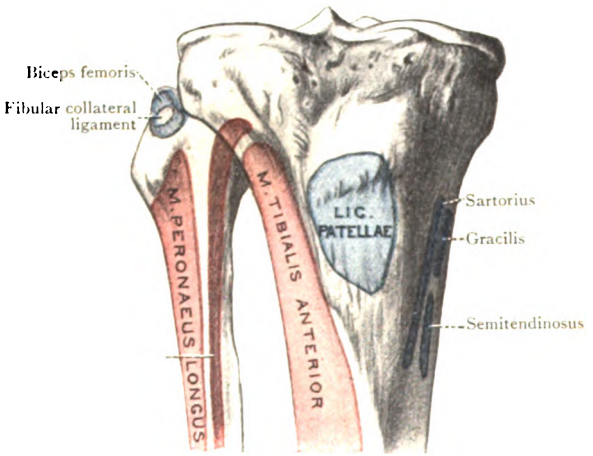


FIG. 92.—Anterior aspect of Proximal Portions of Bones of Leg with Attachments of Muscles mapped out.

middle of the thigh, and is directed obliquely distally and laterally. The muscular belly ends, in the distal third of the thigh, in a long cylindrical tendon which passes distally on the semimembranosus muscle. On the medial side of the knee the tendon bends anteriorly, crosses the tibial collateral ligament of the knee-joint, and, becoming flattened, is inserted into the proximal part of the medial surface of the body of the tibia, near the anterior crest of that bone, and immediately distal to the tendon of the gracilis. From its distal border aponeurotic fibres pass into the deep fascia of the leg; its proximal border is adherent to the gracilis for about half an inch from its insertion, and both tendons are concealed by the

expanded insertion of the sartorius. A mucous bursa lies between the three tendons and the tibial collateral ligament of the knee-joint.

**M. Semimembranosus.**—The semimembranosus muscle arises from the lateral impression on the upper part of the tuberosity of the ischium (Fig. 74, p. 200). The tendon of origin is broad at its attachment to the bone, and narrows as it passes medially beneath the origin of the biceps femoris; it then expands again, and, passing distally and medially, anterior to the semitendinosus, is folded in such a manner as to form a groove, in which the latter muscle lies. The tendon of insertion is inserted chiefly into the groove on the back of the medial condyle of the tibia, under cover of the tibial collateral ligament of the knee-joint. Three additional attachments, however, require to be noted. These are effected by aponeurotic extensions from the tendon of insertion—(1) to the back of the knee-joint, forming a considerable part of the oblique popliteal ligament; (2) to the surface of the popliteus muscle, which is covered by the expansion; and (3) to the tibial collateral ligament of the knee-joint.

**Nervus Ischiadicus** (O.T. **Great Sciatic Nerve**).—The sciatic nerve commences at the lower border of the greater sciatic foramen, and usually terminates about the middle of the thigh by dividing into the tibial nerve and common peroneal nerve. Its relations in the gluteal region have already been studied. In the thigh it lies on the posterior surface of the adductor magnus muscle, and is covered by the long head of the biceps femoris. It gives branches to both heads of the biceps, to the semitendinosus, to the semimembranosus, and to the adductor magnus; the branches to the two last-named muscles arise by a common trunk. In a few cases it may be observed to give off a long articular twig, which enters the popliteal fossa and takes the place of the lateral superior articular nerve, which, as a rule, comes from the common peroneal nerve.

*Dissection.*—To bring the adductor magnus more fully into view, and to facilitate the cleaning of its posterior surface, and at the same time to follow the terminal parts of the perforating arteries, the hamstring muscles should be detached from their origins and thrown distally. First detach the common tendon of the biceps femoris and semitendinosus from the ischial tuberosity. When this has been done the exact attachment of the semimembranosus is displayed, and after that muscle has been again examined, under the present more advantageous circumstances, it also

must be detached from its origin and turned distally. The posterior surface of the adductor magnus will then be fully exposed, and its attachment to the femur and its relations to the perforating arteries can be studied.

**Arteriæ Perforantes.**—Four perforating arteries, branches of the profunda femoris, will be found in the posterior part of the thigh between the adductor magnus muscle and the femur, close to the linea aspera. They are called *first*, *second*, *third*, and *fourth*, according to the level at which they appear, proximo-distally. The *fourth* is the terminal branch of the profunda, and makes its appearance about an inch proximal to the opening in the adductor magnus muscle through which the popliteal artery enters the popliteal fossa. The perforating arteries and their branches must be thoroughly cleaned, together with the apertures in the adductor magnus through which they pass. It will then be seen that they do not pierce the fleshy substance of the muscle. Prepared for each is a tendinous archway, and they reach the posterior region of the thigh by passing between these and the linea aspera, to which the piers of the various arches are attached.

The openings are in the same line with, and are in all respects analogous to the large opening in the adductor magnus muscle for the popliteal artery. The result obtained is the same in each case. When the muscle contracts, the vessels are protected from pressure.

Emerging from the tendinous arches the perforating arteries wind round the posterior border of the femur to gain its lateral aspect and reach the vastus lateralis, in which they end. In this part of their course they pierce the short head of the biceps femoris. The highest member of the series, which lies proximal to the level of the femoral attachment of the biceps, pierces, as we have already seen, the insertion of the glutæus maximus.

**Anastomosis on the Posterior Aspect of the Thigh.**—In a well-injected subject a chain of arterial anastomoses can be traced from the gluteal region to the popliteal fossa, and the present is the best time to examine it. Commencing proximally, in the gluteal region, the superior gluteal artery is found anastomosing with the inferior gluteal, and the inferior gluteal with the terminal branches of the medial circumflex artery. In the posterior part of the thigh the

chain of anastomoses is carried distally by the medial and lateral circumflex arteries anastomosing with the first perforating artery, and by anastomoses between the perforating arteries. The chain is completed distally by anastomoses between the most distal perforating arteries and the muscular branches given from the popliteal artery to the hamstring muscles.

*Dissection.*—At the end of the fifth day after the subject has been placed upon its face, the dissector must paint the various parts in the gluteal and thigh regions with the preservative solution, replace them in position, and fix the skin flaps over them with a few points of suture. On the morning of the following day he will find the body replaced upon its back, with the pelvis and thorax supported by blocks, and he must at once proceed to study any part of the medial region of the thigh previously left undissected, and to the examination of the hip-joint.

**Articulatio Coxæ (Hip-joint).**—The hip-joint is the most perfect example of an enarthrosis or ball-and-socket joint in the body. It does not allow so free a range of movement as that which takes place at the shoulder-joint, but what it loses in this respect it gains in strength and stability. Its great strength and security depend—(1) upon the depth of the acetabulum and the thorough manner in which the head of the femur is received into it; (2) upon the tension and power of the ligaments; (3) upon the length and oblique direction of the neck of the femur; and (4) upon atmospheric pressure.

The *ligaments* in connection with the hip-joint are:—

1. Capsula articularis.
2. Ligamentum teres.
3. Labrum glenoidale.
4. Lig. transversum acetabuli.

The capsule and the ligamentum teres are attached to both bones entering into the construction of the joint. The transverse ligament and the labrum glenoidale are connected with the hip bone only; the former partially fills the acetabular notch whilst the latter surrounds the circumference of the acetabulum in a ring-like fashion, and serves to deepen it still further.

**Capsula Articularis.**—The fibrous stratum of the articular capsule is exceedingly strong, and surrounds the joint on all sides. *Proximally*, it is attached around the acetabulum; above and posteriorly directly to the hip bone, just beyond the rim of the cavity; anteriorly, to the superficial aspect of the labrum glenoidale; and below, to the transverse ligament. *Distally*,

it clasps the neck of the femur, and anteriorly, it is attached to the whole length of the intertrochanteric line, and to the root of the greater trochanter. This attachment is very firm and strong. Posteriorly and distally, it falls short of the intertrochanteric crest by about half an inch, and it presents a weak attachment to the distal part of the posterior surface of the neck of the femur.

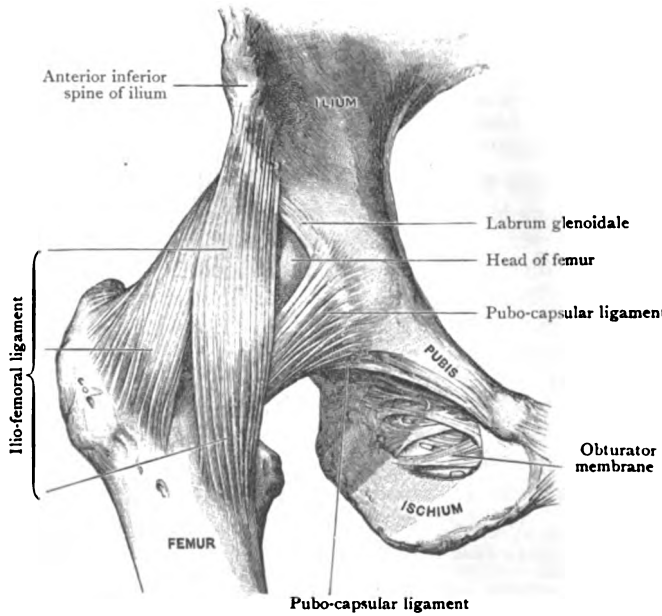


FIG. 93.—Dissection of Hip-joint from the front.

When the capsule of the hip-joint has been carefully cleaned it will be seen that the fibres which compose it run in two different directions. The majority pass in a longitudinal direction from one bone to the other; others, however, may be observed to take *a course* more or less *at right angles to the former*. The latter are seen to advantage only on the posterior aspect of the capsule, where they were noted during the dissection of the gluteal region. The longitudinal fibres are massed on the front of the joint. Certain thickened

portions of the capsule, with more or less distinct attachments, are described under special names. These are:—

1. Ilio-femoral ligament.
2. Pubo-capsular ligament.
3. Ischio-capsular ligament.
4. The zona orbicularis.

*Ligamentum Iliofemorale.*—The ilio-femoral ligament is placed over the front of the articulation, and constitutes the thickest and most powerful part of the capsule. It springs from the anterior inferior spine of the ilium, and from a depressed surface on the bone immediately to the *lateral* side of *the spine.* As it proceeds distally and laterally, it divides into two limbs, which diverge slightly from each other. The *more lateral* portion is implanted into the proximal part of the intertrochanteric line, close to the greater trochanter; the medial portion, longer and almost vertical in direction, passes distally to find attachment into the distal end of the intertrochanteric line. The interval between the two diverging parts of this ligament is occupied by a thinner portion of the capsule. The ilio-femoral ligament is sometimes called the *Y-shaped ligament*, but, in making use of this term, remember that the shape it presents is that of an inverted Y.

*Ligamentum Pubocapsulare* (O.T. *Pubo-femoral Ligament*).—The pubo-capsular ligament is the name applied to fasciculi which spring from the pubic bone and the obturator membrane, and join the distal and anterior aspect of the capsule. In cases where the bursa under the ilio-psoas is continuous with the cavity of the joint, the aperture of communication is placed between this band and the ilio-femoral ligament.

*Ligamentum Ischiocapsulare* (O.T. *Ischio-femoral Ligament*).—The ischio-capsular ligament is a comparatively weak band which springs from the ischium below the acetabulum and passes upwards and laterally, anterior to the tendon of the obturator externus. It terminates in the capsule.

*Zona Orbicularis* (O.T. *Orbicular Ligament*).—The zona orbicularis is composed of circular fibres, which are most distinct on the posterior aspect of the capsule. It encircles the neck of the femur posteriorly and distally, but is lost as it is traced anteriorly towards the proximal and anterior parts of the capsule.

The dissector has already noted the close connection which is exhibited between the capsule of the hip-joint and the tendons of the glutæus minimus, and the reflected head of the rectus femoris. Reinforcing fibres are contributed to the capsule by both of those tendons.

**Movements permitted at the Hip-joint.**—Before the capsule of the joint is opened the range of movement which is permitted at the hip-joint should be tested. *Flexion*, or forward movement, is very free, and is checked by the anterior surface of the thigh coming into contact with the abdominal wall. *Extension*, or backward movement, is limited by the ilio-femoral ligament. That powerful ligament has a most important part to play in preserving the upright attitude with the least possible expenditure of muscular exertion. In the erect posture the line of gravity falls slightly behind the line joining the central points of the two hip-joints. In the upright attitude the ilio-femoral ligaments are tense, and prevent the pelvis from rolling backwards on the heads of the femora. *Abduction*, or lateral movement of the limb, is checked by the pubo-capsular ligament. *Adduction*, or medial movement (*e.g.* as in crossing one thigh over the other), is limited by the proximal portion of the ilio-femoral ligament and the proximal part of the capsule. *Rotation medially* tightens the ischio-capsular ligament, and is therefore, in a measure, restrained by it. *Rotation laterally* is limited by the lateral portion of the ilio-femoral ligament. In *circumduction*, which is produced by combination of the movements of flexion, abduction, extension, and adduction, different parts of the capsular ligament are tightened at different stages of the movement.

The *flexor muscles*, which operate on the femur at the hip-joint, are chiefly—(1) the ilio-psoas, (2) the pectineus, and (3) the rectus femoris; the *extensors* are—(1) the glutæus maximus, and (2) the glutæus medius; (3) the hamstrings; the *abductors*—(1) the upper part of the glutæus maximus, (2) the glutæus medius, (3) the glutæus minimus; the *adductors*—(1) the three adductors, (2) the pectineus, (3) the distal part of the glutæus maximus, and (4) the obturator externus; the *medial rotators*—(1) the anterior part of the glutæus medius, (2) the anterior part of the glutæus minimus, (3) the tensor fasciæ latæ, and (4) the ilio-psoas; the *lateral rotators*—(1) the two obturator muscles, (2) the gemelli, (3) the piriformis, (4) the quadratus femoris, and (5) the distal fibres of the glutæus maximus.

It should be noted that the muscle fibres which act as lateral rotators when the body is erect, become abductors when the hip-joint is flexed, and that the ilio-psoas is a flexor of the hip-joint and a medial rotator of the thigh until flexion is almost complete, but then it becomes a lateral rotator.

*Dissection.*—The hip-joint may now be opened, and in doing this it is advisable to remove, in the first instance, the whole capsule, with the exception of the ilio-femoral ligament. The enormous strength of that portion of the capsule can then be appreciated. It is fully a quarter of an inch thick, and a strain varying from 250 lbs. to 750 lbs. is required for its rupture (Bigelow). It is very rarely torn asunder in dislocations, and consequently the surgeon is enabled in most cases to reduce the displacement by manipulation. The ilio-femoral ligament may now be removed.

**Labrum Glenoidale** (O.T. **Cotyloid Ligament**).—The labrum glenoidale is a firm fibro-cartilaginous ring, which is fixed to the brim or margin of the acetabulum. It bridges across the notch, and thus completes the circumference of the cavity, deepens it, and at the same time narrows slightly its mouth. The labrum glenoidale fits closely upon the head of the femur, and, acting like a sucker, exercises an important influence in retaining it in place. Both surfaces of the labrum are covered by synovial

membrane; its free margin is thin, but it is much thicker at its attachment to the acetabular brim.

**Ligamentum Transversum Acetabuli.**—The transverse ligament consists of transverse fibres which bridge across the acetabular notch, and are attached to its margins. It

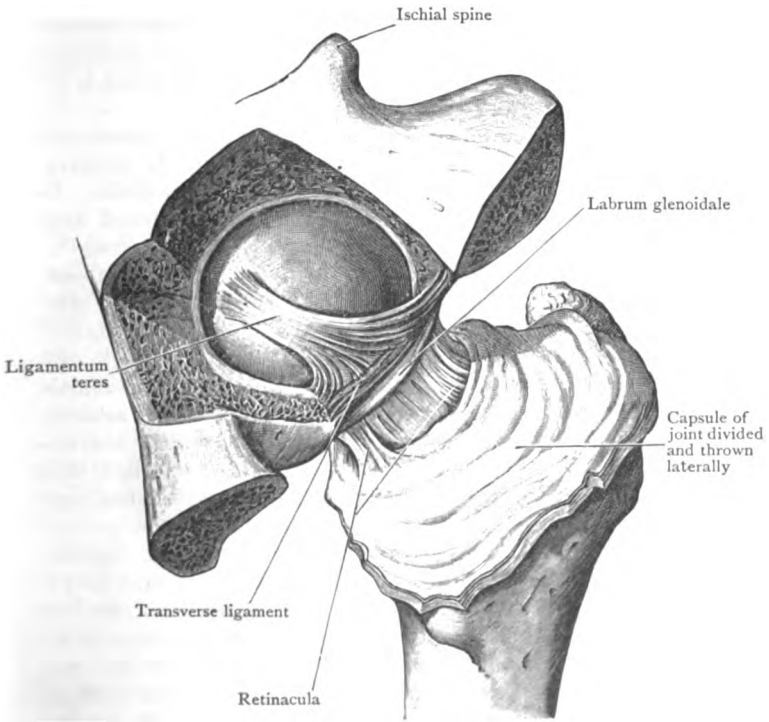


FIG. 94.—Dissection of Hip-joint from behind. The bottom of the acetabulum has been removed to show the ligamentum teres.

lies between the labrum glenoidale laterally and the bottom of the notch medially, but a space is left between the medial margin of the ligament and the bottom of the incisura through which vessels and nerves enter the joint. The lateral margin of the ligament is attached to the labrum glenoidale.

**Ligamentum Teres Femoris.**—The ligamentum teres is

not round, as its name might lead one to expect, but is somewhat flattened and triangular in shape. Its narrow femoral extremity is implanted into the proximal margin of the fovea capitis femoris, whilst its flattened acetabular end is bifid, and is fixed to the margins of the acetabular notch, and also to the transverse ligament. This attachment can be defined by removing the synovial layer and some areolar tissue. The ligamentum teres is surrounded by a prolongation of the synovial layer, and a small artery runs along it to the head of the femur.

It is difficult to understand the part which the ligamentum teres plays in the mechanism of the hip-joint. It presents very different degrees of strength in different individuals. It becomes very tense when the thigh is slightly flexed and then adducted.

**The Interior of the Joint and the Synovial Stratum.**—A mass of soft fat occupies the non-articular bottom of the acetabulum. Upon this the ligamentum teres is placed, and blood-vessels and nerves enter it by passing through the notch under cover of the transverse ligament. The vessels come from the medial circumflex and the obturator arteries, and the nerves come from the anterior branch of the obturator nerve, and from the accessory obturator, when it is present. A nerve-twig is also supplied to the posterior part of the joint by the nerve to the quadratus femoris.

The *synovial stratum* lines the interior of the capsule. From that it is reflected on to the neck of the femur, and it clothes the bone as far as the margin of the articular cartilage which covers the head. Along the line of reflection some fibres of the fibrous stratum proceed proximally on the neck of the femur and raise the synovial layer in the form of ridges. These fibres are termed the *retinacula* or *cervical ligaments.*

The *retinacula* are of some surgical importance. In intracapsular fracture of the neck of the femur they may escape rupture, and they may then, to some extent, help to retain the fragments in apposition. Hence examinations of this class of fracture must be conducted gently, lest by rupturing this ligamentous connection the fragments be permanently displaced.

At the acetabular attachment of the capsule the synovial membrane is reflected on to the labrum glenoidale and invests both its surfaces. It also covers the articular surface

of the transverse ligament and the cushion of fat which occupies the bottom of the cavity. Lastly, it gives a tubular investment to the ligamentum teres.

**Removal of the Limb.**—The limb may now be removed from the trunk by dividing the ligamentum teres. It should then be taken to one of the tables set aside for the dissection of separate parts. Before proceeding to the dissection of the leg it is advisable to study the attachments of the various muscles to the femur. The bulk of these may be removed, but a small portion of each should be left, so that their connections may again be revised, should it be found necessary to do so at a later period.

## THE LEG.

**Surface Anatomy.**—The relation of the tibia and fibula to the surface should be carefully investigated. The sharp crista anterior or shin of the tibia does not form a projection visible to the eye, but, nevertheless, it is subcutaneous, and can be very distinctly felt when the finger is passed along it. It pursues a slightly sinuous course and, in its distal part, becomes rounded-off and indistinct. The broad, flat, medial surface of the body of the tibia is also subcutaneous, distal to the level of the insertion of the sartorius, and the medial border of the bone can be followed by the finger throughout its entire length. The fibula is more deeply placed, and the proximal half of its body cannot be felt from the surface owing to the manner in which it is surrounded by muscles. The head of the bone, however, is very evident where it articulates with the lateral and posterior part of the lateral condyle of the tibia. For a short distance proximal to the lateral malleolus the body of the fibula is subcutaneous, over a triangular area which is interposed between the peronæus tertius muscle anteriorly and the peronæus longus and peronæus brevis muscles posteriorly.

The two malleoli form marked projections in the region of the ankle. The medial malleolus is the broader and more prominent of the two; it does not pass so far distally, but its anterior border is situated more anteriorly than the lateral malleolus. This is due to its greater breadth; because, when examined from behind, the posterior borders of the two projections are seen to occupy very nearly the same plane.

On the posterior aspect of the leg the prominence known

as the "calf of the leg" is visible. This is largely due to the fleshy bellies of the gastrocnemius muscle. Distal to the calf, and immediately proximal to the heel, the powerful tendo calcaneus can be felt. Anterior to this tendon a slight hollow is apparent on each side of the limb.

The skin will be reflected from the dorsum of the foot during the dissection of the leg; therefore the present opportunity should be seized for studying the surface anatomy of the foot. The individual tarsal bones cannot be recognised through the integument which covers the dorsum of the foot; but if the foot is powerfully extended, the head of the talus will be brought into view, in the shape of a slight prominence. The margins of the foot require careful study, because it is by the recognition of certain bony projections in them that the surgeon is enabled to determine the point at which to enter the knife when he is called upon to perform partial amputation of the foot. Examine the *medial margin* first. Begin posteriorly, at the projection formed by the medial process of the calcaneus, and proceed anteriorly. About one inch below the medial malleolus the medial edge of the sustentaculum tali may be recognised, and about one inch, or a little more, anterior to this, is the tubercle of the navicular. Then comes the first cuneiform bone, which is succeeded by the first metatarsal bone. None of these bony points can be said to form distinct prominences on the surface. In order to distinguish them the medial margin of the foot must be carefully palpated. On the *lateral margin* of the foot the tuberosity on the base of the fifth metatarsal bone stands out as a distinct landmark. Posterior to it is the cuboid, and still more posterior the lateral surface of the calcaneus, which is almost completely subcutaneous. When present in a well-developed form, the trochlear process (O.T. peroneal tubercle) on this surface may be distinguished, about one inch distal and a little anterior to the lateral malleolus. If the foot is strongly inverted the anterior end of the calcaneus will be seen to project on the surface.

**Subdivision of the Leg into Regions.**—In the dissection of the leg four distinct regions may be recognised, viz.:—

1. An *anterior crural region*, in which are placed those structures which lie anterior to the interosseous membrane, and between the two bones of the leg.
2. A *medial crural region*, corresponding to the subcutaneous or medial surface of the body of the tibia.

3. A *lateral crural region*, which includes the parts in relation to the lateral surface of the fibula.
4. A *posterior crural region*, in which are placed the parts, on the back of the leg, which lie posterior to the interosseous membrane and the two bones of the leg.

## Anterior Crural Region and Dorsum of Foot.

The anterior crural region should be dissected first, and it is usual to conjoin with this the dissection of the dorsum of the foot. The following parts are exposed :—

1. Superficial veins.
2. Cutaneous nerves.
3. Deep fascia, with its intermuscular septa, the transverse ligament of the leg, the lig. laciniatum, and the cruciate ligament of the leg.
4. Tibialis anterior.
5. Extensor digitorum longus.
6. Peronæus tertius.
7. Extensor hallucis longus.
8. Anterior tibial vessels.
9. Perforating branch of the peroneal artery.
10. Deep peroneal nerve.
11. Recurrent articular branch from the common peroneal nerve.
12. Extensor digitorum brevis.
13. Dorsalis pedis artery.

**Reflection of Skin.**—To place the limb in a convenient position for the dissection of this region, a block should be introduced beneath the knee, and the foot should be extended and fastened firmly to the table by means of hooks. The skin should be reflected from the *tibial* and *peroneal* (*medial* and *lateral*) *crural* regions at the same time. *Incisions* :—(1) a vertical cut along the median line of the leg and dorsum of the foot to the base of the middle toe; (2) a transverse incision across the ankle-joint; (3) a transverse incision across the dorsum of the foot at the roots of the toes.

The four flaps of skin, thus mapped out, must now be raised from the subjacent fatty tissue, and the superficial veins and nerves dissected out.

**Venæ Superficiales (Superficial Veins).**—The *dorsal venous arch* of the foot, which receives the common digital veins, should be dissected in the first place. From the medial extremity of this arch the *great saphenous vein* will be seen to take origin, whilst from its lateral end the *small saphenous vein* proceeds. Trace these vessels proximally. The former will be found to pass *anterior* to the medial malleolus, whilst the latter ascends *posterior to* the lateral malleolus. The great saphenous vein is associated with the saphenous nerve, and the small saphenous vein with the nervus suralis.

**Nervi Cutanei.**—The following are the cutaneous nerves which must be secured in this dissection :—

1. N. cutaneus suræ lateralis.
2. N. suralis.

3. N. saphenus.
4. N. peronæus superficialis.
5. N. peronæus profundus.

The *lateral cutaneous nerve* of the calf is a branch of the *common peroneal nerve* which frequently arises in common with the peroneal anastomotic branch. It turns anteriorly, and is distributed upon the lateral and anterior aspect of the proximal part of the leg. The *nervus suralis* (O.T. short saphenous) can be readily found. It reaches the lateral margin of the foot by passing posterior to the lateral malleolus, in company with the small saphenous vein, and becomes the lateral dorsal cutaneous nerve. Trace it anteriorly, and it will be found to end upon the lateral side of the little toe. On the dorsum of the foot a connecting twig passes between this nerve and the lateral division of the superficial peroneal nerve (nervus cutaneus dorsalis intermedius). The *saphenous nerve* (O.T. *internal saphenous nerve*) should be looked for anterior to the medial malleolus. It descends in company with the great saphenous vein. It may, with care, be followed half-way along the medial margin of the foot, but there it ends. Proximal to the ankle-joint several minute twigs from this nerve may be found passing anteriorly to reach the front of the leg.

The *superficial peroneal nerve* (O.T. *musculo-cutaneous nerve*) appears in the distal third of the leg. It pierces the deep fascia a short way lateral to the middle line of the limb. Almost immediately it splits into a medial and a lateral part. The *medial division* (the nervus cutaneus dorsalis medialis) extends anteriorly, on the dorsum of the foot, and sends one branch to the medial side of the great toe, and a second to supply the adjacent sides of the second and third toes. It likewise gives a number of twigs to the skin upon the medial margin of the foot, and effects junctions with the deep peroneal nerve and the saphenous nerve. The *lateral division* (the intermediate dorsal cutaneous nerve) is smaller than the medial part. It gives several twigs to the skin on the dorsum of the foot, communicates with the lateral dorsal cutaneous nerve, and then divides into two branches, which supply the contiguous margins of the third, fourth, and fifth toes. Therefore, the superficial peroneal nerve furnishes twigs to the two margins of each of the toes with the exception of the adjacent sides of the great toe and the second toe, which are supplied by the deep peroneal nerve, and

the lateral side of the little toe, which is supplied by the lateral dorsal continuation of the nervus suralis (Fig. 98, p. 269).

Very frequently the distribution of the superficial peroneal nerve is more restricted, and in these cases the lateral dorsal cutaneous nerve will, in all probability, be found to supply the lateral two and a half toes.

The *medial terminal branch* of the *deep peroneal nerve* (O.T. *anterior tibial nerve*) pierces the deep fascia on the dorsum of the foot in the interval between the first and second metatarsal bones. It receives a communicating branch from the medial dorsal cutaneous nerve, and ends by dividing into two twigs, which go to supply the adjacent margins of the great toe and the second toe.

**Deep Fascia.**—The fatty superficial fascia should be removed in order that the deep fascia may be displayed. The deep fascia does not form a complete investment for the leg. It is absent over the medial area of the tibia, and is attached to the anterior and medial borders of that bone. It is also absent over the triangular subcutaneous surface on the distal part of the fibula, being attached to the ridges which limit that area anteriorly and posteriorly. It is not equally dense throughout. In the proximal part of the anterior crural region it is thick and strong, but it thins as it is traced distally, and on the dorsum of the foot it becomes exceedingly fine. Its great strength in the proximal part of the anterior crural region is due to the fact that there it gives origin to subjacent muscles. In the neighbourhood of the ankle-joint it forms the thickened bands which retain the tendons in position during the action of the muscles. Four of these may be examined at this stage, viz., the lig. transversum cruris, the lig. cruciatum cruris, and the superior and inferior retinacula of the peroneal muscles.[1]

The *ligamentum transversum cruris* (O.T. *upper part of anterior annular ligament*) is a strong, broad band which stretches across the front of the leg, immediately proximal to the ankle-joint. By one extremity it is attached to the fibula, and by the other to the tibia. The *lig. cruciatum cruris* (O.T. *lower part of anterior annular ligament*) is placed over the ankle-joint. Laterally it presents the appearance of a narrow, well-

[1] In the old terminology the first two bands were respectively the upper and lower parts of the anterior annular ligament of the ankle, and the last two were included under the term external annular ligament.

defined band, which is fixed firmly to the anterior part of the calcaneus. As it is traced medially it will be seen to divide into two diverging limbs. Of these the proximal is attached to the medial malleolus, whilst the distal passes to the medial margin of the foot, and becomes connected with the plantar aponeurosis. The transverse and the cruciate ligaments of the leg are merely portions of the deep fascia which are distinguishable on account of their thickness.

The *superior peroneal retinaculum* is a thickened portion of the deep fascia which passes from the posterior and distal part of the lateral malleolus to the proximal and posterior part of the lateral surface of the calcaneus.

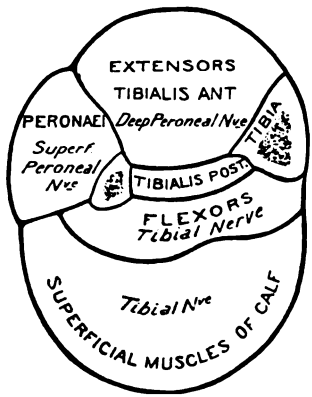


FIG. 95.—Diagrammatic representation of the Fascia of the Leg. The fascia of the tibialis posterior is more a muscular aponeurosis than a true fascial septum; but it is convenient for descriptive purposes to regard it as one of the partitions.

The *inferior peroneal retinaculum* springs from the anterior part of the proximal surface of the calcaneus, where it is continuous with the lateral extremity of the cruciate ligament; its opposite extremity is attached, on the lateral border of the foot, to the trochlear process of the calcaneus and to the lateral surface of the calcaneus distal to the tubercle. The peroneal retinacula bind the tendons of the peronæus longus and brevis to the lateral surface of the calcaneus.

**Intermuscular Septa.**—As the deep fascia of the leg passes posteriorly, over the fibular region, two strong intermuscular septa are given off from its deep surface. These are distinguished as the anterior and posterior fibular septa. The *anterior fibular septum* intervenes between the peroneal muscles and the extensor muscles, and is attached to the anterior crest of the fibula. The *posterior fibular septum* is interposed between the peroneal muscles and the muscles on the back of the leg, and is attached to the lateral crest of the fibula.

The leg is thus subdivided into three osteo-fascial compartments, corresponding to the anterior, lateral, and posterior crural regions. The *anterior compartment* is bounded by the investing deep fascia, the anterior fibular septum, the anterior part of the medial surface of the fibula (that part which lies anterior to the interosseous crest), the interosseous membrane, and the lateral surface of the tibia. The *lateral compartment* is bounded by the lateral surface of the fibula, the investing fascia, and the two fibular septa. The *posterior compartment* is much the largest, and its walls are formed by the posterior surface of the tibia, the posterior part of the medial surface and the whole of the posterior surface of the fibula, the interosseous membrane, the posterior fibular septum, and the investing deep fascia. This compartment is still further subdivided by two partitions; but these will be studied later.

*Dissection.*—The anterior compartment of the leg should now be opened by removing the deep fascia. The transverse and cruciate ligaments, however, must be retained, and their borders should be separated artificially, by the knife, from the deep fascia with which they are continuous. In the proximal part of the leg it will be found impossible to raise the fascia from the subjacent muscles without lacerating their surfaces. It should, therefore, be left in position. At a more distal level it can readily be separated. Divide it in a longitudinal direction midway between the tibia and fibula. On throwing the medial piece medially its firm attachment to the anterior border of the tibia will become evident; and as the lateral piece is turned laterally the anterior fibular septum will come into view.

**Contents of the Anterior Crural Compartment.**—Four muscles are brought into view by the above dissection, viz., the tibialis anterior, the extensor digitorum longus, the extensor hallucis longus, and the peronæus tertius. The *tibialis anterior* lies in relation to the tibia; the *extensor digitorum longus* is placed along the fibula; and on separating those muscles from each other, the *extensor hallucis longus* will be seen in the interval between them. The *peronæus tertius* lies upon the distal portion of the fibula, and in most cases is incorporated with the extensor digitorum longus. The *anterior tibial vessels* and *the deep peroneal nerve* (O.T. *anterior tibial*) proceed distally in this compartment. At first they are deeply placed, but as they approach the ankle they come nearer to the surface.

*Dissection.*—To expose the anterior tibial vessels and the deep peroneal nerve in their entire course, on the front of the leg, the tibialis anterior and the extensor digitorum longus must be separated from each other, along the line of a strong intermuscular septum which dips posteriorly

between them, and affords a surface of origin to each. The knife should

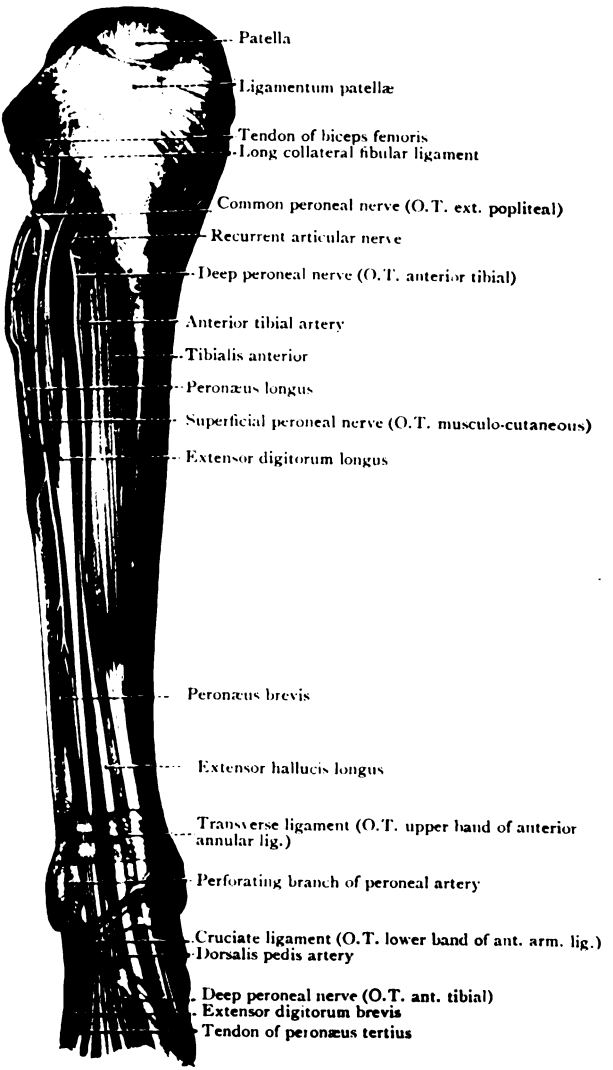
Patella
Ligamentum patellæ
Tendon of biceps femoris
Long collateral fibular ligament
Common peroneal nerve (O.T. ext. popliteal)
Recurrent articular nerve
Deep peroneal nerve (O.T. anterior tibial)
Anterior tibial artery
Tibialis anterior
Peronæus longus
Superficial peroneal nerve (O.T. musculo-cutaneous)
Extensor digitorum longus
Peronæus brevis
Extensor hallucis longus
Transverse ligament (O.T. upper band of anterior annular lig.)
Perforating branch of peroneal artery
Cruciate ligament (O.T. lower band of ant. arm. lig.)
Dorsalis pedis artery
Deep peroneal nerve (O.T. ant. tibial)
Extensor digitorum brevis
Tendon of peronæus tertius

FIG. 96.—Dissection of the Anterior and Lateral Crural Regions.

be carried proximally along the plane of this septum. If the peronæus tertius muscle is drawn aside, the *perforating branch of the peroneal artery* will be seen piercing the interosseous membrane. It is a small artery which descends upon the distal end of the fibula. As the structures in the anterior crural compartment are being exposed and cleaned, the dissector should, at the same time, carry on the dissection of the dorsum of the foot. There the tendons of the muscles on the front of the leg must be followed to their insertions, and the *extensor digitorum brevis muscle* defined. The *dorsalis pedis artery* and the *deep peroneal nerve* should also be followed, and their branches traced to their various destinations.

**M. Tibialis Anterior** (O.T. **Tibialis Anticus**).—The tibialis anterior is a powerful muscle, which takes origin from the distal part of the lateral condyle of the tibia, and from the proximal half of the lateral surface of its body (Fig. 96, p. 264). It derives many fibres also from the deep fascia which covers it, from the fascial septum between it and the extensor digitorum longus, and from the portion of the interosseous membrane on which it rests. In other words, it springs from the structures which form the walls of the medial portion of the osteo-fascial compartment in which it lies.[1] A strong tendon issues from its fleshy belly in the distal third of the leg, and this reaches the dorsum of the foot by passing through both the transverse and cruciate ligaments. On the foot it inclines medially, and, turning round the medial margin, gains insertion, by two slips, into the medial and distal part of the first cuneiform bone, and into the adjoining part of the base of the first metatarsal bone. The tibialis anterior is supplied by the *deep peroneal nerve*.

**M. Extensor Digitorum Longus**.—This muscle arises, for the most part, from the structures which form the lateral portion of the wall of the anterior crural region. Thus, it springs from the distal part of the lateral condyle of the tibia, from the head of the fibula, and from the proximal three-fourths of the anterior part of the medial surface of the body of the fibula (Fig. 96, p. 264). It takes origin also from a small portion of the proximal part of the interosseous membrane, the deep investing fascia of the leg, the anterior fibular septum, and the inter-muscular septum which dips

[1] To understand the attachments of the muscles of the leg, it is necessary to bear in mind that the interosseous membrane, which stretches across the interval between the two bones of the leg, and thus extends the surface of origin for these muscles, is attached to the *interosseous* crest of the tibia (*i.e.* between its lateral and posterior surfaces) and to the interosseous crest of the fibula. The interosseous crest of the fibula traverses the medial surface, and divides it into an anterior and a posterior part. The anterior part gives origin to the extensor muscles and the posterior part to the flexor muscles.

posteriorly between it and the tibialis anterior. The tendon of the extensor digitorum longus descends anterior to the ankle-joint, and, passing through the transverse and cruciate ligaments (p. 261), divides into four pieces, which diverge from each other on the dorsum of the foot to reach the lateral four toes. On the dorsum of the first phalanx each of the medial three slips is joined, on the lateral side, by a tendon from the extensor digitorum brevis.

The manner in which the four tendons of the extensor digitorum longus are inserted, on the dorsal surfaces of the

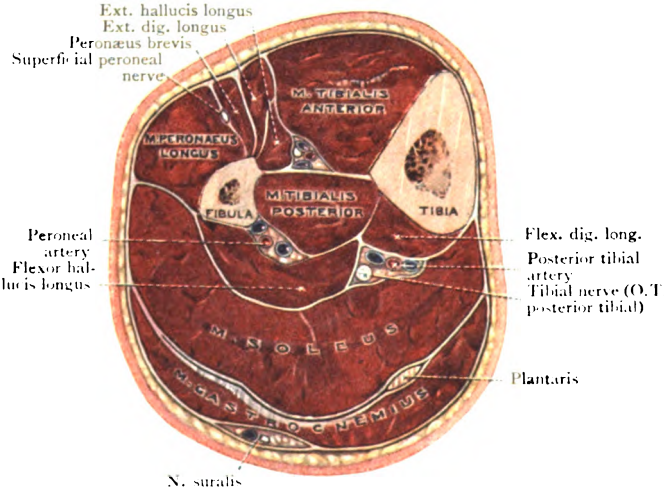


FIG. 97.—Transverse section through the Calf of the Leg.

lateral four toes, is so similar to that in which the corresponding tendons of the fingers are attached, that a very brief description will suffice. An expansion is formed on the dorsal surface of the first phalanx; this is joined by the slender tendons of the lumbrical and interosseous muscles, and divides into a central and two collateral slips. The central slip is inserted into the base of the second phalanx, whilst the stronger collateral slips are prolonged onwards, and, uniting with each other, gain insertion into the base of the ungual phalanx. The extensor digitorum longus is supplied by the *deep peroneal nerve.*

**M. Extensor Hallucis Longus.**—The extensor hallucis

longus is placed in the interval between the tibialis anterior and the extensor digitorum longus. In its proximal part it is hidden from view by those muscles, but near the ankle it comes to the surface. It takes origin posterior to the extensor digitorum longus, from an extremely narrow strip of the anterior part of the medial surface of the body of the fibula, in its middle two-fourths, and also from the adjoining part of the interosseous membrane. Its tendon crosses the distal part of the anterior tibial artery, and reaches the dorsum of the foot by passing distally in front of the ankle-joint and deep to the transverse and cruciate ligaments (p. 261). It is inserted into the dorsal aspect of the base of the ungual phalanx of the great toe.[1] It is *not joined* by the most medial tendon of the extensor digitorum brevis. The extensor hallucis longus is supplied by the *deep peroneal nerve.*

**M. Peronæus Tertius.**—This is a small muscle which is continuous at its origin with the extensor digitorum longus. It arises from the distal fourth of the anterior part of the medial surface of the fibula, and from a corresponding extent of the interosseous membrane. It receives fibres also from the distal part of the anterior fibular septum, which intervenes between it and the peronæus brevis. Its slender tendon is inserted into the dorsal surface of the expanded base of the fifth metatarsal bone. It is supplied by the *deep peroneal nerve.*

**Arteria Tibialis Anterior.**—The anterior tibial artery is the smaller of the two terminal branches of the popliteal. It takes origin in the posterior region of the leg, at the distal border of the popliteus muscle, and it enters the anterior crural region by passing forwards through the opening in the proximal part of the interosseous membrane. In that part of its course it lies close to the medial side of the neck of the fibula, and appears, in the present dissection, immediately distal to the lateral condyle of the tibia. In the anterior part of the leg it takes a straight course distally to the ankle-joint. Then it reaches the dorsum of the foot, and receives the name of *dorsalis pedis.*

In the proximal two-thirds of the leg the anterior tibial artery is very deeply placed. It lies upon the interosseous membrane, in the interval between the tibialis anterior on the medial side, and the extensor digitorum longus and the extensor hallucis longus on the lateral side. In the distal

[1] In most cases it gives a slip to the base of the proximal phalanx also.

third of the leg, where the muscles give place to their tendons, the artery comes nearer to the surface. In that part of its course it rests upon the tibia and is overlapped on the lateral side by the extensor hallucis longus. Immediately proximal to the ankle-joint the tendon of that muscle crosses the artery and comes to lie on its medial side.

Two *venæ comites* closely accompany the anterior tibial artery, and send short communicating branches both anterior and posterior to it. The *deep peroneal nerve* is also intimately related to it. It joins the artery a short distance distal to the knee, and soon takes up a position anterior to the vessel. Near the ankle-joint the nerve, as a rule, assumes a place on the lateral side of the artery.

On the front of the leg the anterior tibial artery gives off the following *branches*:—

1. Muscular.
2. A. recurrens tibialis anterior.
3. A. malleolaris anterior medialis.
4. A. malleolaris anterior lateralis.

The *muscular branches* are numerous, and come off at irregular points along the whole length of the artery. They supply the muscles on the *anterior crural region*.

**The anterior tibial recurrent artery** is a small vessel which springs from the anterior tibial immediately after it reaches the front of the leg. It turns proximally, on the lateral condyle of the tibia, in the fibres of the tibialis anterior muscle. Its terminal twigs reach the front of the knee-joint, and anastomose with the inferior genicular branches from the popliteal artery.

**Malleolar Arteries.**—These arteries take origin immediately proximal to the ankle-joint. The *lateral anterior malleolar artery* is the larger of the two, and passes laterally under cover of the tendons of the extensor digitorum longus and peronæus tertius, to reach the lateral surface of the lateral malleolus. It anastomoses with the perforating branch of the peroneal artery and with the tarsal arteries. The *medial anterior malleolar artery* runs medially under cover of the tendons of the extensor hallucis longus and tibialis anterior. It inosculates with branches from the posterior tibial artery.

**Arteria Dorsalis Pedis.**—The dorsal artery of the foot is the continuation of the anterior tibial. It begins anterior to the ankle-joint at a point midway between the two malleoli, and it extends forwards, upon the dorsal part of the talus, the

navicular bone, and the second cuneiform bone, to the posterior part of the interosseous space between the metatarsal bones of the great toe and the second toe. There it leaves the dorsum of the foot, by dipping plantarwards between the two heads of the first dorsal interosseous muscle, to reach the plantar region, where it unites with the lateral plantar artery in the formation of the plantar arch. Its relations on the dorsum of the foot are very simple. (1) It lies in the interval between the tendon of the extensor hallucis longus on the medial side and the most medial tendon of the extensor digitorum longus on the lateral side. (2) It is crossed first by the proximal band of the cruciate ligament, then by the distal band, and near its termination it is crossed by the most medial tendon of the extensor digitorum brevis; with these exceptions the vessel is covered merely by the integument and fascia. (3) The medial terminal branch of the deep peroneal nerve lies along its lateral side, and two *venæ comites* accompany it.

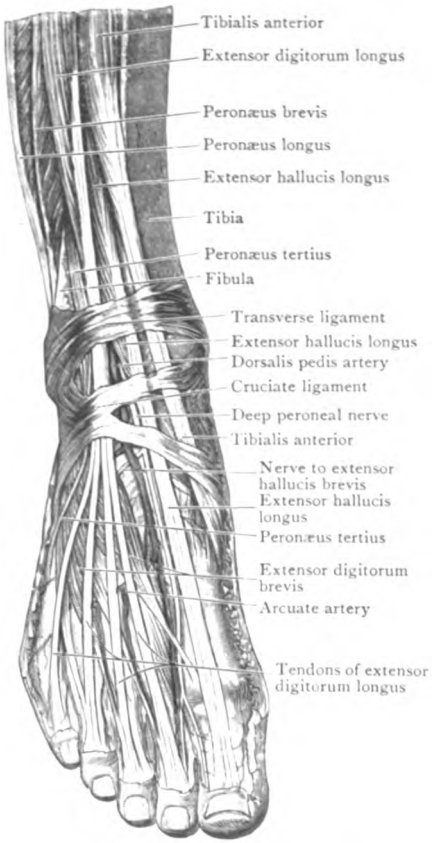


FIG. 98.—Dissection of the Dorsum of the Foot.

As the dorsalis pedis artery traverses the dorsum of the foot it gives off several twigs to the medial margin of the foot, and also three named branches:—

1. The lateral tarsal.
2. The arcuate.
3. The first metatarsal artery.

**Lateral Tarsal and Arcuate Arteries** (O.T. **Tarsal and Metatarsal**).—The *lateral tarsal artery* arises opposite the navicular bone, and the *arcuate artery* arises near the bases of the metatarsal bones. They both run laterally, under cover of

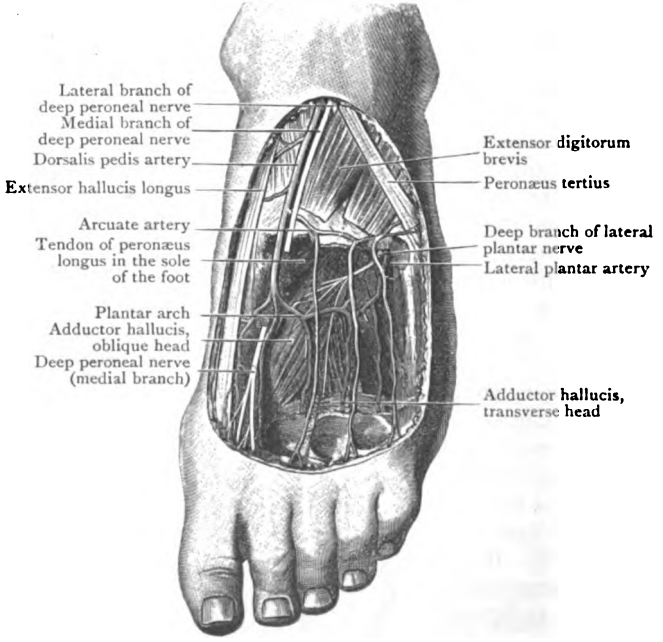
Lateral branch of deep peroneal nerve
Medial branch of deep peroneal nerve
Dorsalis pedis artery
Extensor hallucis longus
Arcuate artery
Tendon of peronæus longus in the sole of the foot
Plantar arch
Adductor hallucis, oblique head
Deep peroneal nerve (medial branch)
Extensor digitorum brevis
Peronæus tertius
Deep branch of lateral plantar nerve
Lateral plantar artery
Adductor hallucis, transverse head

FIG. 99.—Dissection of the Dorsum of the Foot. The 2nd, 3rd, and 4th Metatarsal Bones have been removed to show the Plantar Arterial Arch in the sole of the foot.

the extensor digitorum brevis, to reach the lateral margin of the foot. There they anastomose with branches of the lateral plantar artery. The lateral tarsal artery anastomoses also with the lateral malleolar and peroneal arteries.

From the arch which is formed by the arcuate artery *three dorsal metatarsal arteries* proceed, one to each of the lateral three interosseous spaces, and at the clefts between the toes they divide and supply *dorsal digital twigs* to the

adjacent sides of the second, third, fourth, and fifth toes. From the most lateral interosseous artery a twig is given to the lateral side of the little toe.

**First Dorsal Metatarsal Artery** (O.T. **First Dorsal Interosseous**).—This small vessel takes origin from the dorsalis pedis, at the point where it turns plantarwards to reach the plantar region of the foot. It continues forwards, upon the first dorsal interosseous muscle, and divides into *dorsal digital branches* for the medial side of the great toe and the adjacent sides of the great toe and second toe.[1]

**Perforating Branch of Peroneal Artery** (O.T. **Anterior Peroneal Artery**).—This branch of the peroneal artery reaches the anterior region of the leg by piercing the interosseous membrane, about one and a half or two inches proximal to the lateral malleolus, and it descends upon the distal part of the fibula, under cover of the peronæus tertius. It is distributed on the lateral side of the tarsus, where it anastomoses with the lateral malleolar and the lateral tarsal arteries.

**M. Extensor Digitorum Brevis.**—The extensor digitorum brevis may now be examined. It arises from the anterior part of the calcaneus, and also from the cruciate ligament. It splits into four fleshy bellies, which extend forwards and medially, on the dorsum of the foot, and end in four slender tendons for the medial four toes. The *most medial tendon* crosses the dorsalis pedis artery, near its termination, and is inserted into the dorsal aspect of the base of the first phalanx of the great toe; the remaining three tendons join the long extensor tendons which go to the second, third, and fourth toes. The extensor digitorum brevis is supplied by the *lateral branch* of the *deep peroneal nerve.*

**Nervus Peronæus Profundus** (O.T. **Anterior Tibial**).—The deep peroneal nerve is one of the terminal branches of the common peroneal. It arises on the lateral side of the neck of the fibula, and, piercing the proximal part of the extensor digitorum longus obliquely, joins the anterior tibial vessels a short distance distal to the lateral condyle of the tibia, and accompanies them during the remainder of its course. In the first instance it is placed lateral to them, and then it is anterior; but near the ankle-joint it again lies on their lateral

[1] For the branches from the dorsalis pedis in the plantar region see p. 304.

side. Passing posterior to the transverse and cruciate ligaments, it ends by dividing into a medial and a lateral branch.

In its course through the leg the deep peroneal nerve gives *muscular branches* to the extensor digitorum longus, the tibialis anterior, the extensor hallucis longus, and the peroneus tertius; and a fine *articular twig* to the ankle-joint.

The *medial terminal branch* of the deep peroneal nerve is

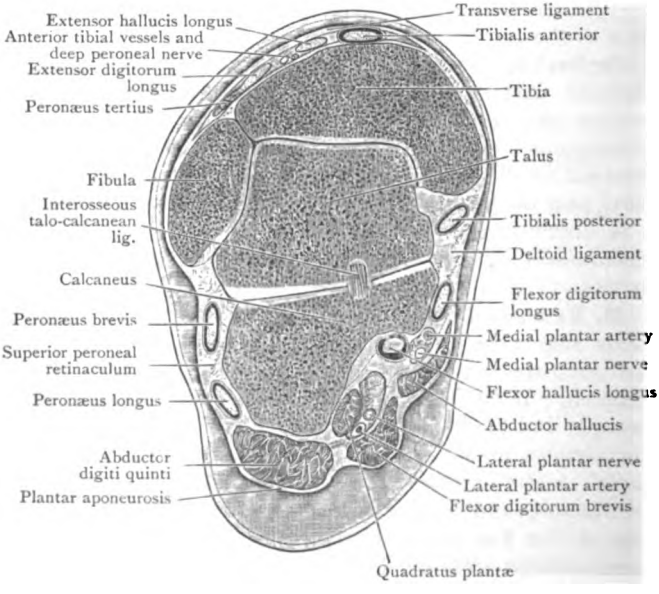


FIG. 100.—Frontal section through the Left Ankle-joint, Talus, and Calcaneus (Paterson).

continued forwards upon the dorsum of the foot along the lateral side of the dorsalis pedis artery. Reaching the first interosseous space, it pierces the deep fascia, and divides to supply the contiguous margins of the great toe and the second toe (p. 269). Before it reaches the surface, it furnishes *articular twigs* to the tarso-metatarsal and metatarso-phalangeal joints of the great toe, and frequently, also, a fine *muscular twig* to the dorsal surface of the first dorsal interosseous muscle.

The *lateral terminal branch* of the deep peroneal nerve turns abruptly laterally, under cover of the extensor digitorum

brevis, and ends on the dorsum of the foot in a gangliform enlargement. Branches proceed from the enlargement to supply the extensor digitorum brevis, and the numerous articulations in the neighbourhood. One fine filament can, in some cases, be traced to the second dorsal interosseous muscle. The terminal swelling resembles closely the corresponding enlargement in which the dorsal interosseous nerve of the upper extremity ends.

**The Transverse and Cruciate Ligaments** (O.T. **Anterior Annular Ligament**).—The dissector should again examine these ligaments, and the arrangement of the structures which pass under them. The *transverse ligament* is attached to the fibula by its lateral end, and to the tibia by its medial extremity. By dividing its fibular attachment, and throwing it medially, it will be seen to give a separate and distinct sheath to the tibialis anterior.

The *cruciate ligament* is the more important of the two. Its attachments have already been noted (p. 261). Examine the manner in which it holds the tendons in position. It consists of two layers, and these, by separating at certain points and becoming reunited at others, form three distinct compartments. Through the *most medial* passes the tendon of the tibialis anterior; through the *intermediate* one passes the tendon of the extensor hallucis longus; and through the *lateral* are transmitted the tendons of the extensor digitorum longus and peronæus tertius. As the tendons pass through the compartments of the ligaments, and for some distance proximal to the transverse ligament and distal to the cruciate ligament, they are surrounded by mucous sheaths. Lastly, note the position of the anterior tibial vessels and the deep peroneal nerve as they pass under cover of the ligaments. They lie between the extensor hallucis longus and the extensor digitorum longus (Fig. 96).

## Peroneal or Lateral Crural Region.

The peroneal or lateral compartment of the leg should now be opened by dividing, in a longitudinal direction, the fascia which covers it. Enclosed within it are:—

1. The peronæus longus.
2. The peronæus brevis.
3. The termination of the common peroneal nerve.
4. The superficial peroneal nerve.

**M. Peronæus Longus.**—The peronæus longus muscle arises from the head and from the lateral surface of the shaft of the fibula in its proximal two-thirds. A surface of origin is also afforded to it by the fascia which covers it, and by the two fibular intermuscular septa. It ends, a short distance proximal to the ankle, in a long tendon, which is continued distally, posterior to the lateral malleolus. Gaining the lateral margin of the foot, it proceeds forwards, on the lateral surface of the calcaneus, to the groove on the plantar surface of the cuboid, which conducts it obliquely into the sole. Its insertion will be examined at a later period. It is supplied by the *superficial peroneal nerve* (O.T. *musculo-cutaneous*).

**M. Peronæus Brevis.**—This muscle arises from the distal two-thirds of the lateral surface of the body of the fibula, anterior and distal to the peronæus longus, and from the fibular intermuscular septum on each side of it. Its tendon descends, posterior to the lateral malleolus, and then turns forwards, on the lateral surface of the calcaneus, to gain an insertion into the projecting base of the metatarsal bone of the little toe.[1] On the posterior surface of the lateral malleolus the tendon of the peronæus brevis lies under cover of the tendon of the peronæus longus, and is therefore in contact with the bone. On the lateral surface of the calcaneus the tendon of the peronæus longus is placed nearer the sole than that of the peronæus brevis.

As the tendons of the two peronæi muscles proceed distally, in the hollow between the lateral malleolus and the posterior prominence of the calcaneus, they are held in place by the *superior peroneal retinaculum*, and their movements are facilitated by the presence of a common mucous sheath. On the lateral surface of the calcaneus the tendons are retained in position by the *inferior peroneal retinaculum*, but each tendon lies in a separate compartment surrounded by its own special prolongation of the mucous sheath. The trochlear process of the calcaneus intervenes between these two sheaths. The peronæus brevis is supplied by the *superficial peroneal nerve*.

**N. Peronæus Communis** (O.T. **External Popliteal Nerve**).—The common peroneal nerve has previously been traced as far as the neck of the fibula. At that point it disappears

[1] A small tendinous slip will, as a general rule, be observed to proceed forwards from the tendon of the peronæus brevis to join the tendon of the long extensor on the dorsum of the little toe. This is the *peronæus quinti digiti*.

from view by passing forwards between the peronæus longus muscle and the bone. The muscle must therefore be carefully turned aside from its origin in order that the nerve may be followed. The nerve will be found to give off a small *recurrent articular nerve* to the knee-joint, and then to divide into the *deep* and *superficial peroneal nerves.*

The *recurrent branch* accompanies the anterior tibial recurrent artery. It turns proximally in the fibres of the tibialis anterior. To the proximal part of this muscle it gives several twigs, whilst its terminal filaments gain the front of the knee-joint.

The *deep peroneal nerve* pierces the proximal part of the extensor digitorum longus to reach the anterior region of the leg, where it has already been dissected.

**N. Peronæus Superficialis** (O.T. **Musculo-Cutaneous Nerve**). —The superficial peroneal nerve passes distally in the substance of the peronæus longus; reaches the interval between the two peronæi muscles; gives branches to both; and, lastly, comes to lie between the peronæus brevis and the extensor digitorum longus. In the distal third of the leg it pierces the deep fascia, becomes cutaneous, and divides into the medial and intermediate dorsal cutaneous nerves of the foot (p. 260).

## Medial Crural Region.

This region corresponds to the subcutaneous or medial surface of the tibia. The deep fascia blends with the periosteum of the bone, and the only structures which have to be examined are:—

1. The great saphenous vein.
2. The saphenous nerve.
3. The expanded tendons of insertion of the sartorius, semitendinosus, and gracilis.
4. Tibial collateral ligament of the knee-joint.
5. Inferior medial genicular artery.
6. Inferior medial articular nerve.

The *great saphenous vein* and the *saphenous nerve*, as they pass from the anterior to the posterior crural region, cross obliquely over the distal third of the medial surface of the tibia.

The insertions of the *sartorius*, *gracilis*, and *semitendinosus* into the proximal part of the medial surface of the tibia sho[w]

again be examined. Observe how the sartorius overlaps the tendons of the other two, and how the tendon of the gracilis overlaps the proximal part of the tendon of the semitendinosus. Mucous bursæ separate these tendons from each other.

The *tibial collateral ligament* of the knee-joint will be seen extending distally, for a short distance, upon the medial aspect of the body of the tibia. Passing forwards under cover of this ligament, so as to gain the anterior aspect of the knee, are the *inferior medial genicular vessels* and the *inferior medial articular nerve.*

## Posterior Crural Region.

The following is a list of the structures which are met with in this dissection:—

1. Superficial veins, { Great saphenous vein. / Small saphenous vein.
2. Cutaneous nerves.
3. Deep fascia.
4. Superficial muscles of the calf, { Gastrocnemius. / Plantaris. / Soleus.
5. Tendo calcaneus (Achillis) and its bursa.
6. Posterior tibial vessels.
7. Tibial nerve.
8. Deep muscles, { Popliteus. / Flexor hallucis longus. / Tibialis posterior. / Flexor digitorum longus.
9. Ligamentum laciniatum.

**Reflection of Skin.**—The limb must now be placed on its anterior aspect, and the muscles of the calf rendered tense by flexing the foot at the ankle-joint. This position should be maintained by the aid of hooks, fastened to the toes and to the under surface of the table. *Incisions.*—(1) A longitudinal incision along the middle line of the leg, on its posterior aspect, to the extremity of the heel. (2) A transverse incision at the distal end of this, extending along the medial and lateral margins of the foot for about two inches on each side.

The two flaps of skin thus marked out must be raised and turned laterally and medially.

**Superficial Veins.** — The *great* and *small saphenous veins* must be traced in the substance of the fatty superficial fascia. Both of these vessels have been seen in previous steps of the dissection. The *great saphenous vein* has been observed to arise from the medial extremity of the venous arch on the dorsum of the foot, and it has been followed proximally, for a short distance, anterior to the medial malleolus, and then

upon the medial aspect of the distal part of the tibia. It has also been dissected upon the medial aspect of the thigh and knee. It can now be exposed in its course along the medial side of the calf of the leg, where it lies a short distance posterior to the medial border of the tibia. The *small saphenous vein* arises from the lateral end of the dorsal venous arch and passes proximally, posterior to the lateral malleolus. It may now be followed, as it ascends along the lateral side of the tendo calcaneus, to the posterior aspect of the leg, where it lies over the interval between the two heads of the gastrocnemius muscle. When it gains the distal part of the popliteal fossa it pierces the deep fascia and joins the popliteal vein.

Associated with each of these veins are certain cutaneous nerves, which must be displayed at the same time. The *posterior cutaneous nerve of the thigh* is closely related to the proximal part of the small saphenous vein, and the *nervus suralis* accompanies the vein in the distal half of the leg. In company with the *great saphenous vein* is the *saphenous nerve.*

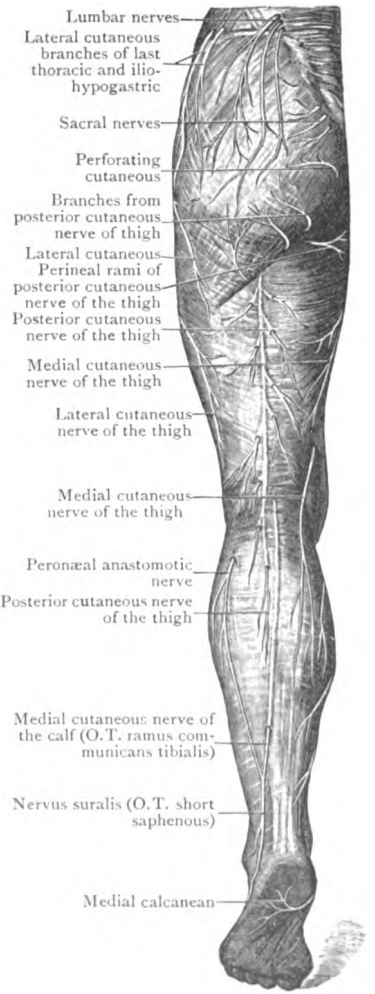
Lumbar nerves
Lateral cutaneous branches of last thoracic and ilio-hypogastric
Sacral nerves
Perforating cutaneous
Branches from posterior cutaneous nerve of thigh
Lateral cutaneous
Perineal rami of posterior cutaneous nerve of the thigh
Posterior cutaneous nerve of the thigh
Medial cutaneous nerve of the thigh
Lateral cutaneous nerve of the thigh
Medial cutaneous nerve of the thigh
Peronæal anastomotic nerve
Posterior cutaneous nerve of the thigh
Medial cutaneous nerve of the calf (O.T. ramus communicans tibialis)
Nervus suralis (O.T. short saphenous)
Medial calcanean

FIG. 101.—Cutaneous Nerves on the posterior aspect of the Inferior Extremity.

**Cutaneous Nerves.**—These are very numerous. On the

*medial side* of the leg are—(1) the *saphenous nerve*; (2) the *posterior branch* of the *medial cutaneous nerve of the thigh*; and (3) the *medial calcanean nerves*.

The guide to the *saphenous nerve* is the *great saphenous vein*. It may now be exposed in its entire course along the medial side of the leg. The *posterior branch* of the *medial cutaneous nerve of the thigh* proceeds distally a short distance posterior to the preceding nerve. It usually ends about the middle of the leg. The *medial calcanean nerves* are branches of the posterior tibial nerve. Dissect for them in the interval between the prominence of the heel and medial malleolus. They pierce the ligamentum laciniatum (O.T. internal annular), nearer the former than the latter, and their branches of distribution to the skin of the heel and sole will be seen in a subsequent dissection.

In the *middle line* of the leg two nerves will be found, viz.—(1) the terminal part of the posterior cutaneous nerve of the thigh, and (2) the medial cutaneous nerve of the calf. They have both been previously seen in the dissection of the popliteal fossa. The medial cutaneous nerve of the calf, a branch of the tibial nerve, descends in the interval between the two heads of the gastrocnemius and pierces the deep fascia midway between the knee and ankle. After it pierces the deep fascia it joins the anastomotic peroneal nerve, to form *nervus suralis*.

On the *lateral side* of the posterior aspect of the leg is the *anastomotic peroneal nerve*, a branch of the common peroneal nerve. It descends upon the lateral head of the gastrocnemius, and, perforating the deep fascia, unites with the medial cutaneous nerve of the calf a short distance distal to the middle of the leg, to form the *nervus suralis*. The latter has already been traced, posterior to the lateral malleolus, to the lateral margin of the foot and little toe.

**Deep Fascia.**—A continuous view of the deep fascia, on the posterior aspect of the leg, can now be obtained by removing the remains of the superficial fat. Observe how thin and transparent it is in the proximal part of the leg, and how it thickens as it is followed distally towards the heel. At no point, however, is it very dense. As it passes over the interval between the heel and the medial malleolus it forms the *ligamentum laciniatum*. It is continuous proximally with the popliteal fascia, and a short distance distal to the knee, on the medial side, it receives a reinforcement of fibres from

the tendons of the sartorius, the gracilis, and the semitendinosus.

**Osteo-fascial Compartments of the posterior region of the Leg.**—Divide the deep fascia along the middle line and turn it laterally and medially. Leave the ligamentum laciniatum intact. When the medial part of the fascia is raised it will be seen to be attached to the medial border of the tibia. In fact, it blends with the periosteum covering the medial subcutaneous surface of that bone. When the lateral portion of fascia is turned aside it will be observed to be directly continuous with the fascia on the front of the leg: further, the strong intermuscular septum (posterior fibular septum) which passes in to join the lateral crest of the fibula, between the peroneal muscles and the muscles on the posterior aspect of the leg, will be demonstrated. In this manner, then, the large, posterior osteo-fascial compartment is formed, and, as the dissection goes on, two partitions will be noticed to stretch across it so as to subdivide it into three portions. The most superficial of these holds the superficial muscles of the calf; the intermediate portion contains the flexor muscles, with the posterior tibial vessels and the tibial nerve: whilst the deepest part encloses the tibialis posterior muscle (Fig. 97, p. 266).

One of these partitions may be exposed at the present moment by removing the fat which is usually accumulated under cover of the tendo calcaneus (Achillis). Subjacent to this tendon is the layer of fascia in question. It stretches between the tibia and fibula, and separates the superficial from the deep group of muscles. In this locality it will be seen to be very dense, and to be strengthened by numerous transverse fibres. It becomes continuous, on the medial side of the ankle, with the ligamentum laciniatum (O.T. internal annular ligament)—indeed, the dissector will not fail to observe that it takes a more prominent part in the formation of this ligament than the investing fascia of the limb. In the proximal part of the leg it becomes very thin.

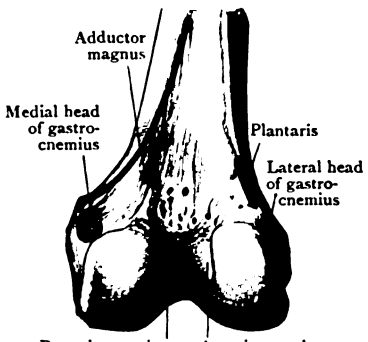


FIG. 102.—Posterior aspect of distal portion of Femur, with Attachments of Muscles mapped out.

**Superficial Muscles.**—The superficial muscles of the calf of the leg are three in number, viz., the gastrocnemius, the plantaris, and the soleus. The gastrocnemius is the most superficial; the soleus is placed under cover of the gastrocnemius; whilst the slender plantaris extends distally and medially between them. The tendons of insertion of the gastrocnemius and soleus unite to form the tendo calcaneus (Achillis).

**M. Gastrocnemius.**—This strong muscle arises by two heads

from the posterior aspect of the distal end of the femur. These heads have been already studied in connection with the popliteal fossa, which they bound in its distal part. The *lateral head* springs from an impression on the lateral surface of the lateral condyle of the femur, and also from a small portion of the popliteal area of the bone, immediately proximal to the lateral condyle. The *medial head* takes origin from the proximal part of the medial condyle, and also from a rough ridge on the adjacent part of the popliteal surface. The two fleshy bellies swell out as they pass distally, and end, near the middle of the leg, in a thin aponeurotic tendon. They do not blend with each other. They are usually separated by a furrow, at the bottom of which the flattened tendon, to which the fasciculi of both heads are attached, may be seen. The medial head is the more bulky of the two, and it extends further distally than the lateral head. The flattened tendon in which they terminate narrows slightly as it descends, and, a short distance distal to the middle of the leg, it blends with the stouter tendon of the soleus to form the tendo calcaneus (Achillis).

The gastrocnemius is supplied by the *tibial nerve.*

*Dissection.*—The medial head of the gastrocnemius may be divided at the level of the knee-joint. The sural arteries from the popliteal trunk, and the branches of supply from the tibial nerve which enter the heads of the gastrocnemius, can thus be preserved. On raising the proximal portion of the medial head, a bursa which intervenes between it and the condyle of the femur will be brought into view. When it is opened with the knife it will, in all probability, be found to communicate with the interior of the knee-joint. The smooth and tendinous opposed surfaces of the gastrocnemius and the soleus, and the narrow tendon of the plantaris, which passes distally and medially between them, are displayed when the medial head of the gastrocnemius is drawn aside.

**M. Plantaris.**—The small fleshy belly of the plantaris is not more than three or four inches long. It lies along the medial side, and partly under cover, of the lateral head of the gastrocnemius, and it arises from the popliteal surface of the femur, immediately proximal to the lateral condyle. It ends in a slender tendon, which is remarkable for its great length. The tendon proceeds distally and medially, between the gastrocnemius and soleus, and then runs along the medial side of the tendo calcaneus (Achillis) to gain insertion into the posterior aspect of the calcaneus. It is frequently closely connected with the tendo calcaneus, and sometimes becomes blended with

it, or with the fascia of the leg before it reaches the tendo calcaneus.

The plantaris is supplied by a branch from the *tibial nerve.*

**M. Soleus.**—This is a flat, thick, and powerful muscle which arises from both bones of the leg, as well as from a strong fibrous arch which is thrown across the posterior tibial vessels. Its *fibular origin* is from the posterior surface of the head and the proximal third of the posterior surface of the body of the bone; by its *tibial origin* it is attached to the linea poplitea of the tibia, distal to the popliteal surface, and, more distally, to the medial border of the bone as far as the middle of the leg (Fig. 104, p. 285). The soleus ends in a strong, stout tendon which joins with the tendon of the gastrocnemius to form the tendo calcaneus (Achillis). Branches from the *tibial nerve* supply the soleus.

**Tendo Calcaneus (Achillis).**—This is the most powerful tendon in the body. It narrows as it descends, but near the heel it again expands slightly. It is inserted into the middle portion of the posterior surface of the calcaneus. The fleshy fibres of the soleus are continued distally on its deep surface to within a short distance of the heel. A mucous bursa intervenes between the tendo calcaneus and the proximal part of the posterior surface of the calcaneus.

*Dissection.*—Divide the soleus muscle along its line of origin from the tibia and separate it from the fibrous arch over the posterior tibial vessels and nerve; then turn it to the lateral side and secure the branches which the muscle receives from the peroneal and posterior tibial arteries.

The deep fascial septum which stretches across from the tibia to the fibula, between the superficial and deep muscles on the back of the leg, may now be removed. In doing this note the manner in which it becomes continuous below with the ligamentum laciniatum. On no account interfere with that ligament. The posterior tibial vessels and the tibial nerve, with their branches, should be dissected with as little disturbance to the deep muscles as possible. The muscle which lies on the fibula is the flexor hallucis longus; the muscle on the tibia is the flexor digitorum longus; whilst the third muscle, between and on a deeper plane than the other two, is the tibialis posterior.

**Termination of the Popliteal Artery.**—The termination of the popliteal artery lies under cover of the proximal border of the soleus. It should now be cleaned, and it will be seen to end at the distal margin of the popliteus muscle by dividing into the *anterior* and *posterior tibial arteries.* Further, the venæ comites which accompany these vessels will be observed to join at this point to form the large popliteal vein.

**Arteria Tibialis Anterior.**—The anterior tibial artery passes forwards, between the two heads of the tibialis posterior muscle, to the anterior region of the leg, where it has already been dissected. In this part of its course the anterior tibial artery gives off the posterior recurrent tibial and a fibular branch. The *posterior tibial recurrent* is a small twig which is not always present. It runs proximally under cover of the popliteus muscle to the back of the knee-joint. The *fibular branch* runs laterally, on the neck of the fibula, and is distributed to the muscles and integument in the neighbourhood.

**Arteria Tibialis Posterior.**—The posterior tibial artery is the larger of the two terminal branches of the popliteal trunk. It takes origin at the distal border of the popliteus muscle and ends in the hollow on the medial side of the calcaneus, under cover of the abductor hallucis, and at the level of the distal border of the ligamentum laciniatum, by dividing into the lateral and medial plantar arteries. In the first instance the artery is placed, between the two bones of the leg, upon the posterior surface of the tibialis posterior muscle; but as it passes distally it inclines gradually medially, and at its termination it lies midway between the prominence of the calcaneus and the medial malleolus.

In its proximal two-thirds the posterior tibial artery is situated deeply, being covered by the superficial muscles of the calf. In the distal third of the leg it lies between the tendo calcaneus and the medial border of the tibia, and is covered merely by the integument and two layers of fascia. More distally it is covered by the ligamentum laciniatum. Proximo-distally it rests against the tibialis posterior, the flexor digitorum longus, the tibia, and the posterior aspect of the ankle-joint.

Throughout its entire course the posterior tibial artery is closely accompanied by two *venæ comites*. The *tibial nerve* is at first on its medial side, but it soon crosses the vessel, and then proceeds distally on its lateral side.

The following are the branches which issue from the posterior tibial artery:—

1. Muscular.
2. A. nutritia tibiae.
3. A. peronæa.
4. Cutaneous branches.
5. Medial calcanean.
6. Ramus communicans.
7. A. plantaris medialis.
8. A. plantaris lateralis.

The *muscular branches* supply the deep muscles on the back of the leg, and one or two of large size enter the soleus.

The *cutaneous branches* are given to the skin on the medial aspect of the leg.

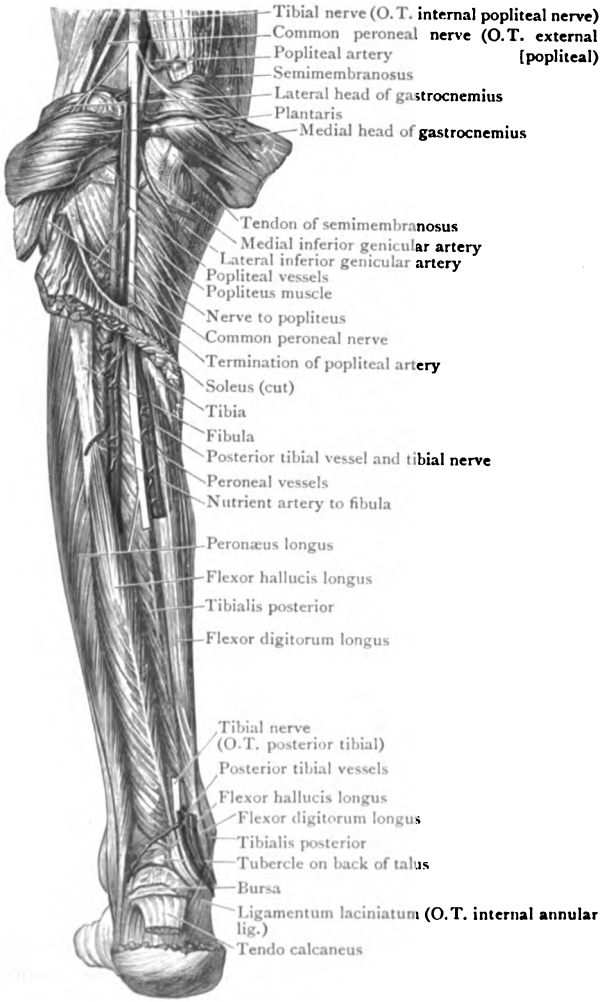


FIG. 103.—Deep Dissection of the Back of the Leg.

The *nutrient artery* springs from the posterior tibial close

to its origin, and, after giving some twigs to muscles, enters the nutrient foramen of the tibia. It is remarkable on account of its large size.

The *communicating branch* is given off about an inch proximal to the distal end of the tibia. It passes transversely laterally, under cover of the flexor hallucis longus, and joins the peroneal artery.

The *medial calcanean branches* pierce the ligamentum laciniatum, and accompany the nerves of the same name to the skin of the heel and the sole.

The *peroneal artery* is a large branch which proceeds from the posterior tibial about one inch or so distal to its origin. In the present stage of the dissection it is seen running obliquely distally and laterally, upon the tibialis posterior, to reach the fibula. It is covered by the soleus, and is accompanied by the nerve to the flexor hallucis longus. It cannot be traced further at present, as it sinks into the substance of the flexor hallucis.

**Crural Part of Nervus Tibialis** (O.T. **Posterior Tibial Nerve**).—The tibial nerve is continued from the popliteal fossa through the posterior region of the leg to the hollow between the heel and the medial malleolus, where it divides into the lateral and medial plantar nerves. It accompanies the posterior tibial vessels, and presents the same relations. For a short distance, in the proximal part of the leg, it lies on the medial side of the posterior tibial artery, but it soon crosses superficial to the artery, and is then continued distally, for the remainder of its course, on the lateral side of the vessel.

It supplies—(*a*) *muscular branches* to the tibialis posterior, flexor hallucis longus, flexor digitorum longus, and soleus; (*b*) *cutaneous twigs*—the *medial calcanean branches*—which spring from it close to its termination, and pierce the ligamentum laciniatum to reach the integument of the heel and sole of the foot; and (*c*) *articular filaments* to the ankle-joint.

**Deep Muscles.**—The *popliteus muscle* will be seen lying upon the posterior aspect of the knee-joint and upon the posterior surface of the tibia proximal to the linea poplitea. Its tendon of origin lies within the capsule of the knee-joint, and cannot be properly studied until that articulation is dissected.

Note the strong fascia which covers the posterior surface of the popliteus, and trace it proximally and medially to the medial side of the

knee. There it will be observed to be continuous with the tendon of the semimembranosus, and through it, therefore, the semimembranosus may be regarded as having an insertion into the linea poplitea of the tibia.

The *flexor hallucis longus* is placed upon the posterior aspect of the fibula, and its tendon will be noticed grooving the posterior border of the talus as it passes distally and forwards to gain the sole of the foot. The *flexor digitorum longus* lies upon the tibia. The *tibialis posterior* rests upon the interosseous membrane upon a deeper plane and between the fleshy bellies of the two flexors.

**Fascia covering the Tibialis Posterior.**—This constitutes the second partition which crosses the posterior osteo-fascial compartment of the leg. It is a strong fascia, which is attached on the one hand to the medial border of the fibula, and on the other to the vertical ridge which descends from the linea poplitea on the posterior surface of the tibia. To demonstrate these attachments, the flexor muscle of the toes must be pushed medially and some of its fibres divided. The flexor hallucis longus must in like manner be pushed laterally. The fascia will then be seen to serve as a surface of origin for both of those muscles; and, on its removal, it will also be observed to give fibres, by its deep surface, to the subjacent tibialis posterior.

FIG. 104.—Posterior aspect of Bones of Leg with Attachments of Muscles mapped out.

**M. Popliteus.**—The popliteus muscle arises by a stout

narrow tendon, within the capsule of the knee-joint, from the anterior part of the popliteal groove on the lateral surface of the lateral condyle of the femur. The fleshy fibres are directed medially and distally, and spread out to obtain insertion into the posterior surface of the tibia proximal to the linea poplitea, and also into the fascia which covers the muscle.

The nerve to the popliteus has already been seen to arise from the *tibial nerve*. It can now be seen hooking round the distal margin of the muscle to reach its anterior surface.

**M. Flexor Hallucis Longus.**—The flexor hallucis longus is a powerful muscle which arises from the posterior surface of the fibula, distal to the origin of the soleus, from the posterior fibular septum, and from the surface of the fascia covering the tibialis posterior. Its tendon occupies a deep groove on the posterior border of the talus, and turns forwards under cover of the ligamentum laciniatum to gain the sole of the foot. The flexor hallucis longus is supplied by the *tibial nerve*.

**M. Flexor Digitorum Longus.**—The flexor digitorum longus arises from the posterior surface of the body of the tibia, distal to the popliteus, and medial to the vertical ridge which descends from the linea poplitea. It also derives fibres from the surface of the fascia which covers the tibialis posterior. After crossing the distal part of the tibialis posterior, its tendon grooves the back of the medial malleolus on the lateral side of the tendon of that muscle. It is continued under cover of the ligament laciniatum into the sole of the foot. The flexor digitorum longus is supplied by the *tibial nerve*.

**M. Tibialis Posterior** (O.T. **Tibialis Posticus**).—This muscle takes origin from the posterior surface of the interosseous membrane, from the posterior part of the medial surface of the body of the fibula, from the posterior surface of the body of the tibia, on the lateral side of the flexor digitorum longus, and from the fascia which covers it. In Fig. 95, p. 262, the compartment which it occupies is shown in a diagrammatic manner, and the surfaces from which it takes origin are indicated. Towards the distal part of the leg the tibialis posterior inclines medially, under cover of the flexor digitorum longus, and its strong flattened tendon grooves the back of the medial malleolus to the medial side of the tendon of that muscle. Proceeding under cover of the ligamentum laciniatum, its tendon is

inserted into the tubercle of the navicular bone, and also, by a number of slips, into certain of the tarsal and metatarsal bones. Those slips will be dissected later. The tibialis posterior is supplied by the *tibial nerve.*

**Arteria Peronæa.**—The peroneal artery may now be traced distally, as it runs along the fibula under cover of the flexor hallucis longus. It is accompanied by two *venæ comites.* About an inch, or an inch and a half, proximal to the ankle-joint it gives off its perforating branch, and then, continuing

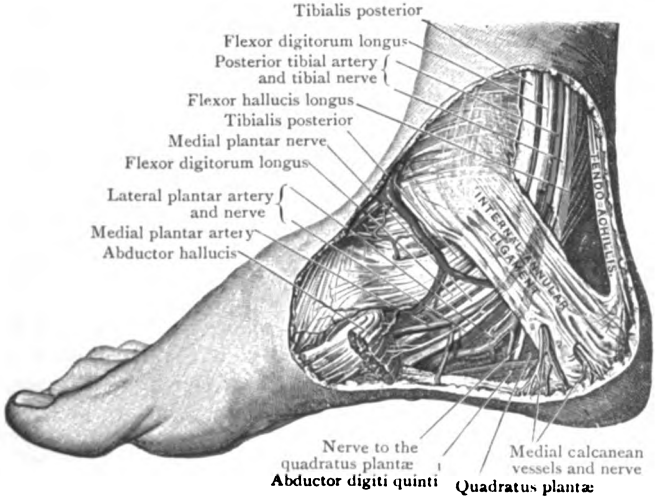


FIG. 105.—Dissection of the medial side of the Ankle, showing the relations of the lig. laciniatum (O.T. internal annular lig.).

distally, it passes posterior to the tibio-fibular syndesmosis and turns forwards, distal to the lateral malleolus, to end on the lateral aspect of the calcaneus by breaking up into a number of lateral calcaneal branches.

In addition to these it gives off—

1. Muscular branches.
2. A. nutritia fibulæ.
3. Ramus communicans.

The *muscular branches* supply the muscles around it. The *fibular nutrient artery* enters the nutrient foramen on the posterior surface of the fibula. The *communicating artery*

arises a short distance proximal to the ankle-joint, and runs transversely medially, under cover of the flexor hallucis longus, to join the posterior tibial artery.

The *perforating branch* passes forwards, through the interosseous membrane, and has already been dissected in the anterior region of the leg (p. 271).

**Ligamentum Laciniatum** (O.T. **Internal Annular Ligament**).—The connections of this thickened band of deep fascia should be carefully studied, and also the arrangement of the structures which pass under cover of it into the sole of the foot. It bridges across the hollow between the prominence of the calcaneus and the medial malleolus, and it is attached to both. Its chief proximal connection is with the layer of the deep fascia which intervenes between the superficial and deep muscles in the posterior region of the leg, but it is continuous also with the general fascial investment of the limb. Its distal margin gives origin to the abductor hallucis, and is connected with the medial portion of the plantar aponeurosis.

The dissector will observe under cover of this ligament —(*a*) the posterior tibial vessels and the tibial nerve; (*b*) to the lateral side of those, the tendon of the flexor hallucis longus; (*c*) to their medial side, the tendons of the flexor digitorum longus and tibialis posterior. From the medial to the lateral side the structures lie in the following order:—

1. Tendon of tibialis posterior.
2. Tendon of flexor digitorum longus.
3. Posterior tibial vessels.
4. Tibial nerve.
5. Tendon of flexor hallucis longus.

The tendons are isolated from each other and from the vessels and nerve by septa, which pass from the deep surface of the ligamentum laciniatum to ridges on the bones. The septa can be demonstrated by slitting up the ligament, for a short distance, in the line of each of the tendons: each of the three compartments will then be seen to be lined with a glistening mucous sheath.

**Anastomosis around the Ankle-joint.**—The dissector should next satisfy himself with regard to the anastomosis of arteries which takes place around the ankle-joint. On the *lateral aspect* of the joint he will observe inosculations taking place between branches of the following arteries:—(*a*) lateral

malleolar; (*b*) perforating branch of peroneal; (*c*) terminal part of peroneal; and (*d*) lateral tarsal.

On the *medial aspect* of the joint the medial malleolar branch of the anterior tibial anastomoses with small twigs from the medial calcanean branches of the posterior tibial.

## SOLE OF THE FOOT.

In this dissection the dissector will meet with the following structures:—

1. Superficial fascia and cutaneous vessels and nerves.
2. Plantar aponeurosis.
3. Superficial muscles, { Abductor hallucis. Flexor digitorum brevis. Abductor digiti quinti.
4. Lateral and medial plantar vessels.
5. Lateral and medial plantar nerves.
6. Tendons of flexor hallucis longus and flexor digitorum longus.
7. Quadratus plantæ and lumbrical muscles.
8. Flexor hallucis brevis. Adductor hallucis, transverse and oblique heads.
9. Flexor brevis digiti quinti.
10. Plantar arterial arch.
11. Plantar metatarsal arteries.
12. Tendons of peronæus longus and tibialis posterior.
13. Interosseous muscles.

**Reflection of Skin.**—The limb should be placed upon the table, with the sole of the foot facing the dissector, and the ankle supported by a good-sized block. Two incisions are required—(1) a longitudinal incision along the middle line of the sole, from the heel to the root of the middle toe; (2) a transverse cut, at the digital extremity of the median incision, across the sole at the roots of the toes. The skin should also be reflected from the plantar surface of each of the toes. This can be done by means of a longitudinal incision along its middle line.

**Superficial Fascia.**—When the flaps of skin which are mapped out by the above incisions are reflected, the peculiar character of the thick layer of superficial fascia becomes apparent. It is tough and granular, and in some respects resembles the superficial fascia which covers the ischial tuberosity. Traversing it are tough fibrous bands, which subdivide the fatty tissue into small lobules, and connect the thick skin of the sole with the plantar aponeurosis.

*Dissection.*—The *medial calcanean nerves*, which have already been found piercing the ligamentum laciniatum, should be traced to their distribution. They supply the skin of the sole in the neighbourhood of the heel.

The superficial fascia may now be removed. Divide it along the middle line of the sole, and turn it laterally and medially, cleaning at the same

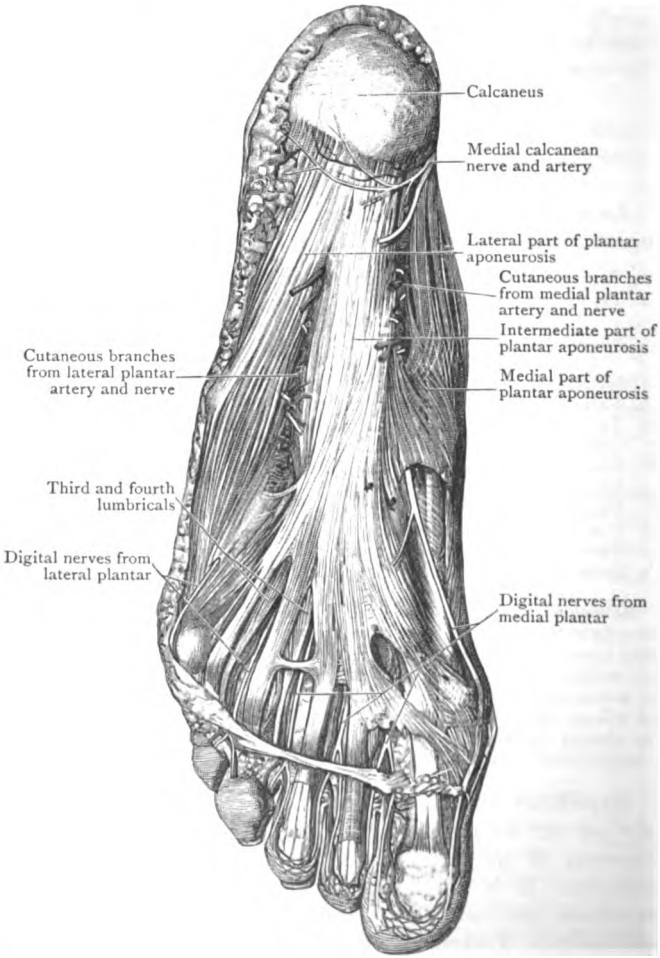
Calcaneus
Medial calcanean nerve and artery
Lateral part of plantar aponeurosis
Cutaneous branches from medial plantar artery and nerve
Intermediate part of plantar aponeurosis
Medial part of plantar aponeurosis
Cutaneous branches from lateral plantar artery and nerve
Third and fourth lumbricals
Digital nerves from lateral plantar
Digital nerves from medial plantar

FIG. 106.—Superficial Dissection of the Sole of the Foot ; the Skin and Superficial Fascia alone removed.

time the plantar aponeurosis. As the dissector approaches the lateral and medial margins of the foot respectively, he will observe two furrows to extend forwards on each side of the intermediate part of the plantar aponeurosis. Along the line of these a number of blood-vessels and some

nerves will be seen piercing the deep fascia in order to reach the skin. Towards the heads of the metatarsal bones the metatarsal arteries and the common plantar digital nerves are unprotected by the aponeurosis, and the dissector must proceed cautiously. The nerves and vessels which go to the medial side of the great toe and to the fibular side of the little toe are especially liable to injury, as they perforate the fascia farther back than the others. A band of transverse fibres, which crosses the roots of the toes and lies over the digital vessels and nerves, should be noticed. It is the *superficial transverse ligament* of the toes, and is closely connected with the skin where that forms the cutaneous webs between the toes. By forcibly separating the toes its connections will become evident. When the relations of the ligament have been studied it may be removed.

**Aponeurosis Plantaris** (O.T. **Plantar Fascia**).—The plantar aponeurosis, which is now brought into view, consists of three portions—(*a*) a medial, (*b*) an intermediate, and (*c*) a lateral part. This subdivision is indicated by a difference in the density of the three parts and by two shallow furrows which traverse the foot in a longitudinal direction, one upon each side of the strong intermediate portion of aponeurosis. Each of the three portions is in relation to a subjacent muscle. The *intermediate portion* covers the flexor digitorum brevis; the *lateral part* clothes the abductor digiti quinti; and the *medial part* covers the abductor hallucis.

The *intermediate portion* of the plantar aponeurosis stands out in marked contrast to the lateral and medial portions in point of strength and density. Posteriorly, where it is attached to the medial process of the calcaneus, it is narrow, but it expands as it passes forwards, and, near the heads of the metatarsal bones, splits into five processes, which are bound together by transverse fibres. In the intervals between the digital slips the metatarsal vessels, the common digital nerves, and the lumbrical muscles appear. Trace the processes forwards. One goes to the root of each toe, and there divides into two slips, which embrace the flexor tendons and become fixed to the flexor sheaths, and to the transverse ligament of the heads of the metatarsal bones on each side of the toe. In its arrangement, therefore, this portion of the plantar aponeurosis closely resembles the intermediate part of the palmar aponeurosis.

The *lateral and medial parts* of the plantar aponeurosis are weak in comparison with the intermediate portion. They merely constitute fascial coverings for the muscles which lie subjacent. A strong band is to be noted in connection with the *lateral part*. It stretches between the prominence

formed by the base of the fifth metatarsal bone and the lateral process of the tubercle of the calcaneus.

In connection with the plantar aponeurosis two *intermuscular septa* also have to be studied. These pass dorsally into the sole, along the lines of the longitudinal furrows which mark off the intermediate from the medial and lateral parts of the aponeurosis. They consequently lie one upon each side of the flexor digitorum brevis, and form partitions which separate it from the abductor hallucis on the one side, and the abductor digiti quinti on the other.

*Dissection.*—To demonstrate these septa, make a transverse incision through the intermediate portion of the plantar aponeurosis, about an inch in front of the medial process of the tubercle of the calcaneus, and also a longitudinal cut through the same piece of aponeurosis, extending from the first incision along the middle line of the foot. Now raise the divided aponeurosis and throw it laterally and medially. Some difficulty will be experienced in effecting this, owing to its affording a surface of origin, in its posterior part, to the subjacent flexor digitorum brevis. As the margins of this muscle are approached the septa are brought into view.

**Muscles and Tendons of the Sole.**—It is customary to look upon the muscles and tendons found in the dissection of the sole as being disposed in four strata, viz. :—

| | |
|---|---|
| First layer. | Abductor hallucis.<br>Flexor digitorum brevis.<br>Abductor digiti quinti. |
| Second layer. | Tendon of flexor digitorum longus.<br>Quadratus plantæ.<br>Lumbrical muscles.<br>Tendon of flexor hallucis longus. |
| Third layer. | Flexor hallucis brevis.<br>Adductor hallucis, oblique and transverse heads.<br>Flexor digiti quinti brevis. |
| Fourth layer. | Interosseous muscles.<br>Tendon of peronæus longus.<br>Tendon of tibialis posterior. |

*Dissection.*—The lateral and medial portions of the plantar aponeurosis should be raised from the subjacent muscles. The three superficial muscles of the sole are then exposed to view and their connections can be studied. The *flexor digitorum brevis* is placed intermediately, the *abductor digiti quinti* extends along the lateral margin of the sole, and the *abductor hallucis* along the medial margin of the sole. In the interval between the abductor hallucis and flexor digitorum brevis the *medial plantar nerve* and *artery* will be found. Follow the nerve toward the toes and dissect out its four common digital branches. While this is being done, care must be taken of the muscular twigs which are given to the flexor hallucis brevis and the most medial lumbrical muscle. Slender branches of the medial plantar artery accompany the common digital nerves. Now trace the trunk of the *medial plantar nerve* posteriorly, by carefully separating the flexor digitorum

brevis and the abductor hallucis along the line of the medial intermuscular septum. It will be found to give a branch of supply to each of those muscles. In the next place, separate the contiguous borders of the flexor digitorum brevis and abductor digiti quinti. The *lateral plantar artery* and *nerve* lie, for a short portion of their course, in the interval between those muscles. Approaching the prominent base of the fifth metatarsal bone, the artery disappears from view, by turning medially under cover of the flexor tendons. At the same point the lateral plantar nerve divides

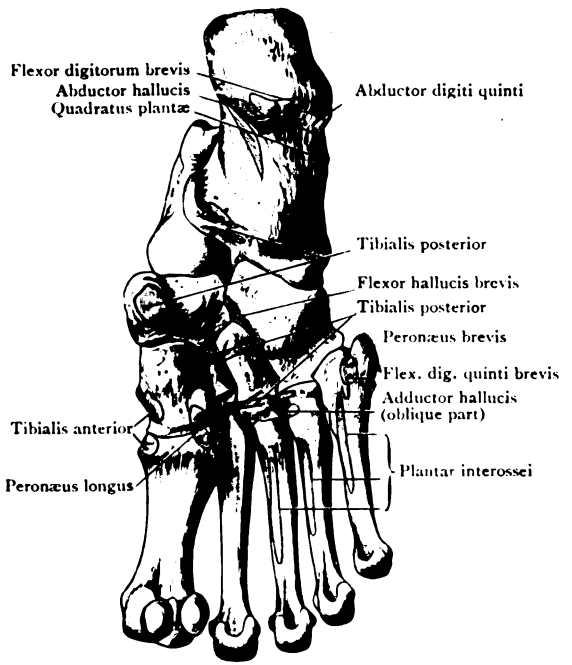


FIG. 107.—Plantar aspect of the Tarsus and Metatarsus, with Attachments of Muscles mapped out.

into its superficial and deep divisions. The *deep division* of the lateral plantar nerve and the deep part of the lateral plantar artery cannot be dissected at present. The *superficial division* of the nerve, however, should be traced to its distribution.

**M. Flexor Digitorum Brevis.**—This muscle arises from the medial process of the calcaneus, from the deep surface of the intermediate part of the plantar aponeurosis, and from the intermuscular septum on each side of it. About the middle of the sole the fleshy belly divides into four slips, which end

in slender tendons for the lateral four toes. These enter the fibrous flexor sheaths of the toes, and will be afterwards studied. The flexor digitorum brevis is supplied by the *medial plantar nerve.*

**M. Abductor Hallucis.**—The abductor hallucis takes origin from the medial aspect of the medial process of the tubercle of the calcaneus, from the medial intermuscular septum, from the distal border of the ligamentum laciniatum, and from the medial part of the plantar aponeurosis, which covers it. A strong tendon issues from the fleshy belly. This is joined, on its lateral and deep surface, by fibres of the medial head of the flexor hallucis brevis, and it is inserted into the medial aspect of the base of the proximal phalanx of the great toe. The abductor hallucis is supplied by the *medial plantar nerve.*

**M. Abductor Digiti Quinti** (O.T. **Abductor Minimi Digiti**).—The origin of the abductor quinti digiti muscle extends medially under cover of the flexor digitorum brevis. The latter muscle must therefore be detached from the calcaneus and turned forwards. The abductor digiti quinti is then seen to have a broad origin from both the medial and lateral processes of the calcaneus, from the lateral intermuscular septum, and the lateral part of the plantar aponeurosis, which covers it. Its tendon is inserted into the lateral aspect of the base of the proximal phalanx of the little toe. The abductor digiti quinti is supplied by the *lateral plantar nerve.*

*Dissection.*—The origin of the *abductor hallucis* from the calcaneus and from the ligamentum laciniatum should be divided and the muscle turned medially. With a little dissection the mode and place of origin of the *plantar arteries* and *nerves* will be made manifest. They are the terminal branches of the *posterior tibial artery* and *tibial nerve*, and they arise in the hollow of the calcaneus, under cover of the origin of the abductor hallucis. But further, the *lateral plantar artery* and *nerve* may now be traced as they pass laterally upon the quadratus plantæ to the point where they were first seen—viz., in the interval between the abductor digiti quinti and the flexor digitorum brevis. While the lateral plantar nerve is being followed, the branches which it gives to the quadratus plantæ muscle and the abductor digiti quinti must be secured. The nerve to the abductor lies close to the tubercle of the calcaneus.

**Art. Plantaris Medialis** (O.T. **Internal Plantar Artery**).—The medial plantar artery is the smaller of the two terminal branches of the posterior tibial artery. It arises in the hollow between the medial malleolus and the prominence of the calcaneus, at, or proximal to, the distal border of the ligamentum laciniatum. At first it is placed under cover of the abductor

hallucis; but, as it proceeds forwards, it appears in the interval between this muscle and the flexor digitorum brevis. Finally, at the root of the great toe, it ends by joining the plantar digital artery to the medial side of the hallux.

The *branches* which proceed from the medial plantar are small but very numerous. They are—(1) three twigs which accompany the common digital branches of the medial plantar nerve to the clefts between the medial four toes—these end by joining the corresponding metatarsal arteries; (2) a series of cutaneous branches to the skin of the sole, which pierce the aponeurosis in the furrow between its medial and intermediate parts; (3) a number of branches to the muscles in the vicinity; (4) some offsets which pass medially under cover of the abductor hallucis to reach the medial border of the foot.

**Art. Plantaris Lateralis** (O.T. **External Plantar Artery**). —The lateral plantar artery is much larger than the medial plantar. It is accompanied by the lateral plantar nerve and two *venæ comites*. From its origin in the hollow of the calcaneus it proceeds laterally, across the sole, to reach the interval between the flexor digitorum brevis and the abductor digiti quinti. In that interval it is continued forwards for a short distance, and then, at the base of the fifth metatarsal bone, it turns suddenly to the medial side, and crosses the sole a second time, under cover of the flexor tendons, forming the plantar arch. In the present stage of the dissection it is displayed only as far as the base of the fifth metatarsal bone. Between its origin and that point its relations are as follows:—(1) It is placed between the abductor hallucis and the hollow of the calcaneus; (2) it lies between the flexor digitorum brevis and the quadratus plantæ; (3) it occupies the interval between the flexor digitorum brevis and the abductor digiti quinti. In the latter situation it is near the surface, and is covered merely by the integument and fasciæ.

The *branches* which proceed from this part of the vessel are —(1) twigs to the neighbouring muscles; (2) *medial calcanean branches*, which arise near its origin, and gain the heel by piercing the origin of the abductor hallucis; (3) cutaneous branches, which appear through the plantar aponeurosis along the line of the lateral intermuscular septum; (4) twigs to the lateral margin of the foot, which anastomose with the lateral tarsal and arcuate branches of the dorsalis pedis.

**Nervus Plantaris Medialis** (O.T. **Internal Plantar Nerve**). —The medial plantar nerve is the larger of the two terminal branches of the tibial nerve. It takes origin in the hollow of the calcaneus, under cover of the ligamentum laciniatum. It accompanies the medial plantar artery, and presents the same relations. After it emerges from under cover of the abductor hallucis, it gives off the proper digital branch to the medial side of the hallux, and then ends, in the interval between the abductor hallucis and the flexor digitorum brevis, by dividing into three common digital branches.

The *branches* of the medial plantar nerve are:—

1. Cutaneous twigs to the skin of the sole.
2. Muscular branches.
3. Proper digital branch to medial side of great toe.
4. Three common digital branches.

The *cutaneous twigs* to the integument of the sole spring from the trunk of the nerve, and pierce the aponeurosis in the line of the medial intermuscular septum.

The *proper digital nerve to the great toe* supplies the medial side of that toe.

The *three common digital branches* pass to the proximal ends of the medial three interdigital clefts, where each divides into two proper digital branches. The proper digital branches of the most medial common digital nerve supply the adjacent sides of the great toe and the second toe; those of the second common digital nerve supply the adjacent sides of the second and third toes; and the proper digital branches of the third common digital supply the adjacent sides of the third and fourth toes. From the third common digital branch of the medial plantar nerve a communication is given to the superficial part of the lateral plantar nerve. The digital distribution of the medial plantar nerve in the foot closely resembles that of the median nerve in the hand.

The proper digital nerves should be traced along the toes. They are arranged in a manner very similar to that of the corresponding nerves of the fingers.

The *muscular branches* go to four muscles of the sole, viz., the abductor hallucis, the flexor digitorum brevis, the flexor hallucis brevis, and the most medial or first lumbrical muscle. The branches which supply the abductor hallucis and the flexor digitorum brevis arise from the trunk of the medial plantar nerve a short distance from its origin. The other

two spring, one from the proper digital nerve to the medial side of the great toe, and the other from the first common digital

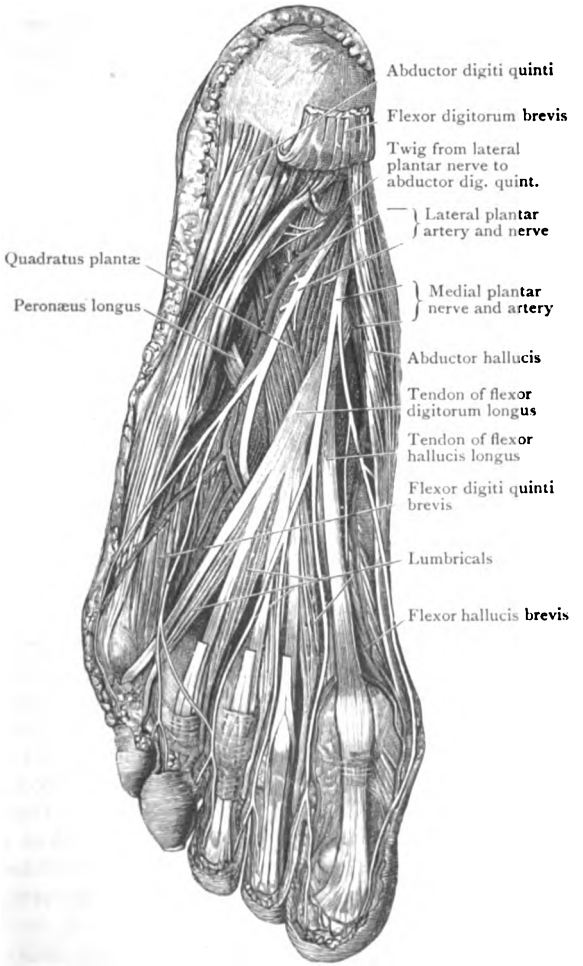


FIG. 108.—Dissection of the Sole of the Foot; the Flexor Digitorum Brevis has been reflected.

nerve: the former supplies the flexor hallucis brevis; the latter supplies the first lumbrical.

**Nervus Plantaris Lateralis** (O.T. **External Plantar Nerve**). —The lateral plantar nerve corresponds to the ulnar nerve in the palm of the hand. It accompanies the lateral plantar artery and possesses the same relations. In the interval between the abductor digiti quinti and the flexor digitorum brevis, opposite the base of the fifth metatarsal bone, it divides into a deep and a superficial part. The *deep division* follows the plantar arch, under cover of the flexor tendons. The *superficial division* divides into a proper and a common digital branch.

From the trunk of the lateral plantar nerve proceed *two muscular branches*, viz., to the quadratus plantæ and to the abductor digiti quinti.

The *first* or *lateral proper digital branch* of the superficial part of the lateral plantar nerve goes to the lateral side of the little toe. It also gives muscular twigs to the flexor brevis digiti quinti and the interosseous muscles in the fourth intermetatarsal space.

The *second common digital branch* divides into two proper digital branches which supply the adjacent sides of the fourth toe and little toe. It sends also a twig of communication to the third common digital branch of the medial plantar nerve.

*Dissection.*—The abductor digiti quinti should be completely detached from its origin, and turned forwards, in order that a good display may be obtained of the structures composing the second stratum of the sole.

**Second Layer of Muscles and Tendons.**—As the tendon of the *flexor hallucis longus* enters the sole it grooves the plantar surface of the sustentaculum tali and inclines medially towards the great toe. The tendon of the *flexor digitorum longus*, on the other hand, inclines laterally to reach the middle of the foot, where it divides into four tendons for the lateral four toes. Moreover, the tendons of these two muscles cross each other in the sole—the tendon of the flexor digitorum lying upon the plantar or superficial surface of the tendon of the flexor hallucis longus, and receiving from it a strong tendinous slip.

Sir William Turner has called attention to the fact that this slip, which passes from the tendon of the flexor hallucis longus to the tendon of the flexor longus digitorum, varies greatly in magnitude and in the manner in which it is connected with the flexor tendons of the toes. In the majority of cases it goes to the tendons of the second and third toes; in some cases, however, only to the tendon of the second toe, or to the tendons of the second, third, and fourth toes. Very rarely does it divide so as to bring

all the tendons of the flexor digitorum longus into connection with the tendon of the flexor hallucis longus.

The *musculus quadratus plantæ*, which is inserted into the tendon of the long flexor of the toes, and also the four *lumbrical muscles*, which arise from the flexor tendons, can now be distinguished. Note the position of the long plantar ligament between the two heads of origin of the quadratus plantæ.

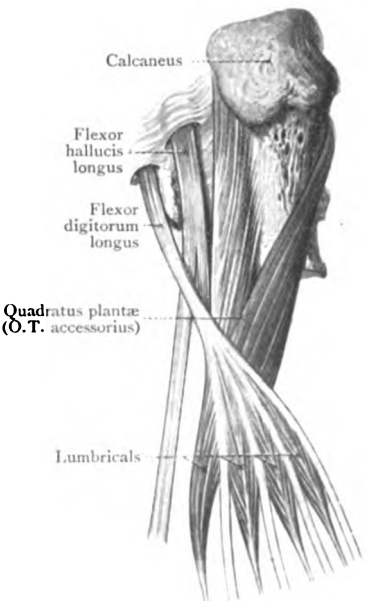


FIG. 109.—Second layer of Muscles and Tendons in the Sole of the Foot.

**Fibrous Flexor Sheaths.**—Before tracing the flexor tendons forwards on the toes, it is necessary to examine the sheaths which retain them upon the plantar aspect of the phalanges. In their construction those fibrous sheaths are precisely similar to the corresponding sheaths of the fingers. They are not so strongly marked, but they present the same thickenings over the shafts of the phalanges and the same want of strength opposite the interphalangeal joints. They may now be opened in order that the enclosed tendons may be examined. A mucous sheath is present in each to facilitate the play of the flexor tendons within it (see p. 123).

**Insertions of the Flexor Tendons.**—Two tendons, one from the flexor digitorum brevis and one from the flexor digitorum longus, enter the flexor sheath of each of the lateral four toes. Of these, the tendon of the former muscle corresponds with a tendon of the flexor sublimis in the hand, whilst the tendon of the flexor digitorum longus corresponds with a tendon of the flexor profundus. Further, they are inserted in exactly the same manner. The tendon of the flexor brevis, which is the more superficial, divides into two

slips, and between those the tendon of the flexor digitorum longus proceeds forwards to its insertion into the plantar aspect of the base of the ungual phalanx. The two slips of the tendon of the flexor brevis are joined by their margins on the deep surface of the long flexor tendon, and then separate again to obtain insertion into the sides of the shaft of the second phalanx, about its middle.

**Tendon of the Flexor Hallucis Longus.**—After giving its slip to the tendon of the flexor digitorum longus, the tendon of the flexor hallucis longus is prolonged forwards to the great toe. On the plantar aspect of the hallux it is retained in place by a fibrous flexor sheath, and finally it is inserted into the base of the terminal phalanx.

**M. Quadratus Plantæ** (O.T. **Flexor Accessorius**).—This muscle takes a course straight forwards from the heel, and acts as a direct flexor of the toes. It also tends to bring the tendons of the long flexor muscle into a line with the toes upon which they operate. It arises by two heads which embrace the calcaneus and the long plantar ligament. The *medial head*, wide and fleshy, springs from the medial concave surface of the calcaneus; the *lateral head*, narrow, pointed, and tendinous, takes origin from the lateral surface of that bone, and also from the long plantar ligament. The quadratus plantæ is inserted into the tendon of the flexor digitorum longus in the middle of the sole. It is supplied by a branch from the *lateral plantar nerve*.

**Mm. Lumbricales.**—The lumbrical muscles of the foot are not so strong as the corresponding muscles in the palm of the hand. They are four in number, and arise from the tendons of the flexor digitorum longus. The lateral three lumbricals spring from the adjacent sides of the tendons between which they lie; the first or most medial muscle takes origin from the medial side of the tendon of the long flexor which goes to the second toe. The slender tendons of the lumbrical muscles proceed to the medial sides of the lateral four toes, and are inserted into the expansions of the extensor tendon on the dorsal aspect of the proximal phalanges. The *first* or *most medial lumbrical* is supplied by the *medial plantar nerve*: the *others* are supplied by the *lateral plantar nerve*.

*Dissection.*—To bring the third layer of muscles into view the following dissection must be made:—Divide the two heads of the quadratus plantæ and draw the muscle forwards from under the lateral plantar vessels and

nerve. Sever also the tendons of the flexor digitorum longus and the flexor hallucis longus at the point where they emerge from under cover of the ligamentum laciniatum. These structures can be thrown forwards towards the toes when the branch from the lateral plantar nerve to the quadratus plantæ is cut. As the lumbrical muscles are raised, the twigs which are furnished to the *second*, *third*, and *fourth* by the deep division of the lateral plantar nerve must be looked for. That for the second lumbrical muscle will be seen to take a recurrent course round the transverse head of the adductor hallucis muscle. Lastly, cut the medial plantar nerve close to its origin and turn it aside.

**Third Layer of Muscles.**—The *flexor hallucis brevis* lies along the lateral side of the abductor hallucis.

The *oblique head of the adductor hallucis* has a very oblique position in the sole, and hides the interosseous muscles to a great extent. It lies to the lateral side of the flexor hallucis brevis.

The *transverse head of the adductor hallucis* is placed transversely across the heads of the metatarsal bones and the plantar ligaments of the metatarso-phalangeal joints.

The *flexor digiti quinti brevis* (O.T. *minimi digiti*) may be recognised from its lying upon the fifth metatarsal bone.

The deep division of the lateral plantar nerve and the plantar arterial arch are partially exposed, but they will be more fully displayed at a later stage.

**M. Flexor Hallucis Brevis.**—This muscle arises from the *cuboid bone* and from the slip from the tendon of the tibialis posterior muscle which goes to the second and third cuneiform bones. It is narrow and tendinous at its origin, but it soon divides into two separate fleshy bellies, which are ultimately inserted one upon each side of the base of the proximal phalanx of the great toe. In the tendons of insertion two large sesamoid bones are developed. The medial head of the flexor hallucis brevis is closely connected with the tendon of the abductor hallucis, and is inserted in common with it. The flexor hallucis brevis is supplied by the *medial plantar nerve.*

**M. Adductor Hallucis** (O.T. **Adductor Obliquus Hallucis and Adductor Transversus Hallucis**).—The adductor hallucis consists of two separate portions called the oblique and the transverse heads of the muscle. The **oblique head** arises from the sheath of the peronæus longus tendon and from the bases of the second, third, and fourth metatarsal bones. It tapers as it approaches the root of the hallux, and is inserted, with the lateral head of the flexor hallucis brevis,

into the lateral aspect of the base of the proximal phalanx of the great toe. It is supplied by the *deep division* of

FIG. 110.—Deep Dissection of the Foot; the Superficial Muscles and also the Flexor Tendons, etc., have been removed.

the *lateral plantar nerve.* The **transverse head** springs by a series of slips from the plantar metatarso-phalangeal

ligaments of the third, fourth, and fifth toes, and proceeds transversely medially, under cover of the flexor tendons, to find insertion into the lateral side of the base of the proximal phalanx of the great toe, in common with the oblique head. Its nerve of supply comes from the *deep division* of the *lateral plantar nerve.*

**Flexor Digiti Quinti Brevis** (O.T. **Flexor Brevis Minimi Digiti**).—The flexor digiti quinti brevis is a single fleshy slip, which springs from the base of the fifth metatarsal bone and the sheath of the peronæus longus tendon. It is inserted into the lateral side of the base of the proximal phalanx of the little toe. Its nerve of supply comes from the *superficial division* of the *lateral plantar nerve.*

*Dissection.*—The oblique head of the adductor hallucis and the flexor hallucis brevis must now be detached from their origins and thrown forwards, in order that the entire length of the plantar arterial arch, and the deep division of the lateral plantar nerve, may be displayed. In raising the oblique head of the adductor hallucis the branch which is given to it by the deep division of the lateral plantar nerve must be secured and retained.

**Arcus Plantaris.** — The plantar arterial arch is the continuation of the lateral plantar artery across the sole of the foot. It runs from the base of the fifth metatarsal bone to the base of the first interosseous space, where it is joined by the terminal plantar portion of the dorsalis pedis artery. The arch is deeply placed; it rests against the interosseous muscles, close to the proximal ends of the metatarsal bones, and it is concealed by the flexor tendons, the lumbrical muscles, and the oblique head of the adductor hallucis. It is accompanied by the deep division of the lateral plantar nerve and by two venæ comites.

The branches which proceed from the arch are:—

1. Articular.
2. Posterior perforating.
3. Second, third, and fourth plantar metatarsal arteries.
4. Plantar digital artery to the lateral side of the little toe.

The *articular branches* rise from the concavity of the arch, and run posteriorly to supply the tarsal joints.

The *posterior perforating branches* are three in number. They pass dorsally through the posterior ends of the lateral three intermetatarsal spaces and between the heads of the corresponding dorsal interosseous muscles. Each ends, on the

dorsum of the foot, by joining the corresponding dorsal metatarsal artery.

The *second*, *third*, and *fourth plantar metatarsal arteries* run forwards in the second, third, and fourth intermetatarsal spaces, pass dorsal to the transverse head of the adductor hallucis, and, at the proximal end of the corresponding interdigital cleft, each plantar metatarsal artery ends by dividing into two plantar digital arteries. The plantar digital branches of the second plantar metatarsal artery supply the adjacent sides of the second and third toes; those of the third supply the adjacent sides of the third and fourth toes; and the plantar digital branches of the fourth plantar metatarsal artery supply the adjacent sides of the fourth and fifth toes.

Immediately before it divides, each plantar metatarsal artery sends dorsally an anterior perforating artery which joins the corresponding dorsal metatarsal artery.

Upon the sides of the toes the plantar digital arteries are distributed in exactly the same manner as the proper digital arteries of the fingers (see p. 118).

The plantar digital branch to the lateral border of the little toe springs from the lateral extremity of the plantar arch, crosses the plantar surface of the flexor digiti quinti brevis, and runs forwards to the distal end of the toe.

The **First Plantar Metatarsal Artery** (O.T. **Arteria Magna Hallucis**) corresponds with the arteria volaris indicis radialis and the arteria princeps pollicis of the hand. It arises from the plantar extremity of the dorsalis pedis, at the point where the latter joins the plantar arch, and runs forwards to the cleft between the great toe and the second toe, where it divides into two plantar digital branches for the supply of the adjacent sides of the first and second toes. Before it divides, it gives off a plantar digital branch to the medial side of the great toe which is joined by the terminal part of the medial plantar artery.

**Deep Division of the Lateral Plantar Nerve.**—This accompanies the plantar arch in its course medialwards across the sole, and ends in the deep surface of the oblique head of the adductor hallucis. In addition to that muscle it supplies all the interosseous muscles (with the exception of those in the fourth space), the transverse head of the adductor hallucis, and the lateral *three* lumbrical muscles. The twig to the second lumbrical takes a recurrent course round the

anterior border of the transverse head of the adductor hallucis.

**Transverse Ligament of the Heads of the Metatarsal Bones.**—The transverse head of the adductor hallucis should now be detached from its origin and thrown medially towards

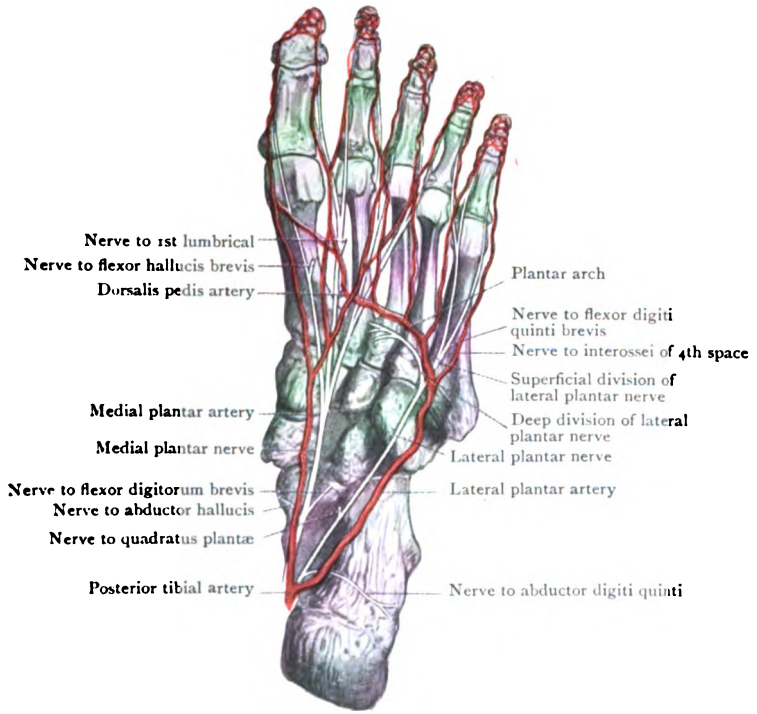
Nerve to 1st lumbrical
Nerve to flexor hallucis brevis
Dorsalis pedis artery
Medial plantar artery
Medial plantar nerve
Nerve to flexor digitorum brevis
Nerve to abductor hallucis
Nerve to quadratus plantæ
Posterior tibial artery
Plantar arch
Nerve to flexor digiti quinti brevis
Nerve to interossei of 4th space
Superficial division of lateral plantar nerve
Deep division of lateral plantar nerve
Lateral plantar nerve
Lateral plantar artery
Nerve to abductor digiti quinti

FIG. 111.—Arteries and Nerves of the Sole of the Foot. (Diagram.)

The plantar nerves and their branches are uncoloured.

the hallux. This brings into view the transverse ligament of the heads of the metatarsal bones—a strong fibrous band which stretches across and is attached to the plantar accessory ligaments of the five metatarso-phalangeal joints. It differs from the corresponding ligament of the hand, inasmuch as it includes within its grasp the plantar accessory ligament of the metatarso-phalangeal joint of the hallux.

*Dissection.*—A satisfactory display of the *interosseous muscles* cannot be obtained unless the transverse ligament is divided between the heads of the metatarsal bones. The toes can then be separated more freely from each other, and the interosseous muscles traced to their insertions. It is well, at this stage, to reflect the flexor digiti quinti brevis also.

**Interosseous Muscles.**—The *plantar interosseous muscles* are three in number, and are so placed that they adduct the lateral three toes towards a line drawn through the second toe. They arise from the plantar aspects of the lateral three metatarsal bones, and each is inserted upon the medial side of the first phalanx of the corresponding toe. The *dorsal interosseous muscles* are four in number. They occupy the four intermetatarsal spaces, and consequently they must be dissected upon both plantar and dorsal aspects of the foot. They are arranged so as to abduct the second, third, and fourth toes from a line drawn through the second toe. They are inserted, therefore, as follows: the *first*, upon the medial side of the second toe; the *second*, upon the lateral side of the same toe; the *third*, upon the lateral side of the third toe; and the *fourth*, upon the lateral side of the fourth toe. The slender tendons of the interosseous muscles are only very slightly attached to the bases of the proximal phalanges. They are inserted for the most part into the expansions of the extensor tendons on the dorsal aspect of the toes.

**Tendon of the Tibialis Posterior.**—Before leaving the sole of the foot the dissector must determine the precise insertions of the tendons of the tibialis posterior and of the peronæus longus. The tendon of the *tibialis posterior* is inserted not merely into the tuberosity of the navicular bone. Fibrous slips are seen to spread out from it, and these may be traced to every bone of the tarsus, with the exception of the talus, and also to the bases of the second, third, and fourth metatarsal bones. As it lies under and gives support to the head of the talus, the tendon of the tibialis posterior has developed within it a sesamoid nodule of fibro-cartilage, or perhaps a sesamoid bone.

**Tendon of the Peronæus Longus.**—The tendon of the peronæus longus turns round the lateral margin of the foot, and runs medially, across the sole, in the groove on the plantar surface of the cuboid bone, to reach the base of the first metatarsal bone. As it traverses the sole it is enclosed in a fibrous sheath. This sheath is formed mainly by fibres derived from the long plantar ligament. Open the sheath,

and its smooth, glistening internal surface will be displayed. The glistening appearance is due to the synovial layer which lines it. The tendon is inserted into the plantar part of the base of the first metatarsal bone, and also to a slight degree into the adjacent part of the first cuneiform bone. In some cases it sends a slip to the base of the second metatarsal bone also. As the tendon winds round the cuboid bone it is thickened, and contains a nodule of fibro-cartilage, or perhaps a sesamoid bone.

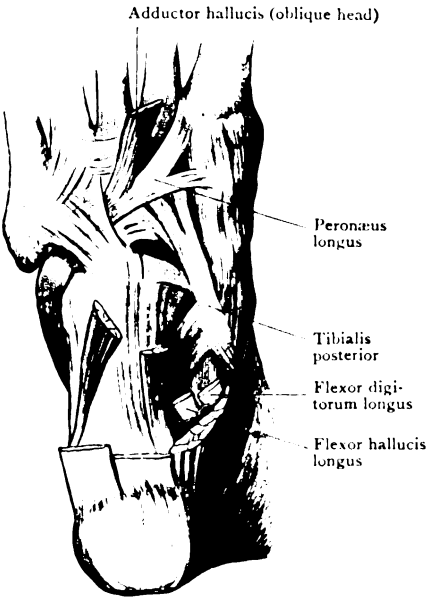


FIG. 112.—The insertions of the Tibialis Posterior and Peronæus Longus Muscles in the Right Foot. (Paterson.)

*Dissection.* — The dissection of the sole of the foot is brought to an end by disarticulating the proximal end of the first metatarsal bone. A good view is thus obtained of the continuity between the dorsalis pedis artery and the plantar arch.

**Anastomosis around the Knee-joint.**—The most important of the anastomoses around the knee-joint are placed on the anterior aspect of the articulation, and take the form of three transverse arches. The *most proximal* of these *arterial arcades* passes through the superficial fibres of the quadriceps extensor, close to the proximal border of the patella, and is formed by the union of a branch from the superior lateral genicular artery with another from the articular branch of the arteria genu suprema. The middle and the distal transverse arches are both placed under cover of the ligamentum patellæ. The *middle arch* runs across in the fatty tissue close to the distal end of the patella. It is formed by the inferior lateral genicular artery, and a branch which results from the union of

a twig from the arteria genu suprema, and another from the superior medial genicular artery. The *most distal arch* lies on the tibia, immediately above its tuberosity, and results from the anastomosis of the anterior recurrent tibial and inferior medial genicular arteries. The proximal and middle of these transverse arches are connected, on each side of the patella, by ascending and descending branches, which anastomose with one another, and thus enclose the patella in an irregularly quadrilateral arterial framework. From all sides of this arterial enclosure, twigs are given off which enter small

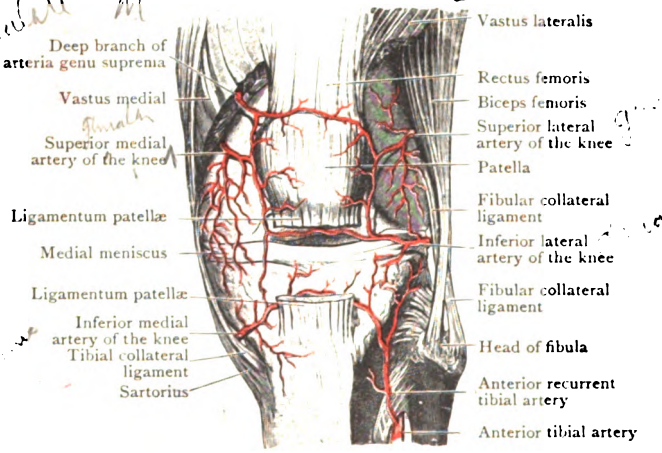


FIG. 113.—Anastomosis on the front of the Left Knee-joint.

foramina on the anterior surface of the patella to supply the osseous substance. Six arteries, therefore, take part in the formation of this system of anastomoses on the front and lateral aspects of the joint, viz., the articular branch of the arteria genu suprema, the two superior and the two inferior genicular branches of the popliteal, and the anterior recurrent branch of the anterior tibial. In addition to the twigs which proceed from these to form the arterial arches, numerous branches are given which spread over the bones in the form of a close meshwork. During the dissection of the articulation these vessels will become apparent.

The knee-joint is supplied on its posterior aspect by twigs derived from all the genicular branches of the popliteal. These twigs are variable in

their origin, and the anastomoses which are formed between them are unimportant and inconstant. They are sometimes supplemented by another artery, the *posterior recurrent tibial.* This small vessel is a branch which arises from the anterior tibial before it leaves the back of the leg. It ascends anterior to the popliteus muscle, ramifies over the distal part of the oblique popliteal ligament, and inosculates with the two inferior genicular branches of the popliteal.

The *middle genicular artery* is destined chiefly for the supply of the interior of the joint. It pierces the oblique popliteal ligament, passes forwards between the cruciate ligaments, and ramifies in the fatty tissue in that situation. Its terminal twigs usually anastomose with the middle arch in front of the knee-joint. It will be dissected, at a later stage, in the interior of the joint.

**Articular Nerves of the Knee-joint.**—The knee-joint is richly supplied with nerves. No less than ten distinct branches may be traced to it. The femoral nerve, the common peroneal, and the tibial nerve trunks contribute three twigs apiece to this articulation, and the obturator nerve furnishes a filament to its posterior aspect. The *femoral nerve* supplies the joint through branches which proceed from the nerves to the vastus lateralis, vastus medialis, and musculus articularis genu. These nerves pierce the fibres of the quadriceps muscle, and are distributed to the proximal and anterior part of the articulation. The articular branch from the nerve to the vastus medialis is of larger size than the other two, and it accompanies the articular branch of the arteria genu suprema. The *common peroneal nerve* gives off—(1) the superior and inferior lateral articular nerves, which accompany the corresponding genicular arteries, and end in fine filaments, which pierce the capsule of the joint; and (2) the recurrent articular nerve which accompanies the anterior recurrent tibial artery. This nerve ends chiefly in the tibialis anterior muscle; but a fine twig may reach the distal part of the anterior aspect of the knee-joint. The *tibial nerve* furnishes the knee-joint with superior and inferior medial articular branches and a middle articular nerve, which accompany the corresponding genicular artery. The branch from the *obturator nerve* descends on the postero-medial aspect of the popliteal artery as far as the back of the knee-joint. At that point it leaves the artery and, inclining forwards, breaks up into several filaments which pierce the oblique popliteal ligament separately.

## ARTICULATIONS.

The dissection of the knee-joint, the ankle-joint, the tibio-fibular joints, and the various articulations of the foot, may now be proceeded with. It is possible that the ligaments may have become hard and dry. If that is the case, soak the joints in water for an hour or two.

### Articulatio Genu (Knee-joint).

In the knee-joint three bones are in apposition, viz., the distal end of the femur, the proximal end of the tibia, and the patella. It is the largest and most complicated articulation in the body; and, when the bones are examined in the dried skeleton, the joint presents an apparent insecurity, because the bony surfaces show little adaptation the one to the other. In reality, however, the knee-joint is very strong, and, on account of the strength of the ligaments which retain the bones in place, it very rarely suffers dislocation. The ligaments on the exterior of the joint are:—

1. The capsular ligament.
2. Two collateral ligaments—fibular and tibial.
3. The ligamentum patellæ (or anterior ligament).
4. The oblique popliteal ligament.

*Dissection.*—The popliteal vessels, tibial and common peroneal nerves, and the muscles surrounding the knee-joint, must be removed. Portions of the tendons of the biceps femoris, semimembranosus, sartorius, semitendinosus, gracilis, and popliteus, together with small pieces of the heads of the gastrocnemius, should be left in place in order that their connections with the ligaments of the joint may be studied. The quadriceps extensor may be divided about three inches proximal to the patella, and the distal part allowed to remain in position. Further, the various genicular arteries, which surround the joint, should be followed to their terminations.

**Capsula Articularis.**—The capsule of the knee-joint, together with the tibial collateral ligament and the oblique popliteal ligament, form a complete investment for the joint. In some places the fibrous or peripheral part of the capsule has disappeared and has been replaced either by bone and cartilage or by tendon, and in other places it has been strengthened and extended by the incorporation of adjacent portions of fascia and tendons; thus, anteriorly, the patella entirely replaces a portion of the capsule. Proximal to the patella the capsule is merely represented by the synovial

stratum covering the posterior surface of the tendon of the quadriceps muscle; on the other hand the antero-medial and the antero-lateral parts of the capsule have been strengthened, by fusion with expansions from the vasti portions of the quadriceps and with the superjacent parts of the fascia lata.

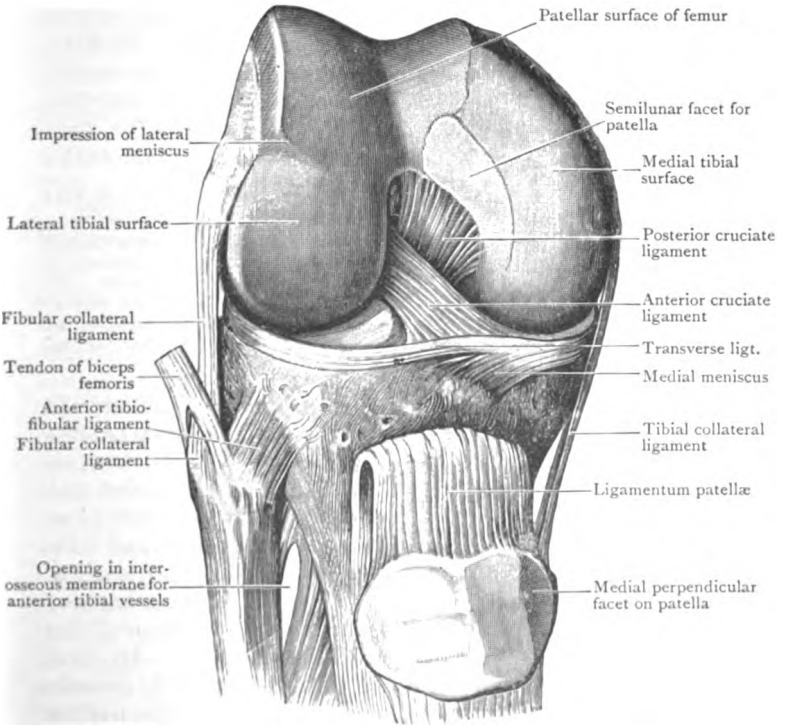


FIG. 114.—Dissection of Knee-joint from the front. The Patella has been thrown distally.

The position and attachments of the original capsule are still indicated, in the adult, by the synovial layer which forms a continuous enclosing membrane except in the region of the patella.

**Ligamentum Patellæ.**—This is a strong reinforcing band situated in relation to the distal and anterior part of the capsule. It constitutes, at the same time, the tendon of

insertion of the quadriceps extensor muscle. Its anterior surface and margins should be carefully defined.

The *ligamentum patellæ* is a strong band, about two inches long, which is attached proximally to the apex and distal border of the patella, and distally to the proximal part of the tuberosity of the tibia. Its superficial fibres are directly continuous over the surface of the patella with the central part of the common tendon of the quadriceps extensor. Its deep surface is separated proximally from the synovial layer by the infrapatellar pad of fat, and distally it is separated from the anterior surface of the proximal end of the tibia by the deep infrapatellar bursa (Fig. 117).

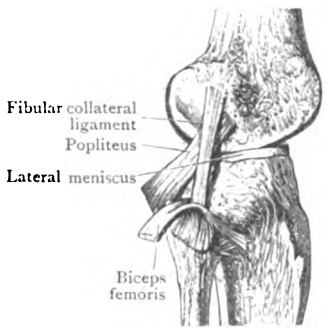


FIG. 115.—The Fibular Collateral Ligament of the Knee-joint.

*Dissection.*—The fibular collateral ligament may be exposed by removing the fascia lata which covers it, and by carefully cleaning the tendon of insertion of the biceps femoris. By this proceeding the inferior lateral genicular artery will be displayed as it runs forwards to the front of the joint.

**Ligamentum Collaterale Fibulare** (O.T. **External Lateral Ligament**).—The fibular collateral ligament is rounded and cord-like. It stands well away from the joint cavity, and is attached proximally to a tubercle on the lateral epicondyle of the femur. Distally, it is fixed to the head of the fibula anterior to the apex. It is closely associated with the tendon of the biceps femoris and the tendon of the popliteus. It splits the tendon of the biceps into two pieces, and extends distally between them to its fibular attachment. The tendon of the popliteus takes origin from the lateral condyle of the femur distal to and anterior to the femoral attachment of the fibular collateral ligament. As the tendon runs backwards it lies under cover of the ligament.

An additional slip is sometimes described as the *posterior part* of the fibular collateral ligament. When present it ends above in the capsule, under cover of the lateral head of the gastrocnemius. Below, it is implanted into the apex of the head of the fibula.

**Ligamentum Collaterale Tibiale** (O.T. **Internal Lateral Ligament**).—The tibial collateral ligament is a long, flat band,

broader in the middle than at either extremity. It springs from the medial condyle of the femur, distal to the adductor tubercle. As it descends it inclines slightly forwards, and, finally, it gains attachment to the margin of the medial condyle and to the proximal part of the body of the tibia below the medial condyle. The main part of the tendon of the semimembranosus extends forwards, under cover of its posterior border, to gain an insertion into the medial condyle of the tibia, whilst more distally the inferior medial genicular vessels are carried forwards between it and the bone. The tendons of the sartorius, gracilis, and semitendinosus, lie upon its superficial surface, but are separated from it by an intervening bursa.

**The Posterior Part of the Capsule and the Ligamentum Popliteum Obliquum** (O.T. **Posterior Ligament**).—The posterior part of the capsule extends as a continuous sheet across the posterior aspect of the joint; laterally it is continuous with the lateral part of the capsule, which lies medial to the fibular collateral ligament, and medially it fuses with the lateral surface of the tibial collateral ligament as the latter crosses the line of the joint. The lateral head of the gastrocnemius fuses with the proximal part of its lateral portion, and the tendon of the popliteus passes through the distal part of the same portion. The medial part of the posterior portion of the capsule is separated from the medial head of the gastrocnemius by a bursa which communicates medially with the bursa between the medial head of the gastrocnemius and the semimembranosus, and it may communicate anteriorly with the cavity of the joint, through an aperture in the capsule. The intermediate part of the posterior portion of the capsule forms part of the anterior boundary of the popliteal fossa, and is strengthened by a strong oblique band, the *oblique popliteal ligament*, which passes proximo-laterally from the distal part of the tendon of the semimembranosus to the medial border of the lateral condyle of the femur.

In addition to the apertures through which the bursa anterior to the medial head of the gastrocnemius communicates with the cavity of the joint, and that through which the tendon of the popliteus emerges, there are several small apertures in the posterior part of the capsule for the transmission of vessels into the interior of the joint.

*Dissection.*—A vertical incision should be made into the joint on each

side of the patella and ligamentum patellæ, in order that the common extensor tendon and the patella may be thrown distally over the proximal end of the tibia. The joint is now opened from the front, and the parts in the interior may be observed.

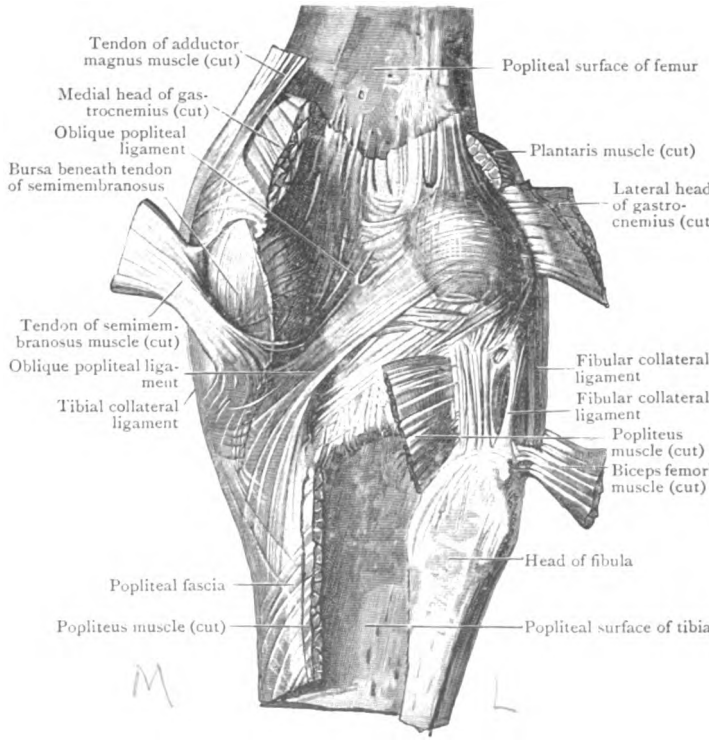


FIG. 116.—The Knee-joint. Posterior view.

**Interior of the Joint.**—First note the great pad of soft fat which is placed on the deep surface of the ligamentum patellæ. In vertical section this fatty mass is triangular in form (Fig. 117). It is termed the *infra-patellar pad*, and it fills up the interval between the patella, femur, and tibia, and adapts itself to the varied forms which that recess adopts in the different movements of the joint. It is separated from the interior of the joint by a covering of the synovial layer, and from its surface a band of the membrane extends posteriorly and proximally to the anterior margin of the intercondylar fossa

of the femur, where it is attached. That band is termed the *patellar synovial fold* (O.T. *ligamentum mucosum*). As it approaches the femur it becomes narrow and slender; but where it covers the surface of the infra-patellar pad it is broad and triangular, and presents two free margins which extend along the lateral borders of the distal part of the patella, and receive the name of *plicæ alares* (O.T. *ligamenta alaria*). It must be clearly understood that these are not ligaments in the ordinary sense of the word, but merely folds of the synovial layer.

Within the joint the dissector can now recognise:

1. The two cruciate ligaments.
2. The two menisci (O.T. semilunar cartilages).

**Stratum Synoviale** (O.T. **Synovial Membrane**).—As the knee-joint is the largest joint in the body its synovial stratum is more extensive than that of any other joint. It lines the deep surfaces of the ligamentous structures of the lateral and anterior parts of the joint. It lines the deep surfaces of the medial and lateral portions of the posterior part of the capsule also, and from them it is prolonged anteriorly along the sides and round the front of the cruciate ligaments. In the anterior part of the joint it is prolonged proximally beyond the articular surface of the distal end of the femur, in the form of a great *cul-de-sac*, under cover of the tendon of the quadriceps. The proximal extremity of this *cul-de-sac* usually communicates by an orifice of greater or less width with the suprapatellar bursa. The synovial layer also invests the menisci, and a pouch-like diverticulum is prolonged posteriorly and distally, along the tendon of the popliteus, which it partially ensheaths, across the posterior part of the external border of the lateral meniscus to the posterior aspect of the proximal end of the tibia. This prolongation lies in close relation with the capsule of the tibio-fibular joint, and in some cases a communication is established between the cavity of the diverticulum and the cavity of the tibio-fibular joint.

*Dissection.*—Divide the patellar synovial fold and remove the infra-patellar pad of fat. The bursa between the ligamentum patellæ and the proximal part of the tibia may now be opened and examined. Next dissect away the intermediate part of the posterior portion of the capsule (oblique popliteal ligament) and trace the middle genicular artery, which pierces it, forwards to the cruciate ligaments. It will now be seen that the posterior surface of the posterior cruciate ligament is not covered by the synovial layer, and that it is connected by areolar tissue to the

deep surface of the posterior part of the fibrous stratum of the capsule. Define the attachments of the cruciate ligaments by removing the synovial layer which is wrapped round them and the areolar tissue in connection with them. The menisci also should receive the attention of the dissector, and the manner in which their fibrous, pointed extremities are fixed to the tibia must be studied. At this stage the changes produced in the degree of tension of the cruciate ligaments, and the change brought about in the position of the menisci by movements of the joint, should be examined.

**Movements at the Knee-joint.**—The movements of the knee-joint are those of flexion and extension. The leg can be bent posteriorly until the prominence of the calf comes into contact with the posterior aspect of the thigh; but in extension the movement is brought to a close when the leg

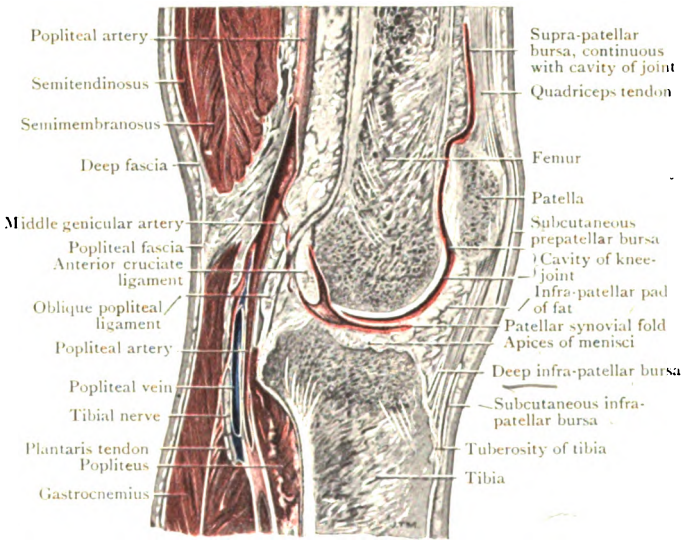


FIG. 117.—Sagittal Section of the Knee-joint.

comes into a line with the thigh. In this position the joint is firmly locked, and the anterior cruciate, the tibial and the fibular collateral ligaments, and the posterior part of the capsule with the accessory oblique popliteal ligament being fully stretched, the leg and thigh are converted into a rigid column of support. In flexion, however, the ligaments mentioned are relaxed, and a certain amount of rotation of the tibia upon the femur is allowed.

Flex the joint acutely, and examine the cartilage-covered surface of the distal end of the femur. It consists of an anterior trochlear portion for the patella, and two condylar surfaces which move on the tibia. The trochlea is separated from the surface of the lateral condyle by a faintly marked groove, which takes a slightly curved course, from the lateral border of the distal end of the femur, medially and posteriorly to the fore

part of the intercondylar fossa. At each extremity this groove widens out into a distinct depression. In full extension the lateral depression rests upon the anterior part of the lateral meniscus, whilst the medial depression rests upon the anterior border of the lateral tubercle of the intercondyloid eminence of the tibia (Bruce Young). The line of demarcation between the trochlea and the distal surface of the medial condyle of the femur is not so distinct. Close to the medial margin of the bone there is a depression which, in full extension, rests upon part of the anterior horn of the medial meniscus (Bruce Young): but lateral to this the trochlear surface is prolonged posteriorly for a certain distance along the anterior and medial margin of the intercondylar fossa. A portion of the medial condyle is thus included in the trochlear surface, viz., the portion skirting the medial border of the anterior part of the intercondylar fossa, and this is termed the "crescentic facet" of the medial condyle.

The posterior surface of the patella may next be examined (Fig. 114), and its movements in connection with flexion and extension of the knee-joint studied. A high vertical ridge divides the posterior surface into a large lateral and a smaller medial area. Each of these is still further subdivided by faint ridges on the cartilage which coats the surface. A faint line upon the medial area of the patella descends in a vertical direction so as to mark off a narrow strip close to the medial border of the bone. This strip is called the *medial perpendicular facet*. Two horizontal lines extend laterally from the lateral border of the medial perpendicular facet to the lateral border of the bone, and subdivide the remainder of the medial area and the whole of the lateral area into three facets each. In a well-marked patella, therefore, the posterior cartilage-covered surface shows seven facets, viz., a proximal pair, a middle pair, a distal pair, and a medial perpendicular facet (Goodsir).

The facetted appearance of the posterior surface of the patella indicates that, in the movements of this bone upon the trochlear surface of the femur, the entire articular surface is never in contact with the femur at the same time. In flexion and extension of the knee, the patella moves distally and proximally in a curved path, the concavity of which looks proximally, posteriorly, and laterally. The different facets come into contact and break contact with the femur in regular succession. Let us suppose the knee-joint to be acutely flexed: in this condition of the limb the medial perpendicular facet of the patella rests upon the crescentic facet of the medial condyle of the femur, while the lateral of the two proximal patellar facets is in contact with the lateral lip of the trochlear surface of the femur. No part of the patella touches the medial lip of the trochlear surface. As the leg is moved from the fully flexed to the fully extended position, the two proximal facets, then the two middle facets, and, lastly, the two distal facets, come successively into contact with the trochlear surface of the femur (Goodsir). In Fig. 117 the position of the patella in the fully extended knee is exhibited.

Now examine the condylar surfaces of the femur (Fig. 114). The posterior two-thirds of the medial condyle will be seen to be of equal extent with, and parallel to, the lateral condyle. The anterior third of the medial condyle, however, turns obliquely laterally to join the trochlear surface. The lateral condylar surface has no corresponding part. The obliquely directed part of the medial condyle gives rise to the "screw-home" movement, which is so characteristic of the knee-joint when fully extended. At the commencement of flexion and at the completion of extension there is a screw movement, or a movement of rotation of the tibia and femur on each other. As the leg is moved forwards from the condition of acute flexion, the condyles of the femur roll and glide over the surfaces on the proximal end of the tibia until the surface of the lateral

condyle, and the corresponding part of the medial condyle, are exhausted. This movement of the femoral condyles has been compared to that of "a wheel partially restrained by a drag" (Goodsir). Any additional movement beyond this point must necessarily take place in connection with the anterior oblique third of the medial condyle. This produces a rotation or screw-like motion of the femur medially. The medial condyle travels backwards round the intercondyloid eminence of the tibia, and the anterior part of the intercondylar fossa comes into contact with the anterior cruciate ligament and the medial tubercle of the intercondyloid eminence (Bruce Young). The joint is now "screwed home" or locked. In the initial stage of flexion the reverse movement must be accomplished. The unlocking of the joint can be brought about only by a rotation medially of the tibia, or a rotation laterally of the femur.

When fully extended, the joint is locked, and the posterior part of the capsule, the collateral ligaments, and the anterior cruciate ligaments are tense. The limb is converted into a rigid column, and the upright posture is thereby maintained with the smallest possible degree of muscular exertion.

The **muscles** which operate upon the bones of the leg so as to produce flexion and extension of the limb at the knee-joint are:—(1) *extensors*, the four parts of the quadriceps extensor; (2) *flexors*, the biceps femoris, popliteus, sartorius, gracilis, semitendinosus, and semimembranosus. Of these, only one is inserted on the lateral side of the limb, viz., the biceps. The other five are inserted into the tibia on the medial side of the leg.

*Dissection.*—In order to obtain a proper view of the attachments of the cruciate ligaments the following dissection should be made:—The femur must be sawn across about two inches proximal to its distal articular surface. When this is done the saw should be applied to the cut surface of the distal part of the bone, and a vertical cut made through it so as to divide it into a right and a left lateral portion. The saw-cut should be planned to end distally in the intercondylar fossa between the condyles and between the proximal attachments of the two cruciate ligaments. By this procedure the cruciate ligaments can be studied singly, or together, and their relation to the collateral ligaments of the joint can be examined. It will be seen that the fibular collateral ligament and the anterior cruciate ligament constitute a pair of ligaments which are fixed to opposite sides of the lateral condyle. The tibial collateral and the posterior cruciate ligaments belong to the medial condyle of the femur, and are attached to its medial and lateral surfaces, respectively. When this relationship is observed, the tibial collateral ligament may be divided. This will, in a measure, set free the medial condyle, and give greater space for the study of the cruciate ligaments.

**Ligamenta Cruciata Genu** (O.T. **Crucial Ligaments**).—The cruciate ligaments are well named, because they cross each other, like the limbs of the letter X, in the interval between the two condyles of the femur. This cruciate arrangement is seen whether they are viewed from the side, by the removal of the distal part of one condyle, or from the front or the back of the joint. The anterior cruciate ligament is attached to the lateral condyle, whilst the posterior is fixed to the medial condyle of the femur.

The *anterior cruciate ligament* springs from the intermediate rough area on the proximal surface of the tibia, immediately anterior to the medial tubercle which surmounts the intercondylar eminence. From that it proceeds proximally, posteriorly, and laterally, to gain attachment to the posterior part of the medial surface of the lateral condyle of the femur (Fig. 118).

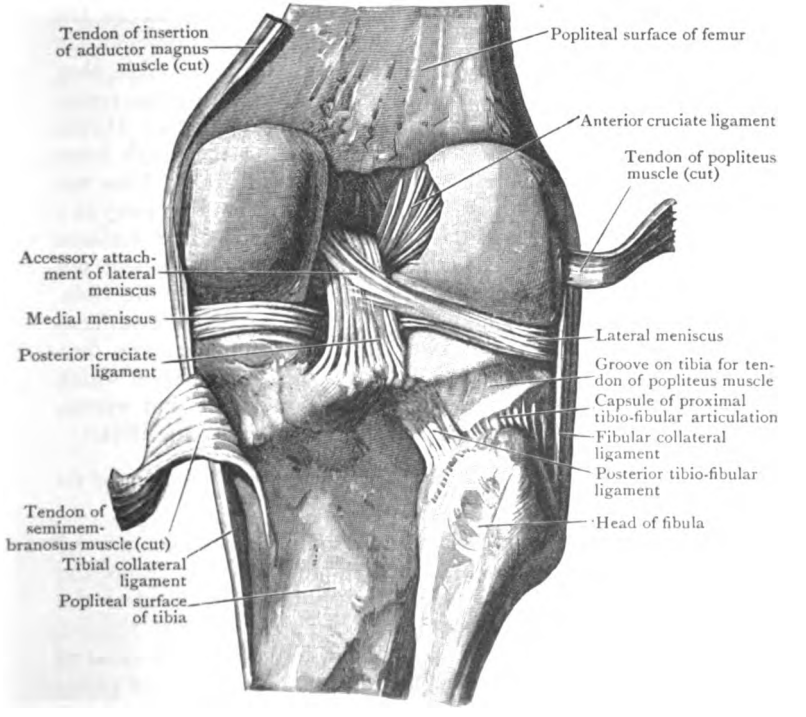
Tendon of insertion of adductor magnus muscle (cut)
Popliteal surface of femur
Anterior cruciate ligament
Tendon of popliteus muscle (cut)
Accessory attachment of lateral meniscus
Medial meniscus
Posterior cruciate ligament
Lateral meniscus
Groove on tibia for tendon of popliteus muscle
Capsule of proximal tibio-fibular articulation
Fibular collateral ligament
Posterior tibio-fibular ligament
Head of fibula
Tendon of semimembranosus muscle (cut)
Tibial collateral ligament
Popliteal surface of tibia

FIG. 118.—The Knee-joint opened from behind by the removal of the Posterior part of the Capsule.

The *posterior cruciate ligament* springs from the posterior sloping part of the intermediate rough area on the proximal surface of the tibia, posterior to the intercondyloid eminence, and posterior also to the attachments of the posterior horns of both menisci. It proceeds proximally, anteriorly, and somewhat medially, and, crossing the anterior cruciate ligament, is attached, in the anterior part of the intercondylar fossa, to the

anterior portion of the lateral surface of the medial condyle. It receives one, or sometimes two, strong slips from the posterior horn of the lateral meniscus (Fig. 118, p. 319).

The anterior cruciate ligament is tight *in extension*, and the posterior cruciate ligament is tight *in flexion* of the knee-joint.

**Menisci** (O.T. **Semilunar Cartilages**).—The menisci are two crescentic plates of fibro-cartilage which are placed on the condylar surfaces of the tibia. They deepen the surfaces upon which the condyles of the femur roll, and, being movable, they fill up the gaps which would otherwise arise during the movements of the joint. Each meniscus presents two fibrous extremities, or horns, which are attached to the rough intermediate surface on the proximal end of the tibia. They are thick towards the circumference of the joint, but thin away to a fine free concave edge in the opposite direction. Both surfaces are smooth and covered with the synovial layer. They do not cover the entire extent of the condylar surfaces of the tibia. The central parts of the latter, as well as the sloping surfaces of the tubercles of the intercondyloid eminence, are free. When the cartilages are raised from the surface upon which they rest, distinct impressions, similar in shape and extent, are seen on the subjacent encrusting cartilage of the tibia.

*Dissection.*—Carefully define the attachments of the fibrous horns of the menisci.

The lateral meniscus is usually somewhat thicker around its circumference than the medial meniscus. It forms the segment of a smaller circle, and its horns being fixed to the tibia close together, a very nearly complete circle is formed. The anterior fibrous horn is attached, immediately in front of the intercondylar eminence, to the lateral side of and partly under cover of the attachment of the anterior cruciate ligament. The posterior horn is fixed to the summit of the intercondylar eminence in the interval between the two tubercles. It also gives a strong slip to the posterior cruciate ligament. The fibular collateral ligament is not in contact with the lateral meniscus. It is separated from it by the tendon of the popliteus, and the impress of the tendon is left on the cartilage in the form of a faint smooth groove on the posterior part of its lateral border. Posteriorly, its circumference is attached to the posterior part of the capsule.

The medial meniscus is semicircular in outline, and forms the segment of a much larger circle than the lateral meniscus. Its anterior fibrous horn is fixed to the anterior part of the intermediate rough area of the tibia, in front of the attachment of the anterior cruciate ligament; its posterior horn is attached to the posterior part of the intermediate rough area of the tibia, behind the intercondylar eminence and in front of the attachment of the posterior cruciate ligament. The circumference of this cartilage is closely connected with the deep surface of the fibrous stratum of the capsule where the latter is fused with the tibial collateral ligament.

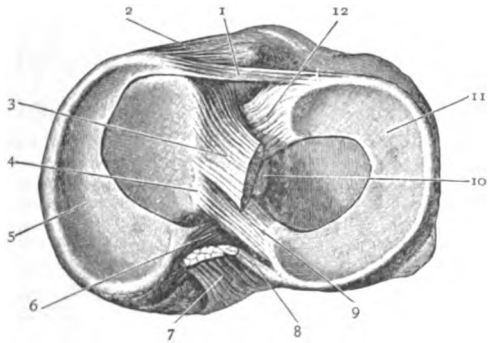


FIG. 119.—Parts attached to the proximal end of the Right Tibia.

1. Transverse ligament.
2. Anterior cornu of medial meniscus.
3. Anterior cruciate ligament.
4. Medial tubercle of intercondyloid eminence of tibia.
5. Medial meniscus.
6. Posterior cornu of medial meniscus.
7. Posterior cruciate ligament.
8. Fasciculus from lateral meniscus to posterior cruciate ligament.
9. Posterior cornu of lateral meniscus.
10. Lateral tubercle of intercondyloid eminence of tibia.
11. Lateral meniscus.
12. Anterior cornu of lateral meniscus.

**Ligamentum Transversum Genu.**—The transverse ligament is a fibrous band which stretches across from the anterior part of one meniscus to the corresponding part of the other, constituting a bond of union between them.

*Dissection.*—The condyles of the femur should now be detached by dividing the fibular collateral ligament and the cruciate ligaments close to their femoral attachments.

**Attachment of Parts to the Proximal Surface of the Tibia.**—The ligamentous structures are attached to the intermediate area on the proximal surface of the tibia in the following order

from before backwards:—(1) The anterior horn of the medial meniscus, on the medial side of the extreme anterior part of the area. (2) The anterior cruciate ligament and the anterior horn of the lateral meniscus: these are placed side by side, but the attachment of the ligament, which lies to the medial side, overlaps that of the lateral meniscus. (3) The posterior horn of the lateral meniscus, on the summit of the intercondylar eminence between its two tubercles. (4) The posterior horn of the medial meniscus, immediately behind the intercondylar eminence. (5) The posterior cruciate ligament, at the posterior part of the area.

### Articulatio Talocruralis (Ankle-joint).

The ankle-joint is a diarthrodial articulation of the ginglymus or hinge variety. The articulation takes place

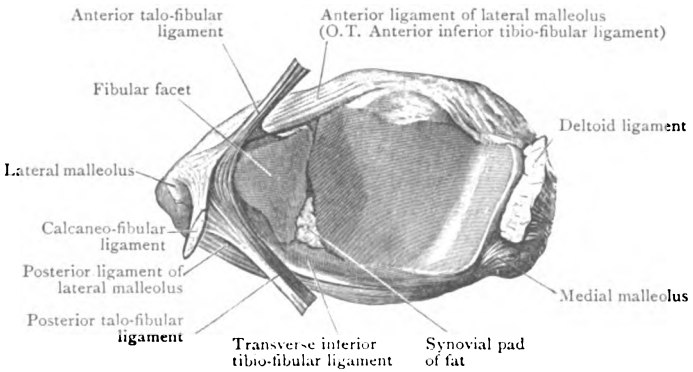


Fig. 120.—Articular Surfaces of Tibia and Fibula which articulate with the Talus.

between the bones of the leg and the talus, and the weight of the body is transferred through it to the foot. It is a joint of great strength; its stability being ensured not only by the powerful ligaments which surround it, but also by the close interlocking of the articulating surfaces.

The bones which enter into the formation of the ankle-joint are the distal ends of the tibia and fibula and the proximal, medial, and lateral surfaces of the talus. The distal

ends of the leg bones are very firmly united together by interosseous and other ligaments which give the joint a certain amount of elasticity or spring. They form a deep hollow resembling a mortice. The proximal part of the talus is received into this cavity.

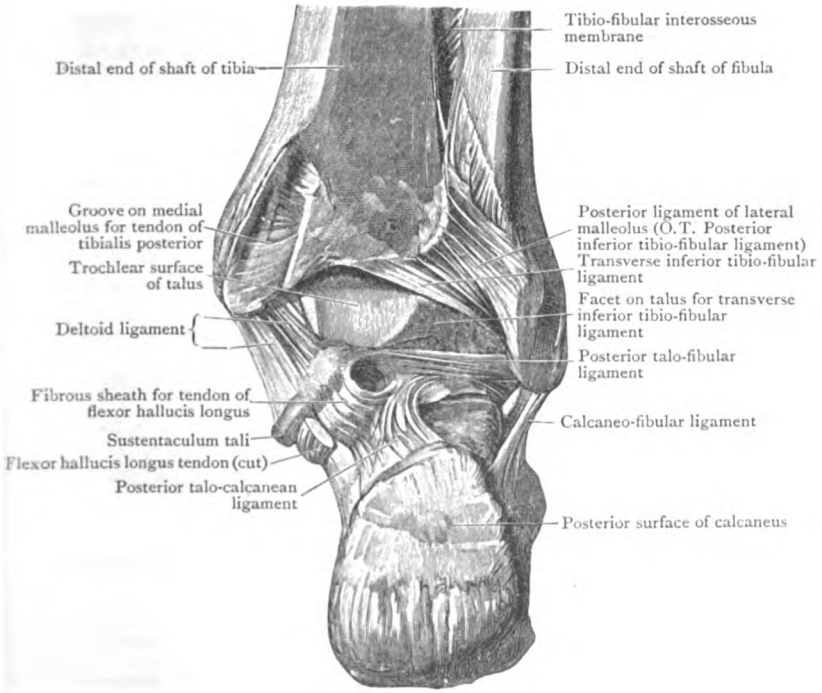
Tibio-fibular interosseous membrane
Distal end of shaft of tibia
Distal end of shaft of fibula
Groove on medial malleolus for tendon of tibialis posterior
Trochlear surface of talus
Deltoid ligament
Fibrous sheath for tendon of flexor hallucis longus
Sustentaculum tali
Flexor hallucis longus tendon (cut)
Posterior talo-calcanean ligament
Posterior ligament of lateral malleolus (O.T. Posterior inferior tibio-fibular ligament)
Transverse inferior tibio-fibular ligament
Facet on talus for transverse inferior tibio-fibular ligament
Posterior talo-fibular ligament
Calcaneo-fibular ligament
Posterior surface of calcaneus

FIG. 121.—Ankle-joint dissected from behind, with part of the Articular Capsule removed.

The ligaments of the ankle-joint are:—

1. Capsula articularis.
2. Ligamentum deltoideum.
3. Ligamentum talofibulare anterius.
4. Ligamentum talofibulare posterius.
5. Ligamentum calcaneo-fibulare.

*Dissection.*—The remains of the transverse and laciniate ligaments, together with the tendons which are in relation to the joint, should be removed and the parts of the capsule should be defined. The anterior and posterior parts of the capsule should be dissected first. They may

then be removed in order to bring the powerful lateral and medial accessory ligaments more fully into relief. At the same time the articulating surfaces will be displayed, and the play of the surfaces can be studied when the joint is flexed and extended.

**Anterior and Posterior Segments of the Capsule** (O.T. **Anterior and Posterior Ligaments**).—These are feeble bands which are placed in front of and behind the joint. They are attached to the margins of the articulating surfaces,

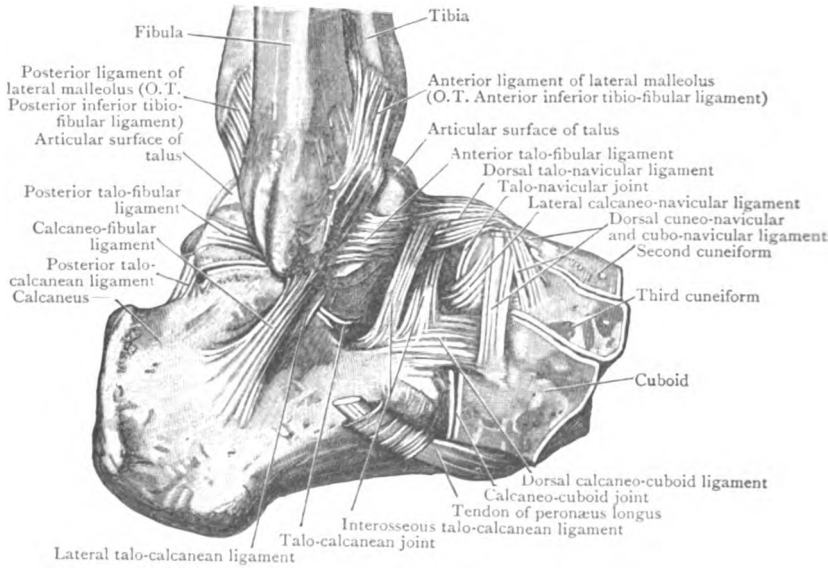


FIG. 122.—Ligaments on the Lateral Aspect of the Ankle-joint and on the Dorsum of the Tarsus.

except in front and distally, where the anterior segment is fixed to the neck of the talus (Fig. 124). The fibres of these ligaments have for the most part a transverse direction.

**The Lateral Accessory Bands** (O.T. **External Lateral Ligament**).—The lateral accessory bands of the capsule of the ankle-joint are three in number. (1) The **anterior talo-fibular ligament**; (2) the **posterior talo-fibular ligament**; (3) the **calcaneo-fibular ligament**.

The *anterior talo-fibular ligament* is the most anterior of the three. It is a flattened band which passes forwards from

the anterior border of the lateral malleolus to the part of the body of the talus immediately adjacent.

The *posterior talo-fibular ligament* is the strongest and the most posterior of the three bands. It runs almost horizontally, from the deep pit posterior to the distal articular surface

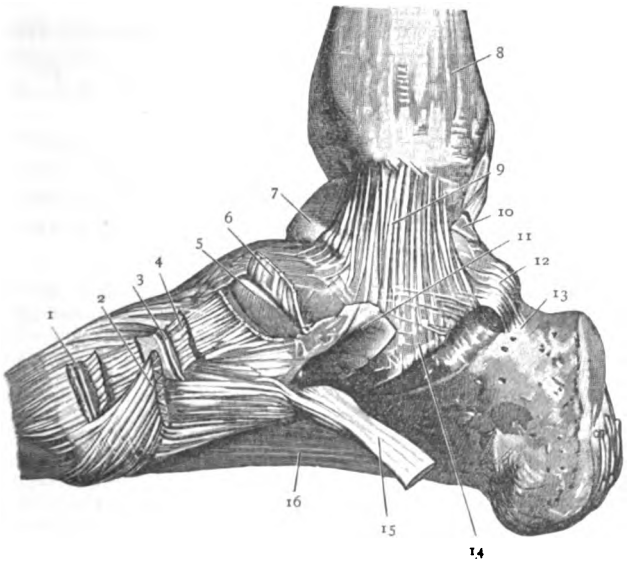


FIG. 123.—Ankle- and Tarsal-joints from the Medial Aspect.

1. First tarso-metatarsal joint (opened).
2. Tendon of tibialis anterior muscle (cut).
3. Medial cuneo-navicular joint (opened).
4. Dorsal cuneo-navicular ligament.
5. Head of talus.
6. Dorsal talo-navicular ligament.
7. Trochlear surface of talus.
8. Medial malleolus.
9. Deltoid ligament of the ankle.
10. Trochlear surface of talus.
11. Groove for tendon of tibialis posterior muscle on inferior calcaneo-navicular ligament.
12. Groove and tunnel for the tendon of flexor hallucis longus muscle.
13. Calcaneus.
14. Sustentaculum tali.
15. Tendon of tibialis posterior muscle (cut).
16. Long plantar ligament.

of the fibula to a prominent tubercle on the posterior surface of the talus.

This tubercle is termed the posterior process of the talus. It is sometimes detached and forms a supernumerary tarsal bone which may represent the os trigonum found in some mammals. In such cases it may be mistaken for a fracture.

The *calcaneo-fibular ligament* is a round, cord-like band

which passes from the distal end of the lateral malleolus to the lateral surface of the calcaneus.

**Ligamentum Deltoideum** (O.T. **Internal Lateral Lig.**).—This is an accessory band on the medial side of the joint. It is strong and of triangular form. Its apex, which is directed proximally, is attached to a shallow pit on the distal end of the medial malleolus. Its fibres diverge from the apex, and are attached in a continuous layer, from before backwards, to the navicular bone, the talus, sustentaculum tali, and posterior to that to the talus again.

**Stratum Synoviale.**—The synovial layer lines the ligaments described above, and in some cases it sends a small process proximally between the tibia and fibula. It is thrown into a transverse fold anteriorly when the joint is flexed, and into a similar fold posteriorly when the joint is extended.

**Movements.**—The movements which take place at the ankle-joint are —(1) flexion (dorsal-flexion); (2) extension (plantar-flexion); and (3) a very limited degree of lateral movement (abduction and adduction) when the foot is fully extended. The two principal movements (flexion and extension) take place around a horizontal axis, which is not transverse, but which is directed laterally and posteriorly, so that it is inclined to the median plane of the body at an angle of about 60° (Krause). This horizontal axis passes through or near the interosseous canal between the calcaneus and talus (Henle). As the articular cavity formed by the tibia and fibula, and also the part of the talus which plays in it, are broader in front than behind, it follows that the more completely the ankle-joint is flexed, the more tightly will the talus be grasped between the two malleoli. In the erect position the talus is held firmly in the bony socket, and portions of its articular surface project both in front of and behind the tibia. The line of the centre of gravity falls anterior to the ankle-joint, and as a result the bones are kept firmly locked. When, on the other hand, the ankle-joint is fully extended (as when we rise on tip-toe) the narrower posterior part of the talus is brought into the socket, and thus a limited amount of lateral movement is allowed. In *flexion* the calcaneo-fibular and posterior talo-fibular bands, the greater part of the deltoid ligament, and the posterior part of the capsule are put on the stretch. In *extension* the anterior talo-fibular ligament, the anterior fibres of the deltoid ligament, and the anterior part of the capsule are rendered tense.

The **Muscles** principally concerned in producing dorsi-flexion of the foot at the ankle-joint are the tibialis anterior and the peronæus tertius; those which operate as plantar-flexors are the superficial muscles of the calf, the tibialis posterior, and the peronæus longus and brevis.

### Tibio-fibular Joints.

The fibula articulates with the tibia by both its proximal and distal extremity. The proximal of the two, the *articulatio tibiofibularis*, is a diarthrodial joint, possessing a cavity and a

capsule with accessory thickenings. The distal joint is a syndesmosis, the *syndesmosis tibiofibularis*, but in some cases a prolongation of the cavity of the ankle-joint projects between the distal ends of the tibia and fibula. The interosseous membrane which occupies the interval between the bodies of the bones may be regarded as a ligament common to both joints.

*Dissection.*—Preparatory to the examination of the tibio-fibular joints the foot must be removed by dividing the ligaments on the medial and lateral aspects of the ankle-joint. The muscles also must be detached from both aspects of the interosseous membrane and the bones of the leg. The ligaments may now be defined.

**Membrana Interossea Cruris.**—The interosseous membrane is a strong membrane which stretches across the interval between the two bones of the leg, and greatly extends the surface for the origin of muscles. It is attached on the one hand to the interosseous border of the tibia, and on the other to the interosseous border of the fibula. It is composed of strong oblique fibres, which take a direction distally and laterally from the tibia to the fibula. An oval opening in its proximal part, immediately distal to the lateral condyle of the tibia, is present for the passage of the anterior tibial vessels, whilst a small aperture, a short distance proximal to the ankle-joint, marks the point where the membrane is pierced by the perforating branch of the peroneal artery.

**Articulatio Tibiofibularis** (O.T. **Superior Tibio-fibular Joint**).—At the tibio-fibular joint the bones are held in apposition by a capsule which is strengthened anteriorly and posteriorly. The fibres of the strengthening bands pass, distally and laterally, from the lateral condyle of the tibia to the head of the fibula. The posterior band is the weaker of the two, and the tendon of the popliteus with its synovial investment rests upon its proximal part. The investment is a prolongation from the synovial layer of the knee-joint, and in some cases it will be found to be directly continuous with the synovial layer of the capsule of the tibio-fibular joint.

The relation of the tendon of the biceps femoris to this joint must not be lost sight of. Attached for the most part to the head of the fibula, its fibres stretch over the front of the joint. Some of its tendinous fibres also obtain insertion into the lateral condyle of the tibia. Firm support is in this way contributed to the tibio-fibular joint.

**Syndesmosis Tibiofibularis** (O.T. **Inferior Tibio-fibular Joint**) (Figs. 120 and 121).—This articulation is constructed upon a stronger plan, because the strength of the ankle-joint very largely depends upon its security. *In some cases* a very narrow strip of the distal part of each of the opposing surfaces of the bones is articular and coated with cartilage, ***in other cases articular cartilage is entirely absent.*** The surfaces of the proximal part of the syndesmosis are always rough, and are held together by an exceedingly strong *interosseous ligament.*

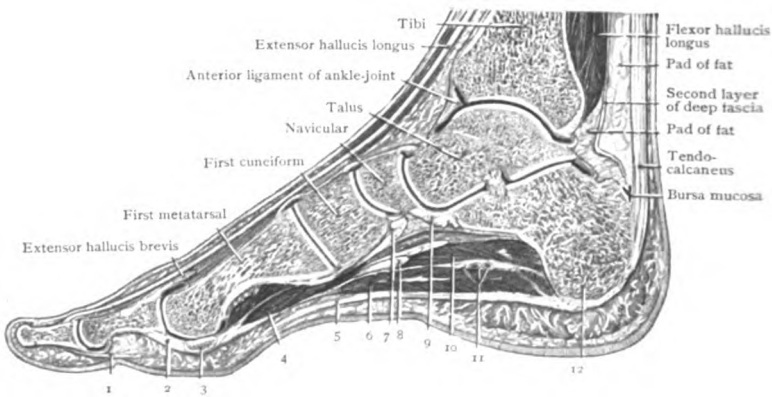


FIG. 124.—Oblique sagittal section through the Foot, along a plane extending from the centre of the heel behind to the centre of the great toe in front.

1. Flexor hallucis longus.
2. Plantar accessory metatarsophalangeal ligament.
3. Sesamoid bone.
4. Flexor hallucis brevis.
5. Plantar aponeurosis.
6. Flexor digitorum brevis.
7. Tibialis posterior tendon.
8. Flexor digitorum longus tendon.
9. Plantar calcaneo-navicular ligament.
10. Quadratus plantæ.
11. Lateral plantar vessels and nerve.
12. Calcaneus.

In addition to this interosseous ligament there are :—

1. Lig. malleoli lateralis anterius (O.T. Ant. inf. tibio-fibular ligament).
2. Lig. malleoli lateralis posterius (O.T. Post. inf. tibio-fibular ligament).
3. Inferior transverse ligament.

The *anterior* and *posterior ligaments* are flat strong bands which pass from the tibia to the fibula, in an oblique direction, laterally and distally.

The distal part of the posterior ligament forms a strong narrow band of yellowish fibres, which takes a transverse course on the back of the joint and is firmly attached to both tibia and fibula, filling up the interval between them. It constitutes a part of the tibio-fibular socket for the talus at the ankle-joint (Figs. 120 and 121); and on the proximal aspect of the articular surface of the talus, the area over which it plays is usually easily distinguished. This portion of the posterior ligament is called the *inferior transverse ligament.*

*Dissection.*—To see the interosseous ligament of the tibio-fibular syndesmosis the bones of the leg may be sawn through about two inches from the distal end of the tibia, and then divided with the saw proximo-distally in a vertical-transverse, or frontal direction. This cut should be planned so as to pass through the tibio-fibular syndesmosis. The short strong fibres of the interosseous ligament will then be seen, and also the short narrow articular interval between the distal portions of the opposing surfaces of the bones when that interval is present. If a cavity is present in the distal part of the joint the synovial layer of the capsule of the ankle-joint is prolonged proximally over the inner surface of those parts of the ligaments of the tibio-fibular syndesmosis which help to form the boundaries of the cavity.

## Articulations of the Foot.

The articulations of the foot are very numerous. They consist of:—

1. Articulationes intertarseæ, tarsometatarseæ, and intermetatarseæ.
2. Articulationes metatarso-phalangeæ.
3. Articulationes digitorum pedis.

The bones which enter into these articulations are the seven tarsal bones, the metatarsal bones, and the phalanges. The tarsal and metatarsal bones are bound together by interosseous, plantar, and dorsal ligaments, and are disposed in the form of two arches, viz., a longitudinal and a transverse. The integrity of these arches is maintained: (1) partly by the forms of the bones; (2) partly by the tension of the ligaments; (3) partly by supporting tendons; and (4) partly by the tension of the plantar aponeurosis.

The longitudinal arch presents a greater height and a wider span along the medial than along the lateral side of the foot. The talus is placed on the summit of this arch and forms its keystone. The posterior pillar of the longitudinal plantar arch is short and solid, being formed by the calcaneus alone; the anterior pillar, much longer, is composed of several bones,

viz., the navicular, the cuboid, the three cuneiforms, and the metatarsus. Further, the anterior pillar may be considered as being formed of a medial column composed of the navicular, the three cuneiform, and the medial three metatarsal bones, and a lateral column composed of the cuboid and the lateral two metatarsal bones. The weight of the body is transmitted to the summit of the arch through the talus, and the most important ligaments concerned in the prevention of excessive flattening of the arch are the *plantar calcaneo-navicular*, the *long plantar ligament*, the *plantar calcaneo-cuboid ligament*, and the various slips of the *tendon of the tibialis posterior*, as they pass to find attachment to the different tarsal and metatarsal bones. The *plantar aponeurosis* also acts powerfully in this way: connecting as it does the extremities of the two pillars of the plantar arch, it operates, as the late Sir George Humphry once pointed out, in the same manner as the "tie-beam" of a roof. The transverse arch of the foot is seen to best advantage across the line of the tarso-metatarsal articulations.

*Dissection.*—The muscles and tendons which have hitherto been only partially detached from the bones of the foot should now be completely removed and the ligaments defined.

**Taloid Articulations.**—The talus articulates by means of the large posterior facet on the plantar surface of its body with the corresponding posterior facet on the dorsal surface of the calcaneus. Its head, on the other hand, is received into a large socket which is formed for it by the sustentaculum tali of the calcaneus, the navicular, and two ligaments which pass between the calcaneus and the navicular—viz., one below, the plantar calcaneo-navicular, and another on the lateral side, the calcaneo-navicular part of the bifurcate ligament. These two taloid articulations are quite distinct.

The ligaments which hold the talus in its place are five in number. Four are attached to the calcaneus and one to the navicular bone. They are :—

1. Lig. talo-calcaneum interosseum.
2. Lig. talo-calcaneum laterale.
3. Lig. talo-calcaneum mediale.
4. Lig. talo-calcaneum posterius.
5. Lig. talo-naviculare [dorsale].

The *interosseous talo-calcanean ligament* is by far the most powerful. It occupies the tarsal canal, and consists of strong

fibres attached distally to the groove between the articular facets on the dorsal surface of the calcaneus, and proximally to the corresponding groove on the plantar surface of the talus.

The *lateral ligament* is a short band of fibres which proceeds from the lateral surface of the talus to the lateral surface of the calcaneus. It is parallel with the calcaneo-fibular ligament of the ankle-joint, but it is placed on a deeper plane, and lies somewhat more anteriorly.

The *medial talo-calcanean ligament* passes distally and forwards, from the medial border of the groove on the talus for the flexor hallucis longus to the sustentaculum tali.

The *posterior talo-calcanean ligament* passes from the posterior border of the talus to the calcaneus. It closes the posterior talo-calcanean articulation behind.

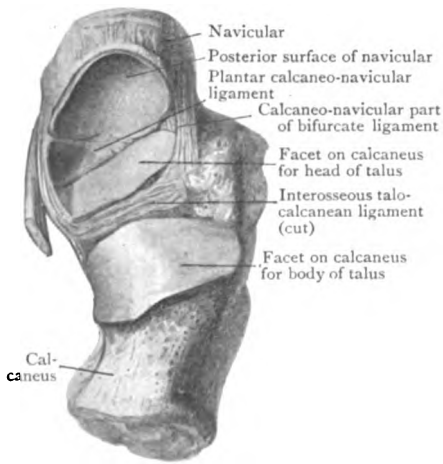
Navicular
Posterior surface of navicular
Plantar calcaneo-navicular ligament
Calcaneo-navicular part of bifurcate ligament
Facet on calcaneus for head of talus
Interosseous talo-calcanean ligament (cut)
Facet on calcaneus for body of talus
Cal-caneus

FIG. 125.—Talus removed so as to show the socket for its head.

The *dorsal talo-navicular ligament* extends, on the dorsum of the foot, from the head of the talus to the navicular bone. It is thin and membranous.

The medial and lateral parts of the capsule of the ankle-joint also help to keep the talus in its place.

*Dissection.*—The talus should now be removed by dividing the various ligaments which hold it in place. By this proceeding the different parts which form the socket for the head of the talus will be brought into view; and the posterior talo-calcanean articulation will be seen to be completely cut off from the anterior articulation by the interosseous talo-calcanean ligament. The great strength of this ligament can now be appreciated, and the facets on the head of the talus studied. These are:—(1) a convex surface which looks forwards and articulates with the navicular; (2) an elongated facet on its plantar aspect (sometimes divided into two), which rests upon the sustentaculum tali; and (3) between these, a triangular facet which corresponds with the dorsal surface of the plantar calcaneo-navicular ligament. In the recent state (and indeed

usually also in the macerated condition of the bone) these three facets are very distinctly mapped off from each other by intervening ridges.

**Calcaneo-navicular Ligaments.**—Although the calcaneus does not directly articulate with the navicular bone, it is

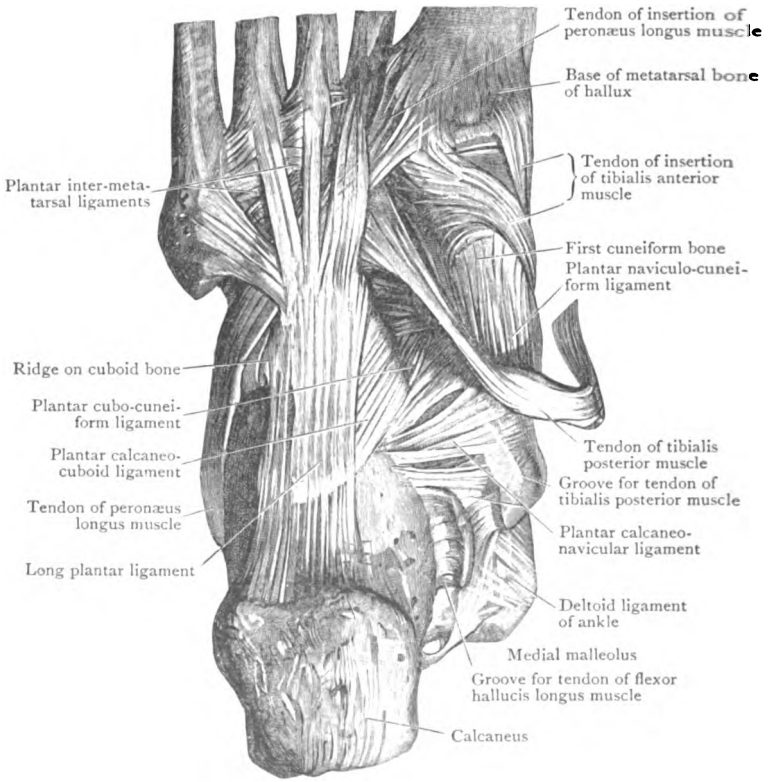
Tendon of insertion of peronæus longus muscle
Base of metatarsal bone of hallux
Tendon of insertion of tibialis anterior muscle
Plantar inter-meta-tarsal ligaments
First cuneiform bone
Plantar naviculo-cunei-form ligament
Ridge on cuboid bone
Plantar cubo-cunei-form ligament
Plantar calcaneo-cuboid ligament
Tendon of tibialis posterior muscle
Groove for tendon of tibialis posterior muscle
Tendon of peronæus longus muscle
Plantar calcaneo-navicular ligament
Long plantar ligament
Deltoid ligament of ankle
Medial malleolus
Groove for tendon of flexor hallucis longus muscle
Calcaneus

FIG. 126.—Plantar Aspect of Tarsal and Tarso-metatarsal Joints.

connected with it by two powerful ligaments, viz., a plantar and the calcaneo-navicular part of the bifurcate ligament.

The *plantar calcaneo-navicular ligament* (O.T. ***inferior calcaneo-scaphoid ligament***) is brought into view by the removal of the talus. It fills up the angular gap between the sustentaculum tali and the navicular bone, and enters into the formation of the socket for the head of the talus

(Fig. 126). Its dorsal surface is smooth and covered with a synovial layer; its plantar surface is supported by the tendon of the tibialis posterior. This ligament has an important part to play in maintaining the integrity of the longitudinal arch of the foot. Posteriorly it is attached to the anterior border of the sustentaculum tali, whilst anteriorly it is fixed to the plantar surface of the navicular bone.

The *calcaneo-navicular part of the bifurcate ligament* (O.T. *external calcaneo-scaphoid ligament*) also forms a small part of the socket for the head of the talus. It is placed deeply in the anterior part of the depression between the calcaneus and the head of the talus, and is the medial part of the V-shaped *ligamentum bifurcatum*, which springs from the anterior part of the proximal surface of the calcaneus and immediately divides into a medial or navicular part and a lateral or cuboid portion. The calcaneo-navicular part is continuous below and medially with the plantar calcaneo-navicular ligament, and dorsally with the talo-navicular ligament.

**Calcaneo-cuboid Articulation.**—In this joint the concavo-convex surface on the anterior aspect of the calcaneus articulates with the corresponding surface on the posterior aspect of the os cuboideum. It is a distinct joint, that is, its cavity does not communicate with the cavities of neighbouring joints. The *ligaments* which bind the two bones together are:—

1. Capsula articularis.
2. Ligamentum calcaneo-cuboideum plantare.
3. Ligamentum plantare longum.

The *capsule* completely surrounds the joint and its dorsal and medial parts, which are somewhat thickened, are sometimes called the dorsal and medial ligaments of the joint. The medial ligament is the calcaneo-cuboid part of the lig. bifurcatum mentioned above.

The *long plantar ligament* springs from the plantar surface of the calcaneus, immediately anterior to the tuber calcanei. It extends forwards to the plantar surface of the cuboid bone where it broadens out and is for the most part attached to the tuberosity of that bone. Numerous strong fibres, however, are prolonged forwards, across the tendon of the peronæus longus, to gain attachment to the bases of

the second, third, and fourth metatarsal bones. The long plantar ligament, therefore, extends over the greater part of the plantar aspect of the lateral portion of the tarsus, and is the longest of the tarsal ligaments. Further, it forms the greater part of the sheath of the tendon of the peronæus longus.

*The plantar calcaneo-cuboid ligament* (O.T. *short plantar ligament*) is placed under cover of the long plantar ligament. Slip the knife between them and carry the cutting edge backwards so as to detach the long plantar from the plantar surface of the calcaneus. When the detached band is thrown forwards the plantar calcaneo-cuboid ligament comes into view, and little dissection is required to make its connections apparent. It is composed of short, strong fibres, not more than an inch in length. They spring from the small tubercle on the anterior part of the plantar surface of the calcaneus, and are attached, anteriorly, to the plantar surface of the cuboid, posterior to its tuberosity. The ligament is broader than the long plantar ligament and is apparent along the medial border of the latter before it is reflected.

In the maintenance of the longitudinal arch of the foot, the long plantar ligament and the plantar calcaneo-cuboid ligament have an importance which is surpassed only by that of the plantar calcaneo-navicular ligament.

The joint between the talus and the navicular and that between the calcaneus and the cuboid are frequently referred to together as the *transverse tarsal joint*. It is here that some parts of the movements of eversion and inversion of the foot take place. It should be noted that all the ligaments which connect together the anterior and the posterior segments of the tarsus at this joint, except one, are attached posteriorly to the calcaneus. They are :—

Plantar calcaneo-navicular,
Bifurcate (navicular part),
Long plantar,
Plantar calcaneo-cuboid,
Calcaneo-cuboid capsule,
} Attached to the calcaneus.

Dorsal talo-navicular,
} Attached to the talus.

**Inter-cuneiform Articulations.** — The three cuneiform bones are held together so firmly that very little individual movement is permitted. The chief uniting structures are *two* strong *interosseous ligaments* which pass between the non-articular portions of their opposed surfaces. These can be seen only when the bones are separated from each other. *Dorsal inter-cuneiform ligaments* also are present. These are short, flat, transversely-placed bands.

**Cuneo-navicular Articulation.** — The three cuneiform bones articulate with the anterior surface of the navicular. They are held in position by *dorsal ligaments*, which pass from the dorsal surface of the navicular to the dorsal surface of each of the cuneiform bones, and by *plantar ligaments*, which are similarly disposed. The strength of the plantar ligaments is greater than that of the dorsal ligaments, and they are formed very largely by slips from the tendon of the tibialis posterior.

The dissector may now divide freely all the dorsal and the most medial of the plantar cuneo-navicular ligaments. The navicular bone can then be drawn backwards so as to expose the interior of the joint. The knife may also be carried round the lateral side of the lateral calcaneo-navicular ligament. A much better view of this ligament is thus obtained, although this dissection entails the division of the dorsal cubo-navicular ligament.

The convex anterior articular surface of the navicular fits into a transversely concave socket, which is formed for it by the posterior surfaces of the three cuneiform bones, and often by a small facet on the medial surface of the cuboid as well. The articular surface of the navicular is divided by prominent ridges into areas or facets corresponding with the different parts of the socket in which it lies. The *synovial stratum*, which lines this joint, is prolonged forwards into the intercuneiform joints.

**Cubo-navicular and Cubo-cuneiform Articulations.**—It has been noted that the anterior pillar of the longitudinal arch of the foot consists of a lateral and a medial column. The tarsal portions of these are connected together by the cubo-navicular and the cubo-cuneiform articulations.

It is only occasionally that the navicular touches and articulates directly with the medial surface of the cuboid. When it does so, the facet on the cuboid lies in series with the articular surfaces on the posterior ends of the cuneiform bones, and forms with them the socket for the anterior surface of the navicular. The *ligaments* which bind the navicular to the cuboid are disposed transversely, and consist of—(1) a series of short strong *interosseous* fibres which bind the opposed surfaces together; (2) a dorsal band; and (3) a plantar band.

The dorsal band has previously been divided in exposing the interior of the cuneo-navicular joint and in defining the lateral calcaneo-navicular ligament, but the interosseous and plantar ligaments may be readily displayed.

The cuboid, by an oval facet on its medial surface, articulates with the third cuneiform bone, forming thereby the *cubo-cuneiform joint.* The two bones are bound together by *interosseous*, *dorsal*, and *plantar ligaments.* By dividing the dorsal ligament and insinuating the knife between the two bones the interosseous ligament may be detected. It is the strongest of the three ligaments.

The *synovial layer* which lines the cuneo-navicular articulation is prolonged into the cubo-cuneiform joint and also into the naviculo-cuboid joint, when that exists.

**Tarso-metatarsal Articulations.**—The bases of the five metatarsal bones articulate with the three cuneiform bones and the cuboid bone, and are very firmly attached to them by dorsal, plantar, and interosseous ligaments.

The *dorsal ligaments* are flat, distinct bands which can readily be defined by the careful dissector. *One* such ligament passes to the base of the first metatarsal from the first cuneiform; *three*, one from each of the cuneiform bones, proceed to the base of the second metatarsal; *one* extends from the third cuneiform to the base of the third metatarsal; *two*, of which one proceeds from the third cuneiform and the other from the cuboid, go to the base of the fourth metatarsal; and *one* passes from the cuboid to the base of the fifth metatarsal.

The *plantar ligaments* are not so regularly disposed. Those in connection with the first and second metatarsal bones are very strong. Some of the bands have an oblique direction, and those which go to the bases of the second, third, and fourth metatarsal bones are more or less connected with the sheath of the tendon of the peronæus longus, and therefore with the long plantar ligament.

To bring the *interosseous ligaments* into view, divide freely the dorsal ligaments, and then forcibly bend the metatarsus plantarwards upon the tarsus. The interosseous ligaments will resist this proceeding, and on looking into the joints the dissector will see them stretched and tense. If the force is continued they will rupture. The interosseous ligaments are three in number, viz., a medial, an intermediate, and a lateral.

The *medial interosseous ligament* is an exceedingly strong band, which passes laterally from the anterior part of the lateral surface of the first cuneiform bone to the adjacent surface of the base of the second metatarsal bone. The

*intermediate interosseous ligament* is small. It passes between the anterior part of the medial surface of the third cuneiform and the adjacent surface of the base of the second metatarsal. The *lateral interosseous ligament* passes from the lateral surface of the third cuneiform bone to the medial side of the base of the fourth metatarsal. One interosseous ligament, therefore, passes from the first cuneiform bone and two from the third cuneiform; and of these, two are attached to the base of the second, and the third to the base of the fourth metatarsal bone.

**Tarso-metatarsal Articular Surfaces.**—The manner in which the metatarsus is implanted upon the tarsus should now be examined. The *first metatarsal* rests against the first cuneiform, and this joint possesses a separate synovial cavity. The *second metatarsal* rests against the second cuneiform, but its base is grasped by the projecting anterior ends of the first and third cuneiform bones, with both of which it articulates, and with both of which it is connected by interosseous ligaments. It is not surprising, therefore, that this metatarsal should possess so little power of independent movement, and present a difficulty to the surgeon when he is called upon to amputate the anterior part of the foot through the tarso-metatarsal articulation. The *third metatarsal* rests against the third cuneiform. The *synovial layer* which lines the joints between the tarsus and the second and third metatarsal bones is continuous with that which is present between the first and second cuneiform bones, and through this with the synovial layer of the cuno-navicular articulation. The bases of the *fourth* and *fifth metatarsal bones* are supported by the cuboid, but that of the fourth, by its medial margin, articulates also with the lateral cuneiform. The joint formed between the lateral two metatarsal bones and the tarsus has a capsule and a cavity separate from that of the adjacent joints.

**Intermetatarsal Joints.**—The bases of the metatarsal bones, with the exception of the first, articulate with each other, and are very firmly bound together.

The ligaments which connect the bases of the lateral four metatarsal bones are *dorsal*, *plantar*, and *interosseous*. To bring the interosseous ligaments into view it is necessary to divide the dorsal ligaments, and then forcibly separate the bases of the bones from each other. They are strong bands

which pass between the non-articular portions of the basal parts of the bones, and they constitute the chief bonds of union.

In addition to these basal ligaments, the strong *transverse metatarsal ligament* of the heads of the metatarsal bones unites the distal extremities of the bones together. This ligament has been previously described (p. 305).

**Joint Cavities of the Foot.**—There are six separate joint cavities in connection with the tarsal, tarso-metatarsal, and intermetatarsal articulations, viz.—(1) The cavity between the posterior facets of the talus and calcaneus. (2) The calcaneo-cuboid joint cavity. (3) The cavity of the joint formed by the head of the talus, the navicular, the sustentaculum tali, the calcaneo-navicular ligament and the navicular part of the bifurcate ligaments. (4) A cavity which extends between the naviculo-cuneiform articulation, and is prolonged forwards between the cuneiforms, and also between the cuboid and third cuneiform bones; this cavity extends beyond the tarsus, and is continuous with the cavity between the second and third metatarsal bones and the tarsus, as well as with the cavities of the joints between the bases of the second, third, and fourth metatarsal bones.[1] (5) A separate cavity lies between the first metatarsal and the first cuneiform. (6) A distinct cavity for the articulations between the cuboid and the two lateral metatarsal bones; this is prolonged distally into the joint between the bases of these two metatarsals.

**Metatarso-phalangeal and Digital Joints.**—These joints are constructed upon a plan almost identical with that of the corresponding joints of the upper extremity. For the detailed description the student is therefore referred to p. 163. In the metatarso-phalangeal joint of the great toe the thick *plantar accessory ligament* or *fibrous plate* holds two large sesamoid bones, which glide upon grooved surfaces on the head of the metatarsal bone.

**Movements.**—The movements which take place in the tarso-metatarsal, intermetatarsal, and in the majority of the tarsal joints, are of a gliding character. In the joints between the talus and navicular, and also between the calcaneus and the cuboid, movements of a wider range are

[1] The lateral interosseous tarso-metatarsal ligament, which passes from the third cuneiform bone (frequently from the cuboid bone) to the base of the fourth metatarsal bone, separates the cavity between the fourth and fifth metatarsal bones and the cuboid from the general tarsal articular cavity.

possible. It is here chiefly that the movements of *inversion* and *eversion* of the foot take place.

The first and the fifth metatarsal bones enjoy a considerable degree of mobility. The second metatarsal is so tightly grasped by the first and third cuneiform bones, and so firmly bound to the tarsus by its basal ligaments, that only a slight degree of movement is possible.

At the metatarso-phalangeal joints, flexion, extension, abduction, and adduction are allowed; whilst the digital joints permit only of flexion and extension.

In the erect posture the parts of the foot which are chiefly concerned in transmitting the weight of the body to the ground are the heel, the head of the first metatarsal bone, and the shaft of the fifth metatarsal bone. Rather more than the middle third of the medial border of the foot is raised above the ground. The lateral border of the foot is more or less in contact with the ground in its entire extent, whilst the tips of the toes rest lightly on the ground. In walking—(1) the heel is brought down; (2) the sole and toes follow; (3) the heel is raised, and the weight of the body is transferred to the heads of the metatarsal bones and the toes. In the second and third parts of this operation the arches of the foot are flattened to a certain extent, but more especially in the third part of the process is the transverse arch spread out. Great elasticity is thus given to the step.

The **muscles** which are chiefly concerned in producing *eversion* of the foot are the three peroneal muscles; those which operate as *invertors* of the foot are the tibialis anterior and the tibialis posterior.

The *extensors of the toes* are the extensor hallucis longus, the extensor digitorum brevis, and the extensor digitorum longus. The lumbrical muscles, and the interosseous muscles, through their insertions into the extensor tendons of the four outer toes, operate as extensors of the second and third phalanges.

The *flexors of the proximal phalanges* are the lumbricales, interossei, flexor hallucis brevis, and flexor digiti quinti brevis. The *flexor of the second phalanges* is the flexor digitorum brevis; whilst the *flexors of the distal phalanges* are the flexor digitorum longus, the quadratus plantæ and the flexor hallucis longus.

*Abduction* and *adduction* of the toes at the metatarso-phalangeal joints are produced by the interosseous muscles, the abductor hallucis, the oblique head of the adductor hallucis, the transverse head of the adductor hallucis, and the abductor digiti quinti. The movements of abduction and adduction take place with reference to a line drawn through the second toe.

For radiographic appearances of the joints of the lower extremity, see Plates at the end of the volume.

# ABDOMEN.

WHEN the body is brought into the dissecting-room, it is first placed in the lithotomy position (Fig. 127), and is retained in that posture for three days, during which time the dissector of the abdomen must dissect the *perineum*.

## MALE PERINEUM.

**Boundaries of the Perineum.**—The perineum may be said to correspond to the inferior aperture or outlet of the pelvis. It is necessary, then, that the student should renew his acquaintance with that part of the skeleton before he begins the dissection. Let him obtain a pelvis with the ligaments *in situ*. He will note that he has to deal with a diamond-shaped space, and that it has the following boundaries: *anteriorly*, the symphysis pubis and the arcuate pubic ligament (O.T. sub-pubic); *posteriorly*, the coccyx; and *on each side*, from before backwards, the rami of the pubis and ischium, the tuberosity of the ischium, and the ligamentum sacro-tuberosum (O.T. great sciatic). If he now turns his attention to the subject before him he can identify these limits. The sacro-tuberous ligament, however, is somewhat obscured, because it is covered by the glutæus maximus muscle, but it can be felt if deep pressure is made in a line between the ischial tuberosity and the coccyx (Figs. 127 and 128).

In the undissected body the superficial area of the perineum is very limited; indeed, when the limbs are extended and approximated (as is the case when one stands erect), it consists merely of a narrow groove running forwards between the thighs, from the coccyx towards the pubis. In this groove are placed the anus or orifice of the anal canal and the roots of the scrotum and penis, whilst in the middle line a cutaneous ridge—the *median raphe*—may be seen. This raphe can be traced from the anus forwards over the scrotum and along the inferior surface of the penis.

**Subdivision of the Space.**—The perineal space has, therefore, a diamond-shaped form, and it is customary to subdivide

it arbitrarily into two portions by drawing an imaginary transverse line between the anterior parts of the ischial tuberosities, immediately in front of the anus. Two triangles are thus mapped out. The anterior of these may be appropriately called the *urogenital triangle*, because the most important objects which it contains are the urethra and the root of the penis; the posterior may be distinguished as the *anal triangle*, because it contains the anal canal.

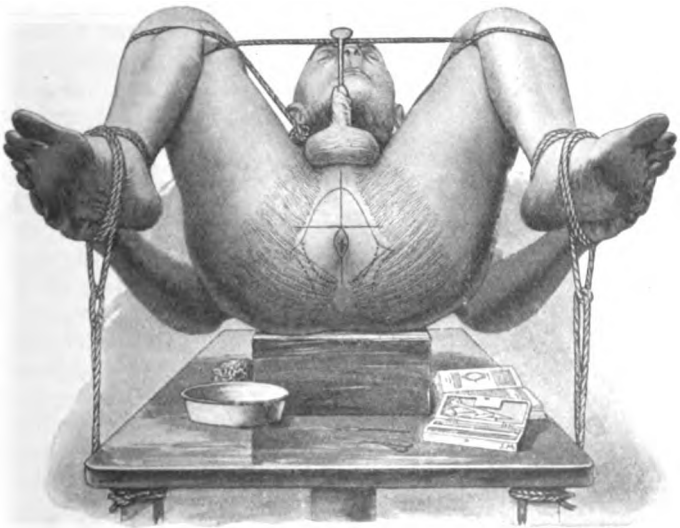

FIG. 127.—Body in Perineal Posture.

**Preparation of Part for Dissection.**—To prepare the part for dissection, a staff should first be introduced into the bladder. The dissector must stand upon the *left* side of the subject. Having smeared the instrument with oil, hold it lightly in the right hand and guide it gently along the upper and right wall of the urethra. When the point of the instrument reaches the inferior fascia of the urogenital diaphragm (O.T. triangular ligament),—a strong fibrous structure which is stretched tightly across the pubic arch—depress the handle, but use no force. Should any difficulty be experienced, introduce the forefinger of the left hand into the rectum to guide the point of the instrument along the membranous and prostatic portions of the urethra. The most dependent part of the scrotum should now be stitched to the prepuce of the penis, and dragging both penis and scrotum forwards upon the staff, they should be fixed by means of the twine to its handle. Lastly, fasten the handle of the staff to the cord which passes behind the flexed knee-joints of the subject.

The anal canal should then be *slightly* distended with tow, and the orifice of the anus stitched up.

**Reflection of Skin.**—Two incisions are required (Fig. 127):—(1) a transverse incision along the line which separates the *anal* from the *urogenital* triangle—*i.e.* in front of the ischial tuberosities; (2) an incision at right angles to the first, in the line of the median raphe. This incision should begin well forwards on the scrotum and be continued back a little beyond the point of the coccyx. The knife should be carried round the anus so as to encircle it.

The four triangular flaps which are marked out should now be reflected. Some difficulty will be experienced in raising the skin. This is due to the presence of a number of fasciculi of involuntary muscle which radiate outwards from the anus. The term *corrugator cutis ani* is applied to this muscle. The *superficial fascia* and the *external sphincter muscle* are now exposed.

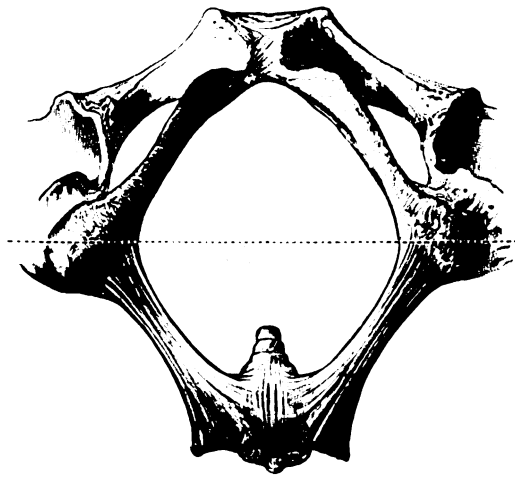

FIG. 128.—Inferior Aperture of Male Pelvis.

**Panniculus Adiposus (Superficial Fascia).**—The student should examine the superficial fascia as it is spread over the entire extent of the perineal space. It shows great differences in character and texture in different positions. At the side of the anal canal it is remarkable for the large quantity of fat it holds in its meshes. This fat is soft and lobulated, and passes upwards upon each side of the anal canal in the form of a pliable and elastic pad. Over the ischial tuberosities the superficial fascia undergoes a striking alteration. There it becomes tough and stringy; dense fibrous septa separate the lobules of fat from each other and connect the skin with the subjacent bone.

Make a deep incision into it with the knife, and a bursa will be displayed intervening between the fascia and bone. The bursal sac is frequently intersected by strong fibrous bands or cords. The superficial fascia of the ischial region acts as a cushion on which the tuberosity of the ischium rests when the body is in the sitting posture.

But, again, if the superficial fascia is followed anteriorly over the urogenital triangle, another change in its character becomes manifest. The farther forwards it is traced the scarcer becomes the fat which it contains in its meshes. In the scrotum the fat entirely disappears and gives place to a thin layer of involuntary muscular fibres. Those fibres constitute the *dartos muscle*, and are recognised by their ruddy colour. The rugosity of the scrotal integument is caused by their contraction.

Over the urogenital triangle the superficial fascia can be shown to consist of two very definite layers. The *superficial layer* is fatty and is not confined to that region. In fact, it is simply a portion of the general fatty covering of the body. Posteriorly, it is continuous with the plugs of fat which fill up the ischio-rectal fossæ; on each side, it leaves the perineum and becomes continuous with the fatty tissue on the medial aspects of the thighs. The *deep layer* is of an altogether different nature. It is a dense membranaceous stratum spread over the urogenital triangle, and it is devoid of fat. It is called the *fascia of Colles*. This sheet of fascia has very definite attachments around the limits of the urogenital triangle. Thus, on each side, it is fixed to the anterior lips of the rami of the pubis and ischium, whilst, posteriorly, it is tucked round the two superficial transverse perineal muscles and blends with the base of the fascia of the urogenital diaphragm (O.T. triangular ligament). A pouch is thus formed, bounded *superficially* by the fascia of Colles, *deeply* by the urogenital diaphragm, *laterally* by the attachment of both to the sides of the pubic arch, whilst, *posteriorly*, it is closed by the union of the fascia of Colles with the base of the fascia of the urogenital diaphragm (Fig. 129, p. 344). Within the pouch certain important parts are placed—viz., the superficial perineal muscles, the perineal vessels and the scrotal nerves, the long perineal branch of the posterior cutaneous nerve of the thigh, the bulb of the urethra, the crura of the penis, and the termination of the pudendal artery. The pouch is partially divided

into two lateral parts by a median septum, which dips deeply from the superficial fascia. This septum is very perfect

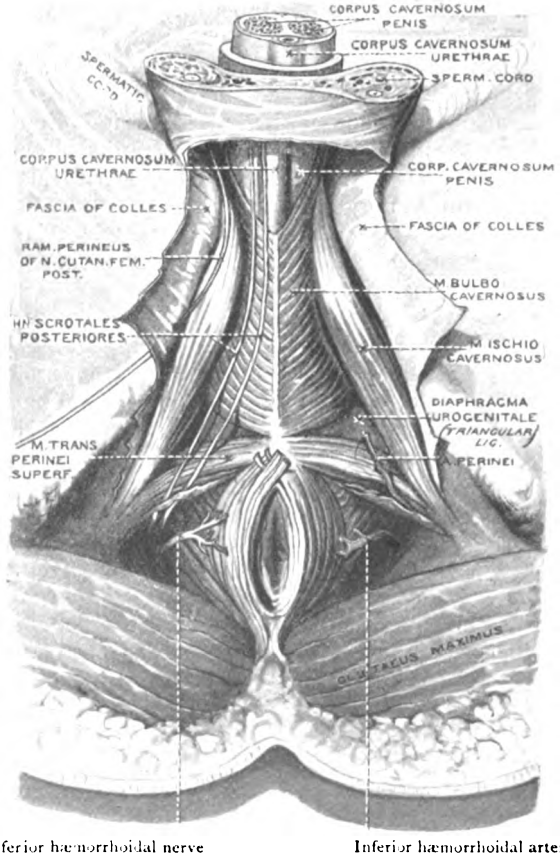


FIG. 129.—Dissection of the Perineum. The Scrotum and the Penis have been cut transversely across and removed.

posteriorly, but becomes incomplete towards the scrotum. Anteriorly, the fascia of Colles passes over the scrotum, penis, and spermatic cords, to the anterior aspect of the abdomen, where it becomes continuous with the fascia of Scarpa (p. 380).

**How to verify these facts.**—The student can verify these facts in two ways, viz.—(1) by inflating the pouch with air, and (2) by dissection. Make a longitudinal incision, large enough to admit the nozzle of the bellows (or, better still, an injection pipe fitted to a bicycle-pump), into the superficial fascia towards the posterior part of the pouch and a little to one side of the middle line. This cut must be carried through the fascia until the fibres of the superficial perineal muscles are exposed. In using the pump the margins of the opening into the pouch must be held tightly around the nozzle of the pipe. The air which is introduced passes forwards, and is at first confined to one side of the pouch. Reaching the scrotum, however, where the septum is incomplete, it forces its way across the median plane, and inflates the opposite side of the pouch. The pouch is now rendered prominent, and the attachments of the fascia become very evident. The air cannot pass into the anal triangle owing to the union of the fascia of Colles with the base of the fascia of the urogenital diaphragm ; it cannot pass down the medial aspect of the thighs, on account of the attachment of the fascia to the sides of the pubic arch ; it can only force its way forwards under the superficial fascia and dartos muscle of the scrotum, and thence on to the penis and along the spermatic cords to the anterior aspect of the abdomen. By this means the dissector obtains a very striking view of the course which would be taken by urine escaping from a rupture in the urethra below the urogenital diaphragm.

The attachments of the fascia of Colles are so important that the student should test them by dissection also. To do this it is necessary to make two incisions through the superficial fascia. Enter the knife in the middle line at the root of the scrotum, and carry it backwards and laterally to the tuber ischii on each side of the body. A central $\Lambda$-shaped flap and two collateral flaps of fascia are thus marked out. When the central portion is raised and turned backwards, the septum of the pouch is brought into view, and the attachment of the fascia to the base of the urogenital diaphragm is demonstrated. When the collateral flaps are turned aside each will be seen to be firmly fixed to the border of the pubic arch. In this dissection the utmost care is demanded on the part of the student. In the areolar tissue immediately subjacent to the superficial fascia are the *superficial perineal vessels* and *scrotal nerves*, which are certain to be injured, or perhaps even reflected with the fascia, unless the greatest caution is exercised.

## Anal Triangle.

The dissection of this portion of the perineal space will disclose the following parts :—

1. The external sphincter ani muscle.
2. The anal canal, covered by the levator ani muscle and the inferior fascia of the pelvic diaphragm.
3. The obturator fascia.
4. The lower border of the glutæus maximus muscle and the ligamentum sacro-tuberosum (O.T. great sciatic).
5. The coccygeus muscle.
6. The inferior hæmorrhoidal vessels and nerve.
7. The perineal artery.
8. The perineal branch of the fourth sacral nerve.
9. The perineal nerve and its branches.
10. The perforating cutaneous branch of the second and third sacral nerves.

**Sphincter Ani Externus.**—When this muscle is cleaned it will be seen to consist of a thick ring of muscular fibres surrounding the orifice of the anal canal. *Posteriorly*, it is attached, by a pointed tendon, to the tip and posterior surface of the terminal part of the coccyx; *anteriorly*, it blends with other perineal muscles in the central point of the perineum. As the fibres pass between the two points of attachment, they encircle the anal orifice and form a true sphincter muscle. Some of the superficial fibres, both in front of and behind the anal opening, are directly attached to the skin. It draws its nervous supply from two sources, viz., the *fourth sacral nerve* and the *inferior hæmorrhoidal nerve*.

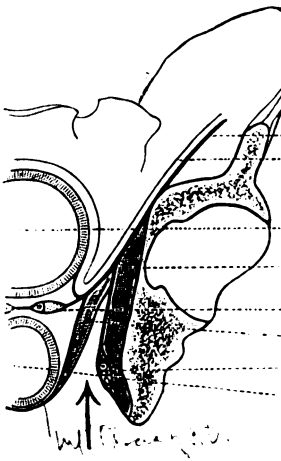


FIG. 130.—Diagram. The arrow is directed upwards into the ischio-rectal fossa. The parietal pelvic fascia is seen upon the medial surface of the obturator internus. Observe also the anal fascia clothing the lateral surface of the levator ani and the rectal fascia upon its medial surface.

**Ischio-rectal Fossa.**—Although the anal canal is the largest and most important object which is contained within the posterior portion of the perineum, it does not fill up the entire extent of the anal triangle. An interval or recess is left upon each side of the anal canal—between it and the ischium,—and to this recess is given the name of the *ischio-rectal fossa*.

In shape the ischio-rectal fossa is pyramidal, the apex of the pyramid being directed upwards towards the pelvic cavity, and the base downwards towards the integument. The medial wall of the space is sloping, whilst the lateral wall is steep and perpendicular.

**Boundaries.**—Whilst the term "*ischio-rectal*" is applied to this fossa, it must be borne in mind that neither the ischium nor the anal portion of the rectum enters directly into the formation of its walls. Both are separated from the space by fascial and muscular layers. Upon the medial aspect of the

ischium is the obturator internus muscle, and this again is covered by the obturator fascia, which is continued down to be attached to the tuberosity of the ischium and the sacro-tuberous ligament. On the other hand, the anal canal is clothed latero-medially by—(1) the inferior fascia of the pelvic diaphragm, a thin fascial membrane which invests the lateral surface of the levator ani; (2) the levator ani muscle; and (3) the rectal portion of the superior fascia of the pelvic diaphragm (O.T. visceral layer of the pelvic fascia)—a thin layer of fascia which covers that part of the pelvic surface of the levator ani which is applied to the anal part of the rectum (Fig. 130). Strictly speaking, therefore, the perpendicular *lateral* or *ischial wall* of the fossa is formed by the obturator fascia, and the sloping *medial* or *rectal wall* by the inferior fascia of the pelvic diaphragm. *Anteriorly*, the space is limited by the fascia of the urogenital diaphragm (O.T. triangular ligament); whilst *posteriorly*, it is bounded by the posterior or distal margin of the glutæus maximus and the sacro-tuberous ligament.

**Contents.**—The ischio-rectal fossa is completely filled up by a mass of fat which is prolonged upwards into it from the superficial fascia. The soft, pliable nature of this fat readily allows of the distension of the anal canal. Embedded in it are certain blood-vessels and nerves. Crossing the fossa from its lateral to its medial wall are the *inferior hæmorrhoidal vessels* and *nerve*; entering the fossa at its posterior part is the *perineal branch* of the *fourth sacral nerve*; turning round the distal border of the glutæus maximus, not far from the coccyx, is the *perforating cutaneous branch* of the second and third sacral nerves; whilst in the anterior part of the space will be found the scrotal branches of the *perineal nerve* (Fig. 129).

*Dissection.*—Begin by exposing the margin of the *glutæus maximus muscle.* Take a point a short distance to the lateral side of the tuber ischiadicum and another in the median plane about an inch above the tip of the coccyx, and cut boldly down through the superficial fascia, in a line between those points, until the fleshy fibres become visible. Winding round the margin of the muscle, so as to gain its superficial aspect, there are a few small arteries and nerves. The arteries are derived from the *inferior hæmorrhoidal vessels*, or from the *inferior gluteal artery*, whilst the nerves are the *perforating cutaneous branch* from the second and third sacral nerves and some offsets from the *posterior cutaneous nerve of the thigh.* All are destined for the supply of the skin on the distal part of the gluteal region. The perforating cutaneous nerve turns round the margin of the glutæus maximus close to the coccyx, whilst the cutaneous branches from the posterior cutaneous nerve of the thigh appear on the

lateral side of the tuber ischiadicum. Having secured these vessels and nerves, clean the distal margin of the glutæus maximus, and then proceed to dissect the ischio-rectal fossa. If the subject is obese, a considerable quantity of fat may be removed at once without endangering the inferior hæmorrhoidal vessels and nerve. Take the surface of the glutæus maximus and the margin of the external sphincter as guides, and transfix the fat with the knife in this plane. The fatty tissue superficial to this plane may be removed *en masse* with safety. The *inferior hæmorrhoidal vessels* and *nerve* may be found by dissecting cautiously in the fat and carrying the knife in an oblique direction, from behind forwards and from the lateral to the medial wall of the space. The perineal branch from the *fourth sacral nerve* appears by the side of the coccyx.

**Roof of the Space.**—When the vessels and nerves of the space are secured, continue to remove the fat from the fossa until its walls are fully displayed. When the finger is passed upwards in the fossa, its passage into the pelvis is prevented by the junction of the inferior fascia of the pelvic diaphragm with the obturator fascia (Fig. 130, p. 346). Further, if the inferior fascia of the pelvic diaphragm is removed, the entrance of the finger into the pelvis is still resisted by the levator ani muscle and also by the superior fascia of the pelvic diaphragm, which passes medially on the superior surface of the levator ani.

**Internal Pudendal Vessels** (O.T. **Internal Pudic**) **and Pudendal Nerve** (O.T. **Pudic**).—The dissector should now pass his finger upwards and downwards, over the surface of the obturator fascia, which covers the medial surface of the obturator internus muscle and forms the lateral wall of the ischio-rectal fossa. About an inch and a half above the inferior border of the ischial tuberosity he will feel, very distinctly, the pudendal vessels and nerve as they pass forwards to gain the urethral triangle. They are enclosed in a tube or sheath formed by the obturator fascia, and called Alcock's canal. The student must for the present be satisfied with palpating these structures. To expose them would necessitate the division of the obturator fascia, and that should be kept entire until the pelvic fascia can be studied as a whole.

**Arteriæ Hæmorrhoidales Inferiores.**—The inferior hæmorrhoidal arteries, usually two or three in number, are branches of the internal pudendal. They pierce the medial wall of Alcock's canal, and pass medially through the fat of the ischio-rectal fossa to supply the anal canal and the muscles in connection with it, as well as the skin around the anus.

Around the anus they anastomose with the corresponding arteries of the opposite side, and with branches from the middle and superior hæmorrhoidal arteries. They also send a few twigs round the distal border of the glutæus maximus, in company with the perforating cutaneous nerve, to supply the skin in the distal part of the buttock.

**N. Hæmorrhoidalis Inferior.**—The inferior hæmorrhoidal nerve accompanies the vessels of the same name. It may proceed directly from the sacral plexus, but more frequently it is a branch of the pudendal nerve. It perforates the medial wall of Alcock's canal, enters the ischio-rectal fossa, and then it breaks up into muscular, cutaneous, and communicating branches. The *muscular twigs* supply the external sphincter ani; the *cutaneous offsets* are given to the skin which surrounds the anus; while the *communicating filaments* pass forwards to join the long perineal branch of the posterior cutaneous nerve of the thigh and the scrotal nerves.

**Perineal Branch of Fourth Sacral Nerve.**—This small nerve enters the ischio-rectal fossa by piercing the coccygeus muscle at the side of the coccyx. It is distributed to the skin between the anus and coccyx, and to the external sphincter ani muscle.

The perineal artery and the perineal nerve will be found in the anterior angle of the fossa close to the lateral wall.

**Ano-coccygeal Body.**—An indefinite mass of muscular and fibrous tissue which lies between the tip of the coccyx and the anus receives the name of *ano-coccygeal body*. It is seen best in sections through the pelvis, and it requires notice on account of the support which it gives to the lower part of the rectum and the anal canal. The muscular tissue which enters into its constitution belongs to the levator ani and the external and internal sphincter muscles (Symington).

## Urogenital Triangle.

The superficial fascia in this locality has already been studied. The following is a list of the structures which still require to be examined:—

1. The posterior scrotal vessels and nerves.
2. The long perineal branch of the posterior cutaneous nerve of the thigh.
3. The root of the penis. {The bulb of the urethra and the crura.

4. The superficial perineal muscles.
   - *a.* Superficial transverse perineal muscle.
   - *b.* Bulbo-cavernosus muscle.
   - *c.* Ischio-cavernosus muscle.
5. Inferior fascia of the urogenital diaphragm.
6. The internal pudendal vessels and the pudendal nerve and their branches.
7. The deep transverse perineal muscle and the sphincter of the membranous urethra.
8. The bulbo-urethral glands.
9. The membranous portion of the urethra.
10. Superior fascia of the urogenital diaphragm.

**Superficial Perineal Vessels and Scrotal Nerves** (O.T. **Perineal**).—The superficial perineal vessels and the scrotal nerves must now be followed out:—

Arteries.
1. The perineal artery.
2. The transverse branch of the perineal artery.

Nerves.
1. The scrotal nerves.
2. The long perineal branch of the posterior cutaneous nerve of the thigh.

The *perineal artery*, a branch of the pudendal, pierces first the medial wall of Alcock's canal, and then the base of the fascia of the urogenital diaphragm, so as to gain the interior of the perineal pouch of fascia. It then crosses the superficial transversus perinei muscle, and is continued forwards, in the interval between the bulbo-cavernosus and ischio-cavernosus muscles, to the scrotum, to the dartos muscle and integument to which it is distributed in the form of numerous long, slender branches, called the *posterior scrotal arteries*. Before it reaches the scrotum, it supplies twigs to the superficial perineal muscles. It is accompanied by the posterior scrotal branches of the perineal nerve.

The *transverse perineal artery* is a small vessel which usually springs from the preceding. It pierces the base of the fascia of the urogenital diaphragm, and, gaining the surface of the superficial transverse perineal muscle, proceeds transversely medially to the interval between the rectum and the bulb, where it ends by supplying the parts in that locality, and by anastomosing with the corresponding vessel of the opposite side.

The *posterior scrotal nerves* are branches of the perineal division of the pudendal nerve. They appear in the anterior part of the ischio-rectal fossa after piercing the fascia on its lateral wall. They leave the fossa by piercing the base of

the inferior fascia of the urogenital diaphragm and passing either superficial or deep to the superficial transverse muscle; then they run forwards in the urogenital triangle to the skin of the scrotum. As they pass forwards they communicate with the long perineal branch of the posterior cutaneous nerve of the thigh.

The *deep branch* of the *perineal nerve* passes deep to the superficial transverse perineal muscle and ends in branches to the deep transverse muscle, the superficial perineal muscles, and the bulb of the urethra.

*Dissection.*—Instead of searching for the long perineal branch of the posterior cutaneous nerve of the thigh at the point where it becomes superficial, and then following it towards its distribution, it is much easier to find it after it has entered the perineal pouch of fascia. There it will be discovered lying in close relation to the preceding two nerves, but to the lateral side of them. Trace it forwards and backwards. It communicates with the inferior hæmorrhoidal nerve, and also with the posterior superficial perineal nerve.

The *long perineal branch of the posterior cutaneous nerve of the thigh* (O.T. *long pudendal nerve*) pierces the deep fascia of the thigh a short distance in front of the ischial tuberosity, and about an inch and a half to the lateral side of the margin of the pubic arch. As it proceeds forwards it inclines medially, and, piercing the attachment of Colles' fascia to the margin of the pubic arch, it accompanies the other vessels and nerves to the scrotum, the lateral and anterior part of which it supplies.

*Dissection.*—Divide the superficial perineal vessels and nerves, and throw them aside.

**Urogenital Diaphragm and Root of Penis.**—The student must now consider the position of the urogenital diaphragm, and the relation which it bears to the root of the penis. The *urogenital diaphragm* is a strong, triangular partition which stretches across the pubic arch and separates the anterior part of the perineum from the pelvis. It consists of the deep transverse muscle of the perineum, and the sphincter urethræ membranaceæ, enclosed between two layers of fascia, an upper and a lower. The two layers of fascia are blended together anteriorly and posteriorly. They are attached laterally to the margins of the pubic arch, and they enclose between them a space which contains not only the muscular part of the diaphragm but also the membranous portion of the

urethra, the bulbo-urethral glands (O.T. Cowper's), the terminal parts of the internal pudendal vessels and some of their branches, and the dorsal nerves of the penis. The blended anterior margins of the *inferior fascia of the urogenital diaphragm* (O.T. *superficial layer of the triangular ligament*), and the *superior fascia of the urogenital diaphragm* (O.T. *deep layer of the triangular ligament*) form the *transverse ligament of the pelvis* and their blended posterior margins form the base of the urogenital diaphragm. The space between the two layers is spoken of as the deep compartment, or pouch, of the urethral triangle, and the area enclosed between the inferior fascia of the urogenital diaphragm and the fascia of Colles is the superficial pouch. The latter pouch has already been opened, and the superficial vessels and nerves which form part of its contents have been displayed. The root of the penis also lies within the superficial area of the urethral triangle, in relation with the inferior aspect of the lower fascia of the urogenital diaphragm.

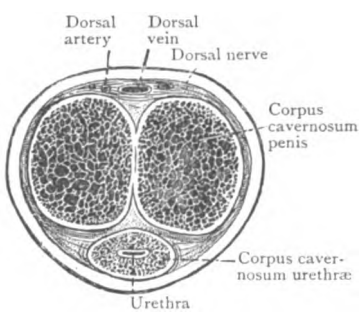


FIG. 131.—Transverse section through the body of the Penis.

With the handle of the knife clear away, for a short distance, the loose tissue which surrounds the body of the penis, which will then be seen to consist of two masses; a superior, the *corpus cavernosum penis*, and an inferior, the *corpus cavernosum urethræ*. The corpus cavernosum penis forms the main mass of the anterior two-thirds of the penis. It has the form of a flattened cylinder grooved upon its superior and inferior surfaces. Anteriorly, the corpus cavernosum penis is partially separated into two halves by a perforated septum. Posteriorly, at the apex of the pubic arch, it divides into two portions called the *crura of the penis*. The groove on the superior surface lodges the dorsal vessels and nerves of the penis; and the corpus cavernosum urethræ lies in the deeper groove on the inferior surface. Immediately behind the point where it begins to diverge from its fellow each crus is slightly dilated; thence, backwards

to its posterior extremity, it gradually tapers away. It is firmly fixed to the corresponding pubic arch by an attachment which extends from the apex of the arch backwards to within a short distance of the ischial tuberosity; it is attached also to the adjacent part of the lower surface of the inferior fascia of the urogenital diaphragm. The corpus cavernosum urethræ is slender in comparison with the corpus cavernosum penis; it is lodged in the groove on the inferior

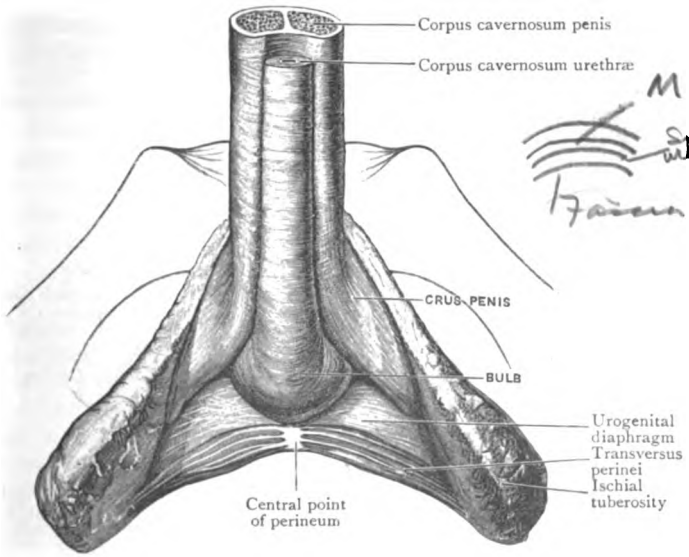


FIG. 132.—The Root of the Penis and the Fascia inferior of the Urogenital Diaphragm (O.T. triangular ligament) (Formalin specimen).

surface of the latter; and it is traversed throughout its whole length by the urethra. It is continued posteriorly, beyond the point where the corpus cavernosum penis divides into the two crura, to within a short distance of the anus, and as it passes backwards it expands, forming the *bulbus urethræ*, which lies between the diverging crura, and is attached, by its superior surface, to the inferior surface of the lower fascia of the urogenital diaphragm. The posterior extremity of the bulb is frequently notched in the middle line—an indication of an original double constitution.

The bulb and the two crura together constitute *the root of the penis*, and each is provided with a special muscle, which at present hides it from view. The bulb is covered by a bipenniform muscle called the *bulbo-cavernosus*, whilst moulded upon the surface of each crus is the *ischio-cavernosus*. These muscles must now be cleaned and their connections examined.

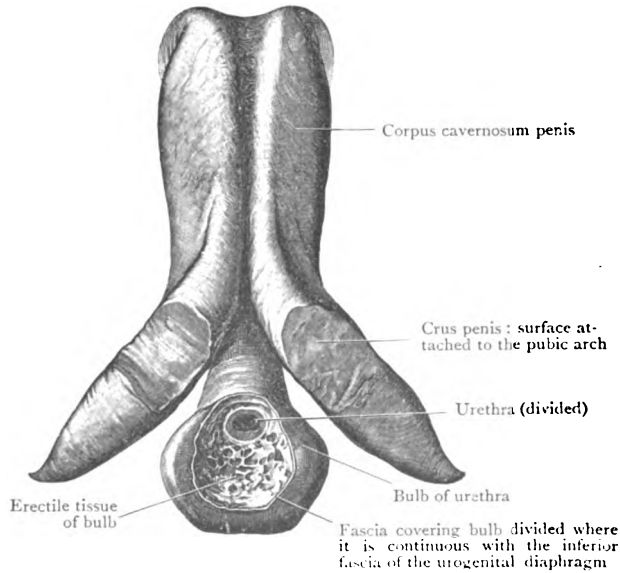
Corpus cavernosum penis
Crus penis : surface attached to the pubic arch
Urethra (divided)
Bulb of urethra
Erectile tissue of bulb
Fascia covering bulb divided where it is continuous with the inferior fascia of the urogenital diaphragm

FIG. 133.—Dorsal or attached aspect of the Penis. The specimen was hardened by formalin injection and removed from the pubic arch and the urogenital diaphragm.

**Superficial Perineal Muscles.**—Under this heading are included not only the bulbo-cavernosus and ischio-cavernosus muscles, but also the superficial transverse perineal muscles. The superficial perineal muscles have been seen to lie within the pouch formed by the superficial fascia and the inferior fascia of the urogenital diaphragm. When the superficial fascia is removed each will be found to be invested by its own delicate layer of fascia.

**M. Transversus Perinei Superficialis.**—The superficial transverse perineal muscle is a narrow slip of muscular fibres

which arises from the medial aspect of the inferior ramus of the ischium close to the tuberosity. It passes medially and unites with the corresponding muscle of the opposite side in the central point of the perineum.

The *central point of the perineum* is a tendinous septum, situated in the middle line of the body, close to the posterior end of the bulb and a short distance in front of the anus. Towards this point a number of the perineal muscles converge to obtain attachment. *On each side*, it gives attachment to a superficial transverse perineal muscle; *posteriorly*, to the sphincter ani; *anteriorly*, to the posterior fibres of the bulbo-cavernosus; whilst *superiorly*, the anterior fibres of the levator ani descend to reach it.

**M. Bulbo-cavernosus** (O.T. **Ejaculator Urinæ**).—The bulbo-cavernosus muscle is spread over the bulb and posterior part of the corpus cavernosum urethræ. It is composed of two symmetrical halves, and its fibres take origin from the central point of the perineum and from a fibrous median raphe which is prolonged forwards between the two halves of the muscle. The insertion differs according to the point at which the muscle is examined. The *posterior fibres* are attached to the superficial aspect of the inferior fascia of the urogenital diaphragm; the *middle fibres*, constituting the greater part of the muscle, sweep around the corpus cavernosum urethræ, so as to invest it completely, and are inserted into an aponeurosis upon the superior surface of that portion of the penis; lastly, the *anterior fibres* form two long narrow muscular bands which diverge from each other like the limbs of the letter V, and, passing forwards, over the sides of the corpus cavernosum penis, are inserted into an aponeurosis on the dorsum of the penis. Thus the *posterior fibres* partially embrace the bulb; the *middle fibres* embrace the corpus cavernosum urethræ; whilst the *anterior fibres* embrace the body of the penis. The bulbo-cavernosus supports the urethra during micturition, and by its contraction it ejects the last drops of urine or semen from the passage.

**M. Ischio-cavernosus** (O.T. **Erector Penis**).—The ischio-cavernosus lies upon the crus penis. It arises by fleshy fibres from the medial aspect of the ischial tuberosity, and is inserted by an aponeurotic expansion into the lower and lateral surface of the anterior portion of the crus.

**Perineal Nerve.**—This is one of the two terminal branches

of the pudendal nerve. It supplies twigs to the skin, to the muscles of the perineum, and to the bulb of the penis. The *cutaneous scrotal branches* have already been followed out. *Muscular twigs*, occupying a deeper plane, may be traced to each of the three superficial perineal muscles and to the levator ani, whilst a few minute offsets pierce the inferior fascia of the urogenital diaphragm to supply the deep transversus perinei muscle. The *nerve to the bulb* is a small branch which breaks up into filaments which enter the posterior part of the corpus cavernosum urethræ.

**Perineal Triangles.**—If the superficial perineal muscles are now examined, in regard to the relations which they hold to each other, the student will see that they constitute the boundaries of a small triangular space upon each side of the middle line. The *base* of the triangle is formed by the superficial transversus perinei; *laterally* it is limited by the ischio-cavernosus, and *medially* by the bulbo-cavernosus. Let the student now place the point of his finger within this space and press upwards and backwards. He will find that his finger rests upon a strong resisting membrane. This is the inferior fascia of the urogenital diaphragm (O.T. triangular ligament), which therefore forms the roof of the space.

*Dissection.*—To bring the inferior fascia of the urogenital diaphragm fully into view, it is necessary, in the first place, to remove the superficial perineal muscles. When this is done the three divisions of the root of the penis are exposed to view, and their manner of attachment (which has already been described, p. 354) can be studied. Detach, in the next place, the left crus of the penis from the side of the pubic arch, and turn it aside. This must be effected with care, so as not to destroy the attachment of the fascia to the side of the pubic arch, or to injure the pudendal artery and dorsal nerve of the penis, which pierce the anterior part of the fascia.

**Inferior Fascia of the Urogenital Diaphragm** (O.T. **Superficial Layer of the Triangular Ligament**).—This is now seen to be a strong fibrous membrane which stretches across the pubic arch. It must be regarded as lying in the same morphological plane as the bony and ligamentous wall of the pelvis, and as completing the pelvic wall in front, much in the same manner as the obturator membrane fills up the obturator foramen.

Upon each side the inferior fascia of the urogenital diaphragm is attached to the medial surfaces of the rami of the pubis and ischium. Its base has already been seen to blend, along the posterior border of the superficial

transversus perinei muscles, with the fascia of Colles. In addition to this attachment, however, a careful dissection in a good subject will show that the central part of the base projects backwards in the form of a short process or beak, which joins the central point of the perineum. Near the symphysis pubis the anterior margin, fused with the anterior margin of the superior fascia of the diaphragm, forms the transverse ligament of the pelvis. Between the anterior

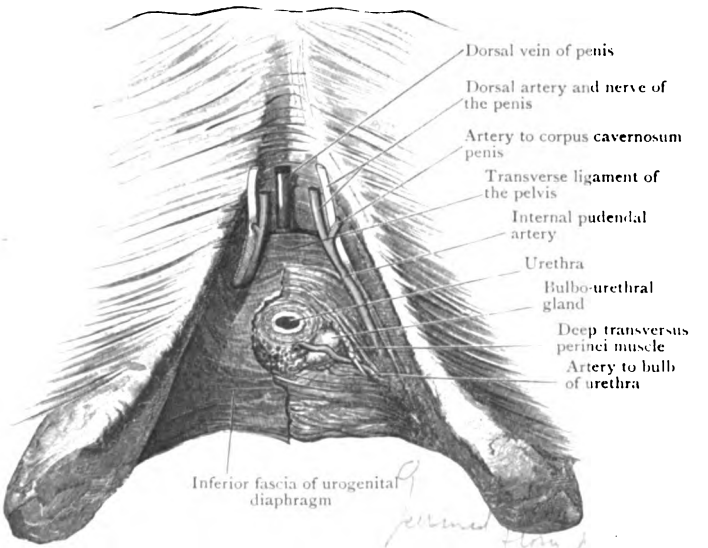
Dorsal vein of penis
Dorsal artery and nerve of the penis
Artery to corpus cavernosum penis
Transverse ligament of the pelvis
Internal pudendal artery
Urethra
Bulbo-urethral gland
Deep transversus perinei muscle
Artery to bulb of urethra
Inferior fascia of urogenital diaphragm

FIG. 134.—Deep dissection of the Perineum. The penis has been removed, the urethra cut across, and the inferior fascia of the urogenital diaphragm removed on the left side.

border of this band and the arcuate ligament of the pubis an oval gap is left for the passage of the dorsal vein of the penis.

In the erect posture of the body the superficial surface of the urogenital diaphragm looks downwards and forwards, whilst its deep surface looks upwards and backwards towards the cavity of the pelvis. In close contact with its inferior fascia are the parts which constitute the root of the penis, viz., the bulb and the two crura and the muscles which are associated with them, and also the superficial transversus perinei muscle on each side. The structures which lie between

its two fasciæ will be studied when the inferior fascia is reflected.

The inferior fascia of the urogenital diaphragm is not an unbroken continuous layer. It is pierced—(1) by the urethra; (2) by the internal pudendal arteries; (3) by the dorsal nerves of the penis; (4) by the arteries to the bulb; (5) and lastly, at its base, where it blends with the superficial fascia, by the superficial perineal vessels and nerves. The *aperture for the urethra* is situated in the middle line, one inch below the symphysis pubis. It is not a clean-cut hole with sharp edges. The margins of the opening, which are separated by a considerable interval from the circumference of the urethra, are prolonged over the bulb of the urethra so as to form for it a fibrous capsule. As soon as the urethra gains the superficial aspect of the fascia it sinks into the bulb, and is carried forwards through the entire length of the corpus cavernosum urethræ to its external opening on the glans penis. On each side of the urethral aperture there is a small opening in the fascia which gives passage to the corresponding *artery to the bulb.* Half an inch farther forwards the *dorsal nerve of the penis* and the *internal pudendal artery* pierce the fascia on each side, close to the margin of the pubic arch, and under cover of the corresponding crus penis.

The term "*inferior* or *superficial fascia*" of the urogenital diaphragm which is applied to this membrane, implies that there is a deeper or superior fascia to be studied in connection with it; and so there is. But whilst these fasciæ are very intimately connected, they must be looked upon as being distinct structures. The superficial or inferior fascia of the urogenital diaphragm is in the same morphological plane as the bony wall of the pelvis and the obturator membrane, and, in fact, completes the pelvic wall in front. The *superior fascia of the urogenital diaphragm* is merely the parietal layer of the pelvic fascia carried round to the front of the pelvis. Consequently the connections of the latter layer can be examined very much better in conjunction with the pelvic fascia. It should now be noted—(1) that, with the inferior fascia it encloses the urogenital diaphragm; (2) that the anterior and posterior margins of the two layers are blended together; (3) that the interval between the two is closed laterally by the attachment of both layers to the margins of

the pubic arch; and (4) that the space between the two layers contains:—

1. The membranous portion of the urethra and its sphincter muscle.
2. The deep transverse perineal muscle.
3. The bulbo-urethral (Cowper's) glands.
4. The internal pudendal vessels, the dorsal nerves of the penis, and the arteries to the bulb.

*Dissection.*—To expose these parts, on one side, reflect the inferior fascia of the urogenital diaphragm on that side, but carefully preserve the fascia on the opposite side, so that it may serve as a landmark in the subsequent dissection of the pelvis. On the side selected detach the fascia from the pubic arch, and, cautiously raising it from the subjacent structures, throw it medially towards the bulb.

**Pars Membranacea Urethræ (Membranous Portion of the Urethra).**—The canal of the urethra is subdivided for descriptive purposes into three parts, according to the structures which are in relation to its walls, as it passes from the bladder to its termination on the glans penis. These are—(1) the prostatic portion; (2) the membranous portion; and (3) the cavernous portion. Each of these subdivisions has a very definite relation to the urogenital diaphragm; the prostatic part is placed *above and posterior to* both fasciæ of the diaphragm; the membranous part is situated *between* the two fasciæ; whilst the cavernous portion lies *anterior and inferior to* the diaphragm.

Now that the inferior fascia of the diaphragm is removed upon one side, the student can, with the point of the finger, readily feel the staff as it lies within the membranous portion of the urethra. He should examine the surroundings of that canal. It is the shortest subdivision of the urethra, and is about one inch distant from the symphysis pubis. Throughout its entire extent it is enveloped by the fibres of the sphincter muscle, and on this account it is sometimes called the muscular part of the urethra. On each side, and at a lower level, is a bulbo-urethral (Cowper's) gland, whilst between it and the symphysis pubis is the dorsal vein of the penis, which is separated from it by the transverse ligament of the pelvis.

**M. Transversus Perinei Profundus** and **M. Sphincter Urethræ Membranaceæ** (O.T. **Compressor Urethræ Muscle**).—The deep transverse muscle of the perineum is a small fan-shaped muscle which lies between the fasciæ of the urogenital diaphragm. It has a tendinous origin

from the margin of the pubic arch at the junction of the pubic and ischial rami. Expanding as it passes medially, it unites with its fellow of the opposite side in a medial raphe, below and behind the membranous part of the urethra. Its posterior border lies in the angle between the inferior and superior fasciæ of the urogenital diaphragm, and its anterior border is blended with the external layer of the sphincter muscle of the membranous urethra. The *sphincter of the membranous urethra* consists of internal and external groups of fibres. The internal group is formed of circular fibres which embrace the urethra; they are continuous above with the muscular fibres of the prostate and below with the circular muscular fibres around the posterior part of the cavernous portion of the urethra. The external layer consists of transverse fibres which arise, together with the deep transverse muscle of the perineum, from the margin of the pubic arch and from the inferior fascia of the urogenital diaphragm. As they approach the median plane some of the fibres pass anterior and some posterior to the membranous part of the urethra, and they blend with the corresponding fibres of the opposite side. These muscles are supplied by one or two delicate twigs from the *perineal division* of the *pudendal nerve.*

**Glandulæ Bulbo-urethrales** (O.T. **Cowper's Glands**).—As a general rule, the bulbo-urethral glands can readily be detected by raising the posterior fibres of the deep transverse perineal muscles. They are small lobulated bodies of a deep yellow colour, and resemble peas, both in size and in shape. They are placed, one on each side of the middle line, immediately below the membranous part of the urethra, and are overlapped by the posterior part of the bulb—separated from it, however, by the inferior fascia of the urogenital diaphragm. From each a minute duct proceeds, but this duct does not open into the membranous portion of the urethra. It passes forwards between the wall of the urethra and the substance of the bulb for the distance of one inch, and opens on the floor of the cavernous part of the urethra.

**Art. Pudenda Interna** (O.T. **Internal Pudic**).—The internal pudendal artery is a branch of the hypogastric. It is met with in three different regions of the body—viz., (1) within the cavity of the pelvis; (2) in the gluteal region, where it lies upon the spine of the ischium; and (3) in the perineal space. It is consequently described as con-

sisting of a *pelvic*, a *gluteal*, and a *perineal part*. The *perineal* [illegible] *third part* of the pudendal artery enters the perineum by passing through the lesser sciatic foramen. At first it is placed deeply; but it is found to become more superficial as it is traced forwards, and, at the same time, to incline medially, so that, at its termination, it lies close to the middle line of the body.

In the rectal triangle the pudendal artery is contained

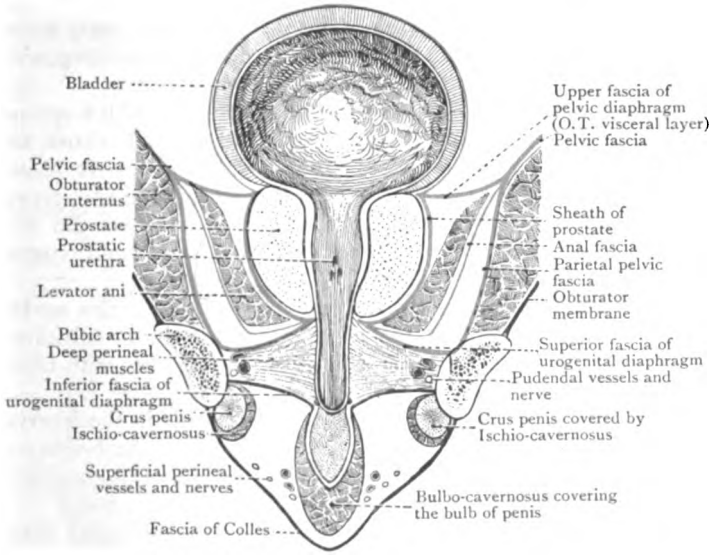


FIG. 135.—Vertical section (schematic) through the pubic arch to show the two perineal compartments.

within a sheath, termed Alcock's canal, which is formed by the splitting of the obturator fascia which forms the lateral wall of the ischio-rectal fossa. It lies fully an inch and a half above the level of the lowest part of the ischial tuberosity, and is accompanied by two veins and the two divisions of the pudendal nerve. Of the latter the dorsal nerve of the penis lies above it and the perineal nerve below it. Reaching the base of the urethral triangle, the pudendal artery insinuates itself between the two fasciæ of the uro-genital diaphragm, and, gradually emerging from under cover of the bone, proceeds forwards along the edge of the pubic

arch to a point about half an inch below the symphysis, where it pierces the inferior fascia of the urogenital diaphragm, and immediately ends, under cover of the crus penis, by dividing into two branches, viz.—(1) the artery to the corpus cavernosum penis, and (2) the dorsal artery of the penis (Fig. 134, p. 357).

**Branches of the Internal Pudendal Artery.**—The pudendal artery has already been seen to give off the *inferior hæmorrhoidal*, and the *perineal arteries*, and to divide into its two terminal branches—the *dorsal artery of the penis* and the *artery to the corpus cavernosum penis*. Between the fasciæ of the urogenital diaphragm it gives origin to the *artery to the bulb*.

The *artery to the bulb* is a short, wide vessel which springs from the pudendal about a quarter of an inch above the level of the base of the urogenital diaphragm. It passes medially, between the two fasciæ of the diaphragm, and, giving a small twig to the bulbo-urethral gland, it enters the substance of the bulb. It supplies the bulb and corpus cavernosum urethræ with blood (Fig. 136).

The *artery to the corpus cavernosum penis* pierces the medial aspect of the crus penis, and is carried forwards in the substance of the corpus cavernosum penis, which it supplies with blood (Fig. 136).

The *dorsal artery of the penis* runs forwards in the interval between the crura penis, and, passing between the two layers of the suspensory ligament of the penis, gains the dorsum of the penis, where it will be afterwards traced (Fig. 222).

**N. Pudendus** (O.T. **Pudic Nerve**).—The pudendal nerve is a branch of the sacral plexus. Following the internal pudendal artery it enters Alcock's canal, and, after giving off the *inferior hæmorrhoidal nerve*, it divides into two terminal divisions, viz.—(1) the perineal nerve, and (2) the dorsal nerve of the penis.

The *perineal nerve* has been seen to break up into the following branches:—

| | |
|---|---|
| *Cutaneous.* | Posterior Scrotal. |
| *Muscular.* | 1. Nerve to the bulbo-cavernosus. |
| | 2. Nerve to the ischio-cavernosus. |
| | 3. Nerve to the transversus perinei superficialis. |
| | 4. Nerve to the transversus perinei profundus. |
| | 5. Nerve to the sphincter urethræ membranaceæ. |

It supplies also one or two branches to the bulb and the corpus cavernosum urethræ.

The *dorsal nerve of the penis* follows the pudendal artery between the two fasciæ of the urogenital diaphragm, where it lies more completely under shelter of the side of the pubic arch than the artery. Finally, piercing the inferior fascia of the diaphragm, about half an inch below the symphysis pubis, it accompanies the dorsal artery of the penis. At the root of the penis it supplies one or two twigs to the corpus cavernosum penis.

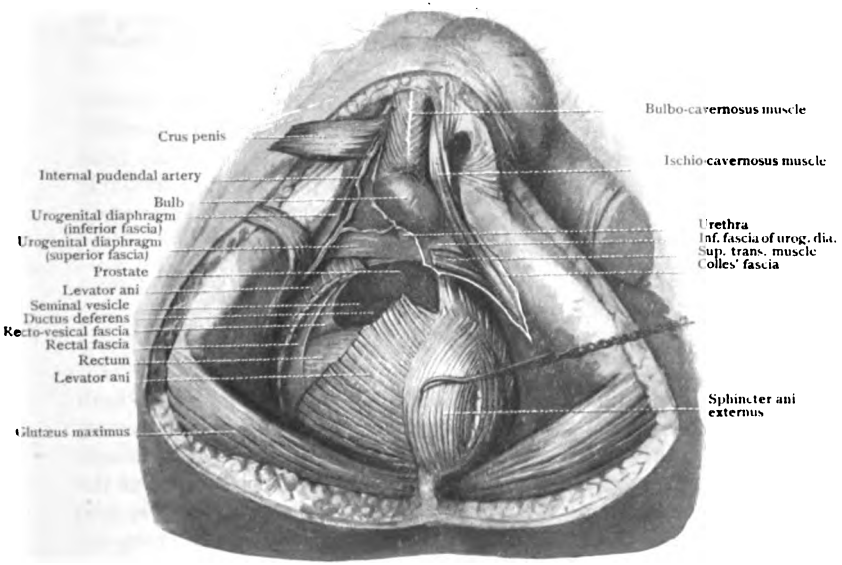


FIG. 136.—Dissection to expose the Prostate from the Perineum.

The dissection of the perineum, to the extent usually possible in three days, is now completed, and the student should notice that in the urethral triangle he has opened two fascia-bounded compartments. The superficial compartment lies between Colles' fascia and the urogenital diaphragm. Posteriorly this is closed by the union of the fascia and the diaphragm. Laterally it is closed by the attachment of the fascia and the diaphragm to the rami of the ischium and pubis. Anteriorly, since the fascia of Colles is continuous with the deep layer of the superficial fascia of the abdominal wall, the pouch is open, and fluid poured out into it can pass upwards to the abdominal wall. For the contents of the pouch see p. 343. The deep pouch lies between the two fasciæ of the urogenital diaphragm. It is closed posteriorly and anteriorly by the union of the two fasciæ and laterally by the attachment of the two fasciæ of the diaphragm to the rami of the pubis and ischium. For the contents of the deep compartment

see p. 359. Above the superior wall of the deep compartment lie the apex of the prostate gland and the anterior borders of the levatores ani muscles. To approach the prostate, therefore, through the urethral triangle, a series of alternating fascial and muscular strata would have to be divided, viz.—

1. The fascia of Colles.
2. The superficial perineal muscles.
3. The inferior fascia of the urogenital diaphragm.
4. The deep transverse perineal muscle and the sphincter of the membranous urethra.
5. The superior fascia of the urogenital diaphragm.

This, however, is not a practicable way of approaching the prostate, and the method which should be adopted to display the posterior surface of the gland will be described when the investigation of the pelvic fascia is undertaken (see p. 566).

A pad of tow, soaked in preservative mixture, should be placed in the perineum, and the flaps of skin carefully stitched over it. On the *fourth day* after the body has been brought into the dissecting-room, it is placed upon its back, and the dissectors of the abdomen commence work upon the abdominal wall.

## FEMALE PERINEUM.

The boundaries of the female perineum are identical with those in the male (p. 340). The region is wider, however, and of greater extent. For purposes of description it is subdivided, by an imaginary transverse line drawn in front of the anus and the tuberosities of the ischia, into a *posterior, anal triangle*, and an *anterior, urogenital triangle.*

**External Anatomy.**—The anal triangle presents the same points for consideration as in the male. The external anatomy of the urogenital triangle demands careful study, because it includes the external organs of generation. They are—

1. The mons Veneris.
2. The labia majora.
3. The labia minora.
4. The clitoris.
5. The urethral opening.
6. The vaginal orifice.

All these parts are included under the common term of *pudendum muliebre* or *Vulva.*

**Mons Veneris.**—This is a marked cushion-like eminence situated in front of the pubes. The projection is due to

a collection of adipose tissue under the integument. It is covered with hair.

**Labia Majora.**—These correspond to the scrotum, cleft along the middle line. They are two rounded folds, which commence anteriorly at the mons Veneris, where they meet in the anterior commissure, and extend downwards and backwards towards the anus. They diminish in thickness as they proceed backwards, and they meet posteriorly in the posterior commissure. Laterally they are covered by skin studded with scattered hairs, whilst medially they are coated with smooth humid integument, the free surface of which is lubricated by a semi-solid secretion, derived from numerous sebaceous glands which open upon it. During parturition the labia majora are unfolded, and thus give the vagina a greater capability of dilatation.

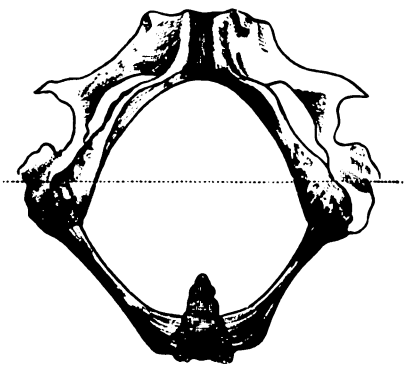

FIG. 137.—Outlet of Female Pelvis.

The labia majora enclose an elliptical fissure, which is termed the *rima pudendi*, or the *urogenital fissure*, on account of its containing the apertures of the urethra and vagina.

**Labia Minora** or **Nymphæ.**—These represent the prepuce, and part of the ventral portion of the penis of the male. They are two pendulous folds of integument which lie between the labia majora. To display them fully the labia majora must be pulled apart. They are placed one on each side of the vaginal orifice. As they pass forwards they become more prominent, and at the same time converge towards one another. When they reach the clitoris, each terminates by splitting into two divisions or folds. The smaller and lower fold is attached to the inferior surface of the clitoris, and receives the name of *frenulum clitoridis*. The upper fold arches over the clitoris like a hood, and unites with the corresponding fold of the opposite side to form the *præputium clitoridis*.

A short distance in front of the posterior commissure the posterior extremities of the labia minora are usually connected

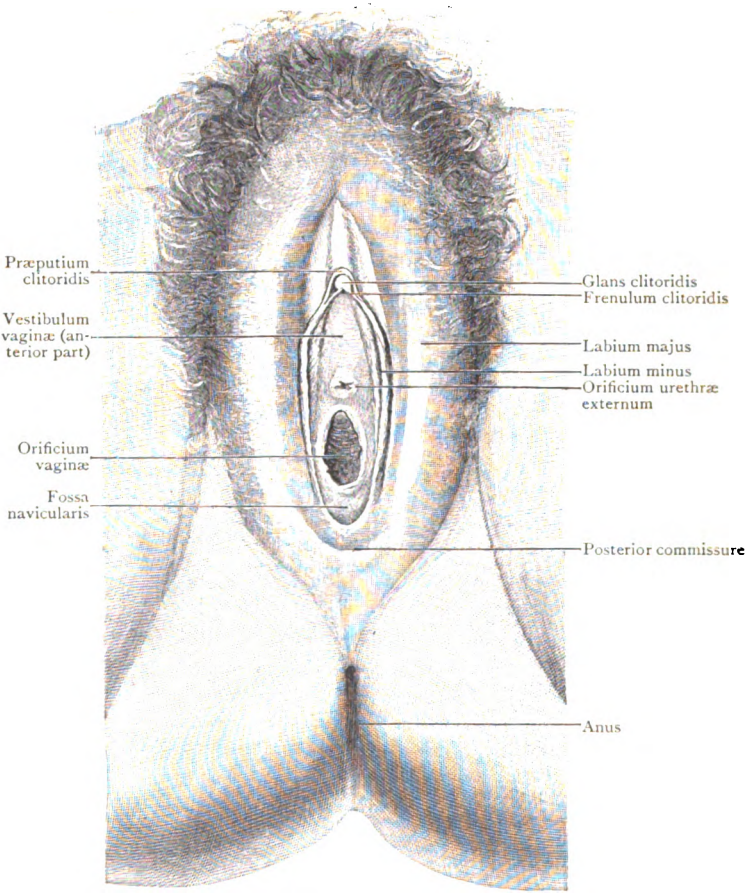


FIG. 138.—Female External Genital Organs.

The frenulum labiorum pudendi is seen stretching across behind the fossa navicularis and in front of the posterior commissure. The ducts of the greater vestibular glands open in the intervals between the vaginal orifice and the medial edges of the labia minora. (Dixon.)

together by a transverse fold, the *frenulum labiorum pudendi*, and immediately anterior to and above this fold, between it

and the posterior border of the orifice of the vagina, is a depression, the *fossa navicularis.*

The frenulum pudendi may be absent, and if present it is usually ruptured during the first labour.

It may be well for the student to bear in mind that the term "perineum" is used by obstetric surgeons in a very restricted sense. It is applied by them to the small region between the anus and the frenulum labiorum pudendi.

**Clitoris.**—The clitoris is the homologue of the penis, and, notwithstanding its diminutive proportions, it presents a close resemblance to the male organ both in appearance and structure. It is a minute elongated projection placed below the anterior commissure, and surmounted by a sensitive rounded tubercle called the *glans*; but it is not traversed by the urethra. The manner in which its prepuce and frenulum are formed has already been described. To obtain a proper view of the clitoris the student must lay hold of the glans with the forceps and draw it out from the prepuce.

**Vestibule.**—The dissector should next take note of a smooth triangular interval which exists between the clitoris and the entrance to the vagina. The term *vestibule* is given to this area. It is bounded laterally by the labia minora, and towards its lower part or base is seen the orifice of the urethra.

The triangular outline of the vestibule is seen only when the labia are forcibly drawn apart from each other. In the natural condition of parts the labia are in close apposition, and the vestibule then forms the deep boundary of that part of the pudendal cleft which lies between the clitoris and the vagina.

**Urethral Orifice.**—This lies close to the opening of the vagina, about one inch below the clitoris. It usually presents the appearance of a vertical slit, and the mucous membrane around it is prominent, pouting, and slightly puckered, so that when the tip of the finger is passed over the vestibular area the opening can readily be distinguished by touch.

**Vaginal Orifice.**—The vaginal opening in the virgin is partially closed by the *hymen*—formed by two semilunar folds of mucous membrane attached to the sides of the entrance to the vagina, and united together anteriorly and posteriorly. The form of the hymen, however, is very variable. Sometimes it is present in the shape of a septum attached around the entire circumference of the vaginal entrance, but

pierced in the centre by a circular opening or an antero-posterior slit; again, it may be cribriform, or fringed along its free margin. Lastly, it may constitute a complete septum across the opening of the vaginal canal. In that case awkward results ensue from the retention of the menstrual fluid. After it has been ruptured its position is marked by certain rounded elevations which have received the name of *caruncul*æ *hymenales.*

Close to each side of the vaginal orifice, in the groove between it and the posterior part of the labium minus, is the opening of the duct of the *greater vestibular* (*Bartholin's*) *gland*, an orifice just visible to the naked eye.

**Passage of Catheter and Examination of Orificium Externum Uteri.**—The dissector should now practise the passing of the female catheter, and afterwards introduce a speculum into the vagina, to obtain a view of the orificium externum uteri.

Before the catheter is passed, the forefinger of the left hand should be placed in the orifice of the vagina, with its palmar surface directed upwards towards the pubes. If the instrument is now directed along this finger and the point raised slightly, when it reaches the entrance to the vagina, a little manipulation will cause it to enter the urethra.

When the speculum is introduced into the vagina, the points to be noted in connection with the external orifice of the uterus are:—(1) the small size of the opening; (2) the two rounded and thick lips which bound the aperture. Both in the virgin and in women who have borne children it is a transverse cleft, but in the former it is small and its anterior and posterior lips are smooth and rounded, whilst in the latter it is usually larger and its lips are frequently cleft and scarred. Note, further, that the anterior lip is the thicker and shorter of the two, whilst the posterior lip is the longer.

**Reflection of Skin.**—The anal canal should be slightly filled with tow, and the vulva and anal orifice stitched up.—*Incisions*—(1) A transverse incision should, in the first place, be carried from one ischial tuberosity to the other, in front of the anus. (2) The urogenital fissure and the orifice of the anus should next be closely encircled by incisions, and these joined by a cut along the median plane. (3) Lastly, carry an incision forwards from the second or third piece of the coccyx along the median plane to the cut which surrounds the anus.

Four flaps are thus marked out; the two anterior may be thrown forwards and laterally, and the two posterior backwards and laterally.

**Superficial Fascia.**—The superficial fascia of the perineum

is now laid bare. In the anal triangle it agrees in every particular with the same portion of fascia in the male (p. 342). In the anterior or urogenital triangle, however, owing to the difference in the external organs of generation, there is a slight modification. It presents the same two layers. In the superficial fatty layer, where it covers the labia majora, there are *dartos fibres* similar to those in the scrotum of the male. The deeper layer has the same attachments as in the male, viz., to the anterior lips of the pubic arch, and to the base of the urogenital diaphragm; but it is not so membranous, and consequently does not form so distinct a stratum. The two fascial pouches are also present in the female, and are sometimes spoken of as the *vulvo-scrotal sacs*. Their separation along the median plane is not due to the interposition of a median septum, as in the male, but to the presence of the urogenital fissure.

### Anal Triangle.

Nothing need be added to what has already been written regarding this portion of the perineal space in the male. In both sexes the steps of the dissection and the parts found are precisely the same (*vide* p. 345).

### Urogenital Triangle.

**Superficial Perineal Vessels and Nerves.** — Under this heading are included:—

*Arteries.*
- The superficial perineal artery.
- The transverse perineal artery.

*Nerves.*
- The posterior labial nerves.
- The long perineal branch of the posterior cutaneous nerve of the thigh.

They have precisely the same disposition as the corresponding vessels and nerves in the male, with the exception, that they are somewhat smaller, and are distributed to the labium majus, instead of to the scrotum. For a detailed description of these structures, the student may refer to p. 350.

*Dissection.*—The superficial perineal vessels and nerves should now be divided and thrown backwards, and the superficial perineal muscles cleaned. These are three in number, viz., the transversus perinei superficialis, the ischio-cavernosus, and the bulbo-cavernosus. The two first have a position similar to the corresponding muscles in the male; the bulbo-cavernosus

lies upon the side of the vagina close to its orifice. To obtain a good view of these muscles the superficial fascia of the labia should be dissected away.

In cleaning the muscles the dissector should look for the small nerve twigs which are given to each by the perineal division of the internal pudendal nerve.

**Superficial Perineal Muscles.**—*The transversus perinei superficialis* has the same disposition as in the male, but it is rare to find it so well marked in the female. In most subjects its

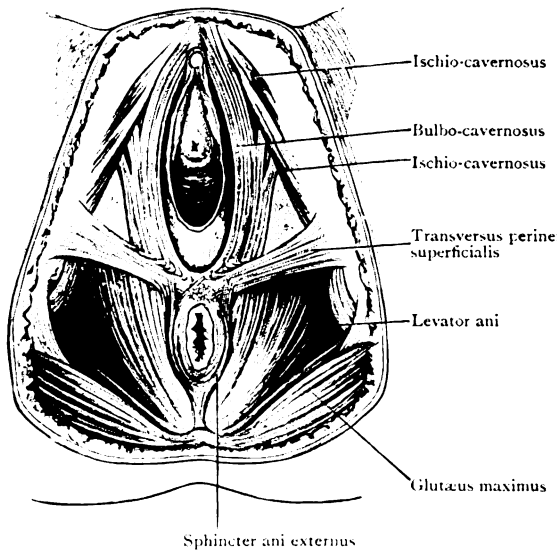


FIG. 139.—Muscles of the Female Perineum (Peter Thompson).

fibres are pale, and it is generally very difficult to define. It is a slender fasciculus which takes origin from the medial surface of the ramus of the ischium, close to the tuberosity, and passes obliquely forwards and medially to its insertion into the central point of the perineum.

In the female the central point of the perineum is placed behind the vaginal orifice.

The *ischio-cavernosus* is much smaller than the corresponding muscle in the male. It arises from the medial aspect of the ischial tuberosity, and is inserted by a tendinous expansion on the surface of the crus clitoridis.

The *bulbo-cavernosus* (O.T. *sphincter vaginæ*) is a true sphincter muscle. It consists of two halves, which are placed one on each side of the vaginal orifice and vestibule, closely adapted to the surfaces of the two halves of the bulb of the vestibule. Posteriorly the fibres of opposite sides unite behind the vaginal opening, and are attached to the central point of the perineum, some of the fibres intermixing with those of the sphincter ani. Anteriorly the two portions of the muscle become narrower, and, converging towards the middle line, are attached to the sides of the clitoris. In some cases a small fasciculus, on each side, may be observed to reach the dorsum of the clitoris and there gain insertion into a tendinous expansion which lies superficial to the dorsal vein. This fasciculus is comparable to the anterior fibres of the bulbo-cavernosus of the male, which embrace the body of the penis.

**Perineal Triangle.**—The dissector should now observe that the three perineal muscles form the sides of a small triangle, the floor of which is constituted by the inferior fascia of the urogenital diaphragm.

**Perineal Body.**—It has been already stated that the term "perineum" is confined by the obstetrician to the narrow interval between the frenulum pudendi and the anus. Now that this part has been dissected, it will be seen to consist of an indefinite mass of fibrous and muscular tissue, which occupies the interval between the anal canal and the vagina. This is known as the *perineal body*. Muscular tissue belonging to the sphincter ani, levatores ani, and bulbo-cavernosus, together with the central point of the perineum, enter into its constitution.

*Dissection.*—The bulbo-cavernosus should now be carefully raised from the surface of the bulb, and the ischio-cavernosus from the surface of the crus clitoridis. The transversus perinei superficialis may be removed at the same time.

**Bulbus Vestibuli.**—The bulb of the vestibule is now displayed. It consists of two oblong bodies, composed of erectile tissue, placed one on each side of the vestibule and entrance to the vagina. Somewhat narrow in front, they expand as they pass backwards, and each is invested by a fibrous capsule derived from the urogenital diaphragm, upon the inferior fascia of which they rest. Laterally each presents a rounded convex surface which is coated with the bulbo-cavernosus muscle, whilst each erectile mass rests, medially,

upon the wall of the vagina. In front of the urethra, between it and the clitoris, the two halves of the bulb are brought into direct communication with each other by a venous plexus called the *pars intermedia*, which, in turn, is continuous with the erectile tissue of the glans clitoridis. To obtain a proper idea of these connections, it is necessary to study specimens which have been specially injected and prepared.

The arrangement of erectile tissue in the female corresponds, more or less closely, with the condition present in the male. The apparent dissimilarity is due to the presence of the urogenital fissure and orifice of the vagina. Suppose, for a moment, that the latter is obliterated and that the vestibule is closed in the form of a canal which carries the urethra forwards to the extremity of the clitoris. The two halves of the bulb would then be in contact with each other, and its entire surface would be covered by a muscular stratum, after the manner of the bulb and bulbo-cavernosus in the male. Further, the urethra would be surrounded by erectile tissue, and the *pars intermedia* would correspond, to some extent, to that portion of the corpus cavernosum urethræ which, in the male, lies in front of the bulb and becomes continuous with the glans penis.

*Dissection.*—If the stitches uniting the lips of the pudendal cleft have not been already removed they should now be taken away. The crura clitoridis have been exposed by the removal of the ischio-cavernosus muscles. To obtain a good view of the entire organ, strip the skin from the body of the clitoris, and clear away the loose tissue which surrounds it. In doing this, however, remember that on its dorsal aspect certain vessels and nerves run forwards to reach the glans, and that suspending it from the front of the pubes there is the suspensory ligament.

**Clitoris.**—The *body of the clitoris* is a cylindrical mass of erectile tissue called the *corpus cavernosum clitoridis*; it is homologous with the structure that bears the corresponding name in the male. Along the middle line it is partially separated into two lateral halves by an imperfect *septum*. The body of the clitoris, which is about an inch and a half long, is bent in a downward direction on itself, at the lower border of the symphysis pubis. Anteriorly it terminates in a small rounded tubercle, which bears the name of the *glans clitoridis*. The glans, however, is not structurally continuous with the corpus cavernosum. It is a little mass of erectile tissue continuous with the pars intermedia, and fitting into a slight concavity which is formed for its reception on the extremity of the

corpus cavernosum. Posteriorly, opposite the lower part of the symphysis pubis, the corpus cavernosum separates into two parts, the *crura clitoridis*, which diverge widely from each other. Each crus is attached by its deep surface to the rami of the pubis and ischium, and is covered by the corresponding ischio-cavernosus muscle.

The clitoris, then, consists of three parts:—(1) *a glans* continuous with the pars intermedia; (2) *a body*; and (3) *two crura*, attached to the sides of the pubic arch. It has been

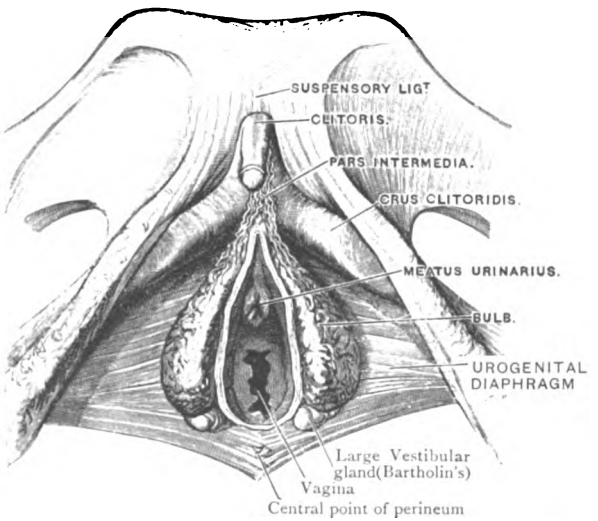


FIG. 140.—Dissection of Female Perineum to show the Clitoris and the Bulb of the Vestibule.

noted that the pars intermedia corresponds with part of the corpus cavernosum urethræ in the male. This apparatus in the female, therefore, closely resembles the penis in the male, the chief differences being the diminutive size of the clitoris, and the fact that the glans clitoridis is not perforated by the urethra.

*Dissection.*—Detach the left crus clitoridis from the side of the pubic arch and throw it aside. This dissection requires care, because the internal pudendal artery, the dorsal nerve of the clitoris, and the small artery which enters the crus, are very apt to be injured. The internal pudendal vessels and the dorsal nerve of the clitoris will be seen piercing the

inferior fascia of the urogenital diaphragm about half an inch below the symphysis pubis, and a little way lateral to the middle line.

**Urogenital Diaphragm.**—A good view is now obtained of the inferior fascia of the urogenital diaphragm (O.T. triangular ligament). Owing to the greater width of the pubic arch, it is a more extensive membrane than in the male (see Fig. 140). It does not possess the same strength, however, and is not so perfect, seeing that it is pierced by the vaginal canal.

In the median plane it is pierced, fully an inch below the symphysis pubis, by the urethra, and, immediately below the urethral opening, by the vagina. Its base is perforated by the superficial perineal vessels and nerves, whilst, on each side, the internal pudendal artery and the dorsal nerve of the clitoris pierce it about half an inch below the symphysis.

The dorsal vein of the clitoris passes backwards through an oval opening between its upper border, the so-called transverse ligament of the pelvis, and the arcuate ligament of the pubis.

As in the male, the urogenital diaphragm consists of the deep transverse muscles of the perineum and the sphincter urethræ membranaceæ, enclosed between a superficial and a deep layer of fascia. Between the two fasciæ lie portions of the urethra and the vagina, and parts of the internal pudendal vessels and the dorsal nerves of the clitoris. The two fascial layers are fused, as in the male, a short distance below the arcuate ligament of the pubis, where their united margins form the transverse ligament of the pelvis, and they are fused posteriorly also, at the base of the diaphragm.

*Dissection.*—The inferior fascia of the urogenital diaphragm should be reflected upon one side. Detach it from the margin of the pubic arch and throw it medially. The structures between the two layers may now be examined.

**Urethra Muliebris.**—The female urethra is a short canal, which extends from the neck of the bladder to its orifice at the base of the vestibule. It measures about one and a half inches in length, and has an oblique and slightly curved course from above downwards and forwards. The concavity of the curve is directed forwards. So close is its relation to the anterior wall of the vagina, that it may almost be said to be embedded in it.

At the present stage of the dissection, the urethral canal is covered by the fibres of the sphincter urethræ muscle.

A special peculiarity of the female urethra is its great dilatability. Cases are on record in which vesical calculi weighing from two to four ounces have traversed it, and thus escaped from the bladder. It thus happens that in the extraction of foreign substances from the female bladder, it is rarely necessary to have recourse to the knife.

**M. Transversus Perinei Profundus** and **M. Sphincter Urethræ Membranaceæ** (O.T. **Compressor Urethræ Muscle**).—The deep transverse muscle of the perineum is less marked in the female than in the male, and is also less distinctly separable from the sphincter of the membranous part of the urethra. It arises laterally from the margin of the pubic arch, at the junction of the ischial and pubic rami, and terminates medially on the lower part of the posterior wall of the vagina. Its anterior fibres blend with the posterior fibres of the sphincter of the urethra. The *sphincter* consists of an internal layer of fibres arranged circularly round the urethra, and an external layer which springs from the pubic arch, anterior to the origin of the deep transverse muscle and from the inferior fascia of the urogenital diaphragm. As the fibres of this layer approach the median plane some pass in front of the vagina and urethra, and others are attached to the posterior wall of the vagina. Both the above muscles are supplied by twigs from the perineal branch of the pudendal nerve.

**Glandulæ Vestibularis Majores** (O.T. **Bartholin's Glands**).—The greater vestibular glands are the representatives of the bulbo-urethral glands of the male. They are two round or oblong bodies, about the size of a bean, placed one upon each side of the entrance to the vagina immediately behind the rounded end of the bulb, and under cover of the bulbo-cavernosus. A long duct proceeds from each gland, and opens in the angle between the labium minus and the hymen or carunculæ hymenales (Fig. 140, p. 373).

**Internal Pudendal Vessels and the Pudendal Nerve.**—The internal pudendal vessels and the pudendal nerve have a disposition similar to the corresponding vessels and nerve in the male (p. 360). If anything, they are somewhat smaller.

The student must therefore look for the *artery to the bulb*, a branch of the internal pudendal, which in this case is given to the bulb of the vagina, and the two terminal branches of the internal pudendal artery, viz., the *dorsal artery of the clitoris*, and the *artery to the corpus cavernosum*.

The pudendal nerve ends by dividing into the perineal nerve and the dorsal nerve of the clitoris.

The *perineal nerve* gives off—(1) the posterior labial branches to the skin covering the labium majus: they correspond with the posterior scrotal nerves in the male; (2) muscular twigs to all the perineal muscles; and (3) a branch to the bulb of the vestibule.

The *dorsal nerve of the clitoris* gives a twig to the corpus cavernosum, and runs forwards with the artery of the same name, between the crura, to reach the dorsum of the clitoris.

**Dorsal Vessels and Nerves of the Clitoris.**—On the dorsum of the clitoris a little dissection will display the *dorsal vein* occupying the groove in the middle line, with a *dorsal artery* and *nerve* lying upon each side of it.

The arteries and nerves should be traced forwards to their distribution in the glans.

The *dorsal vein of the clitoris* takes origin in the glans. As it proceeds backwards it receives certain superficial veins, and also tributaries from the corpus cavernosum clitoridis. At the root of the clitoris it passes between the transverse ligament of the pelvis and the arcuate ligament of the pubis, and is continued backwards into the pelvis, to join the plexus of veins on the wall of the vagina in the region of the neck of the bladder. It communicates also with the internal pudendal vein.

## ABDOMINAL WALL.

After the dissection of the perineum is completed, the body is placed upon its back, with blocks under the thorax and pelvis, and the dissectors of the abdomen begin the dissection of the abdominal wall (Fig. 141).

**External Anatomy.**—It is well, however, before proceeding to the actual dissection of the part, that some attention should be paid to the general configuration and bony prominences of the region. If the subject is obese the abdomen presents a smooth, rounded, and protuberant appearance; if, on the other hand, it is spare, the abdominal wall is depressed, and the lower margin of the thorax above, and the pubes, the iliac crests, and the inguinal ligaments below, stand out in marked relief. In the median plane the student will notice a linear depression, extending downwards towards the symphysis. This corresponds with the *linea alba* or the interval between

the two recti muscles. It is an important line to the surgeon, because here the wall of the abdomen is thin and devoid of blood-vessels. In this line the trocar is introduced into the abdomen in the operation of paracentesis abdominis or tapping.

In the linear depression, rather nearer the pubes than the xiphoid process, is the *umbilicus* or *navel.* This is a depressed and puckered cicatrix, the floor of which is raised in the form of a little button-like knob. It results from the closure of an opening, in the abdominal wall of the fœtus, through which passed the constituents of the umbilical cord, viz. — the umbilical vein, the two allantoic or umbilical arteries, and the stalk of the allantois.

In powerful, well-developed subjects the rectus muscle stands out on each side of the middle line, and its lateral margin gives rise to a curved line, the concavity of which is directed medially. This line corresponds to the *linea semilunaris—i.e.*, the line along which the aponeurotic tendon of the internal oblique muscle splits to enclose the rectus. The linea semilunaris may, on certain occasions, be selected by the surgeon as the site for incisions through the abdominal wall.

The student should now place his finger upon the upper part of the symphysis pubis and carry it laterally, over the pubic crest, to the pubic tubercle; from this he should follow the line of the inguinal ligament (Poupart's) to the anterior superior spine of the ilium, and, having identified those parts, he should next endeavour to determine the position of the subcutaneous inguinal ring (O.T. external abdominal). This is easily done in a male subject. Immediately lateral to the tubercle of the os pubis the spermatic cord can be felt as it passes over the inguinal ligament to reach the scrotum. Taking this as a guide, push the loose skin of the scrotum upwards before the finger. The tip of the finger enters the opening, the sharp margins of which can now be felt.

The spermatic cord, as it passes downwards into the scrotum, should be taken between the finger and thumb. On pressure being applied, the ductus deferens can be easily distinguished at the back of the cord, by the hard whipcord-like feel that it conveys to the fingers.

The crest of the ilium, as it proceeds upwards and backwards from the anterior superior spine, can be easily felt. Indeed, in most cases, it is visible to the eye for a distance

of about two and a half inches. At the point where it disappears from view a prominent tubercle is developed on its external lip. It is there, at the highest point of the iliac crest which can be seen from the front, that the lateral outline of the trunk joins the ilium. As will be seen later, use is made of this fact in subdividing the abdominal cavity into regions.

In females who have borne children the skin over the lower part of the abdomen is wrinkled and scarred.

**Parts to be dissected.**—A dissection of the abdominal wall will display the following parts:—

1. Superficial fascia.
2. Cutaneous vessels and nerves.
3. The external oblique muscle of the abdomen.
4. The internal oblique muscle of the abdomen.
5. The anterior branches of the lower six thoracic nerves and accompanying vessels; the ilio-inguinal and ilio-hypogastric nerves.
6. The transversus abdominis muscle.
7. The rectus and pyramidalis muscles and the sheath of the rectus.
8. The transversalis fascia.
9. The inferior epigastric and deep circumflex iliac arteries.
10. The superior epigastric and musculo-phrenic arteries.
11. The spermatic cord.
12. The inguinal canal.
13. The extra-peritoneal fat.
14. The parietal peritoneum.

**Reflection of Skin.**—*Incisions*—(1) Along the middle line of the body from the xiphoid process to the symphysis pubis. The knife should be carried round the navel so as to surround it with a circular incision. (2) From the xiphoid process transversely round the thorax, as far back as the knife can be carried. (3) From the symphysis pubis laterally, along the line of the inguinal ligament, to the anterior superior spine of the ilium, and then backwards along the crest of the ilium (Fig. 141).

The large flap of skin thus mapped out should be carefully raised from the subjacent superficial fascia and turned laterally. If the abdominal wall is flaccid, the dissection may be facilitated by inflating the abdomen. Make an incision through the umbilicus, large enough to admit the nozzle of the bellows or an injection-pipe fixed to a bicycle-pump, and when the walls are quite tense secure the opening with twine, which should previously be *sewn* round the lips of the incision.

**Panniculus Adiposus (Superficial Fascia).**—The superficial fascia which is now laid bare is seen to present the same appearance, and possess the same characters, as in other localities. Above, it is thin and weak, and is directly continuous with the corresponding fascia over the thorax; below, it becomes more strongly marked, and acquires a greater density. Towards the lower part of the abdomen the superficial fascia develops special characters; it consists of two

layers—a fatty superficial stratum called *Camper's fascia*, and a deep membranous stratum termed *Scarpa's fascia*.

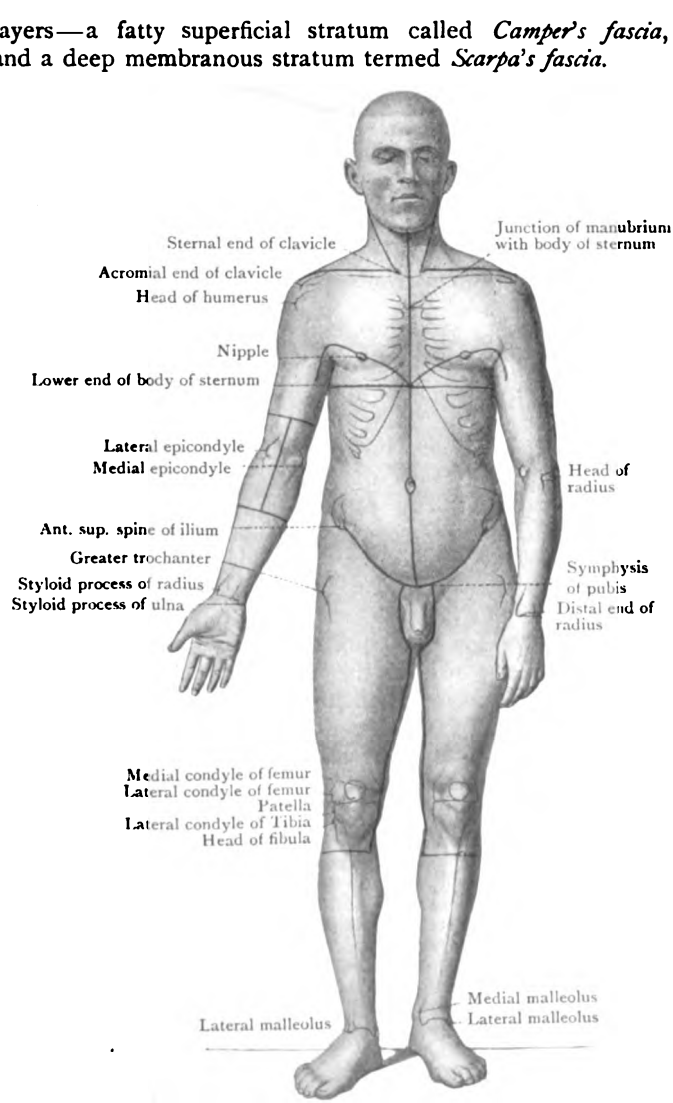


FIG. 141.—Surface view, with Incisions and Bony Points.

There is another point, however, in which the superficial

fascia differs somewhat from the same fascia in other parts of the body. It is more elastic, and this elasticity is due to the presence of elastic fibres in its deeper membranous part. Over the lower part of the linea alba the elastic tissue is collected in the form of a distinct band which, in the region of the symphysis pubis, becomes connected with the penis and its suspensory ligament. A reference to comparative anatomy gives interest to this fact. In the human subject this elastic band is the rudimentary representative of a continuous and distinct layer of yellow elastic tissue (*the abdominal tunic*) which is present in the horse and other quadrupeds in which the weight of the viscera is sustained chiefly by the abdominal wall.

When the two layers of the superficial fascia are followed downwards from the front of the abdomen, the fatty layer of Camper passes over the inguinal ligament and becomes directly continuous with the fatty superficial fascia on the front of the thigh. The relations of the fascia of Scarpa are very different. In the region of the pubes it is carried continuously downwards over the spermatic cords, the penis and scrotum, into the perineum, where it becomes continuous with the fascia of Colles. On the lateral side of the spermatic cord, in the region of the groin, it proceeds downwards, and ends, immediately distal to the inguinal ligament, by blending with the fascia lata of the thigh.

These connections of the fascia of Scarpa are so important that it is necessary to undertake a special dissection, in order that they may be demonstrated. As this encroaches somewhat upon the region of the thigh, it must be done in conjunction with the dissector of the lower extremity. A transverse incision should be made through the entire thickness of the superficial fascia on the front of the abdomen from the anterior superior spine of the ilium to the median plane of the abdomen. On raising the inferior edge of the divided fascia the two layers can be easily distinguished. Insinuate the fingers between the fascia of Scarpa and the subjacent pearly-looking tendon of the external oblique muscle. Little resistance will be met, as the fascia of Scarpa is bound down only by some lax areolar tissue. As the superficial fascia is thus raised from the aponeurosis of the external oblique, the anterior cutaneous branch of the ilio-hypogastric nerve will be seen piercing the aponeurosis and entering the deep surface of the superficial fascia, a little way above the subcutaneous inguinal ring. The fingers can be readily passed downwards behind the fascia of Scarpa as far as the inguinal ligament. There it will be found that they can force their way no farther. The passage of the hand into the thigh is barred by the blending of the fascia of Scarpa with the fascia lata of the thigh. At that level the fascia of Scarpa ceases to exist; it loses its identity by becoming fused with the deep fascia of the thigh along the line of, and immediately distal to, the inguinal ligament.

Towards the pubes the finger can be pushed downwards behind the fascia of Scarpa and along the spermatic cord into the perineum. No barrier opposes the passage of the finger in this direction. The continuity of the fascia of Scarpa and the fascia of Colles is thus demonstrated.

If the dissector now recalls the fact that, in the urethral triangle of the perineum, the fascia of Colles is attached laterally to the margins of the pubic arch, and posteriorly to the base of the urogenital diaphragm, whilst above the level of the pubic crests it is continuous with the fascia of Scarpa on the front of the abdominal wall, he will have little difficulty in understanding the course which urine takes when extravasated from a rupture of the urethra in front of the urogenital diaphragm. The effused fluid is directed upwards into the scrotum over the penis, and along the spermatic cords to the front of the abdomen. From the abdomen it cannot pass downwards to the front of the thighs, owing to the attachment of Scarpa's fascia to the fascia lata. Unless vent be given to it by early and free incisions, it will continue to ascend over the abdomen.

**Cutaneous Nerves.**—A dissection must now be made of the cutaneous nerves of the abdomen. These are arranged on the same plan as the cutaneous nerves of the thorax. We have therefore to look for an *anterior* and a *lateral series.*

| | |
|---|---|
| Anterior series. | 1. Anterior cutaneous nerves.<br>2. Anterior cutaneous branch of the ilio-hypogastric nerve.<br>3. The ilio-inguinal nerve. |
| Lateral series. | 1. Lateral cutaneous nerves.<br>2. Lateral cutaneous branch of the last thoracic nerve.<br>3. Lateral cutaneous branch of ilio-hypogastric nerve. |

The *anterior cutaneous nerves* are the small terminal twigs of the lower five or six thoracic nerves. They pierce the aponeurotic sheath of the rectus muscle at variable points, some close to the median line and others a little distance from it. After entering the superficial fascia they run for a short distance laterally.

To find these nerves, the best plan to adopt is to divide the superficial fascia along the middle line, and reflect it cautiously laterally. The small arteries which accompany the nerves serve as guides.

The *anterior cutaneous branch* of the ilio-hypogastric lies in series with the preceding. In the dissection of the superficial fascia it has been seen piercing the aponeurosis

of the external oblique immediately above the subcutaneous inguinal ring.

The *ilio-inguinal nerve* comes out through the subcutaneous

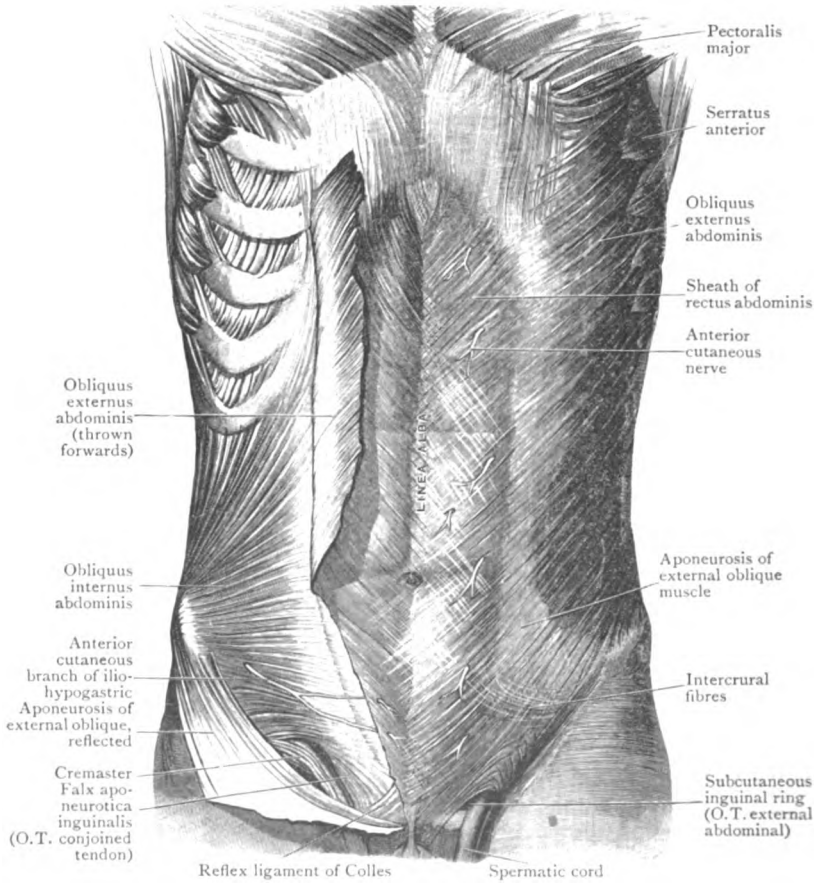


FIG. 142.—Dissection of Anterior Wall of the Abdomen.
The obliquus externus abdominis has been reflected on the right side.

inguinal ring, and is distributed to the integument of the scrotum and the medial aspect of the thigh.

The *lateral cutaneous nerves* are branches of the lower six thoracic nerves. They become superficial between the

digitations of the external oblique muscle, and then each divides into an anterior and posterior division. The *posterior divisions* are small, and are directed backwards over the latissimus dorsi. The *anterior divisions* run forwards, and a careful dissector may trace them as far as the lateral margin of the rectus abdominis.

The *lateral cutaneous branch of the last thoracic nerve* differs from the other members of the series in not dividing into an anterior and a posterior division, and in being destined for the supply of the integument over the gluteal region. It pierces the external oblique muscle, in a line with the other lateral nerves, and is then directed downwards over the crest of the ilium. It crosses the iliac crest from one to two inches behind the anterior superior spine.

The *lateral branch of the ilio-hypogastric nerve* also is distributed to the skin of the gluteal region. It pierces the external oblique immediately above the iliac crest, which it crosses usually opposite the tubercle which projects from the external lip of the crest, about two and a half inches behind the anterior superior spine of the ilium.

**Arteriæ Cutaneæ (Cutaneous Arteries).** — Cutaneous arteries are found accompanying the cutaneous nerves. Those which are associated with the lateral cutaneous nerves are branches of the *aortic intercostal arteries*, whilst those in relation to the anterior cutaneous nerves are derived from the *superior* and *inferior epigastric arteries*.

In addition to these, *three* small branches of the femoral artery ramify in the superficial fascia of the groin.

These are—

1. The superficial external pudendal.
2. The superficial epigastric.
3. The superficial circumflex iliac.

They take origin in the thigh, a short distance distal to the inguinal ligament, and, piercing the fascia lata, diverge from each other in the superficial fascia.

The *superficial external pudendal* is directed medially over the spermatic cord. It gives branches to the skin of the scrotum and inferior surface of the penis.

The *superficial circumflex iliac* proceeds laterally and upwards along the line of the inguinal ligament (Poupart's), and ends in the skin in the neighbourhood of the anterior superior spine of the ilium.

The *superficial epigastric* takes a vertical course upwards, and, crossing the inguinal ligament, ramifies in the superficial fascia over the inferior part of the abdomen. Its branches extend as high as the level of the umbilicus.

The small *veins* which accompany these arteries open into the great saphenous vein.

**Muscles of the Abdominal Wall.**—The abdominal wall is formed anteriorly and laterally by *five pairs of muscles*, and by the aponeuroses which constitute their tendons. *Anteriorly* are the two recti muscles and the two pyramidales muscles. The recti are placed parallel to the middle line, and extend in a vertical direction from the pubic bones to the lower margin of the thorax. *On each side* three fleshy and aponeurotic strata are met with. From the surface towards the abdominal cavity they are—(1) the external oblique muscle; (2) the internal oblique muscle; (3) the transversus abdominis muscle. The direction taken by the muscular fibres which compose each of these layers is different. The external oblique corresponds in this respect with the external intercostal muscles; the fibres proceed obliquely downwards and forwards. Again, the internal oblique resembles the internal intercostal muscles in the direction of its fibres; they are directed upwards and forwards; thus the fibres of the two oblique muscles cross each other like the limbs of the letter X. Lastly, the fibres composing the transversus abdominis muscle pursue a horizontal or transverse course.

This difference of direction in the fibres which compose these three strata is a source of strength to the fleshy part of the abdominal wall, which, consequently, offers a strong barrier to the protrusion of any of the abdominal contents. The two oblique muscles and the transversus are prolonged to the middle line in the form of aponeuroses. The union of these with the corresponding aponeuroses of the opposite side forms the *linea alba*—a strong band which extends, in the median line, from the symphysis pubis to the xiphoid process.

*Dissection.*—Remove the superficial fascia from the front of the abdomen. This will expose the aponeurosis of the external oblique muscle. Towards the thorax this aponeurosis is very thin, and is liable to injury, unless the dissection is performed with care. Proceed cautiously also at the lower part of the abdomen, above the medial end of the inguinal ligament. There the aponeurosis is pierced in the male by the spermatic cord. The lips of the opening thus formed are prolonged downwards upon the cord in the

form of a thin membrane called the *external spermatic fascia*. In defining this, the blade of the knife must not be used. Work entirely with the handle. The thin layer of deep fascia which is spread over the muscular part of the external oblique muscle must also be removed. In doing this it is not necessary to carry the knife in the direction of the fleshy fasciculi. Indeed, the muscle can best be cleaned by carrying the knife at right angles to the general direction of the fibres. In front, the deep fascia will be seen to blend with the aponeurosis of the muscle, along the line of junction between the tendinous and fleshy fibres. The slips of origin of the external oblique muscle from the lower eight ribs must each be carefully defined.

**M. Obliquus Externus Abdominis (External Oblique).** — The external oblique muscle arises by *eight* pointed processes or digitations from the outer surfaces and lower borders of the lower eight ribs (Fig. 142). Of these, the *upper three* interdigitate with the digitations of the serratus anterior, and the latissimus dorsi interdigitates with the *lower four*. From this origin the fibres proceed downwards and forwards, with varying degrees of obliquity. The *posterior fibres* have a nearly vertical direction, and are inserted into the anterior half of the external lip of the crest of the ilium. The *superior fibres* are almost horizontal, and the *intermediate fibres* are directed obliquely downwards and forwards, and all end in a strong aponeurosis called the *aponeurosis of the external oblique*.

FIG. 143.—Crest of the Ilium as seen from above (semi-diagrammatic), with Attachments of Muscles mapped out.

*Superiorly* the aponeurosis of the external oblique is very thin, and is carried forwards to be attached to the xiphoid process. It is from this part that the pectoralis major derives fibres of origin. *Inferiorly* the aponeurosis is folded upon itself to form the inguinal ligament, which is attached laterally and superiorly to the anterior superior spine of the ilium, and medially and inferiorly to the tubercle of the pubis. *Between the upper and lower attachments* the aponeurosis lies in front of the rectus, and is inserted into the linea alba and into the front of the os pubis.

In connection with this aponeurosis, note that it is broadest

and strongest inferiorly, that it is narrowest about the level of the umbilicus, and that it widens somewhat again towards the ribs. Superiorly it is so thin that the fibres of the rectus muscle shine through it.

**Annulus Inguinalis Subcutaneus** (O.T. **External Abdominal Ring**) (Figs. 144 and 145).—In the male, the aponeurosis of the external oblique is pierced, immediately above the pubis, by the spermatic cord; in the female, it is pierced, at the same point and in the same manner, by the round ligament of the

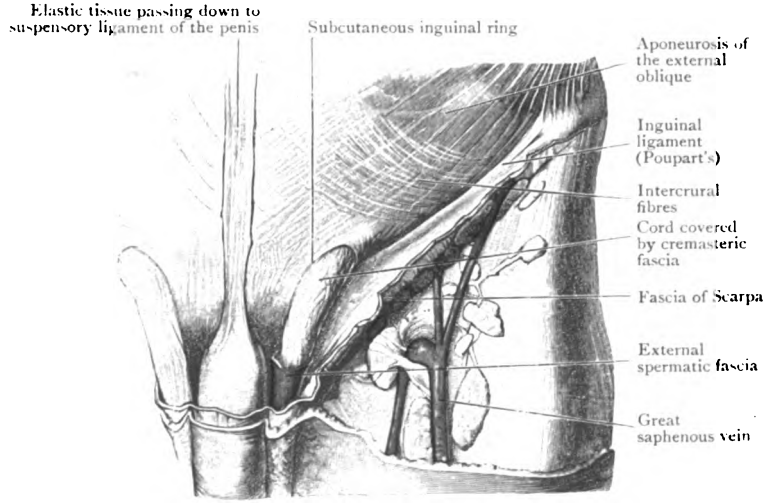
Elastic tissue passing down to suspensory ligament of the penis
Subcutaneous inguinal ring
Aponeurosis of the external oblique
Inguinal ligament (Poupart's)
Intercrural fibres
Cord covered by cremasteric fascia
Fascia of Scarpa
External spermatic fascia
Great saphenous vein

FIG. 144.—Dissection of the Subcutaneous Inguinal Ring and the parts in its vicinity.

uterus. The aperture which is thus formed receives the name of the *subcutaneous inguinal ring*. At the present stage of the dissection this opening is not visible, because a thin fascial covering is carried downwards from its lips upon the spermatic cord or upon the round ligament of the uterus. This is called the *external spermatic* or the *intercrural fascia*. If the cord is raised and rendered tense, this covering will be observed to invest it completely, and to be somewhat funnel-shaped—wide above, but closing upon the cord as it is traced downwards.

With the point of the knife divide the external spermatic

fascia around the cord, and then, with the handle, define the margins of the subcutaneous inguinal ring. When this is done, the dissector will observe that the term "ring," as applied to this opening, is apt to convey to the mind an erroneous impression. It is not circular, but triangular, in shape. The direction of the opening is very oblique, the base of the

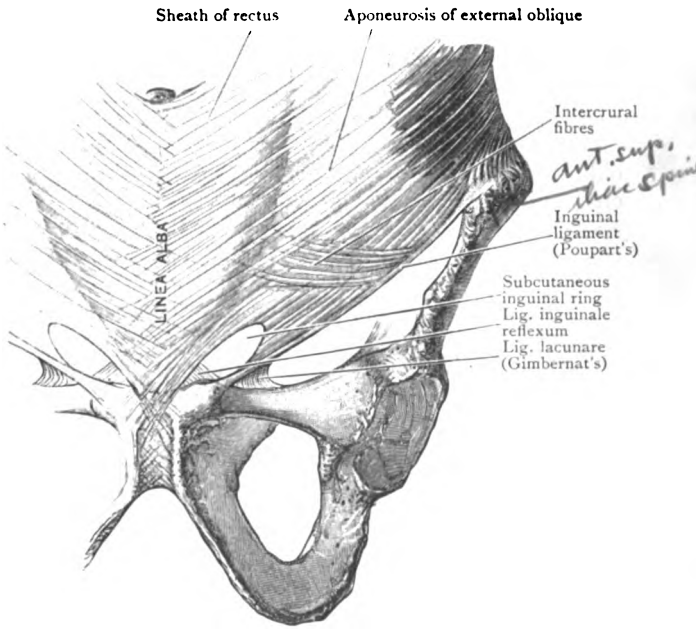


FIG. 145.—Dissection to show the connections of the inferior part of the Aponeurosis of the External Oblique Muscle.

triangle being formed by the crest of the pubis, whilst the apex is directed laterally and slightly upwards.

The subcutaneous inguinal ring, therefore, is merely a small gap or interval left between that portion of the aponeurosis of the external oblique muscle, which forms the inguinal ligament, and that portion which is inserted into the front of the pubic bone. The margins of the aperture are termed *the crura of the ring*. The *superior crus* is flat and broad, and is attached to the symphysis pubis. Some of its fibres cross the median plane, decussate with the corre-

sponding fibres of the other side, and are inserted into the front of the opposite pubic bone. The *inferior crus* is merely the medial end of the inguinal ligament. It is, therefore, thick and strong, and is fixed to the pubic tubercle. The spermatic cord, as it issues from the subcutaneous inguinal ring, rests upon the inferior crus.

The *size* of the subcutaneous inguinal ring is very variable. In the male, the average length may be said to be one inch, and the breadth about half an inch. In the female, it is much smaller; and the round ligament of the uterus, which passes through it, ends in the superficial fascia of the groin.

On a close inspection of the lower part of the external oblique aponeurosis, the student will observe a number of cross fibres arching over its surface. These are called the *fibræ intercrurales*, and in some cases they are very strongly marked. They begin at the inguinal ligament, close to the iliac spine, and curve upwards and medially, upon the aponeurosis, above the subcutaneous inguinal ring. The function of these fibres is very evident, and the term "*intercrural*" is derived from the part which they play. They bind together the two crura of the ring, and prevent their further separation. There is a direct continuity between the intercrural fibres and the external spermatic fascia, which clothes the cord, and consequently, as already stated, the term "intercrural fascia" is frequently applied to the external spermatic fascia.

**Reflection of the Obliquus Externus.**—Between the last rib and the crest of the ilium the posterior border of the external oblique muscle is free, and as this border will be examined when the body is placed on its face it must not be disturbed at present. Begin by detaching the upper six serrations of the muscle from the ribs; from the interval between the sixth and seventh serrations carry an incision downwards, through the fibres of the muscle, to the posterior border of the tubercle on the external lip of the iliac crest. Raise the anterior portion of the muscle from the surface of the subjacent internal oblique and turn it medially, dividing the fleshy fibres inserted into the iliac crest close to the bone. Next, divide the aponeurosis horizontally, in a line leading from the anterior superior spine to the lateral border of the rectus. The greater part of the muscular and aponeurotic portion of the external oblique can now be thrown medially. The dissector must proceed with care on approaching the lateral border of the rectus, because a little beyond that the anterior lamella of the aponeurosis of the internal oblique fuses with the deep surface of the aponeurosis of the external oblique. Define the line of union, and notice that it does not extend beyond the lower margin of the thorax. Above that the rectus is covered merely by the aponeurosis of the external oblique; its lateral margin in this locality is bare, and the hand can be freely passed between it and the costal cartilages.

On the *left side* of the body, the parts below the horizontal line drawn from the anterior superior iliac spine to the lateral border of the rectus, along which the aponeurosis of the external oblique muscle has been divided, should be preserved intact for the special study of the structures associated with inguinal hernia. On the *right side* of the body, divide the lower part of the aponeurosis along the lateral border of the rectus down to the pubis. This incision should pass to the medial side of the superior crus of the subcutaneous inguinal ring, so that that opening may be preserved. The triangular flap of aponeurosis must now be thrown downwards and laterally. By this proceeding the inguinal ligament, the internal oblique muscle, and the cremaster muscle are displayed for study.

**Ligamentum Inguinale** (O.T. **Poupart's Ligament**).—The inguinal ligament is merely the thickened lower border of the aponeurosis of the external oblique folded backwards upon itself. It thus presents a rounded surface towards the thigh and a grooved surface towards the abdominal cavity. The manner in which it is attached by its lateral and medial extremities deserves the close study of the dissector. *Laterally* it is fixed to the anterior superior spine of the ilium; *medially* it has a double attachment, viz.—(1) to the pubic tubercle, which may be considered as its attachment proper; (2) through the medium of the lacunar ligament (*Gimbernat's*) to the pecten pubis (ilio-pectineal line).

The inguinal ligament does not pursue a straight course between its iliac and pubic attachments. It describes a curve, the convexity of which is directed downwards and laterally towards the thigh. By its inferior border it gives attachment to the fascia lata. When this is divided, the inguinal ligament at once loses its curved direction.

**Ligamentum Lacunare** (O.T. **Gimbernat's Ligament**) (Fig. 145).—This is a triangular process of aponeurotic membrane. Raise the spermatic cord, place the finger behind the medial end of the inguinal ligament, and press downwards. The structure upon which the finger rests is the ligament in question, and the student should note that, at this point, it offers a barrier to the passage of the finger into the thigh. With the handle of the knife, its shape and connections can be easily defined. Its *apex* is fixed to the pubic tubercle; by *one margin* it is attached to the medial part of the inguinal ligament; by its *other margin* it is inserted for the distance of an inch into the pecten pubis. Its *base* is sharp, crescentic, and free, and is directed laterally towards the femoral sheath. The dissector should thoroughly realise that the lacunar ligament is not an independent structure.

It is merely the medial part of the folded-back margin of the inguinal ligament which, in the vicinity of the pubic tubercle, obtains an attachment to bone.

The lacunar ligament occupies an oblique plane, its lower or femoral surface looking distally and slightly forwards and laterally, whilst its upper or abdominal surface looks upwards and slightly backwards and medially. It is of importance that the student should note the precise relation which this ligament bears to the spermatic cord. Taken in conjunction with the inguinal ligament and the aponeurosis of the external oblique, it forms a groove in which the cord lies.

**Ligamentum Inguinale Reflexum** (O.T. **Triangular Fascia**) (Fig. 145).—The reflex inguinal ligament is a small triangular sheet of fibres which springs from the crest of the pubic bone and the medial end of the pecten pubis. It passes upwards and medially, under cover of the superior crus of the subcutaneous inguinal ring, and passes into the linea alba. If the fibres which compose it are followed through the linea alba, they will be found to be continuous with the fibres of the aponeurosis of the external oblique muscle of the opposite side. It must, therefore, be considered as an additional insertion of that muscle. It is, frequently, so poorly developed that its true relations and connections are demonstrated with difficulty, if indeed they are capable of demonstration at all.

*Dissection.*—The internal oblique muscle should now be cleaned. Towards its lower part it will be seen to be pierced by certain nerves, and these must be preserved. Close to the iliac crest the *lateral branches* of the ilio-hypogastric and last thoracic nerves will be noticed emerging from the midst of its fleshy fibres, whilst anteriorly it is pierced by the *anterior branch* of the ilio-hypogastric and by the *ilio-inguinal nerve*. The former of these appears near the anterior superior iliac spine, and then proceeds medially under cover of the external oblique aponeurosis, which it soon pierces. The ilio-inguinal nerve will be found perforating the internal oblique a short distance medial to the hypogastric nerve and at a lower level. It becomes superficial by passing through the subcutaneous inguinal ring.

Care must be taken in defining the inferior margin of the muscle to preserve its relations to the spermatic cord, and not to injure the muscular fasciculi which it gives to the cremaster muscle.

**M. Obliquus Internus Abdominis (Internal Oblique)** (Fig. 142).—The internal oblique muscle *arises*—(1) from the lateral half of the abdominal grooved surface of the inguinal ligament; (2) from the intermediate line of the anterior two-thirds of the iliac crest; (3) from the lumbar fascia.

From these origins the muscular fibres radiate, but the general direction is from below upwards and medially. The *posterior fibres* ascend, and are inserted into the lower borders of the cartilages of the lower four ribs. These fibres occupy the same plane as the internal intercostal muscles—indeed, they will be observed to be directly continuous with the fibres of the internal intercostal muscles of the lower two spaces. The *lowest fibres*, those springing from the inguinal ligament, arch downwards and medially, and join with the lowest fibres

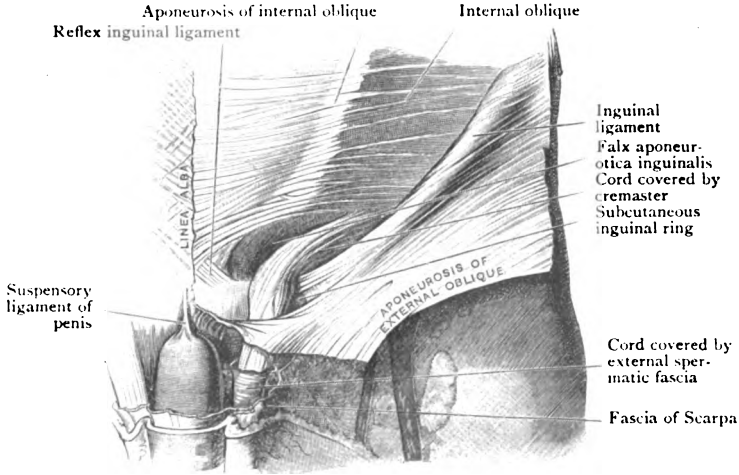


FIG. 146.—Dissection of the Inguinal Region.
The aponeurosis of the external oblique is turned down.

of the transversus in a flat tendon, called the *falx inguinalis* (O.T. *conjoined tendon*), which is inserted into the pubic crest, and into the pecten pubis, for fully half an inch of its extent, behind the lacunar ligament and the reflex inguinal ligament, (Figs. 142 and 146). The *intermediate fibres* proceed upwards and medially, and end in a strong aponeurosis, which extends from the inferior margin of the thorax to the pubis. By this aponeurosis they gain insertion into the inferior borders of the cartilages of the seventh and eighth ribs and the xiphoid process, and into the linea alba throughout its entire length. The manner in which the aponeurosis reaches the middle line requires special description.

At the lateral margin of the rectus muscle the aponeurosis of the internal oblique splits into two layers—a superficial and a deep. The *superficial layer of the aponeurosis* passes in front of the rectus, and has already been seen to fuse with the aponeurosis of the external oblique muscle. The *deep layer* is carried medially behind the rectus, and becomes incorporated with the subjacent aponeurosis of the transversus muscle. But this arrangement does not hold good lower down than a point about midway between the umbilicus and the pubis. Below that point the aponeurosis does not split, but passes entirely in front of the rectus to join the aponeurosis of the external oblique.

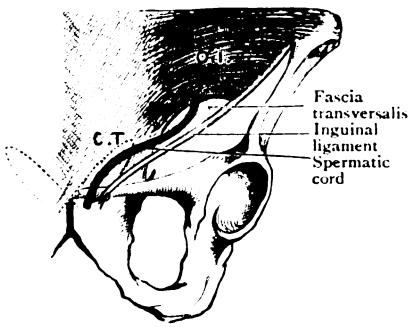


FIG. 147.—Diagram to illustrate the relation of the lower border of the Internal Oblique Muscle to the Cord, the Falx Inguinalis, and the Inguinal Canal.

O.I. Internal oblique muscle.
C.T. Falx Inguinalis.

The position of the subcutaneous inguinal ring is indicated by a dotted outline.

It is important to mark exactly the relation which the inferior part of the muscle bears to the spermatic cord. At first the cord lies behind the fleshy fibres, but it soon emerges, clothed by the cremaster muscle, and, as it is continued downwards and medially to the subcutaneous inguinal ring, it lies in front of the falx aponeurotica inguinalis (O.T. conjoined tendon). Especially note the position of the falx inguinalis in relation to the subcutaneous inguinal ring. It lies immediately behind it, and gives strength to this otherwise weak point in the abdominal parietes.

**M. Cremaster.** — This muscle supports the testis and spermatic cord, and is consequently peculiar to the male. It *arises* from the medial part of the inguinal ligament, and it derives fibres also from the inferior border of the internal oblique (rarely from the inferior border of the transversus abdominis muscle). The fleshy fibres descend upon the lateral and anterior aspects of the cord in the form of loops, the concavities of which are directed upwards. The depth to which

these loops descend varies. Some reach the tunica vaginalis of the testis, and the scrotum should now be opened up, on the right side, in order that they may be traced downwards to that point; the majority of the fibres, however, do not reach so far down, some going no farther than the subcutaneous inguinal ring. Upon the posterior aspect of the cord the loops are directed upwards, and some, reaching the os pubis, obtain a tendinous insertion into its tubercle and crest.

It will be noticed that the cremasteric fleshy loops do not form a complete investment for the cord and testis. The intervals between the fasciculi are occupied by areolar tissue, and this combination of muscular and areolar tissue is sometimes termed the *cremasteric fascia.*

**Reflection of Internal Oblique.**—On the *right* side of the body the entire muscle may be reflected, but on the left side preserve the inferior portion of it (*i.e.*, that part which is still covered by the aponeurosis of the external oblique) *in situ.* Begin below by dividing the muscular fibres along the crest of the ilium. The depth to which the knife should be carried is indicated by the dense areolar tissue which lies between the internal oblique and the subjacent transversus muscle. An ascending branch from the deep circumflex iliac artery also will serve as a guide. This vessel emerges from the fibres of the transversus muscle, close to the anterior part of the iliac crest, and is then directed upwards upon its surface. Although this vessel has not attained the dignity of a name, it is a very constant branch. On the right side the fibres springing from the inguinal ligament should also be severed, but on the left side carry the knife horizontally, from the anterior superior spine of the ilium to the lateral margin of the rectus. Now turn to the upper part of the muscle, and make an incision through it, along the lower margin of the thorax, from the lateral border of the rectus to the last rib. Lastly, carry the knife downwards, from the tip of the last rib to the crest of the ilium.

The muscle freed in this manner can be thrown medially towards the lateral border of the rectus. In doing this the dissector must proceed with caution, because he has reached the plane of the main trunks of the nerves of the abdominal wall and the arteries which accompany them. These pass medially between the internal oblique and the transverse muscles, and, as the former muscle is raised, they are apt to adhere to its deep surface and be cut.

In all probability the student will experience considerable difficulty in separating the lowest part of the internal oblique from the corresponding portion of the transversus abdominis. At that level the two muscles are always closely connected, and in some cases they may be even found to be partially blended.

The *cremaster muscle* should also be reflected from the spermatic cord. This can best be done by making a longitudinal incision along it. Entering the deep surface of the cremaster are a small *branch of the inferior epigastric artery* and the *external spermatic nerve* (*a branch of the genito-femoral*). These constitute its vascular and nervous supply, and must, if possible, be secured. Now clean the transversus abdominis muscle, and dissect out the vessels and nerves which lie upon it.

**Nerves of the Abdominal Wall.**—The dissector will find the following nerves running forwards upon the transversus abdominis muscle:—

1. The anterior branches of the lower seven thoracic nerves.
2. The ilio-hypogastric nerve. } From the anterior branch of the first
3. The ilio-inguinal nerve. } lumbar nerve.

The *lower seven thoracic nerves* enter the abdominal wall at the margin of the costal arch, where they insinuate themselves between the internal oblique and the transversus abdominis muscle. Then they run to the lateral border of the rectus muscle, where they disappear by piercing, and passing within, the sheath of the muscle. In a subsequent dissection they will be observed sinking into the substance of the rectus, supplying it with twigs, and then turning forwards to pierce the sheath a second time. They end on the front of the abdomen as the *anterior cutaneous nerves.* Midway between the vertebral column and the linea alba they give off the *lateral cutaneous branches.* They supply offsets also to the transversus abdominis and two oblique muscles. Minute arteries accompany these nerves.

The *last thoracic nerve* also supplies the oblique and transverse muscles, and, in addition, it gives a branch to the pyramidalis muscle. Its *lateral cutaneous* or *iliac branch*, however, goes to the skin of the buttock.

The *ilio-hypogastric* and *ilio-inguinal* are the lowest two nerves of the series. They are directed forwards between the internal oblique and the transversus, close to the crest of the ilium.

The ilio-hypogastric is the higher of the two. It gives off an *iliac* or *lateral cutaneous branch*, which pierces the two oblique muscles, and then crosses the crest of the ilium to reach the skin of the gluteal region. The *anterior portion* of the nerve perforates the internal oblique, a short distance in front of the anterior superior spine of the ilium, and then runs forwards towards the linea alba. It does not enter the sheath of the rectus, but becomes superficial by piercing the aponeurosis of the external oblique immediately above the subcutaneous inguinal ring.

The *ilio-inguinal nerve* gives off no lateral branch. It pierces the internal oblique, to which it gives branches, a short distance above the inguinal ligament, and it becomes superficial by passing through the subcutaneous inguinal ring.

**M. Transversus Abdominis** (O.T. **Transversalis Muscle**). —This is the deepest of the three muscular strata which enter into the formation of the wall of the abdomen. It has a threefold origin, viz.—from the pelvis, from the vertebral column, and from the costal cartilages. By its *pelvic origin* it is attached to the lateral third of the inguinal ligament and to the anterior two-thirds of the internal lip of the crest of the ilium; by its *costal origin* it arises from the inner surfaces of the costal cartilages of the lower six ribs, by a series of slips or digitations which interdigitate with the slips of origin of

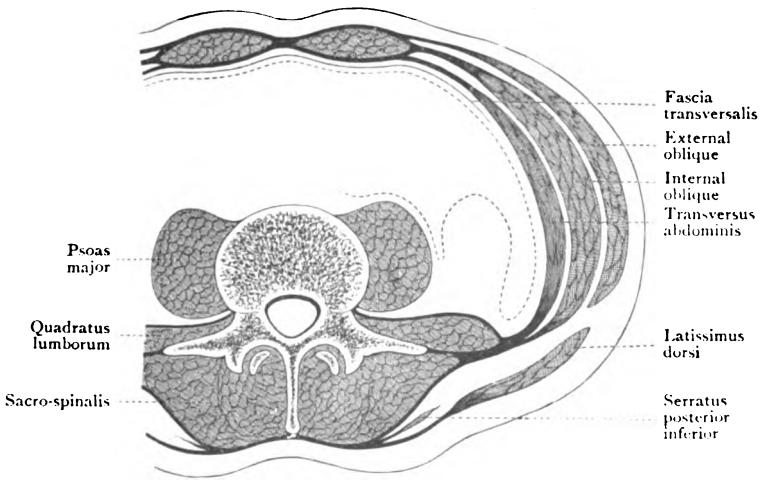


FIG. 148.—Lumbo-dorsal fascia and sheath of Rectus abdominis. The dotted line represents the Peritoneum.

the diaphragm; by its *vertebral origin* it is attached, through the medium of the lumbo-dorsal fascia, to the spinous processes, and the tips and roots of the transverse processes, of the lumbar vertebræ. Indeed, the lumbo-dorsal fascia constitutes the posterior aponeurosis of this muscle. The manner in which this fascia is attached to the vertebræ needs further explanation. As it approaches the vertebral column it splits into three layers or lamellæ; of these the *posterior lamella* is attached to the tips of the spinous processes, the *anterior lamella* to the roots of the transverse processes, and the *intermediate lamella* to the tips and adjacent sides of the transverse processes. Two compartments are thus formed,

the posterior of which is occupied by the sacro-spinalis (O.T. erector spinæ), whilst in the anterior is placed the

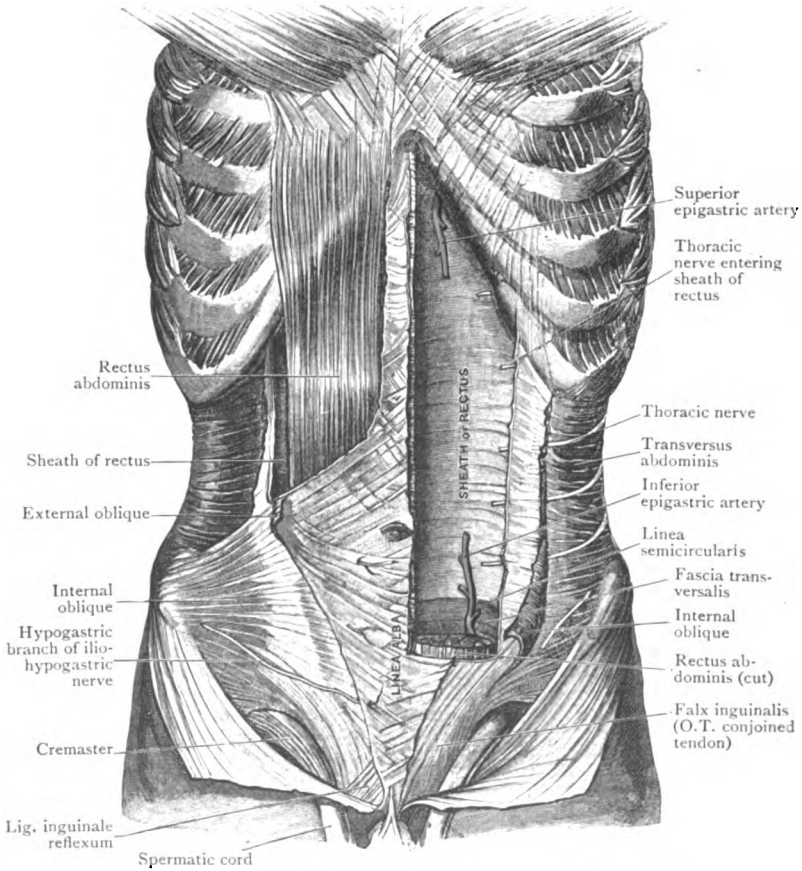


FIG. 149.—Deep dissection of the Anterior Wall of the Abdomen. On the *left side* the external oblique and the internal oblique have for the most part been removed, the sheath of the rectus opened, and the greater part of the contained muscle removed. On the *right side* the external oblique, the upper part of the internal oblique, and the upper part of the anterior wall of the sheath of the rectus have been removed.

quadratus lumborum. These are points which cannot be demonstrated in this dissection, but a reference to Fig. 148 will help the student to understand the arrangement.

Anteriorly, the fibres of the transversus abdominis muscle end in a strong aponeurosis, which is inserted into the linea alba, the pubic crest, and the ilio-pectineal line. Towards the aponeurosis the fleshy fibres for the most part run in a transverse direction. The lower fibres, however, take a curved course downwards and medially, so that the muscle presents an arched lower margin.

The dissector has already seen that the lowest portions of the aponeuroses of the internal oblique and the transverse muscles blend to form the *falx inguinalis* (O.T. *conjoined tendon*). It is through the medium of the falx inguinalis that the transversus abdominis gains its insertion into the pubic crest and into the pecten pubis. The aponeurosis of the transversus abdominis constitutes the greater portion of the falx inguinalis —indeed, whereas the internal oblique aponeurosis has an attachment to the pecten pubis of little more than half an inch, the aponeurosis of the transversalis is fixed to fully an inch of that crest.

Above the level of the falx inguinalis the aponeurosis of the transversus is inserted into the linea alba, but in passing medially to that insertion it presents two different relations to the rectus muscle. Down to a point midway between the umbilicus and pubes it passes *behind* the rectus, and blends with the posterior lamella of the aponeurosis of the internal oblique. Below that point it passes *in front of* the rectus, and blends with the aponeuroses of the internal oblique and external oblique.

*Dissection.*—The sheath of each rectus should now be opened by a vertical incision along the middle line of the muscle. The divided anterior lamella should then be carefully raised from the surface of the muscle and turned laterally and medially. At the lineæ transversæ this can be done only with difficulty, so close is the connection between the sheath and the tendinous intersections of the muscle.

**Contents of the Sheath of the Rectus.**—Within the rectal sheath we find the following structures:—

1. The rectus muscle.
2. The pyramidalis muscle.
3. The terminal portions of the anterior branches of the lower seven thoracic nerves.
4. The inferior epigastric artery, some of its branches, and venæ comites.
5. The superior epigastric artery, some of its branches, and venæ comites.

In cleaning the rectus keep in mind the thoracic nerves. These will now be seen entering the sheath and sinking into the

rectus. After supplying it with twigs, they pass forwards from its substance as the *anterior cutaneous nerves* of the abdomen.

**M. Rectus Abdominis.**—The rectus abdominis is a broad band of muscular fibres which stretches between the thorax and the pubes, at the side of the linea alba. Inferiorly, it *arises* by two heads; of these, the lateral and larger is attached to the pubic crest, whilst the medial and smaller is fixed to the ligaments in front of the symphysis pubis (Fig. 74, p. 200). Towards the thorax the muscle widens and becomes thinner, and its *insertion* is effected by three large slips into the anterior aspect of the costal cartilages of the *fifth*, *sixth*, and *seventh ribs*.

The rectus muscle is broken up into portions by irregular tendinous intersections—the *inscriptiones tendineæ* or *lineæ transversæ*. These are usually three in number, and are placed, one at the level of the umbilicus, another opposite the xiphoid process, and a third midway between. A fourth intersection is sometimes found below the level of the umbilicus. The tendinous intersections are adherent to the sheath of the rectus in front; but they have no attachment to the sheath behind, a fact which can be demonstrated by raising the muscle.

**M. Pyramidalis.**—This is a small triangular muscle—not always present—which springs from the front of the pubis and the ligaments of the symphysis, and is inserted into the linea alba. It lies anterior to the lower part of the rectus, and is supposed to act as a tensor of the linea alba.

The nerve of supply to the pyramidalis comes from the last thoracic nerve. To bring it into view the muscle must be carefully detached from the linea alba and turned downwards towards the pubis. The nerve will be exposed as it enters its deep surface.

**Vagina Recti Abdominis (Sheath of the Rectus).**—The dissector is now in a position to study the manner in which the sheath of the rectus is formed. An examination of the relations which the aponeuroses of the three flat muscles of the abdomen bear to the rectus will show that the sheath is incomplete, and does not entirely surround the rectus. It is deficient *posteriorly*, both above and below.

From the lower margin of the thorax to a point midway between the umbilicus and pubes it encloses the rectus upon all sides. In that part of its extent the *anterior wall* is formed by the aponeurosis of the external oblique fused with the anterior layer of the aponeurosis of the internal oblique, whilst the

*posterior wall* is formed by the fusion of the posterior layer of the aponeurosis of the internal oblique with the aponeurosis of the transversus abdominis (Fig. 148).

*Superiorly*, the rectus muscle rests directly upon the costal cartilages, and the sheath is represented merely by the aponeurosis of the external oblique, which covers the muscle anteriorly. *Inferiorly* also, the posterior wall of the sheath is absent, and the rectus rests on the transversalis fascia. There the anterior wall is formed by a blending of all three aponeuroses (Fig. 150).

The lower free margin of the posterior wall of the sheath is easily defined when the rectus is raised with the handle of the knife. It frequently presents a sharp lunated edge, the concavity of which is directed downwards towards the pubis. It is called the linea semicircularis (O.T. *semilunar fold of Douglas*). The inferior epigastric artery will be

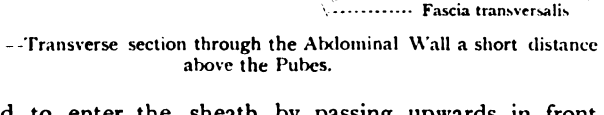


FIG. 150.—Transverse section through the Abdominal Wall a short distance above the Pubes.

observed to enter the sheath by passing upwards in front of this free border (Fig. 149).

The linea semicircularis of Douglas is often rendered indistinct by the presence of scattered tendinous bundles crossing behind the lower part of the rectus.

**Linea Alba.**—The linea alba can now be studied to the best advantage. It is a dense fibrous cord or band which extends perpendicularly between the xiphoid process and the symphysis pubis. It is formed by the union and decussation of the fibres composing the aponeuroses of the two oblique muscles and the transverse muscles of opposite sides. Above the umbilicus it is broad and band-like; whilst below that point it becomes narrow and linear. A close examination will show that it is pierced by several small round openings, for the transmission of blood-vessels, and from some of these the dissector may observe minute fatty masses protruding. A little below its middle is the umbilicus, but the foramen, of which this is the remains, is completely closed at birth;

indeed, in the adult the linea alba is stronger at that point than elsewhere.

**Fascia Transversalis.**—This is a thin layer of fascia which is spread out upon the deep surface of the transversus abdominis muscle. The fascia of one side is directly continuous with the fascia of the opposite side, and forms a part of an ex-

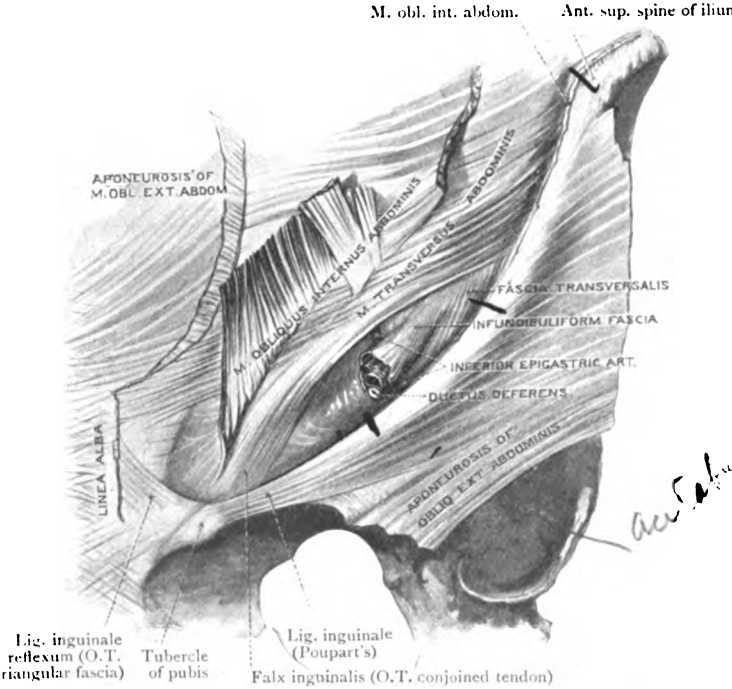


FIG. 151.—Deep dissection of the Inguinal Region. The internal oblique has been reflected to show the whole length of the inguinal canal; and the cord, enclosed within the infundibuliform fascia, is seen cut across.

tensive fascial stratum which lines the entire abdominal wall, and is placed between the abdominal muscles and their aponeuroses on the one hand, and the extra-peritoneal fatty tissue on the other.

Traced upwards, the fascia transversalis becomes thin and, at the margin of the thorax, it is directly continuous with the fascia which covers the lower surface of the diaphragm. Towards

the inguinal region it plays an important part as a constituent of the abdominal wall.

In the present state of the dissection (on the right side of the body), a small gap or interval is seen to exist between the arched lower border of the transverse muscle and the inguinal ligament. The membrane which fills up this interval is part of the *transversalis fascia.* At no part of the abdominal wall is the transversalis fascia stronger than here, and this accession of strength is obviously for the purpose of compensating for the deficiency in the transverse muscle, which, at this point, does not descend so low as the inguinal ligament. In this interval the transversalis fascia has an important relation to the spermatic cord. The fascia is pierced by the cord, but as yet no opening is visible. Take hold of the cord and draw it downwards and medially. The margins of the aperture through which it passes will be observed to be prolonged downwards upon the cord in a funnel-shaped manner, so as to invest it upon all sides with a tube of fascia. This investment, which is thus seen to come directly from the fascia transversalis, is called the *infundibuliform* or *internal spermatic fascia.*

*Dissection.* — It must now become the object of the dissector to demonstrate the more important attachments of this fascia. He must, therefore, divide the fibres of the transverse muscle along the lateral part of the inguinal ligament and along the crest of the ilium, and, raising the muscle from the subjacent fascia, throw it upwards. It is not necessary to reflect the entire muscle.

**Attachments of the Fascia Transversalis.**—When the fascia is cleaned, with the handle of the scalpel, it will be seen to be attached *laterally* to the internal lip of the iliac crest. Along the line of this attachment, which is by no means firm, it becomes continuous with the *fascia iliaca*—that portion of the same fascial stratum which covers the iliacus and psoas muscles in the iliac fossa. Close to the crest of the ilium the fascia transversalis is pierced first by the ascending branch and then by the terminal branches of the deep circumflex iliac artery. *Anteriorly*, in the inguinal region, its connections are more complicated, and must be studied at three different points —(1) between the anterior superior spine of the ilium and the femoral artery, where it will be seen to be attached to the inguinal ligament; along this line also it becomes continuous with the fascia iliaca; (2) opposite the femoral vessels, where it

is carried distally into the thigh behind the inguinal ligament, to form the anterior part of the femoral sheath (*vide* p. 182); (3) medial to the femoral vessels, where it is attached to the ilio-pectineal line or pecten of the superior ramus of the pubis, behind the falx inguinalis (O.T. conjoined tendon), with which it is partially blended.

**Annulus Inguinalis Abdominalis (Abdominal Inguinal Ring).**—It has been noted that the transversalis fascia is pierced by the spermatic cord. The opening through which it passes is called the *abdominal inguinal ring* (O.T. internal abdominal ring). This opening can be defined from the front only by an artificial dissection, viz.—by dividing the infundibuliform fascia around the cord and pushing it upwards with the handle of the knife. The ring thus defined lies about half an inch above the inguinal ligament, at a point midway between the symphysis pubis and the anterior superior spine of the ilium. Through the opening the dissector can see the extra-peritoneal fat, upon which the transversalis fascia rests, and, just medial to the opening, he will notice the inferior epigastric artery, pursuing its oblique course upwards and medially, and shining through the fascia. If the handle of the knife is now introduced into the ring and carried laterally between the fascia and extra-peritoneal fat, the attachments of the fascia to the inguinal ligament and to the iliac crest can be very clearly shown.

**Canalis Inguinalis (Inguinal Canal).**—The dissector has observed that the spermatic cord in the male and the round ligament in the female pierce the abdominal wall above the inguinal ligament. The passage which is formed for their transmission receives the name of the *inguinal canal.* Now, as this canal is a source of weakness to the abdominal wall, and as it is in connection with it that inguinal hernia occurs, the student will understand how necessary it is that he should examine it carefully from all points of view.

The *inguinal canal* is a narrow channel of about one inch and a half in length. It begins at the abdominal inguinal ring, which may be spoken of as its inlet, and ends at the subcutaneous inguinal ring, which constitutes its outlet. It is, consequently, very oblique, having a direction almost directly medialwards, with a slight inclination downwards and forwards. So much for its length and direction; its floor, its anterior wall, and its posterior wall have still to be examined.

The *floor* is formed, in the first part of the canal, by the upper grooved surface of the inguinal ligament. Towards the outlet, however, the floor becomes broader and more definite; here it is formed not only by the inguinal ligament, but also by the lacunar ligament. At this point, as the student has already observed, the cord rests directly upon the abdominal surface of the lacunar ligament. The parts which enter into the formation of the *anterior wall* are—(1) the aponeurosis of the external oblique, throughout the entire extent of the canal; and (2) the lower border of the internal oblique, in the lateral third of the canal. These facts can be readily verified if the structures are restored to their original positions. The parts which compose the *posterior wall* are still *in situ*. Named in order, from the inlet to the outlet, they are—(1) the fascia transversalis; (2) the falx inguinalis; and (3) the ligamentum inguinale reflexum, when it is developed.

But it may be asked, does the transversus abdominis muscle take no part in the formation of the inguinal canal? The student can readily satisfy himself as to this point. He will notice that the arched lower border of this muscle does not descend so low as that of the internal oblique; that, in fact, it stops short immediately above the abdominal inguinal ring. The canal is closed superiorly by the approximation of the anterior and posterior walls above the cord and by the intervention between the walls of the lower border of the transversus abdominis.

There is still another point to be noted, viz., the relation which the inferior epigastric artery bears to the posterior wall of the canal. This vessel can be felt (and, indeed, in most cases seen) extending obliquely upwards and medially, posterior to the transversalis fascia, to the lateral border of the rectus. A triangular space is thus mapped out by the artery, the inguinal ligament, and the lateral border of the rectus. This receives the name of the *triangle of Hesselbach*. The space corresponds with the posterior wall of the inguinal canal, and chiefly with that part of it which is composed of the falx inguinalis (O.T. conjoined tendon).

In the female the inguinal canal is much smaller than in the male. It has the same boundaries; and it is traversed by the round ligament of the uterus.

**Arteries of the Abdominal Wall.**—The following arteries will be found in the abdominal wall:—

1. The intercostal and lumbar arteries.
2. The inferior epigastric artery.
3. The deep circumflex iliac artery.
4. The superior epigastric artery.
5. The musculo-phrenic artery.

The *intercostal arteries* of the lower two spaces are prolonged forwards between the internal oblique and the transversus abdominis. They have already been noted accompanying the corresponding nerves. In front, they anastomose with branches of the epigastric arteries, whilst, inferiorly, they effect communications with the lumbar arteries.

The *abdominal branches* of the *lumbar arteries* ramify between the same two muscles as the preceding vessels, but at a lower level in the abdominal wall. Anteriorly, they anastomose with branches of the inferior epigastric artery; above, with the intercostal arteries; and below, with the deep circumflex iliac and the ilio-lumbar arteries.

**Arteria Epigastrica Inferior** (O.T. **Deep Epigastric Artery**). —The inferior epigastric branch of the external iliac is a vessel of some size. It takes origin about a quarter of an inch above the inguinal ligament. At present it is seen shining through the fascia transversalis and forming the lateral boundary of Hesselbach's triangle. Divide the fascia transversalis along its course and note the two veins which accompany the artery. Study the course and relations of this vessel. At first it runs medially for a short distance, between the inguinal ligament and the abdominal inguinal ring, and then, changing its direction, it is carried upwards and medially on the medial side of the ring. Reaching the deep surface of the rectus it enters the rectus sheath, and, proceeding vertically upwards, ends, near the lower margin of the thorax, in branches which sink into the substance of the muscle and anastomose with the superior epigastric artery.

In the first part of its course, the inferior epigastric lies in the extra-peritoneal fat between the peritoneum and the fascia transversalis. Soon, however, it pierces the fascia, and, passing in front of the linea semicircularis, ascends between the rectus muscle and the posterior wall of its sheath. These are its immediate relations, but there are others of equal importance, viz., (1) as it runs upwards it lies close to the medial side of the abdominal inguinal ring; (2) as the spermatic cord traverses the inguinal canal it lies in front of the artery, separated from it only by transversalis fascia; (3) as the ductus deferens passes

from the inguinal canal into the abdominal cavity it hooks round the lateral side of the artery.

The *branches* which spring from the inferior epigastric are—

1. External spermatic.
2. Pubic.
3. Cutaneous.
4. Muscular.

The *external spermatic* is a small twig which supplies the cremaster muscle and anastomoses with the internal spermatic artery. The *pubic*, also insignificant in size, runs medially, on the pubis, and sends downwards an obturator branch which anastomoses with a small branch from the obturator. The importance of this branch arises from the fact that the anastomosis which it establishes sometimes becomes so large as to take the place of the obturator artery. The *muscular branches* are given to the substance of the rectus, and the *cutaneous offsets* pierce the abdominal muscles and anastomose with the superficial epigastric artery.

**Arteria Circumflexa Ilium Profunda.**—The deep circumflex iliac artery springs from the lateral side of the external iliac artery, about the same level as the inferior epigastric, and runs laterally, behind the inguinal ligament, to the anterior superior spine of the ilium. From that point onwards it takes the crest of the ilium as its guide, and ends by anastomosing with branches of the ilio-lumbar artery. At first it is placed in the extra-peritoneal fat, between the fascia transversalis and the peritoneum. Its course behind the inguinal ligament is indicated by a whitish line, which marks the union of the fascia transversalis and fascia iliaca; and if the transversalis fascia is now divided along this line the deep circumflex iliac will be exposed. At the crest of the ilium the vessel pierces the fascia transversalis, and lies between that and the transversus muscle; and lastly, about the middle point of the iliac crest, it pierces the transversus muscle, and its terminal twigs ramify between it and the internal oblique. Thus the artery gradually approaches the surface, as it passes from its origin to its termination.

The dissector has already seen the *ascending branch* which it sends upwards between the internal oblique and transverse muscles.

**Art. Epigastrica Superior and Art. Musculo-phrenica.**—These are the two terminal branches of the internal mam-

mary artery. The *superior epigastric* will be found behind the rectus muscle and within the upper part of its sheath. It gives twigs to the rectus, and anastomoses with the inferior epigastric and the intercostal arteries.

The *musculo-phrenic* cannot be seen until the transversus abdominis is reflected from the costal cartilages. It will be found at the level of the eighth cartilage. Thence it proceeds downwards, along the attachment of the diaphragm, as far as the last intercostal space. It gives branches to the diaphragm, and others (anterior intercostals) which enter some of the lower intercostal spaces.

*Dissection.*—When the transversalis fascia is reflected the only layers which intervene between the dissector and the abdominal cavity are the extra-peritoneal fatty tissue and the parietal peritoneum.

If the subject is a male, now is the best time for the student to examine the constitution of the scrotum, spermatic cord, and testis. This can be done at present only on the right side, as the parts on the opposite side must be kept *in situ* for the study of hernia. After that study has been made the dissection can be repeated on the left side.

**Scrotum.**—This is a pendulous purse-like arrangement of the skin and superficial fascia for the lodgment of the testes. The skin composing it is of a dark colour and rugose, and is traversed, along the middle line, by a *median raphe* or ridge, which indicates its bilateral character.

*The superficial fascia* possesses certain characters peculiar to itself. It has a ruddy colour, and is totally devoid of fat. The ruddy tint is due to the presence of involuntary muscular fibres which take the place of the fat, and constitute what is called the *dartos muscle*. The rugosity of the scrotal skin is maintained by these muscular fibres. But, further, the superficial fascia forms an imperfect septum or partition, which divides the interior of the scrotum into two chambers —one for each testis. These points in connection with the construction of the scrotum have all, to a certain degree, been noted in the dissection of the perineum.

The two scrotal tunics are not the only coverings of the testis. Each constituent of the abdominal wall has been seen to contribute an investment to the spermatic cord, and each in turn is continued down so as to clothe the testis. Presuming, then, that the skin and superficial fascia are reflected, the testis and cord within the scrotum will still be found to be invested by:—

1. The external spermatic fascia, from the aponeurosis of the external oblique.
2. The cremasteric fascia—the muscular element of which is derived partly from the internal oblique.
3. The internal spermatic fascia, from the fascia transversalis.

The dissector will find it difficult to demonstrate these different investments of the testis in every subject. In cases of large herniæ of old standing, however, they become thickened, and are more readily recognisable, but the dissector always works at a great disadvantage when he attempts to unfold the coverings of the cord and unravel its constituent parts while they are attached to the body. The cord and testis of the right side should be removed after the former with its coverings is divided at the level of the subcutaneous inguinal ring. The specimen should then be placed in a cork-lined tray and dissected under water. Having fastened the cord and testis, with pins, to the bottom of the tray, the dissector will experience little difficulty in displaying the different layers, and a splendid demonstration will be afforded of the constituent parts of the cord.

From the above description the student will understand that there is only *one* tunic common to both testes, viz., the integument; that the superficial fascia and dartos, forming the dartos tunic, and the investments derived from the abdominal wall, constitute special tunics for each testis.

**Funiculus Spermaticus.**—The spermatic cord is formed by the association together of certain blood-vessels, nerves, and lymph vessels, along with the ductus deferens, all of which are proceeding to or coming from the testis. These structures come together at the abdominal inguinal ring, and this may be taken as the point at which the cord begins. It has already been traced in its course through the inguinal canal, and has been observed to issue from it through the subcutaneous inguinal ring. It is now seen as it lies within the scrotum suspending the testis.

Before dissecting out the constituent parts of the cord, examine the extra-peritoneal fatty tissue which lies behind the abdominal inguinal ring. Note that a process of this tissue is prolonged downwards with the cord. Now, with the handle of the knife, gently separate the extra-peritoneal fat from the subjacent peritoneum. Behind the abdominal inguinal ring the peritoneum shows a slight bulging forwards, and a slender fibrous band may be detected passing into the cord from the most prominent part of this bulging. This fibrous cord is the remains of the tube of peritoneum which, in the fœtus, connected the serous investment of the testis (the tunica vaginalis) with the general peritoneal lining of the abdomen. In some cases it may be

traced as far as the testis, but more commonly it extends down the cord only for a short distance; indeed, it is frequently absent.

To obtain a proper conception of this fibrous thread, it is necessary that the student should understand that neither the testis nor the tunica vaginalis are developed in the scrotum. In the early months of fœtal life the rudimentary scrotum is devoid both of tunica vaginalis and testis, and

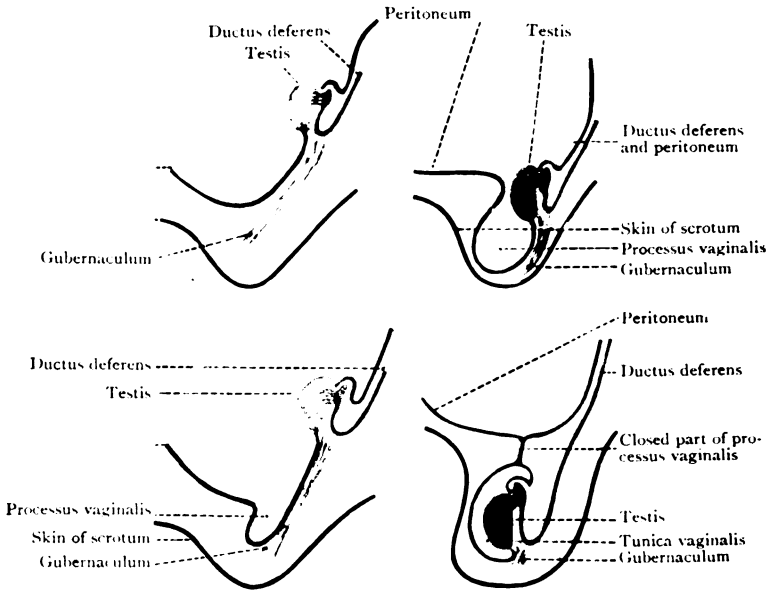


FIG. 152.—Diagrams illustrating the Descent of the Testis and the Derivation of the Tunica Vaginalis from the peritoneal lining of the abdominal cavity.

the testis lies on the posterior wall of the abdomen, projecting forwards into the great serous cavity of the abdomen, which is called the peritoneal cavity. The wall of the peritoneal cavity is formed by a membrane called the peritoneum, and the inner surface of the membrane is lined with a layer of flat epithelium—peritoneal epithelium. The peritoneum which is in contact, externally, with the wall of the abdomen is called the *parietal peritoneum*: but here and there the posterior wall of the peritoneal sac is invaginated by one or other of the abdominal viscera. When the invaginating viscus carries forward more peritoneum than is necessary to cover its surfaces, the excess of peritoneum forms a fold which connects the viscus with the posterior wall of the abdomen; such folds are called mesenteries and they connect the peritoneum covering the invaginating viscus, which is termed the *visceral peritoneum*, with the parietal

peritoneum lining the inner surface of the abdominal wall. The testis is developed in the lumbar region; and it projects forwards into the peritoneal cavity, covered with a layer of epithelium which is continuous with the peritoneal epithelium. It also invaginates a portion of the wall of the peritoneal sac and so produces a mesentery connecting the testis and the epithelium which covers its surface with the parietal peritoneum; this mesentery is called the mesorchium.

The testis and its mesorchium gradually descend in the wall of the peritoneal sac to the inguinal region; and, at the same time, a diverticulum of peritoneum, the *processus vaginalis*, is projected through the inguinal portion of the abdominal wall into the scrotum, producing by its passage the inguinal canal, and prolonging the cavity of the peritoneum into the scrotum. During the latter part of the seventh and the early part of the eighth month of fœtal life the testis, with its epithelium and its mesorchium, descends along the posterior wall of this diverticulum, and during the ninth month it comes to rest near the lower end of the scrotum, where it projects forwards in the posterior wall of the lower part of the processus vaginalis. In the meantime, the cavity of the upper part of the processus vaginalis disappears and its peritoneal wall forms a solid fibrous cord (*Rudimentum processus vaginalis*). The lower part of the sac, thus cut off, is the tunica vaginalis of the testis. Its cavity is now entirely separated from the cavity of the peritoneum, but its wall is still connected with the peritoneum, for a longer or shorter time, by the fibrous cord which is the remains of the upper part of the processus vaginalis. In most cases, however, this cord undergoes atrophy, from below upwards, and in many cases, as already mentioned, it entirely disappears.

The orifice of communication between the processus vaginalis and the peritoneal cavity is closed usually before birth; and the cavity of the upper portion of the process, from the abdominal inguinal ring to the persistent tunica vaginalis, is generally obliterated during the first month of extra-uterine life.

The cause of the descent of the processus vaginalis and the testis is still a subject of dispute. It has been suggested:—(1) that it is due to different growth energy in adjacent parts; (2) to traction from below, produced by a musculo-fibrous cord, the *gubernaculum of the testis*, which grows through the inguinal part of the abdominal wall and is attached to the interior of the scrotum, whilst, above, it is attached to the testis and the adjacent peritoneum; (3) to the action of intra-abdominal pressure, tending to displace the testis downwards.

*Dissection.*—The coverings of the spermatic cord should now be removed, and the parts which enter into its formation isolated from each other.

**Constituent Parts of the Spermatic Cord.**—The following are the structures which form the spermatic cord:—

1. The ductus deferens (O.T. vas deferens).
2. Blood-vessels.
   - Arteries.
     - The internal spermatic.
     - The external spermatic.
     - The artery to the ductus deferens.
   - Veins.
     - The pampiniform plexus of veins.
3. Lymph vessels.
4. Nerves.
   - External spermatic.
   - Sympathetic twigs.

These are all held together by loose areolar tissue which

intervenes between them, and also by the investments which are given to the cord by the abdominal wall.

The *external spermatic artery* is a branch of the inferior epigastric, and has already been seen entering the cremaster muscle. The *external spermatic nerve*, a branch of the genito-femoral nerve, has a similar destination. It has been displayed in a previous stage of the dissection.

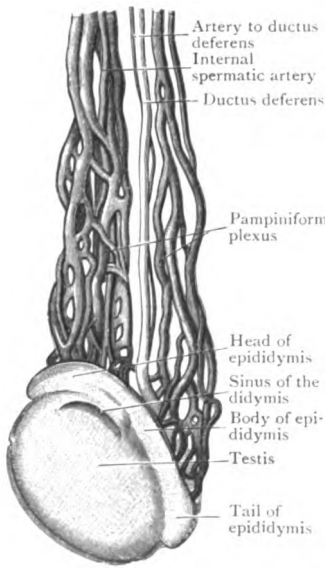


FIG. 153.—Dissection of the Left Spermatic Cord to show its constituent parts. (From Waldeyer, modified.)

The *internal spermatic artery* arises, within the abdomen, from the front of the aorta; it enters the cord at the abdominal inguinal ring, and proceeds to the testis, into the posterior border of which it sinks, after dividing into several smaller twigs. The *testicular veins* issue from the testis at its posterior border, and, as they pass upwards, they form, in the cord, a bulky plexus, which is termed the *pampiniform plexus*. A single vessel, the *spermatic vein*, issues from this, and enters the abdomen through the abdominal inguinal ring. On the right side it pours its blood into the inferior vena cava; on the left side it joins the left renal vein.

The *ductus deferens* (O.T. *vas deferens*), the duct of the testis, can always be distinguished by the hard, firm, cord-like sensation which it gives when the spermatic cord is held between the finger and thumb. It ascends in the posterior part of the cord. At the abdominal inguinal ring, however, it separates from the spermatic vessels, and lies to their medial side; as it enters the abdomen it hooks round the inferior epigastric artery.

The *artery to the ductus deferens* is a small branch from a superior vesical. It follows the duct to the testis.

The *sympathetic filaments* extend downwards upon the internal spermatic artery. They come from the renal and aortic plexuses.

The *spermatic lymph vessels* enter the abdomen through the abdominal inguinal ring, and join the lumbar glands.

**Testis** (O.T. **Testicle**).—The testis should next be examined. First note its position in the scrotum. It lies somewhat

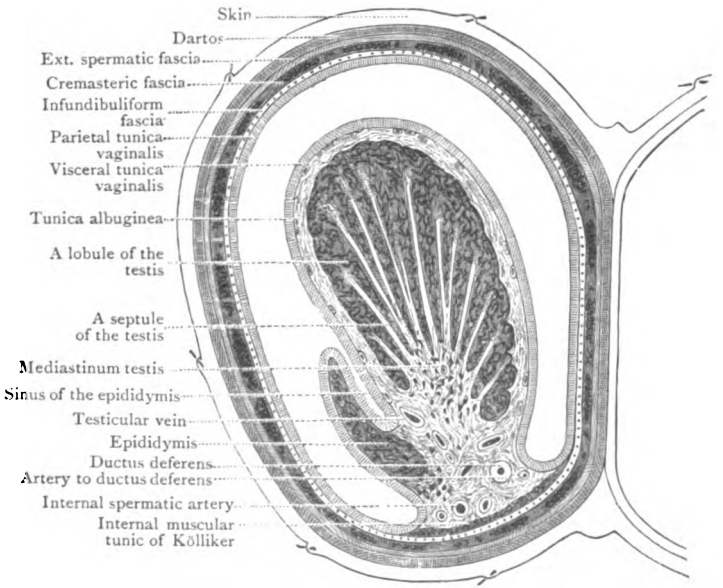


FIG. 154.—Transverse section through the left side of the Scrotum and the Left Testis, seen from above. The sac of the tunica vaginalis is represented in a distended condition.

obliquely, with its superior extremity directed forwards and laterally, and its inferior extremity backwards and medially. The left testis hangs usually at a lower level than the right.

Each testis is enveloped by the *tunica vaginalis testis.*

The *tunica vaginalis* is a serous sac, and, consequently, presents a *parietal* or *scrotal* portion, and a *visceral* or *testicular* portion. The dissector can demonstrate its extent in a striking manner by making a small aperture in the parietal part, and then introducing a blow-pipe into the serous cavity and inflating it with air. It will be seen to be considerably larger than

the gland which it envelops. It ascends for some distance upon the spermatic cord, and it descends beyond the testis. When flaccid, the parietal part is simply wrapped loosely over the visceral portion which adheres to the surface of the testis.

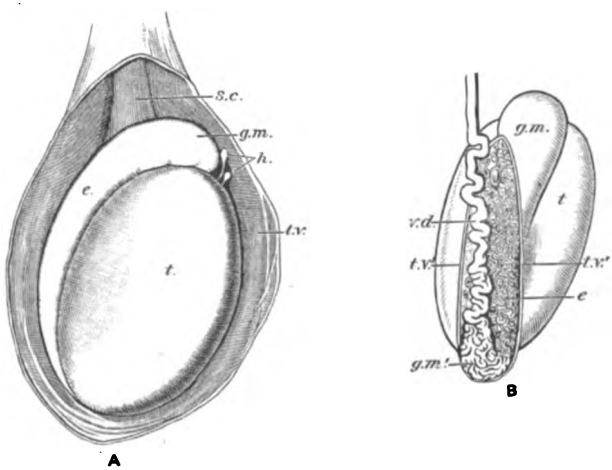


FIG. 155.

A. The Right Testis and Epididymis within the tunica vaginalis. (A. F. Dixon.)

*s.c.* Spermatic cord.
*g.m.* Caput epididymidis.
*e.* Corpus epididymidis.
*t.* Testis.
*h.* Appendix testis (Morgagni).
*t.v.* Tunica vaginalis.

B. The Right Testis and Epididymis seen from behind, after removal of the parietal part of the tunica vaginalis. (A. F. Dixon.)

*t.v'.* Cut edge of tunica vaginalis along the line where the *parietal part* becomes continuous with the *visceral part*.
*v.d.* Ductus deferens.
*g.m'.* Cauda epididymidis.

*Dissection.*—Open into the sac of the tunica vaginalis by running a pair of scissors along the anterior aspect of the parietal part. When the parietal portion of the tunica vaginalis is folded backwards, the form of the testis may be studied, and also the manner in which it is attached to the posterior wall of the sac.

**Body of the Testis and Epididymis.**—The testis is an oval body, with flattened sides. The posterior margin also is somewhat flattened, and is in relation with the *epididymis*. The epididymis is an elongated and arched structure, adapted

to the superior extremity and lateral side of the posterior margin of the testis. The superior extremity of the epididymis is enlarged, and is termed the *caput epididymidis*; its inferior extremity is called the *cauda epididymidis*; while the intervening portion, which is narrow, receives the name of the *corpus epididymidis* (*body of the epididymis*). The caput epididymidis surmounts the superior extremity of the testis like a helmet, and is attached to it both by the visceral tunica vaginalis, which is continued over it, and also by the *ductuli efferentes*, which pass from the testis into the epididymis. The *cauda epididymidis* is fixed to the back of the testis merely by the visceral tunica vaginalis and some intervening areolar tissue. The *body of the epididymis* is free, and is separated from the body of the testis by an involution of the serous covering which forms the wall of the *sinus epididymidis*.

If the superior extremity of the body of the testis is carefully examined, two minute structures will be observed attached to it, close to the head. These are the *appendices testis* (O.T. *hydatids of Morgagni*), remnants of an embryonic canal called Müller's duct. One of the appendices is usually pear-shaped and stalked; the other is smaller and generally sessile.

The *ductus deferens* emerges from the inferior extremity of the tail of the epididymis, and then passes upwards upon the posterior margin of the testis and on the medial side of the body and head of the epididymis. By this relation, the side to which a given testis belongs can be readily detected. The vessels have already been seen entering and emerging from the posterior margin of the testis.

**Visceral Layer of the Tunica Vaginalis Testis.**—Having learned the foregoing points concerning the testis, the student is in a position to trace the visceral layer of the tunica vaginalis. Observe that it is attached to the posterior border of the testis, where the vessels enter and emerge, and that it covers the sides of the epididymis. On the lateral surface of the organ it forms a little *cul-de-sac* between the body of the epididymis and the body of the testis. This is called the *sinus of the epididymis* (O.T. digital fossa). Note particularly that it is along the posterior border of the testis that the epithelium lining the tunica vaginalis becomes continuous with the epithelium on the testis.

*Dissection.*—Some of the main facts relating to the structure of the testis may be learned by a careful naked-eye examination of its different

parts. For this purpose place it in a cork-lined tray and dissect it under water. Having fixed it to the bottom of the tray, with pins, begin by tracing the vessels into the gland. As this is done, a quantity of involuntary muscular tissue spread over the posterior border of the testis and the epididymis becomes apparent. This is the *inner muscular tunic of Kölliker.* Now free the tail and body of the epididymis from the back of the gland. This can be easily done by cutting the serous covering as it passes from one to the other, and breaking through the fibrous tissue which intervenes between the tail and the lower part of the body of the testis. Do not interfere with the head. When the body and tail of the epididymis are turned aside, the body of the testis may be divided transversely, with a sharp knife, about its middle, into an upper and a lower portion.

**Structure of the Testis.**—The cut surface of the lower part of the body of the testis may now be studied. The dense, tough fibrous coat which envelops it, under cover of the epithelium, first attracts attention. It is called the *tunica albuginea.* At the posterior margin of the testis it will be seen to be projected into the interior, in the form of a thick fibrous elevation. This extends along the whole length of the posterior border, and receives the name of the *mediastinum testis* (corpus Highmori). It is traversed by the vessels that pass into and out from the gland, and it is tunnelled also by a plexus of seminal canals, called the *rete testis* (*Halleri*).

From the front and sides of the mediastinum testis radiating fibrous lines will be seen passing into the substance of the testis. These are the cut margins of incomplete fibrous septula which extend towards the deep surface of the tunica albuginea and become connected with it (Fig. 154). By means of these partitions and of the mediastinum testis, the space enclosed by the tunica albuginea becomes broken up into a large number of lobules or compartments, two to three hundred in number, the walls of which are imperfect. Such is the fibrous framework of the body of the testis.

The blood-vessels have a very definite arrangement with reference to this framework. Passing in through the mediastinum they spread out on the deep surface of the tunica albuginea, and upon both surfaces of the fibrous septula which bound the testicular compartments. The vascular mesh-work thus formed is sometimes called the *tunica vasculosa.*

The proper glandular substance of the testis is lodged within the compartments described above. It consists of an enormous number of fine hair-like tubes, termed the *contorted*

*seminiferous tubules.* Two or more occupy each compartment, and constitute what is called a *testicular lobule.* In this they are closely packed and are coiled and convoluted to an extraordinary degree. The dissector should now endeavour to unravel some of these tubuli seminiferi under water. It will be impossible to open them out in their whole length, but a sufficiently good demonstration may be obtained to make their general arrangement apparent. Each tube averages two feet in length.

Approaching the mediastinum testis, the tubuli seminiferi contorti join each other at acute angles and form a smaller number of tubes, which finally become straight and considerably reduced in diameter. These are called the *tubuli seminiferi recti.* They enter the mediastinum and join the *rete testis.*

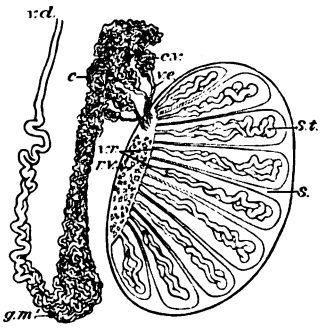


FIG. 156.—Diagram illustrating the Structure of the Testis. (A. F. Dixon.)

*v.d.* Ductus deferens.
*g.m'.* Cauda epididymidis.
*c.* Caput epididymidis.
*c.v.* Lobuli epididymidis.
*v.e.* Ductuli efferentes testis.
*v.r.* Tubuli seminiferi recti.
*r.t.* Rete testis.
*s.t.* Contorted seminiferous tubule.
*s.* Septula testis.

*Dissection.*—The tubuli seminiferi contorti should now be removed from the lower part of the testis. This can be done with the forceps under a stream of water. A good view is then obtained of the fibrous framework of the testis. The strength of the tunica albuginea becomes evident, whilst the mediastinum testis, and the septules which proceed from it, are seen to great advantage.

The dissector must next endeavour to ascertain the manner in which the secretion of the testis passes from the rete testis into the epididymis. For this purpose the upper part of the testis, with the attached epididymis, must be examined. Gently raise the caput epididymidis from the surface of the body of the testis by dividing the visceral part of the tunica vaginalis which binds them together, and carefully break down the intervening connective tissue. Under favourable circumstances the *ductuli efferentes* may be seen.

**Structure of the Epididymis.**—The *ductuli efferentes testis* are fifteen to twenty delicate ducts which leave the upper part of the rete testis, pierce the tunica albuginea, and pass into the caput epididymidis. In the caput the ductuli efferentes become coiled and form a series of small conical

masses, called the *lobuli epididymidis.* Ultimately these ducts open into a single convoluted canal, termed the *ductus epididymidis.* The head of the epididymis is thus composed of the lobules of the epididymis and the coiled duct of the epididymis. The body and tail of the epididymis are formed of the continuation of the same canal, coiled and convoluted upon itself to a remarkable degree.

The intricacy of its flexuosities will be better understood by simply stating that if it were completely opened out it would be found to measure twenty feet or more. At the lower end of the tail of the epididymis the duct of the epididymis becomes continuous with the ductus deferens.

*Dissection.*—The dissector should endeavour to unravel a part of the ductus epididymidis. The coils are held together by areolar tissue and the dissection is very tedious.

**Penis.**—The penis has already, to a certain extent, been studied in the dissection of the perineum (p. 351). It has been seen to be composed of the *corpus cavernosum penis* and the *corpus cavernosum urethræ.* Posteriorly, the corpus cavernosum penis divides into the two crura penis, which are attached to the sides of the pubic arch; anteriorly, the corpus cavernosum penis ends in a blunt, rounded extremity, which is covered by the glans penis. The corpus cavernosum urethræ, when traced backwards into the perineum, expands into the *bulb of the urethra*, which is attached, in the median plane, to the inferior fascia of the urogenital diaphragm; traced forwards to the extremity of the penis, it is again found to expand into the *glans penis*, which fits like a cap upon the rounded end of the corpus cavernosum penis. The glans penis is conical in shape, and the projecting margin of its base is termed the *corona glandis.* The urethra opens at the extremity of the glans by a vertical fissure, called the *orificium urethræ externum* (O.T. *meatus urinarius*).

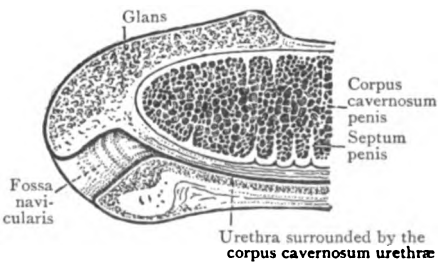


FIG. 157.—Median section through the terminal part of the Penis.

The *integument of the penis* is remarkable for its great delicacy and elasticity, and the absence of hairs. It has a brownish tint, and is freely movable over the organ. At the glans the skin leaves the body of the penis, and, passing for a variable distance over the glans, is folded back upon itself so as to form the *prepuce*. The deep layer of the prepuce reaches the penis again behind the corona glandis, and is then reflected forwards over the glans to become continuous with the mucous membrane of the urethra at the external urethral orifice. A slight fold will be observed on the under surface of the glans, extending from the lower angle of the external orifice to the prepuce; this is the *frenulum preputii*.

*Dissection.*—Reflect the integument from the surface of the penis by making a longitudinal incision along the middle line of the dorsum. The superficial fascia will then be seen to be composed of a quantity of loose areolar tissue, which is devoid of fat. The suspensory ligament and the dorsal vessels and nerves of the penis should now be dissected. The vessels and nerves are covered by the deep fascia of the penis.

**Suspensory Ligament of the Penis.** — The suspensory ligament of the penis is a strong fibro-elastic band of a triangular shape. By its posterior border it is attached to the symphysis pubis. Towards the penis it separates into two lamellæ, which join the deep fascia of the body of the organ. Between the two lamellæ are placed the dorsal vessels and nerves.

**Dorsal Vessels and Nerves.**—On the dorsum of the penis, in the groove which extends along the middle line of the corporus cavernosum penis, is the *deep dorsal vein*; on each side of this is the *dorsal artery*, and superficial and lateral to the artery is the *dorsal nerve*. On the dorsum of the penis, therefore, we find *one* vein, *two* arteries, and *two* nerves.

The *dorsal vein* of the penis begins by several twigs from the glans and prepuce. It extends backwards in the middle line, passes between the two layers of the suspensory ligament, and gains the pelvis by passing under the arcuate ligament. It ends by joining the pudendal plexus of veins.

The *dorsal arteries* are the terminal twigs of the internal pudendal vessels. They pass forward between the two layers of the suspensory ligament, and, continuing their course, on the dorsum of the penis, they terminate in branches to the glans penis.

The *dorsal nerves* are branches of the pudendal. They

have a similar course to the arteries, and end in fine twigs to the papillæ of the glans.

## Trigonum Lumbale and Lumbar Fascia.

On the sixth day after the body was placed on its back it will be turned upon its face, with blocks supporting the thorax and pelvis, and in this position it will remain for five days. At the end of the first or the beginning of the second day of this period, when the dissector of the upper extremity has cleaned the latissimus dorsi, the dissector of the abdomen must take the opportunity of examining the posterior border of the external oblique. As the posterior border of the muscle passes from the last rib to

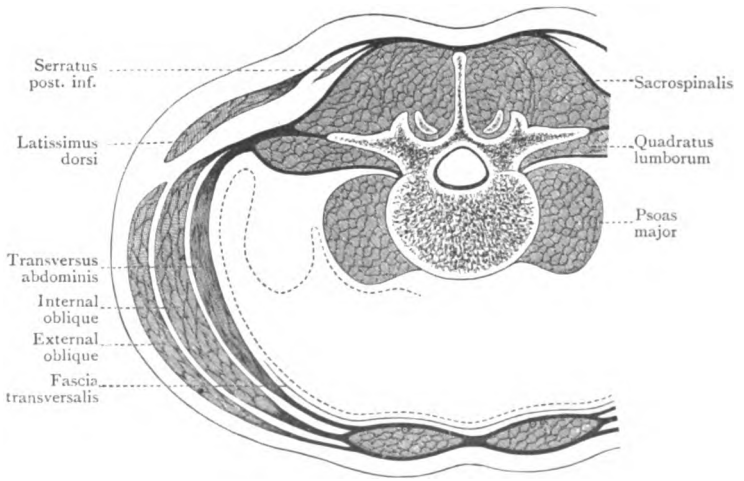


Fig. 158.—Lumbar fascia and sheath of Rectus abdominis. The dotted line represents the Peritoneum.

the external lip of the iliac crest it is quite free, and, in many cases, there is a small triangular interval between it and the lower part of the lateral border of the latissimus dorsi in which the fibres of the more deeply situated internal oblique can be seen. This is the *trigonum lumbale Petiti*. It is a comparatively weak region of the abdominal wall, and in some rare cases hernia of the abdominal contents occurs through it. Not uncommonly, however, the lateral border of the latissimus dorsi overlaps the posterior border of the external oblique, and in these cases the trigonum lumbale does not exist.

On the third day, after the dissector of the upper extremity has reflected the muscles which connect the upper extremity with the trunk on the posterior aspect, the dissector of the abdomen, in association with the dissector of the head and neck, should examine the lumbar fascia and the lumbar origins of the internal oblique and the transversus abdominis muscles.

The lumbar fascia is a portion of the lumbo-dorsal fascia which binds

down the deep muscles of the back at the sides of the spines of the vertebræ. In the thoracic region it is a thin transparent lamina which extends from the spines of the vertebræ to the angles of the ribs. At the upper end of the thoracic region it disappears into the neck under cover of the serratus posterior superior. In the lumbar region it becomes much stronger and more complicated. Above, it is continuous with the dorsal portion of the fascia and is attached to the last rib. Medially, it is attached to the tips of the spines and transverse processes, and to the fronts of the transverse processes of the lumbar vertebræ; laterally, it is connected with the transversus abdominis and the internal oblique, and, below, it is closely attached to the posterior part of the external lip of the iliac crest. In the pelvic region it is attached to the spines of the sacrum and to the back of the lower part of the sacrum and to the back of the coccyx. In the lumbar region its posterior lamella covers the rounded column of the spinal muscles, and to this part the remains of the origin of the latissimus dorsi and the serratus posterior inferior will be found attached. The former must be cleared away; the latter extends upwards and laterally to its attachment to the lower four ribs. It must be cut through at right angles to its fibres and turned aside, its nerves of supply, from the anterior branches of the lower thoracic nerves, being sought for on its deep surface. The remains of its origin from the lumbar fascia must be cleared away and then a vertical incision must be made through the fascia, midway between the medial and lateral borders of the rounded mass of the spinal muscles, and at each end of the longitudinal incision a transverse incision must be made, one just below the last rib and the other just above the iliac crest. The transverse incisions should commence at the spine and should not extend beyond the lateral margin of the mass of spinal muscles. The medial part of the divided fascia must be turned to the median plane and its attachments to the tips of the spine verified. The lateral part should be pulled laterally, and at the lateral border of the mass of spinal muscles it will be found to blend with a deeper layer. Push the spinal muscles medially and follow the middle lamella to its attachment to the tips of the transverse processes. The dissectors should then note that the upper fibres of origin of the internal oblique spring from the lumbar fascia just lateral to the line where the middle and posterior lamellæ of the fascia blend. There is still, however, another lamella of the lumbar fascia—the anterior lamella. To display this the dissector must divide the middle lamella vertically, close to its attachments to the tips of the transverse processes, and transversely along the line of its attachment to the iliac crest. The middle lamella can then be turned laterally, and the posterior surface of the quadratus lumborum is brought into view. When the lateral border of this muscle is displaced towards the median plane the anterior lamella of the lumbar fascia will be exposed. The dissector should place his finger upon its surface and trace it medially and laterally. Medially he will be able to follow it to, or to within a short distance of the roots of the transverse processes of the vertebræ, and laterally he will find that it joins the remainder of the fascia some distance lateral to the union of the posterior and middle lamellæ. He must note, further, that beyond the union of the three lamellæ the lumbar fascia is continued into the transversus abdominis, and thus it is, through the lumbar fascia, that the transversus obtains its origin from the tips of the spines and transverse processes, and the fronts of the transverse processes of the lumbar vertebræ. When the dissector has satisfied himself regarding the lamellæ of the lumbar fascia and their relation to the internal oblique and the transversus abdominis, he should carefully divide the anterior lamella longitudinally, and, introducing his finger through the incision, into the extra-peritoneal fatty tissue, he should scrape away the

latter until he exposes the lower part of the kidney, below the level of the last rib, and the adjacent part of the colon, which lies along the lower and lateral part of the kidney. After this has been done the dissector of the abdomen ceases work till the body is re-turned, when he will re-examine the anatomy of the inguinal region in association with the formation of hernia, and afterwards proceed to the investigation of the abdominal cavity and its contents.

## HERNIA.

The anatomy of the abdominal wall, in the regions where hernia most frequently occurs, is of such great importance to the surgeon that special attention must be paid to it by the dissector.

Hernia is the term applied to the abnormal protrusion, through the wall of the abdomen, of a viscus, or a part of a viscus, or of a part of a peritoneal fold which supports or is attached to a viscus.

It occurs most commonly where the peritoneal sac, or a diverticulum of the peritoneal sac, was prolonged through the abdominal wall at some period of intra-uterine development. The two situations in which such prolongations are always present are the inguinal region and the umbilicus; and it is stated that a small diverticulum is almost always met with, in the subinguinal region, dipping into the mouth of the femoral canal of the femoral sheath. These three regions, therefore, are the situations in which hernia is most often met with, and it is asserted that the most important factor in the production of hernia is the presence of a more or less definite persisting diverticulum of the peritoneum.

The diverticulum which existed in the inguinal region was the processus vaginalis described on pp. 408, 409. This diverticulum passed obliquely through the wall of the abdomen, producing the inguinal canal; and, although the diverticulum disappears, the canal made by its passage may be looked upon, to a certain extent, as a source of weakness to the part of the wall through which it runs. The weakness, however, is more apparent than real, for the canal is so oblique in the adult that its abdominal opening, *the abdominal inguinal ring*, is one and a half inch distant from its superficial opening, the *subcutaneous inguinal ring*; the opening is, therefore, valvular and the intra-abdominal pressure, forcing the posterior wall against the anterior wall, tends to close the

canal; moreover, the constituent parts of the anterior and posterior walls are so arranged that weakness of one wall is compensated for by strength in the opposite wall. The dissector should now proceed to demonstrate the truth of these statements by making a special dissection of the inguinal region on the left side of the body, which has been kept intact for the purpose.

*Dissection.*—Begin by reflecting the aponeurosis of the external oblique. Make a vertical incision through it, parallel to the lateral border of the rectus, and carry the incision downwards on the medial side of the superior crus of the subcutaneous inguinal ring. The aponeurosis can thus be thrown downwards and laterally; and, at the same time, the subcutaneous ring is preserved. The internal oblique, cremaster, and falx inguinalis should now be cleaned, and their precise relations to the spermatic cord studied. Notice that the fleshy lower border of the internal oblique overlaps the upper part of the cord, whilst, towards the outlet of the inguinal canal, the falx inguinalis lies behind the cord. Next, replace the aponeurosis of the external oblique, and introduce the point of the forefinger into the subcutaneous ring and press directly backwards. Observe that the finger rests either upon the lig. inguinale reflexum, which lies anterior to the falx inguinalis, or, if the reflex inguinal ligament is absent, upon the falx inguinalis itself; that, in fact, the ligament and the falx and the fascia transversalis intervene between the finger and the extra-peritoneal fatty tissue and the peritoneum. The lower part of the internal oblique muscle should now be separated from the transversalis by insinuating the handle of the knife between them. When this is done, divide the internal oblique close to the inguinal ligament, and throw it medially. At the same time, make a longitudinal incision through the cremaster muscle, and turn it aside from the surface of the cord.

All further dissection must be effected from the inside. Divide the abdominal wall horizontally, from side to side, at the level of the umbilicus. When the lower part is raised and its posterior aspect is examined, three peritoneal folds are seen—the *plicæ umbilicales*—a median and two lateral. In the median fold lies the middle umbilical ligament or urachus, which descends from the umbilicus to the apex of the bladder, and in each lateral fold is the obliterated portion of the umbilical branch of the hypogastric artery of the corresponding side. Each lateral fold, with the contained obliterated artery, descends from the umbilicus to the side of the bladder, if the latter is distended, and to the lateral wall of the pelvis, if the bladder is empty. The lower part of the fold lies on the posterior surface of the abdominal wall, a short distance to the medial side of the abdominal inguinal ring. Still more lateral on each side is another fold caused by the inferior epigastric artery, as it ascends to the posterior aspect of the rectus abdominis. This fold is placed at a short distance to the lateral side of the lateral umbilical fold, but runs more or less parallel with it.

By means of these folds three fossæ are mapped out on each side of the middle line above the inguinal ligament; they are termed the supravesical, the medial, and lateral inguinal fossæ, and are regarded as determining, to some extent, hernial protrusions in the inguinal region. The supravesical fossa lies between the fold enclosing the middle umbilical ligament and that enclosing the obliterated part of the umbilical artery, and the subcutaneous inguinal ring is in front of its lower part, separated from it by the most medial part of the posterior wall of the inguinal canal. The medial inguinal fossa,

narrow but frequently very deep, lies between the fold containing the obliterated part of the umbilical artery and that containing the inferior epigastric artery. It is behind that part of the posterior wall of the inguinal canal which is formed by the transversalis fascia only. The lateral inguinal fossa lies to the lateral side of the fold formed by the inferior epigastric artery and its lowest, medial, and deepest part corresponds with the abdominal inguinal ring.

Having determined these points, the dissector can proceed as follows :— Divide the lower part of the abdominal wall in a vertical direction along the linea alba, from the umbilicus to the pubes. Make this incision a little on one side of the middle umbilical ligament, and, on nearing the pubic symphysis, be careful not to injure the bladder, which may project upwards beyond it. On throwing the left flap downwards and laterally, it may be possible to detect the position of the abdominal inguinal ring, from the fact that in some cases the peritoneum is slightly dimpled into it. Now strip the peritoneum from the flap as far down as the inguinal ligament. This can be easily done with the fingers, as its connection with the extra-peritoneal fatty tissue is very slight. Next, separate the extra-peritoneal fatty tissue from the fascia transversalis with the handle of the knife, proceeding with great care as the inguinal ligament is approached. The *abdominal inguinal ring*, or the inlet of the inguinal canal, is now seen from within. From this point of view the opening is more like a vertical slit in the fascia transversalis than a ring. Its lower and lateral margin will be seen to be specially strong and thick. Note the inferior epigastric artery passing upwards and medially, close to its medial margin. Further, observe the ductus' deferens and the spermatic vessels entering it; the former, as it disappears into the canal, hooks round the inferior epigastric artery. Introduce the tip of the little finger into the opening and push it gently along the line of the inguinal canal. Whilst the finger is still in the opening raise the flap of the abdominal wall and look at it from the front, then a very striking demonstration of the infundibuliform fascia will be obtained.

When the dissection is satisfactorily completed the student should note that there are three portions of each wall of the canal. At the medial end of the anterior wall lies the subcutaneous inguinal ring, covered, and to a certain extent closed, by the intercrural fibres descending on the spermatic cord. Immediately to the lateral side of the subcutaneous ring the anterior wall is formed by the aponeurosis of the external oblique only, and at its lateral end the anterior wall is composed of the external oblique aponeurosis and the lower fibres of the internal oblique muscle: the anterior wall, therefore, is weakest at its medial and strongest at its lateral extremity. The posterior wall, on the contrary, is strongest at its medial end and weakest at its lateral end. At its medial end, behind the subcutaneous inguinal ring, it is three layers thick, the layers, from before backwards, being the lig. inguinale reflexum, the falx inguinalis, and the transversalis fascia. More laterally, opposite the region where the anterior wall consists of external oblique aponeurosis alone, the posterior wall is formed by the transversalis fascia and the falx inguinalis, and still more laterally, where the anterior wall is formed by both external oblique aponeurosis and internal oblique muscle, the posterior wall is represented by transversalis fascia only. The walls of the canal are well adapted, therefore, to resist the effects of intra-abdominal pressure. The student must remember, however, that, for practical purposes, in association with the formation of hernia, the contents of the abdomen may be looked upon as being of a fluid or semifluid nature; consequently, if a portion of the abdominal contents happens to slip through the abdominal inguinal ring, into a persisting, though shrunken, processus vaginalis, the action of the abdominal pressure will, thenceforth, tend to

distend the inguinal canal and force the abdominal contents further and further along it, until they eventually protrude through the subcutaneous inguinal ring. The coverings of such a hernia will naturally be the constituent parts of the abdominal wall in the inguinal region: that is, from within outwards, (1) peritoneum, (2) extra-peritoneal fat, (3) infundibuliform portion of transversalis fascia, (4) cremasteric fascia, (5) intercrural fascia, (6) superficial fascia, and (7) skin. A hernia which travels obliquely through the abdominal wall, along the line of the inguinal canal, is called an *oblique inguinal hernia*, and, as the neck of the hernial sac lies to the lateral

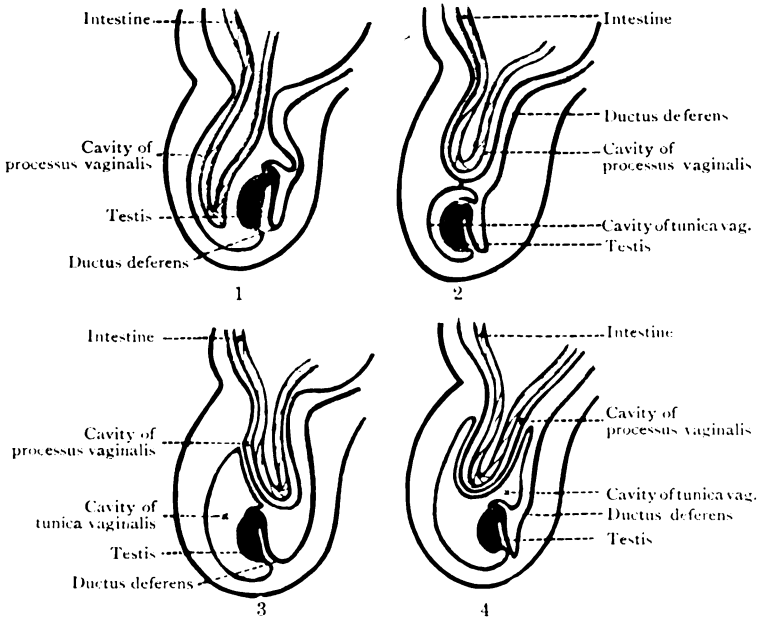


FIG. 159.—Diagram illustrating different forms of scrotal hernia.

side of the inferior epigastric, it is called a *lateral inguinal hernia*. If the cavity of the persisting processus vaginalis, into which the hernia has passed, is still continuous with the cavity of the tunica vaginalis, the herniated viscus or peritoneal fold will enter the tunica vaginalis of the testis; but, if the cavity of the upper part of the processus vaginalis has been separated from that of the lower part by the formation of an oblique or transverse septum, the upper part of the processus, with its contained hernia, may be forced downwards either anterior or posterior to the lower part, or the lower end of the upper part may invaginate the upper end of the lower part. Herniæ differentiated from each other by the relationship which the upper part of the processus, containing the herniated viscus, bears to the lower part, the tunica vaginalis, are described by surgeons under special names which the student will find fully explained in manuals of surgery. There are,

however, other forms of inguinal hernia which do not pass through the abdominal inguinal ring, but through the posterior wall of the canal, on the medial side of the inferior epigastric artery, and between it and the obliterated part of the umbilical artery, or, still more medially, between the obliterated part of the umbilical artery and the lateral border of the rectus. Such herniæ, because they do not pass obliquely along the inguinal canal but more directly through its posterior wall, are called by the surgeon *direct inguinal herniæ*. As there are no congenital diverticula of the peritoneum in these regions such herniæ must be due either to the slow distension of weak points in the posterior wall of the inguinal canal, under the influence of the intra-abdominal pressure, or to the instant rupture of such points when the pressure is suddenly increased. After a pouch of the posterior wall, containing gut, has been protruded into the canal, or after a portion of the peritoneal sac containing gut has been forced through the posterior wall into the canal, the action of the abdominal pressure will tend to force the protrusion along the line of least resistance, which is usually along the canal to the subcutaneous inguinal ring. The coverings of the direct hernia will differ according to whether the hernia has torn the posterior wall or forced it forwards as a covering, and, in the latter case, according to whether the hernia has passed from the medial inguinal pouch, between the inferior epigastric artery and the obliterated part of the umbilical artery, or through the supravesical pouch, at the medial side of the obliterated artery. The coverings of the hernia passing from the medial inguinal pouch will be the same as those of the oblique hernia, except that transversalis fascia will take the place of infundibuliform fascia; but if the hernia passes from the supravesical pouch, on the medial side of the obliterated part of the umbilical artery, it will push before it the falx inguinalis, it will enter the canal below the upper border of the cremasteric fascia, and it will receive no sheath from the latter fascia; from within outwards, therefore, its anatomical coverings will be—(1) peritoneum, (2) extra-peritoneal fat, (3) transversalis fascia, (4) falx inguinalis, (5) intercrural fascia, (6) superficial fascia, (7) skin. The student should understand also that whilst it is commonly believed that oblique herniæ are usually due to the persistence of a portion of the processus vaginalis there is no anatomical reason why a new peritoneal sac should not be formed in the region of the lateral inguinal fossa, that is, in the region of the abdominal inguinal ring, as easily as in other regions. If such a pouch were formed it would pass along the line of the canal, its coverings would be similar to those of a hernia which had passed into the upper persisting part of the processus vaginalis, and its relationship to the tunica vaginalis would depend largely upon the size of the latter sac, that is, upon how much of the lower part of the original processus remained unobliterated, and upon the more anterior or more posterior position of the upper end of the tunica vaginalis.

**Femoral Hernia.**—This consists in the protrusion of some abdominal contents from the abdominal cavity into the region of the thigh. In its descent it passes *behind* the inguinal ligament, along the *femoral canal* of the femoral sheath. It is consequently mainly the duty of the student who is engaged in the dissection of the lower limb, and within whose domain the femoral sheath lies, to investigate the anatomical connections of this variety of hernia (p. 185). Still, it is essential that the dissector of the abdomen should examine, from its abdominal aspect, the *femoral ring*, or aperture of communication between the femoral canal and the abdominal cavity, and give the dissector of the lower limb an opportunity of doing so likewise.

The *femoral ring* is placed immediately below the inguinal ligament, in the interval between the external iliac vein and the base of the lacunar

ligament (Gimbernat's). If the peritoneum is still in position at this point it may exhibit a slight dimpling or depression as it passes over the ring. Strip the peritoneum from the greater part of the iliac fossa. The extra-peritoneal fatty tissue, as it stretches across the femoral ring, will be observed to be denser, stronger, and more fibrous than elsewhere. A special name is applied to this small portion of the extra-peritoneal fatty tissue. Seeing that it is applied to the ring in such a manner as to close the femoral canal at its abdominal end, it is called the *septum femorale*. The extra-peritoneal fatty tissue should now be dissected away with the handle of the knife, to the same extent as the peritoneum. The *fascia iliaca*, clothing the iliacus and psoas muscles, is thus exposed, and the dissector should note that the external iliac vessels lie *inside* and not *outside* this fascia.

The student is now in a position to study the manner in which the *femoral ring* is formed. Let him follow the fascia iliaca and the fascia transversalis towards the inguinal ligament. If the dissection has been carefully performed it will be obvious that, to the lateral side of the external iliac vessels, these two fasciæ become directly continuous with each other, and, further, that along the line of union they are both firmly attached to the inguinal ligament. It is evident, then, that no hernial protrusion could leave the abdominal cavity behind the inguinal ligament lateral to the iliac vessels.

In the region of the iliac vessels the arrangement of the fascia will be found to be different. There the fascia iliaca is carried downwards behind the vessels, whilst the fascia transversalis is prolonged downwards in front of the vessels and behind the inguinal ligament. In the region of the thigh they together constitute a funnel-shaped sheath for the femoral artery and vein, and for some lymph vessels ascending to the abdomen. This sheath is divided into three compartments by two antero-posterior partitions. The femoral artery occupies the lateral compartment, and the vein the intermediate compartment, whilst the medial compartment, called the *femoral canal*, is occupied by the lymph vessels and, sometimes, by a small lymph gland.

An essential difference between these compartments is this—that whilst the lateral two are completely filled up by the artery and vein, the femoral canal is much wider than is necessary for the passage of its contents. Gauge the width of the femoral ring by introducing the point of the little finger. It is readily admitted within the opening. Here, then, is a source of weakness to the abdominal wall, and one which is greater in the female than in the male, seeing that the distance between the iliac spine and pubic tubercle is proportionally greater in the female, and, in consequence, the femoral ring wider.

When the finger is within the ring, mark the structures which surround it—*anteriorly*, the inguinal ligament, with the spermatic cord or round ligament of the uterus; *posteriorly*, the ramus of the pubis, giving origin to the pectineus muscle, which is covered by the pectineal portion of the fascia lata; *medially*, the sharp, crescentic free border of the lacunar ligament; and *laterally*, the external iliac vein.

It is still more necessary to note the relations of the blood-vessels to the femoral ring. The *external iliac vein* has been seen to lie to its lateral side. The *inferior epigastric artery*, as it ascends on the posterior aspect of the abdominal wall, is close to its upper and lateral margin, and sends its *pubic branch* medially in front of it. More important than any of these is the relation of the *obturator artery*, when it takes origin from the inferior epigastric. This anomalous vessel may adopt one of three courses:—(1) It may follow the course of the pubic artery, an

enlarged form of which it in reality is, and pass medially *in front* of the ring, and then descend along its *medial* margin. In that case, the ring is surrounded on all sides, except posteriorly, by important vessels. (2) It may pass downwards and backwards across the femoral ring. (3) It may run downwards between the ring and the external iliac vein (*vide* p. 185).

Medial to the femoral sheath the passage of a hernial protrusion behind the inguinal ligament is effectually prevented by the lacunar ligament.

Femoral hernia is more common in females, and inguinal hernia in males; and for the very evident reason that, in the female, the femoral canal is relatively larger, whilst in the male the passage of the spermatic cord weakens the inguinal region more than the passage of the small round ligament of the uterus in the female.

**Umbilical Hernia.**—If the dissector examines the umbilicus he will find that he is dealing with a dense fibrous ring which embraces and fuses with the remains of the umbilical vein, the remains of the obliterated parts of the umbilical arteries and the urachus, the whole forming a dense nodule of fibrous tissue closely connected with the superjacent skin. The umbilicus marks the position where, during a large part of intra-uterine life, the peritoneal cavity was prolonged through the abdominal wall into the root of the umbilical cord, which attached the fœtus to the mother. For a considerable time a portion of the gut lies in the extra-abdominal sac in the root of the umbilical cord, but, before birth, it is withdrawn into the abdomen and the sac shrinks and disappears. If a remnant of the sac persists in the substance of the abdominal wall, after birth, the wall is weakened and a portion of the abdominal contents may be forced into the diverticulum, causing its distension and producing an umbilical hernia. The anatomical coverings from within outwards would be—(1) peritoneum, (2) aponeuroses of the abdominal wall equivalent to the stretched linea alba, (3) superficial fascia, (4) skin.

If the fœtal condition persists until birth a portion of the gut lies in the umbilical cord, separating the three vessels; and more than one case has occurred in which the bowel has been cut when the cord was divided after the birth of the child.

## ABDOMINAL CAVITY.

When the dissector has completed his examination of the regions where hernia most commonly occurs he should proceed to study the abdominal cavity and its contents. The abdomen must be more completely opened by an incision carried upwards, from the umbilicus to the xiphoid process, immediately to the left side of the median plane. When the two flaps, thus formed, are thrown upwards and laterally, over the lower margin of the thorax, a strong fibrous cord, the *ligamentum teres*, will be seen extending from the umbilicus to the inferior surface of the liver. It is the remains of the left umbilical vein of the fœtus. As it ascends towards the liver, it gradually recedes from the

posterior surface of the anterior abdominal wall, taking with it a fold of peritoneum termed the *falciform ligament* of the liver.

**Shape and Boundaries of the Abdominal Cavity.**—The abdominal cavity is ovoid in shape, its vertical diameter being the longest. *Superiorly*, it is roofed by the dome-shaped diaphragm, which presents a deep concavity towards the abdomen. *Inferiorly*, it is floored by the pelvic diaphragm, formed by the levatores ani and the coccygei muscles, which also is concave towards the abdominal cavity. Neither the roof nor the floor is complete and unbroken. The diaphragm is perforated by certain structures which pass between the thorax and the abdomen. The continuity of the pelvic diaphragm is broken by the passage of certain structures between the pelvic division of the abdominal cavity and the perineum. The upper part of the abdominal cavity extends upwards for a considerable distance under the shelter of the lower ribs and their costal cartilages. The protection which is thus afforded to the viscera in this portion of the cavity is most complete laterally and posteriorly. Anteriorly, as the costal cartilages ascend towards the sternum, a wide Λ-shaped gap is left between those of opposite sides. The level to which the costal arches descend on either side varies greatly in different subjects, but, in the great majority of cases, a narrow belt of abdominal wall, from one to two inches wide, is left between the lower border of the chest wall and the highest point of the iliac crest. This receives no skeletal

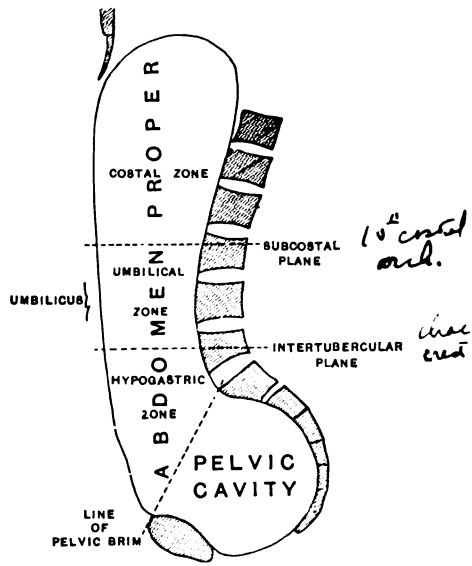


FIG. 160.—Outline of the Abdominal Cavity as seen in median section. The planes of subdivision are indicated by dotted lines.

support beyond that which is afforded by the vertebral column.

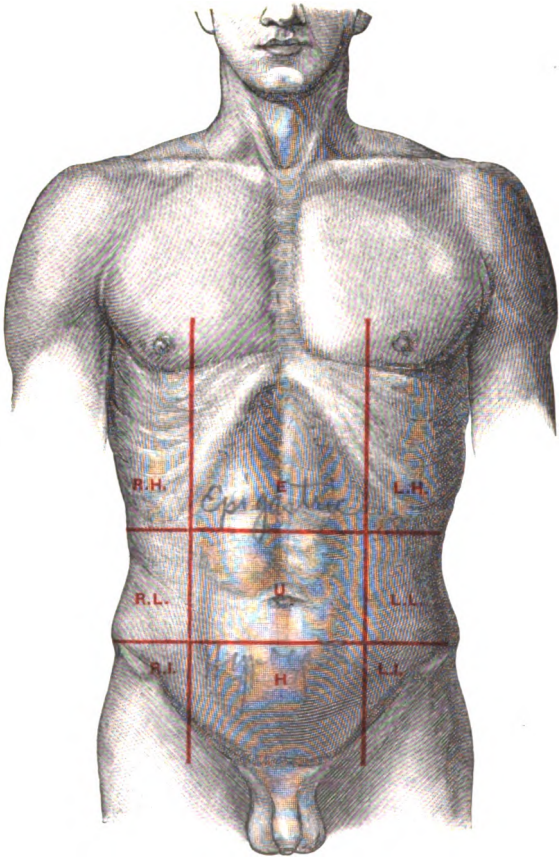


FIG. 161.—Planes of subdivision of the Abdominal Cavity.

R.H. Right hypochondrium.
R.L. Right lumbar region.
R.I. Right iliac region.
E. Epigastric region.
U. Umbilical region.
H. Hypogastric region.
L.H. Left hypochondrium.
L.L. Left lumbar region.
L.I. Left iliac region.

Inferiorly, the expanded iliac bones give support to the abdominal walls posteriorly and laterally, whilst, in its lowest

part, the pubic, ischial, sacral, and coccygeal bones form very complete bony boundaries for the cavity.

Whilst the abdominal cavity, therefore, is very fully protected, posteriorly and laterally, by skeletal parts, the anterior wall is almost entirely formed by the muscles and aponeuroses which have already been dissected.

From this it will be seen that the roof, floor, and the greater part of the abdominal wall are composed of muscular structures, the contraction of which would diminish the capacity of the cavity and subject the contained viscera to compression.

**Subdivision of the Abdominal Cavity.**—In dealing with so large a cavity, and one which contains such a diversity of contents, it is convenient to subdivide it into regions, in order that the precise position of each viscus may be accurately defined. In making the first subdivision, advantage is taken of the brim of the pelvis minor. That part of the cavity which is situated above this is termed the **abdomen proper**; whilst the part which lies below it is called the **pelvis minor.** These two portions of the general abdominal cavity do not lie the one directly over the other. The long axis of the abdomen proper is very nearly vertical; that of the small pelvis is very oblique, and directed backwards and downwards. Indeed, the small pelvis presents the appearance of a recess leading backwards and downwards from the lower and posterior part of the abdominal cavity (Fig. 160).

The abdomen proper is still further subdivided by means of four arbitrary planes of section. Two of these are supposed to pass through the body in a horizontal direction, and two in a vertical direction. The former are termed the *subcostal* and the *intertubercular planes* of subdivision, and the position of each is determined as follows:—A horizontal line is drawn around the body at a level corresponding to the most dependent parts of the tenth costal arches. This gives the position of the subcostal plane. A second line is drawn horizontally around the trunk so as to pass, on each side, through the highest point on the iliac crest that is seen from the front. This point is always easily determined, as a prominent tubercle juts out from the external lip of the iliac crest at this level. It is situated rather more than two inches behind the anterior superior iliac spine, and it marks the point where the outline of the trunk meets the iliac crest. The

line which encircles the body at this level indicates on the surface the position of the intertubercular plane of subdivision.

The two horizontal planes, thus placed, map out the abdomen into three districts or zones, which are termed, from above downwards—(1) the *costal*, (2) the *umbilical*, and (3) the *hypogastric zone*.

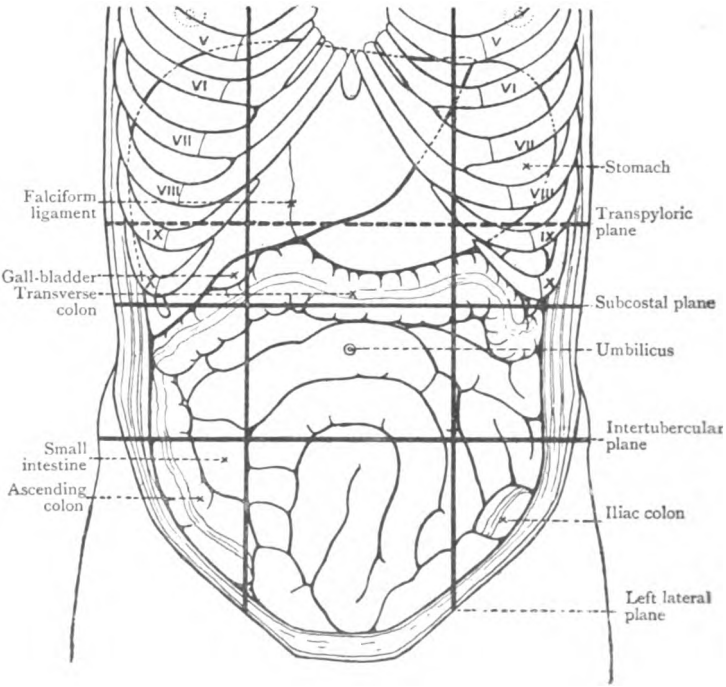


FIG. 162.—The Abdominal Viscera, as seen from the front, after removal of the greater omentum. The dark lines indicate the subdivision of the abdominal cavity. (Birmingham.)

The two vertical planes of subdivision are called the *right* and *left lateral planes*. Each corresponds, on the surface, to a perpendicular line reared from the midpoint between the symphysis pubis and the anterior superior spine of the ilium.

By these lateral planes, each of the three zones determined by the horizontal planes of section is subdivided into three.

The costal zone is mapped off into a central, *epigastric*

*region* and a *right* and a *left hypochondriac region*; the umbilical zone, into a central, *umbilical region* and a *right* and a *left lumbar region*; and the hypogastric zone, into a central, *hypogastric region* and a *right* and a *left iliac region*.

**Contents of Abdomen Proper.**—The following structures lie within the abdominal cavity.

1. Abdominal part of the alimentary canal. { Stomach. Small intestine. Large intestine.
2. Glands situated outside the walls of the alimentary canal and pouring their secretions into it. { Liver, with its gall-bladder or reservoir. Pancreas.
3. The spleen.
4. The two kidneys, the ureters, and the two suprarenal glands.
5. Lymph glands, lymph vessels, the cisterna chyli, and the commencement of the thoracic duct.
6. The abdominal aorta, with its various visceral and parietal branches.
7. The inferior vena cava and its tributaries, and the commencements of the vena azygos and hemiazygos.
8. The vena portæ and its tributaries.
9. The lumbar plexuses of nerves.
10. The abdominal portions of the sympathetic nervous system.
11. The peritoneal membrane, which lines the cavity and invests the viscera.

When the abdominal cavity is opened, a very partial view of the contained viscera is obtained, so long as they are left undisturbed. On the right side of the costal zone the sharp margin of the liver may be observed, projecting slightly below the ribs, whilst, opposite the ninth costal cartilage, the fundus of the gall-bladder is seen peeping out from under cover of the liver, and projecting slightly beyond its anterior border. In the same zone, to the left of the liver, a portion of the stomach is visible, whilst extending downwards from the greater curvature or anterior border of this viscus is a broad apron-like fold of peritoneal membrane, called the *greater omentum*. This usually contains a quantity of fat in its meshes, and is spread out like an apron, so as to hide from view the viscera which occupy the lower two zones. Sometimes, however, the greater omentum is narrow and short; or it may be turned more or less completely upwards or to one side. In either case some of the coils of the small intestine will be seen, and also, in all probability, those parts of the large intestine which occupy the right and left iliac fossæ. The part lying in the right iliac fossa is called the *cæcum*, whilst the part situated in the left iliac fossa is the *iliac colon*. It

may also chance that the bladder is full, in which case its apex will be observed projecting above the pubes. Lastly, in pregnant females the gravid uterus will be visible, reaching a height which corresponds with the period of gestation.

Raise the greater omentum and turn it upwards over the inferior margin of the thorax. By this proceeding the coils of the small intestine are exposed, and a part of the large intestine which extends across the cavity of the abdomen will be seen attached to the posterior part of the greater omentum. This is the *transverse colon*

Note that all the viscera which have been seen are covered by a smooth glistening membrane, *the peritoneum.* This membrane forms the immediate boundary of a space, *the peritoneal cavity*, which has been opened into by the reflection of the anterior wall of the abdomen. The dissector should recognise that under normal circumstances the peritoneal cavity is merely a potential cavity, and that it becomes an actual cavity only when the surgeon or dissector pulls its walls apart in opening into it, or when its walls are forced apart by abnormal collections of fluid or gas.

Replace the greater omentum and commence a fuller consideration of the general position, relations, and connections of the viscera by examining the general position of the liver.

**Hepar.**—The liver is the large, reddish-brown organ which occupies a large part of the upper portion of the abdomen, where it lies in the epigastric region and both hypochondriac regions. A very large portion of its surface is in contact with the diaphragm, which separates it from the contents of the lower part of the thorax. The inferior border of its anterior surface is seen crossing the subcostal angle from above downwards and to the right, and continuing to the right either along or immediately below the right costal arch. Opposite the tip of the ninth right costal cartilage the fundus of the gall-bladder projects from beneath it. Pass the hand over the anterior and upper surfaces of the liver, and note that they are connected to the anterior abdominal wall and to the diaphragm, respectively, by a fold of the peritoneal lining of the abdomen which is called the falciform ligament. Raise the inferior margin of the liver and note that the lower and posterior surfaces of the liver are connected to the stomach by a fold of peritoneum called the *lesser omentum.*

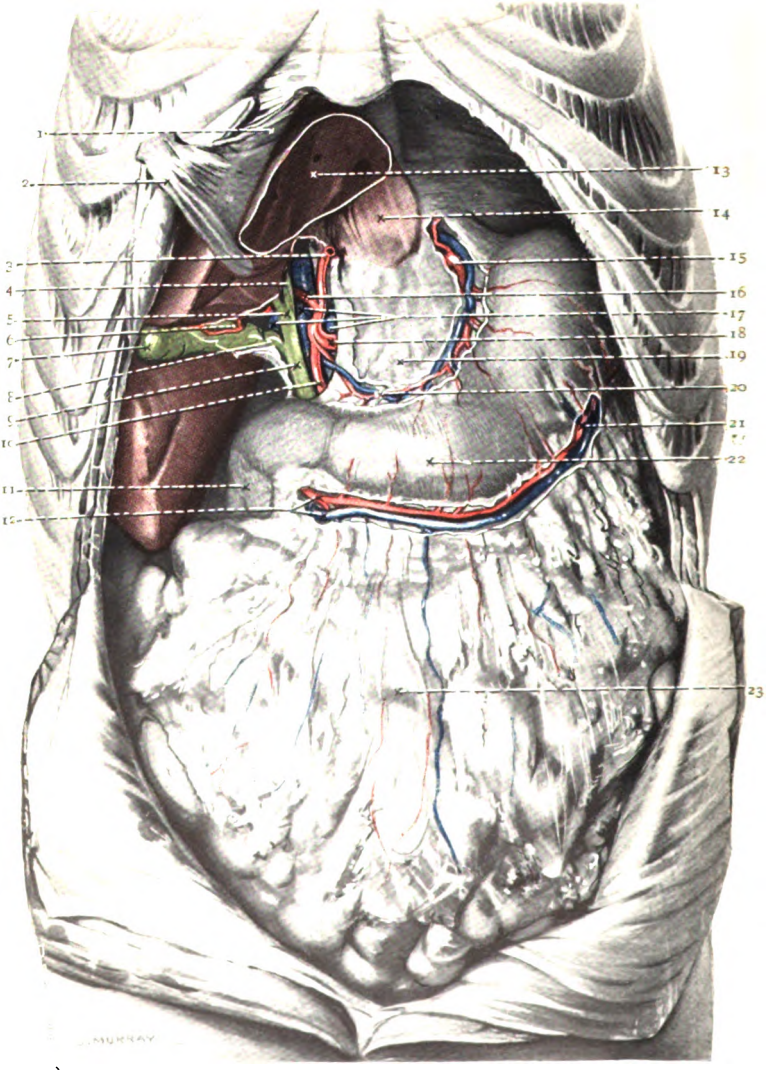


*To face page* 433.

FIG. 163.—View of the Interior of the Abdomen.

The upper part of the anterior wall of the abdomen has been removed. The lower part has been divided in the median plane and turned aside.

The greater part of the left lobe of the liver has been removed and the pyloric part of the stomach has been displaced downwards.

The liver is seen in the upper and right portion of the abdominal cavity, with the gall-bladder and the cystic artery on the inferior surface of its right lobe.

The round ligament of the liver and the falciform ligament have been pulled over the right costal arch and have been fixed to the wall of the thorax. From the point of attachment the round ligament runs downwards and backwards to the umbilical fossa of the liver, and the falciform ligament extends backwards to the anterior and upper surfaces of the liver.

Below and to the left of the liver is the stomach, which is connected to the liver by a fold of peritoneum called the lesser omentum. From the lower border of the stomach the greater omentum hangs down in front of the contents of the lower part of the abdominal cavity.

The anterior layer of the lesser omentum has been removed along the upper or lesser curvature of the stomach, to display the right and left gastric vessels, which lie between the two layers; and it has been removed also along the right or free margin of the omentum, to display the hepatic artery and its branches, the portal vein and the bile duct, the cystic duct and the common hepatic duct.

By the displacement downwards of the pyloric end of the stomach, the gastro-duodenal branch of the hepatic artery has been brought into view.

The anterior layer of the greater omentum has been removed along the lower part of the greater curvature of the stomach to display the right and the left gastro-epiploic vessels.

1. Falciform ligament.
2. Ligamentum teres.
3. Left hepatic artery.
4. Left hepatic duct.
5. Common hepatic duct.
6. Cystic artery.
7. Fundus of gall-bladder.
8. Cystic duct.
9. Bile duct.
10. Gastro-duodenal artery.
11. Duodenum, 2nd part.
12. Right gastro-epiploic vessels.
13. Face of section of left lobe of liver.
14. Caudate lobe, seen through lesser omentum.
15. Left gastric artery.
16. Right hepatic artery.
17. Portal vein.
18. Hepatic artery.
19. Lesser omentum.
20. Right gastric vessels.
21. Left gastro-epiploic artery.
22. Stomach.
23. Greater omentum.

Fasten the lower border of the anterior surface of the liver to the right costal arch and examine the stomach.

**Ventriculus.**—The stomach is a pear-shaped organ which lies in the left hypochondriac and epigastric regions, partly below and partly to the left side of the liver. Its long axis runs obliquely and is curved upon itself, the base or *fundus* of the organ being situated above, behind, and to the left, whilst the apex or *pylorus* lies lower, more anteriorly, and more to the right. Traced from its highest to its lowest point, it runs first forwards and slightly downwards, then to

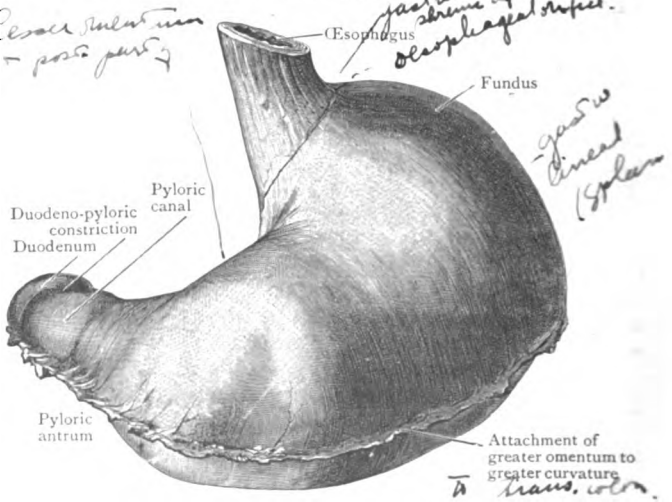


FIG. 164.—Stomach of a Child, two years of age, hardened *in situ* by formalin injection.

the right, and finally slightly backwards to its junction with the duodenum or proximal portion of the small intestine. When the left lobe of the liver is pulled upwards and to the right the œsophagus will be found entering the stomach a little to the right of the highest point of the fundus, at the *cardiac* or *œsophageal orifice*. From this point the two borders of the stomach can be traced to the pyloric end of the organ. The upper border or *lesser curvature* is much the shorter; it runs downwards and to the right in a fairly uniform curve. The *greater curvature* is much longer. First it ascends from the œsophagus to the highest point of the fundus. After crossing

the fundus it runs forwards and downwards with a marked convexity to the left; finally it runs to the right and slightly backwards with a convexity downwards. The second portion is frequently spoken of as the left lateral border and the last portion as the inferior border of the stomach; the junction of these two parts is commonly the lowest portion of the organ and, when the body is recumbent, it lies on a level with the tips of the tenth costal cartilages, but in the erect posture and when the stomach is full it may descend to a much lower point, even to the level of the umbilicus or still lower. The dissector will find that the lesser curvature is attached to the lower and posterior surfaces of the liver by a fold of peritoneum which is called the *lesser omentum*. The part of the greater curvature immediately adjacent to the œsophagus is attached to the diaphragm by a peritoneal fold, the *gastro-phrenic ligament*; the descending part of the greater curvature is attached to the spleen by the *gastro-lienal ligament* (O.T. *gastro-splenic omentum*); and the lower part of the greater curvature is connected with the transverse colon by the *greater omentum*. The first of these connections can be demonstrated by pulling the stomach downwards, the second, by pulling it to the right, and the last, by raising the greater omentum, which hangs down from the lower border, and turning it upwards over the lower margin of the costal arch. The surfaces of the stomach are an anterior or superior and a posterior or inferior. The latter cannot be seen at the present stage of dissection; it rests on the stomach bed. The anterior is directed upwards and forwards; and the student should note that it is in relation to the left and above with the diaphragm, below with the anterior wall of the abdomen, in the region of the subcostal angle, and above and to the right with the lower surface of the liver. After examining the stomach the dissector should look for the spleen.

**Lien (The Spleen).**—The spleen cannot be seen, when the abdominal organs are undisturbed, if it is of normal size and is lying in its normal position, but it can easily be felt if the hand is passed backwards, round the left margin of the stomach, into the posterior part of the left hypochondriac region, and it can be brought into view by pulling the stomach towards the right side. When this has been done the spleen will be found to be attached to the stomach by the gastro-lienal ligament

(omentum) and to the anterior surface of the left kidney, which can easily be felt, by a fold of peritoneum called the *lieno-renal ligament*. At the same time the dissector should note that the lower end of the spleen is supported by an angular bend of the large intestine, called the *left colic flexure*, and by a fold of peritoneum, the *phrenico-colic ligament*, which connects the left colic flexure with the lower surface of the diaphragm, at the level of the eleventh rib in the mid-axillary line.

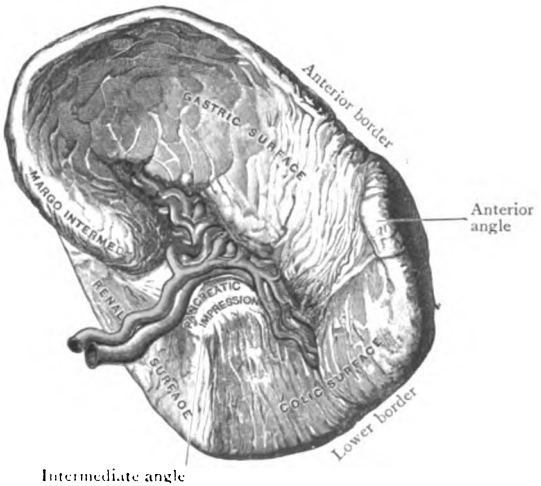


FIG. 165.—The Spleen (visceral aspect).

**Intestinum (The Intestine).** — When the dissector has satisfied himself regarding the general position and attachments of the liver, stomach, and spleen, he should familiarise himself with the parts, position, and the attachments of the intestine. There are two main parts of the intestine, the small and the large. They cannot, however, be distinguished from each other by size alone, for the calibre of each part varies according to the state of contraction or relaxation of its muscular walls.

**Intestinum Tenue.**—The small intestine commences at the pyloric end of the stomach, under cover of the liver, which must be raised to expose it. The termination of the stomach and the commencement of the intestine is marked by

a thick ring of muscle fibres, the *valvula pylori* (O.T. *pyloric sphincter*), and in many cases by a distinct constriction due to the contraction of the sphincter. The first part of the intestine runs backwards from the pylorus to the upper part or *neck* of the gall-bladder, where it turns downwards and disappears from view behind a portion of the large intestine

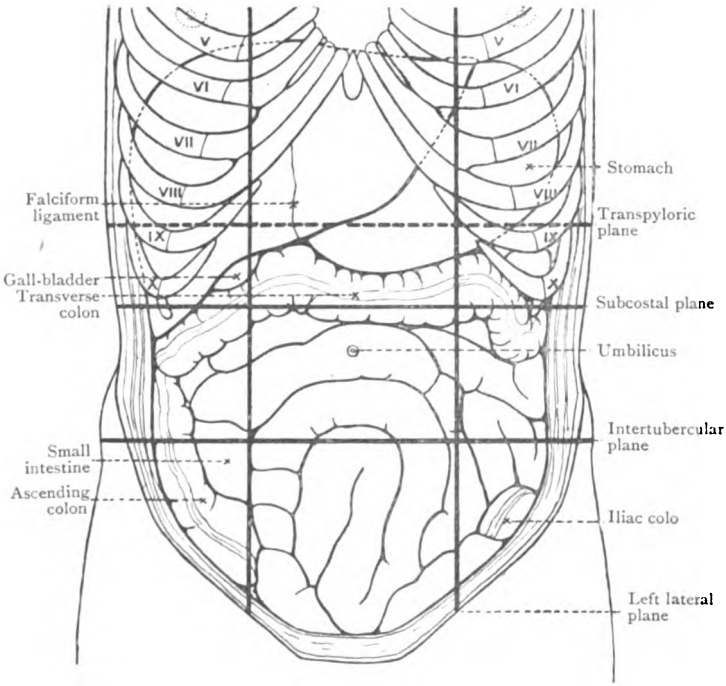


FIG. 166.—The Abdominal Viscera, as seen from the front, after removal of the greater omentum. The dark lines indicate the subdivision of the abdominal cavity. (Birmingham.)

called the transverse colon. To trace it further, turn the greater omentum upwards over the lower part of the thoracic wall and expose the area below and behind the omentum. The central and greater portion of this area is filled with coils of the small intestine, but at the lateral and upper borders of the area portions of the large intestine are seen.

A mere glance is sufficient to distinguish the small from

the large intestine. The chief points of difference are—(1) The wall of the small intestine is smooth and uniform, whereas the wall of the large intestine is puckered and sacculated. (2) The longitudinal muscle fibres in the wall of the small intestine are distributed uniformly round the tube, but in the large intestine they are collected into three longitudinal bands, *tæniæ coli*, which are separated from each other by intervals and are distinctly visible to the naked eye. These bands are shorter than the tube itself; consequently the walls of the tube are puckered. (3) Attached to the great intestine are the *appendices epiploicæ*. These are small peritoneal pouches, containing fat, which hang from the free border of the gut.

The dissector should attempt to pull the small intestine forwards, and he will find that it is attached to the posterior wall of the abdomen by a fold of peritoneum, called *the mesentery*, which runs obliquely downwards and to the right, from the level of the left side of the second lumbar vertebra to the right iliac fossa. The parts of the large intestine lying to the right of the mass of coils of small intestine are the cæcum below and the ascending colon above. The part crossing from side to side, above the small intestine, now that the greater omentum is reversed, but which is normally in front of the small intestine, is the transverse colon; it is attached to the posterior wall of the abdomen by a fold of peritoneum called the *transverse meso-colon*. The parts to the left of the coils of the small intestine are, from above downwards, the descending colon in the lumbar region, and the iliac colon in the left iliac region. The portion of the small intestine which is attached to the posterior wall of the abdomen by the mesentery is arbitrarily divided into two parts, an upper two-fifths, called *jejunum* (*intestinum jejunum*), and a lower three-fifths, called *ileum* (*intestinum ileum*). Pull the jejunum and ileum downwards and to the left and follow the mesentery to its highest point, where the jejunum will be found to become continuous at a distinct flexure, the *duodeno-jejunal flexure*, with a portion of the small intestine which is not enclosed in the mesentery but lies behind the peritoneum below the arch of the transverse meso-colon; this is the terminal part of the first portion of the small intestine—the duodenum. If the dissector will now hold the omentum forwards he will be able to trace the duodenum from the

pyloric end of the stomach, first backwards to the neck of the gall-bladder, then downwards behind the transverse colon and meso-colon, to the right of the median plane, and finally from right to left, behind the upper part of the mesentery, to the duodeno-jejunal flexure, where it becomes continuous with the jejunum. He will thus demonstrate the continuity of the three portions of the small intestine. Next he should follow the mesentery downwards into the right iliac fossa, where he will find that the terminal portion of the ileum joins the large intestine, a short distance above the lower end of the latter and on its left side. The portion of the large intestine below the entrance of the ileum is a sac which terminates blindly below and is called the *cæcum* (*intestinum cæcum*). Turn the cæcum and the lowest part of the ileum upwards and to the right to expose the *vermiform process*, which springs from the medial and posterior aspect of the cæcum a short distance below the ileo-cæcal junction. The cæcum is continuous above with the *ascending colon*, which must be traced upwards to the right hypochondriac region where, under cover of the anterior part of the lower surface of the liver, it joins the transverse colon at an angular bend, the *right flexure of the colon* (O.T. *hepatic flexure*). The *transverse colon* extends across the abdomen from the right to the left hypochondriac region, forming a bold curve with the convexity directed downwards and forwards. It is connected to the stomach by the greater omentum and to the posterior wall of the abdomen by the transverse meso-colon. It is exposed when the omentum is turned upwards over the lower part of the costal arch and it will be found to terminate, immediately below the inferior extremity of the spleen, by joining the *descending colon* at a second angular bend, the *left flexure of the colon* (O.T. *splenic flexure*). The descending colon passes downwards through the left lumbar region, and at the level of the iliac crest it becomes the *iliac colon*, which runs downwards and medially across the left iliac region, parallel with the inguinal ligament, to the brim of the pelvis minor, where it becomes the *pelvic colon*. To expose the pelvic colon lift the coils of small intestine out of the pelvis. It will then be found either that the pelvic colon runs first across to the right side of the pelvis, above the bladder, then back to the left side, and finally downwards and medially to the third piece of the sacrum, where it becomes continuous with the

*rectum*; or that the first loop, instead of lying on the upper surface of the bladder, hangs down into the pelvis close to its left lateral wall. The *rectum* commences at the termination of the pelvic colon and runs downwards and forwards to end in the anal canal. Only its upper part can be seen at present, the lower part being concealed by the bladder, and in the female by the vagina (see Fig. 171).

If the subject is a female the **uterus** will be found occupying the central part of the pelvis. It lies between the rectum behind, and the bladder in front, and is connected on each side to the lateral wall of the pelvis by a fold of peritoneum called the *broad ligament* (see Figs. 171 and 247).

The dissector should notice that the cæcum presents the appearance of a blind diverticulum clothed on all sides with peritoneum; that the transverse colon and the pelvic colon are attached to the posterior wall of the abdomen by folds of peritoneum called mesenteries; that the vermiform process is attached to the posterior surface of the mesentery of the ileum by a fold of peritoneum called the *mesentery of the vermiform process* (O.T. meso-appendix), and that the remaining parts of the large intestine are not, as a rule, provided with mesenteries, but that they lie against the posterior wall of the abdomen, projecting forwards against the peritoneum which covers them only anteriorly and on the sides.

After the dissector has familiarised himself with the positions, continuity, and attachments of the various parts of the abdominal portion of the alimentary canal he should proceed to locate the kidneys. Throw the omentum upwards, pull the small intestine downwards and to the right, and examine the concavity of the left flexure of the colon, where a considerable part of the lower portion of the left kidney can be *seen and felt*, lying behind the peritoneum. Pull the small intestine over to the left and downwards, examine the concavity of the right flexure of the colon, and note that only a small part of the lower portion of the right kidney can be felt and seen in this situation, behind the peritoneum. Replace the small intestine and the omentum, pull the liver upwards and to the right, and the greater part of the upper portion of the right kidney will be exposed or can be felt in the region immediately above the right flexure of the colon. Replace the liver and pass the hand backwards into the posterior part of the left hypochondrium, to the back of

the spleen, and palpate the upper and lateral part of the left kidney, as it lies against the diaphragm.

The positions and connections of the various viscera must now be studied in greater detail. Commence with the consideration of the liver.

**Hepar (The Liver).**—The liver has already been seen crossing the costal angle and projecting below the right costal margin. It is the largest gland in the body, and is a solid pliant organ, which occupies a large part of the

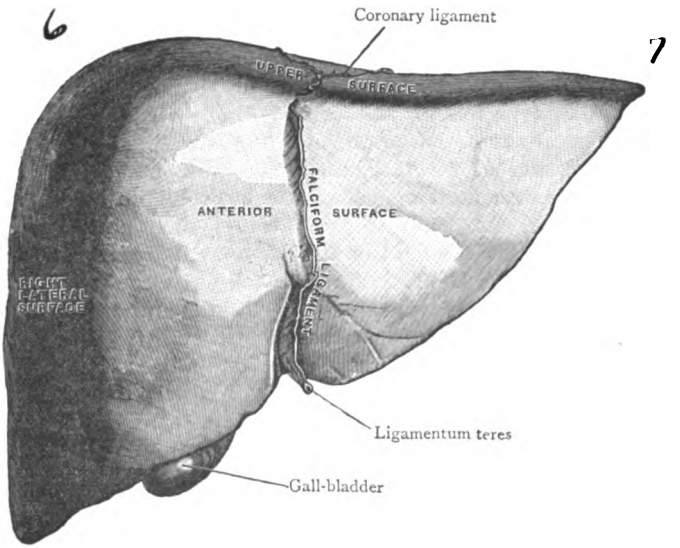


FIG. 167.—Anterior Surface of the Liver.

epigastric and right hypochondriac regions, and smaller portions of the left hypochondriac and right lumbar regions. It is almost entirely surrounded by the peritoneal lining of the abdomen. The portions which can be investigated, at the present stage of dissection are smooth to the touch, and they present a smooth and glistening appearance. The dissector should pass his hand over the surfaces of the organ and he will find that it has the form of an irregular four-sided pyramid. The *base* of the pyramid lies to the right, where it is in contact with the diaphragm, from the level of the seventh to the level of the eleventh rib in the mid-

axillary line. The edge-like *apex* lies to the left, at the level of the left sixth rib in or near the left lateral plane. The *anterior* and *superior* surfaces are smooth and convex. The anterior is attached to the anterior abdominal wall, and the superior to the under surface of the diaphragm, by a fold of peritoneum, called the falciform ligament, which separates each surface into a smaller left and a larger right portion, corresponding to the left and right lobes of the liver respectively.

The anterior surface is triangular in outline. It passes gradually, over rounded and indistinct borders, into the superior surface and the base, but it is separated from the inferior surface by a sharp and definite margin. Its left and right portions are in contact with the diaphragm, and the intermediate part is in contact with the anterior wall of the abdomen in the region of the subcostal angle. Its position can be indicated on the surface by three lines. (1) The first commences at the level of the left sixth rib in the left lateral plane, and ends to the level of the right sixth rib midway between the right lateral plane and the right border of the body. (2) The second commences at the same point as the first and passes obliquely downwards and to the right to the tip of the tenth right costal cartilage. (3) The third connects the right extremities of the first and second.

The *superior surface* is accurately adapted to the lower surface of the diaphragm, which separates it from the lungs and pleuræ, and from the heart and pericardium. Immediately below the heart it is slightly concave, but to the right and left of the cardiac concavity it is markedly convex, and more convex on the right than on the left side. Pass the hand backwards over the upper surface of the right lobe and note that in the right lateral plane it rises to the level of the fourth intercostal space, or even to the lower border of the fourth rib.

Pass the hand still further back over the upper surface, and note that at the junction of the superior and posterior surfaces a layer of peritoneum, the upper layer of the *coronary ligament*, passes from the liver to the diaphragm. Carry the fingers to the right along the coronary ligament round to the base where, at the junction of the base with the posterior surface, a triangular fold of peritoneum, the *right triangular ligament*, will be found, connecting the liver with the diaphragm. Now pass the hand over the upper surface of the

left lobe, and note that before the posterior border is reached the fingers are carried up to the diaphragm by a triangular fold of peritoneum, the *left triangular ligament* (see Fig. 200).

Examine the lower border of the anterior surface; note that it is cleft at the lower margin of the attachment of the falciform ligament by a notch, the *umbilical notch.* Through that, between the right and left lobes, the ligamentum teres, which lies in the rounded lower margin of the falciform ligament, passes into the umbilical fossa on the lower surface of the liver. Further to the right, in or near the right lateral plane and opposite the tip of the ninth right costal cartilage, the fundus of the gall-bladder projects below the liver, in the majority of cases.

Raise the lower margin of the liver and examine the *inferior surface.* It looks downwards, backwards, and to the left, and, over the whole of its extent, it is in contact with other viscera; on this account it is frequently called the *visceral surface.* It conceals the upper and right portion of the anterior surface of the stomach, the first part and the upper portion of the second part of the duodenum, the lesser omentum, the greater part of the gall-bladder; to the right of the gall-bladder it is in relation, posteriorly, with a large portion of the anterior surface of the right kidney, and, more anteriorly, with the right flexure of the colon (see Fig. 169). It is divided into right and left portions by a fossa, the *umbilical fossa*, which contains the ligamentum teres. This fossa extends from the umbilical notch in the lower border of the anterior surface to the junction of the inferior and posterior surfaces, where it becomes continuous with the fossa for the ductus venosus. Trace the lesser omentum upwards to the lower surface of the liver, and note that it is attached to the margins of a fissure which extends from the neck or uppermost part of the gall-bladder on the right to the umbilical fossa on the left. This is the *porta hepatis* or transverse fissure; it lies at the junction of the inferior with the posterior surface. Note, further, that the upper border of the lesser omentum is continued upwards on the posterior surface of the liver, where it is attached to the bottom of the fossa for the ductus venosus.

The posterior surface, which is largely in relation with the diaphragm, cannot be conveniently examined at present (see Fig. 200).

**Vesica Fellea (The Gall-Bladder).**—Pull the liver upwards and to the right, and examine the position, the attachments, and the connections of the gall-bladder. It is a small pyriform sac, with a capacity of from one to two ounces. It lies in the right hypochondriac region, close to the right lateral plane. Its lower extremity or fundus projects below the lower margin of the anterior surface of the liver, at the level of the ninth right costal cartilage, in the right lateral plane and immediately to the right of the lateral border of the right rectus abdominis muscle. From that point the body of the organ runs upwards, backwards, and to the left, to the right extremity of the porta hepatis, where a constricted portion of its upper end, called the *neck*, becomes continuous with the *cystic duct*, which connects the gall-bladder with the bile-duct. The upper and anterior surface of the body of the gall-bladder is embedded in a sulcus on the inferior surface of the right lobe of the liver, which is called the fossa for the gall-bladder; and it is attached to the liver by areolar tissue and by a number of small veins which pass from the gall-bladder into the substance of the liver, where they communicate with branches of the portal vein. The fundus and the lower or posterior surface are covered with peritoneum, and the lower surface is in contact, posteriorly and above, with the first and second parts of the duodenum, and below with the transverse colon.

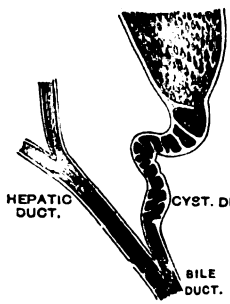


FIG. 168. — Diagram of the Cystic and Hepatic Ducts. (From Gegenbaur, modified.)

The cystic duct is enclosed in the right extremity of the upper border of the lesser omentum.

*Dissection.*—Make a longitudinal incision through the lower surface of the gall-bladder from the fundus to the neck, and examine the structure of its walls and its lining membrane. In addition to its partial serous covering it has (1) a strong coat composed of muscular and white fibrous tissue, and (2) an internal mucous coat. The mucous membrane is stained green by the bile, and it presents a honeycombed appearance, being raised into numerous ridges which surround polygonal depressions; in the neck the ridges assume a spiral form and constitute the so-called *spiral valve* of Heister, which is continued into the cystic duct.

To obtain a satisfactory view of the lesser omentum and its contents the left lobe of the liver must be removed. Cut through it from before back-

wards, immediately to the left of the line of attachment of the falciform ligament. On the lower surface the knife must be carried backwards along the umbilical fossa, close to its left margin, and it must emerge on the posterior surface in the fossa for the ductus venosus and close to the left margin of that fossa (see Fig. 170).

The portion of liver removed must be carefully preserved so that it may afterwards be re-attached to the right lobe.

**Omentum Minus.**—The lesser omentum is a fold of peritoneum which connects the lesser curvature of the stomach and the first part of the duodenum with the margins of the porta hepatis (O.T. transverse fissure) on the inferior surface of the liver, and with the bottom of the fossa for the ductus venosus on the posterior surface. Its left and lower margin is attached to the stomach and duodenum; its upper margin is attached to the liver; and its right border is free and forms the anterior boundary of an aperture, the *foramen epiploicum* (O.T. foramen of Winslow), which connects the cavity of the larger part of the peritoneal sac, the great sac, with the smaller part, the omental bursa. The guide to this aperture is the gall-bladder, and if the dissector carries his finger upwards and backwards along the lower surface of the gall-bladder to its neck, and then turns it backwards and to the left, he will find that it passes through the epiploic foramen into the omental bursa.

The lesser omentum contains a large number of important structures between its two layers, viz.—two of the arteries which supply the stomach; the hepatic artery and the portal vein, which carry blood to the liver; the bile ducts, through which the bile is conducted to the duodenum; and numerous nerves, lymph vessels, and lymph glands. The dissector should now display these structures by removing portions of the anterior layer of the fold. It is not probable that he will be able to remove it in a continuous sheet; but he must take care not to destroy the posterior layer.

*Dissection.*—Commence at the upper border of the stomach, immediately below the œsophagus, and expose the *left gastric artery*; follow this downwards to its anastomosis with the *right gastric branch* of the hepatic artery, and upwards to the point at which it gives off its œsophageal branch; trace the latter along the œsophagus to the diaphragm. Remove the peritoneum from the front of the œsophagus and find the *left vagus nerve*, which descends on the front of the lower end of the œsophagus. Trace the terminal branches of the nerve to the wall of the stomach and into the lesser omentum. Whilst cleaning the left gastric artery the dissector may possibly see some of the *anterior left gastric lymph glands* at the upper

FIG. 169.—View of the Interior of the Abdomen.

The upper part of the anterior wall of the abdomen has been removed. The lower part has been divided in the median plane and turned aside.

The greater part of the left lobe of the liver has been removed and the pyloric part of the stomach has been displaced downwards.

The liver is seen in the upper and right portion of the abdominal cavity, with the gall-bladder and the cystic artery on the inferior surface of its right lobe.

The round ligament of the liver and the falciform ligament have been pulled over the right costal arch and have been fixed to the wall of the thorax. From the point of attachment the round ligament runs downwards and backwards to the umbilical fossa of the liver, and the falciform ligament extends backwards to the anterior and upper surfaces of the liver.

Below and to the left of the liver is the stomach, which is connected to the liver by a fold of peritoneum called the lesser omentum. From the lower border of the stomach the greater omentum hangs down in front of the contents of the lower part of the abdominal cavity.

The anterior layer of the lesser omentum has been removed along the upper or lesser curvature of the stomach, to display the right and left gastric vessels, which lie between the two layers; and it has been removed also along the right or free margin of the omentum, to display the hepatic artery and its branches, the portal vein and the bile duct, the cystic duct and the common hepatic duct.

By the displacement downwards of the pyloric end of the stomach, the gastro-duodenal branch of the hepatic artery has been brought into view.

The anterior layer of the greater omentum has been removed along the lower part of the greater curvature of the stomach to display the right and the left gastro-epiploic vessels.

1. Falciform ligament.
2. Ligamentum teres.
3. Left hepatic artery.
4. Left hepatic duct.
5. Common hepatic duct.
6. Cystic artery.
7. Fundus of gall-bladder.
8. Cystic duct.
9. Bile duct.
10. Gastro-duodenal artery.
11. Duodenum, 2nd part.
12. Right gastro-epiploic vessels.
13. Face of section of left lobe of liver.
14. Caudate lobe, seen through lesser omentum.
15. Left gastric artery.
16. Right hepatic artery.
17. Portal vein.
18. Hepatic artery.
19. Lesser omentum.
20. Right gastric vessels.
21. Left gastro-epiploic artery.
22. Stomach.
23. Greater omentum.

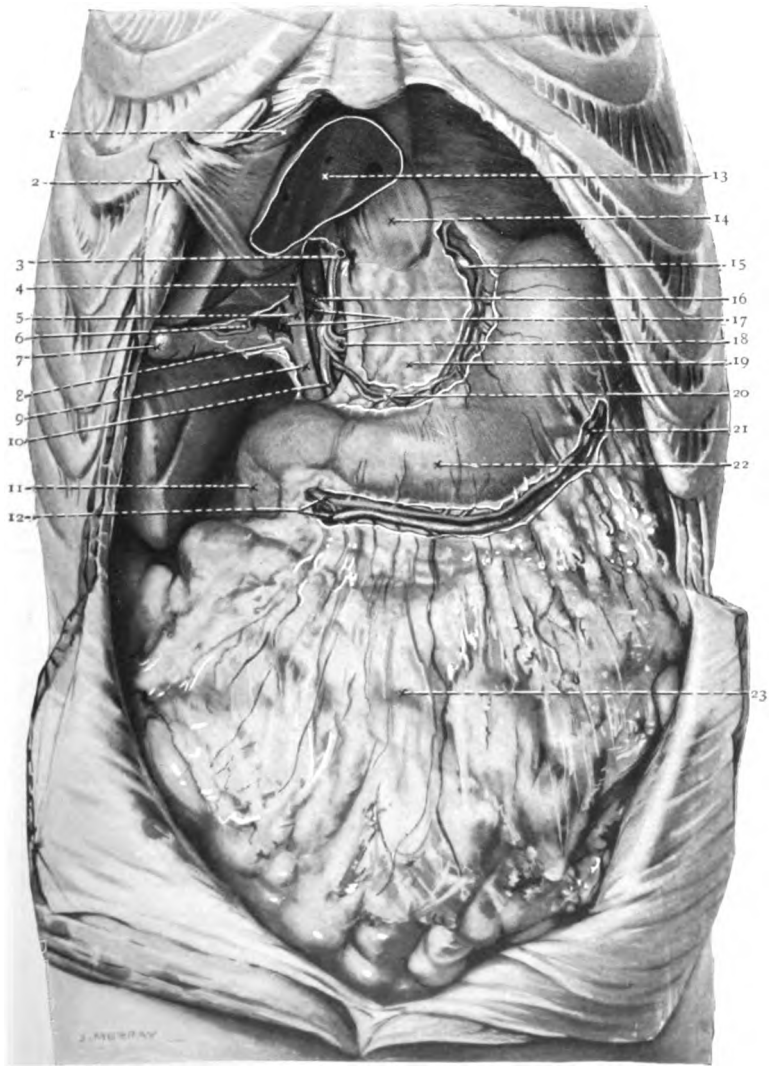


*To face page* 446.

extremity of the lesser curvature. Trace the right gastric artery to its origin from the *hepatic artery* and follow the latter upwards, in the right border of the lesser omentum, to its division into right and left branches immediately below the porta hepatis. On the walls of the artery some of the fibres of the hepatic plexus of sympathetic nerves may be recognised, and at its side some of the *biliary lymph glands* may be seen. Clean both terminal branches of the hepatic artery carefully, especially the right branch, which passes either anterior or posterior to the hepatic duct. To the right of the hepatic artery find the *bile duct*; trace it downwards to the point where it disappears behind the first part of the duodenum, and upwards to the upper border of the lesser omentum, where it is formed by the union of the *common hepatic duct* with the *cystic duct*. Follow the cystic duct to the neck of the gall-bladder, noting that it makes an S-shaped bend. Continue the incision already made in the gall-bladder into the cystic duct and note that the spiral arrangement of the mucous membrane is continued into the duct. Follow the common hepatic duct upwards into the porta hepatis, to the point where it is formed by the union of the *right* and *left hepatic ducts*, which come respectively from the right and left lobes of the liver. Clean away the areolar tissue from between the hepatic artery and the bile duct and display the *portal vein*, which lies behind them. Trace it upwards to its division into right and left branches, at the porta hepatis, and downwards to the first part of the duodenum where it disappears from view at the present stage of dissection. Note that the portal vein lies immediately in front of the epiploic foramen (Winslow), and that its posterior surface is covered by the peritoneum of the anterior margin of the foramen.

**Omentum Majus (The Greater Omentum).** — After the dissector has displayed and studied the structures situated between the two layers of the lesser omentum he should examine the greater omentum which hangs down, like an apron, in front of the viscera which lie in the lower part of the abdomen. It is a double fold of peritoneum and consists, therefore, of two anterior and two posterior layers, the former being separated from the latter by a portion of the cavity of the omental bursa. The upper margins of the anterior two layers are attached to the lower part of the greater curvature of the stomach, where they become continuous with the peritoneum on the anterior and posterior surfaces of that viscus. To the left and above, the anterior two layers are continuous with the two layers of the gastro-splenic ligament, but at a lower level the anterior two layers become continuous with the posterior two layers at the free left border. Similarly at the lower and the right margins of the greater omentum the anterior two become continuous with the posterior two layers. The upper margins of the posterior two layers are attached to the lower border of the transverse colon, and, through the peritoneum on the anterior and posterior surfaces of the latter, they become continuous with the two layers of the transverse meso-colon, which attaches the transverse colon to the

structures lying on the posterior wall of the abdomen. The contents of the greater omentum are—(1) a portion of the cavity of the omental bursa which separates the anterior two layers from the posterior two layers; (2) between the anterior two layers, along the lower border of the stomach, the right and left gastro-epiploic blood vessels and their branches, with lymph vessels and small lymph glands; (3) between the posterior two layers small branches of the middle colic artery which have crossed the surfaces of the transverse colon and are descending into the lower border of the greater omentum, where, in very favourable circumstances, their anastomoses with descending branches of the gastro-epiploic arteries may be seen.

*Dissection.*—Take away the more superficial of the anterior two layers of the greater omentum along the lower border of the stomach and expose the gastro-epiploic arteries. Trace the left artery to the left to the gastro-splenic ligament, and note that it passes forwards to the stomach between the two layers of the ligament. At a later stage it will be followed to the splenic artery, from which it springs. Trace the right artery to the right to the point where it springs from the gastro-duodenal artery at the lower border of the first part of the duodenum.

Remove the anterior two layers of the greater omentum (see Fig. 170). This part of the dissection is not always easy to accomplish, for not uncommonly the posterior of the anterior two layers is fused with the anterior of the posterior two layers, the lower part of the cavity of the omental bursa being obliterated; but if the dissector commences near the left end of the lower border of the stomach he will usually find the cavity persistent. First, he should pull the lower border of the stomach forwards, and cut through the anterior two layers of the omentum below the left gastro-epiploic artery; next, he should introduce his fingers through the opening and gradually separate the anterior two from the posterior two layers; then he must enlarge the opening, and, after separating the anterior from the posterior layers as far as possible, he must cut away the anterior layers. After this portion of the dissection is completed he must introduce one hand into the cavity of the omental bursa and he will find that he can pass it upwards behind the stomach and behind the posterior surface of the lesser omentum to the liver. If now he turns his fingers to the right he will be able to pass them behind the portal vein and through the epiploic foramen into the great sac. He should note as he passes his hand upwards that the cavity of the omental bursa is constricted, between the œsophagus above and to the right and the pylorus below and to the left, by two folds of peritoneum which pass forwards from the posterior wall of the abdomen to the œsophagus and the pylorus respectively. He will find, at a later stage of the dissection, that these folds are connected with the peritoneum on the anterior surface of the pancreas; they are therefore called the left and right gastro-pancreatic folds. The left is produced by the left gastric artery as it passes round the left border of the sac to gain entrance into the lesser omentum, and the right is produced by the hepatic artery as it turns round the right margin of the sac at the lower border of the epiploic foramen (Winslow).

Next, remove the remainder of the lesser omentum and so open into the upper part of the omental bursa; but take care not to injure the contents

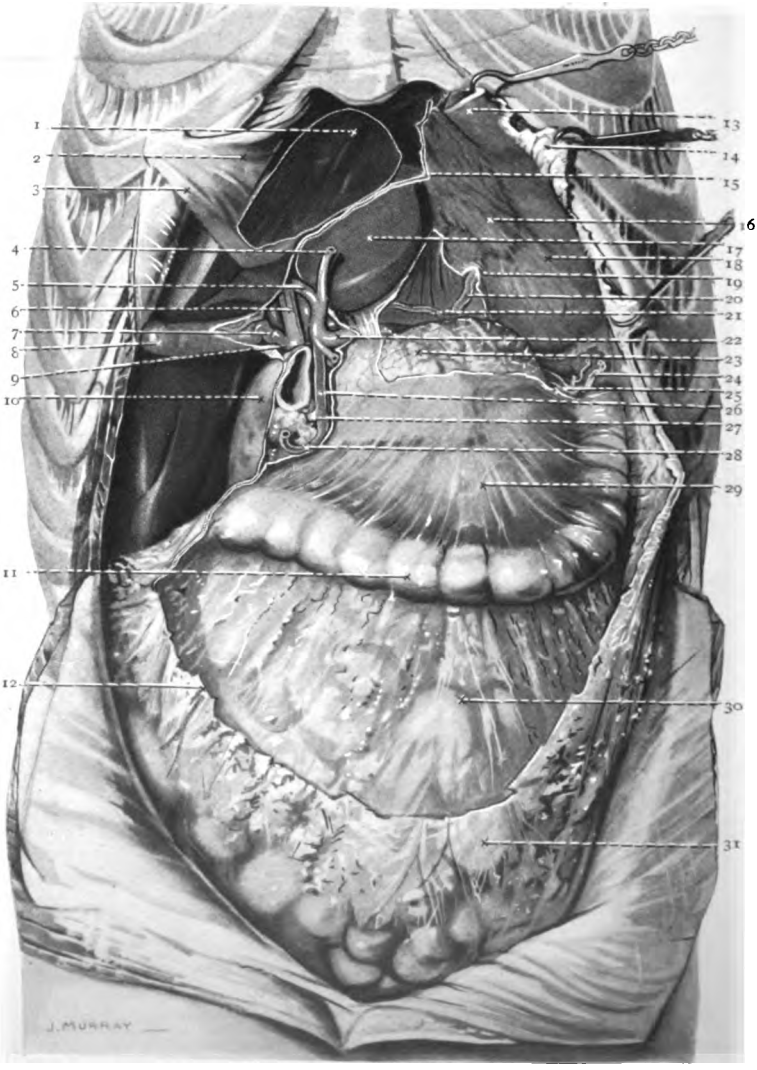


*To face page* 449.

FIG. 170.—Dissection of the Abdomen to display the Posterior Wall of the Omental Bursa and some of its relations; a stage further of the dissection shown in Fig. 163.

The greater part of the left lobe of the liver has been removed and the remainder of the liver has been displaced upwards and to the right. The round ligament of the liver and the falciform ligament have been stitched to the right costal arch. All the lesser omentum, except the posterior layer of its right free margin, has been removed or turned aside.

The greater omentum has been detached from the lower part of the greater curvature of the stomach and a large segment of the wall formed by its anterior two layers has been removed.

The stomach has been divided near its pyloric end and afterwards turned upwards and to the left under cover of the left costal arch, to the margin of which the divided end has been fastened.

A portion of the peritoneal layer which forms the upper part of the posterior wall of the omental bursa has been removed to display a part of the pancreas.

The posterior wall of the omental bursa, which is displayed, is formed from below upwards by—(1) the posterior two layers of the greater omentum. (2) The transverse colon, enclosed between two layers of peritoneum which are continuous below with the posterior two layers of the greater omentum and above with the two layers of the transverse meso-colon. (3) The transverse meso-colon, formed by two layers of peritoneum of which only the upper or anterior is visible in the figure. (4) The ascending layer of the transverse meso-colon, which is the upward prolongation of the upper layer of the transverse meso-colon across the anterior surface of the pancreas to the diaphragm.

1. Cut surface of left lobe of liver.
2. Falciform ligament.
3. Ligamentum teres.
4. Left hepatic artery.
5. Right hepatic artery.
6. Common hepatic duct.
7. Cystic duct.
8. Fundus of gall-bladder.
9. Bile duct.
10. Duodenum, junction of 1st and 2nd parts.
11. Transverse colon.
12. Cut edge of anterior wall of omental bursa.
13. Stomach.
14. Part of greater omentum.
15. Cut edge of lesser omentum.
16. Lesser omentum.
17. Caudate lobe of liver.
18. Stomach.
19. Left gastro-pancreatic fold.
20. Left gastric artery.
21. Right inferior phrenic artery.
22. Hepatic artery, in right gastro-pancreatic fold.
23. Pancreas.
24. Left gastro-epiploic artery.
25. Splenic artery.
26. Gastro-duodenal artery.
27. Superior pancreatico-duodenal artery.
28. Right gastro-epiploic artery.
29. Transverse meso-colon.
30. Posterior wall of omental bursa.
31. Anterior two layers of greater omentum.

of the lesser omentum. First cut through the posterior layer along the left border of the hepatic artery, then carry the incision upwards along the margin of the fossa for the ductus venosus. Finally cut through the posterior layer for a short distance along the lesser curvature of the stomach, above the left gastric artery, and turn the separated portion of the lesser omentum to the left over the stomach. Again introduce the hand from the lower part into the upper part of the omental bursa and examine again the constriction of the cavity between the œsophageal and pyloric ends of the stomach and the gastro-pancreatic folds, which cause it.

It is not possible to make a thorough examination of the cavity of the omental bursa till the stomach, which lies in its anterior wall, has been turned aside. Divide the right gastric artery and the right gastro-epiploic artery immediately to the left of the pylorus, then cut through the stomach in the same situation and turn it over to the left side. The greater part of the anterior wall of the omental bursa is now removed, and the cavity and the remaining boundaries can be examined.

**The Cavity of the Omental Bursa** extends from the lower margin of the greater omentum below to the liver above, and a narrow, pouch-like recess is prolonged upwards, behind the liver, to the inferior surface of the diaphragm. The posterior wall of the sac is formed, from below upwards, by—(1) the posterior two layers of the greater omentum; (2) the transverse colon, covered with peritoneum; (3) the transverse meso-colon; and, above the line of attachment of the transverse meso-colon to the posterior abdominal wall, by (4) the upper of the two layers of the transverse meso-colon, the so-called "*ascending layer*," which passes upwards, in front of the pancreas, the upper and medial part of the left kidney, the left suprarenal gland and the crura of the diaphragm, to the under surface of the diaphragm, from which it is reflected forwards to the upper part of the posterior surface of the liver. The outline of the pancreas can be seen through the thin peritoneum; and the kidney and the suprarenal glands, if not visible, are easily felt.

The narrow, pouch-like upper portion of the cavity of the omental bursa is bounded posteriorly, as already stated, by the peritoneum on the abdominal surface of the crura of the diaphragm; superiorly, by the reflection of the peritoneum forwards to the posterior surface of the liver; anteriorly, by the peritoneum on the posterior surface of a small subdivision of the posterior aspect of the right lobe of the liver called the caudate lobe (O.T. Spigelian); on the left, by the reflection of the posterior layer of the lesser omentum from the margin of the fossa for the ductus venosus to the crura of the diaphragm; and, on the right, by the reflection of the peritoneum from the right crus of the diaphragm to the right lateral margin of the caudate lobe.

This recess, when the body is recumbent, is the most dependent part of the omental bursa

The anterior wall of the omental bursa is formed, from above downwards, by the peritoneum on the posterior surface of the caudate lobe of the liver, the lesser omentum, the peritoneum on the posterior surface of the stomach, and by the anterior two layers of the greater omentum.

The left lateral boundary is formed—(1) in the region of the uppermost recess, by the reflection of the peritoneum from the fossa for the ductus venosus to the crura of the diaphragm; at a lower level, posteriorly, by (2) the lieno-renal ligament, which passes from the left kidney to the spleen (see Fig. 172); and anteriorly by (3) the gastro-splenic ligament, which connects the spleen with the stomach; and, at a still lower level, by (4) the union of the anterior two layers with the posterior two layers of the greater omentum at the left free border of the omentum (Fig. 173). The splenic artery runs forwards in the left lateral wall, between the layers of the lieno-renal ligament; and the short gastric branches and the left gastro-epiploic branch of the splenic artery run onwards to the stomach between the layers of the gastro-splenic ligament.

The right lateral wall is formed, from below upwards, by the union of the anterior two layers with the posterior two layers of the greater omentum at its right free border (Fig. 170); next, by the reflection of the posterior of the anterior two layers backwards from the posterior surface of the first part of the duodenum to the front of the pancreas, where it becomes continuous with the ascending layer of the transverse meso-colon (Fig. 173). Immediately above the duodenum the right boundary is absent and the omental bursa communicates with the great sac through the epiploic foramen. Above the epiploic foramen the right margin of the omental bursa is formed, in the upper recess, by the reflection of the peritoneum from the right border of the caudate lobe of the liver to the right crus of the diaphragm. The hepatic artery turns round the right border of the bursa immediately behind the upper border of the first part of the duodenum, producing the right gastro-pancreatic fold previously mentioned.

**The Great Sac of the Peritoneum.**—After the dissector has made himself thoroughly conversant with the cavity of the omental bursa he should study the cavity of the great sac. It is the cavity into which he opened when he cut through

the abdominal walls to display the interior of the abdomen. It extends from the diaphragm above to the pelvic floor below (Fig. 171) across the abdomen from one side wall to the other (Fig. 174); and it is divided by the lower part of

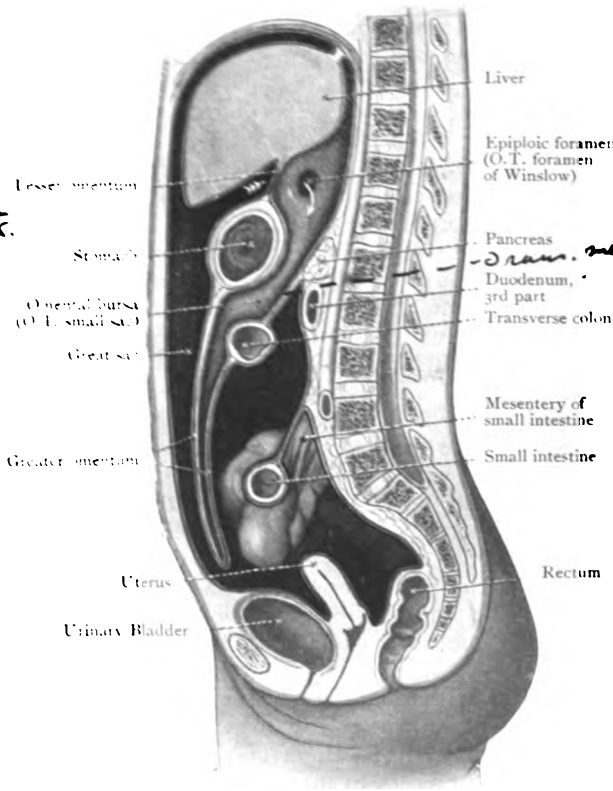


FIG. 171.—Sagittal section of Abdomen showing cavities.

the walls of the omental bursa, that is, by the greater omentum, the transverse colon, and the transverse meso-colon, into an upper and anterior, and a lower and posterior part, which are continuous with each other round the borders of the greater omentum (see Fig. 174). The upper and anterior part of the sac extends upwards to the lower surface of the diaphragm, where it intervenes between the liver and the diaphragm, and

where it is separated into right and left parts by the falciform ligament. The right part of the upper portion extends backwards, between the liver and the diaphragm, to the coronary ligament, which separates the upper surface of the right lobe of the liver from the posterior surface (Fig. 200): the left part of the upper end of the sac passes backwards, over the upper surface of the left lobe of the liver,

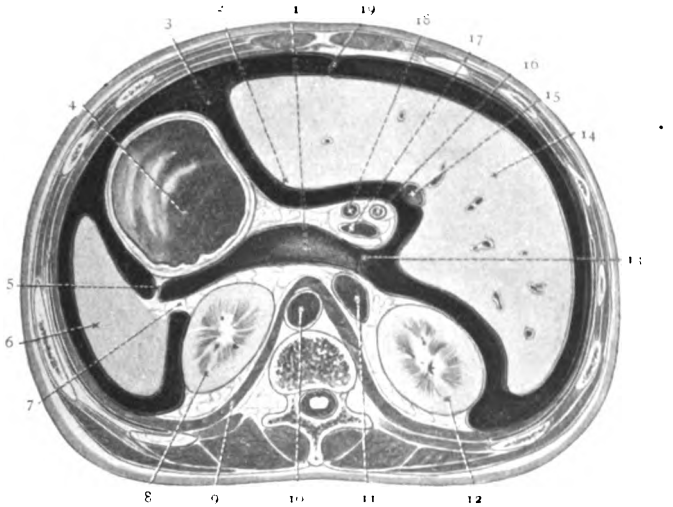


FIG. 172.—Transverse Section of Abdomen at the level of the Epiploic Foramen.

1. Omental bursa (O.T. small sac).
2. Omental tubercle of liver.
3. Great sac.
4. Stomach.
5. Gastro-splenic ligament (O.T. gastro-splenic omentum).
6. Spleen.
7. Lieno-renal ligament.
8. Left kidney.
9. Diaphragm.
10. Aorta.
11. Inferior vena cava.
12. Right kidney.
13. Epiploic foramen (O.T. foramen of [Winslow).
14. Liver.
15. Gall bladder.
16. Bile duct.
17. Portal vein.
18. Hepatic artery.
19. Falciform ligament.

to the left triangular ligament. Below the falciform ligament the upper and anterior part of the great sac extends, as a continuous cavity, from side to side, and it projects backwards, on each side, deeply into the hypochondriac, lumbar, and iliac regions (see Figs. 172 and 173). The backward extensions of the great sac form two deep gutters, one on each side, in which collections of fluid may become lodged when the body is lying recumbent. The lateral boundary of each of the gutter-like recesses is the side

wall of the abdomen, formed superiorly by the diaphragm, which separates the peritoneal gutters from the lower parts of the pleural sacs, and inferiorly by the flat muscles of the abdomen. The medial wall of the right gutter is formed by the right kidney and the ascending colon (see Figs. 173 and 174): and the medial wall of the left gutter by the

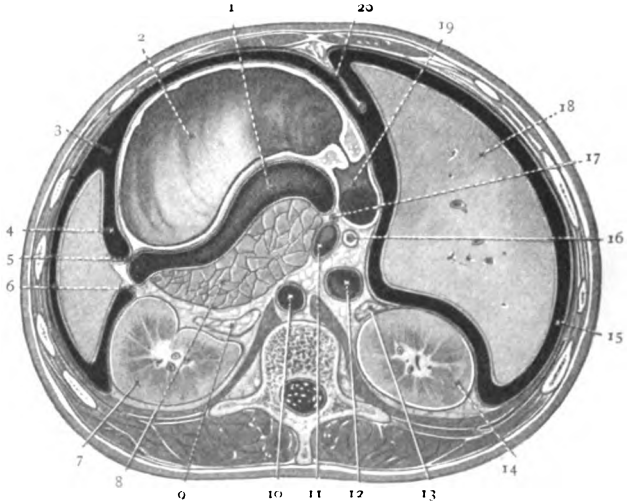


FIG. 173.—Transverse Section of Abdomen immediately below the Epiploic Foramen.

1. Omental bursa (O.T. small sac).
2. Stomach. 3. Great sac. 4. Great sac.
5. Gastro-splenic ligament (O.T. gastro-splenic omentum).
6. Lieno-renal ligament.
7. Left kidney.
8. Pancreas.
9. Left suprarenal gland.
10. Aorta.
11. Portal vein.
12. Inferior vena cava.
13. Right suprarenal gland.
14. Right kidney.
15. Great sac.
16. Bile duct.
17. Gastro-duodenal artery.
18. Liver.
19. Duodenum, 1st part.
20. Falciform ligament.

lieno-renal ligament and left kidney above and by the descending colon below (see Figs. 173 and 174).

The dissector should pass his hand, from above downwards, along each of these lateral gutters of the anterior part of the great sac, and he will find that each is divided by a transverse fold of the peritoneal wall into an upper and a lower part, but the division occurs at very different levels on the opposite sides. On the left side the fold which separates the upper from the lower part of the left gutter is the phrenico-colic ligament, which lies at the level of the eleventh

rib in the mid-axillary line. On the right side the dividing fold is placed much lower and is frequently less distinct. It passes from the side wall of the abdomen, in the upper part of the iliac region, to the lateral wall of the lower part of the ascending colon. The lateral gutters and the folds which divide them are of importance because they tend to localise abnormal collections of blood or inflammatory

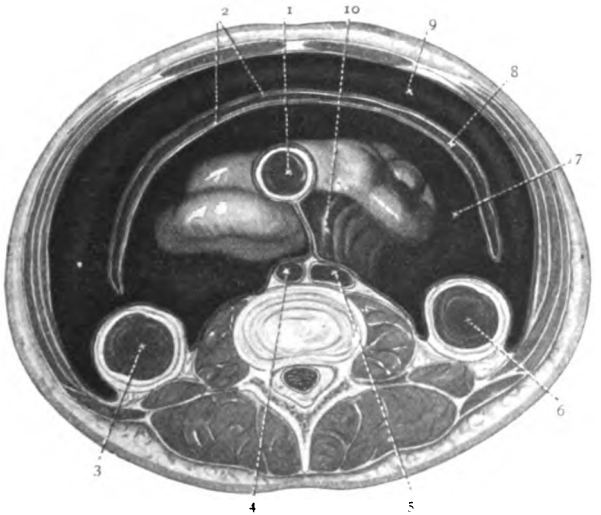


FIG. 174.—Transverse section of Abdomen through the fourth lumbar vertebræ.

1. Small intestine.
2. Greater omentum and omental bursa.
3. Descending colon.
4. Aorta.
5. Inferior vena cava.
6. Ascending colon.
7. Great sac.
8. Omental bursa (O.T. small sac).
9. Great sac.
10. Mesentery.

effusions which may be in the cavity of the great sac; and the dissector should note that in the recumbent posture the lowest part of each lateral gutter is situated at the level of the upper part of the kidney, in the region of the last intercostal space.

The upper portion of the posterior part of the cavity of the great sac—the part behind the greater omentum—also is divided, in the upper part of its extent, into two parts, by the mesentery of the small intestine, which runs obliquely from the left side of the second lumbar vertebra to the right iliac fossa.

The upper boundary of each subdivision of the posterior and lower part of the cavity of the great sac is the transverse meso-colon (Fig. 171). The lateral boundary of the right part is the ascending colon, and of the left part the descending colon (Fig. 174). The lateral gutter of the right part of the

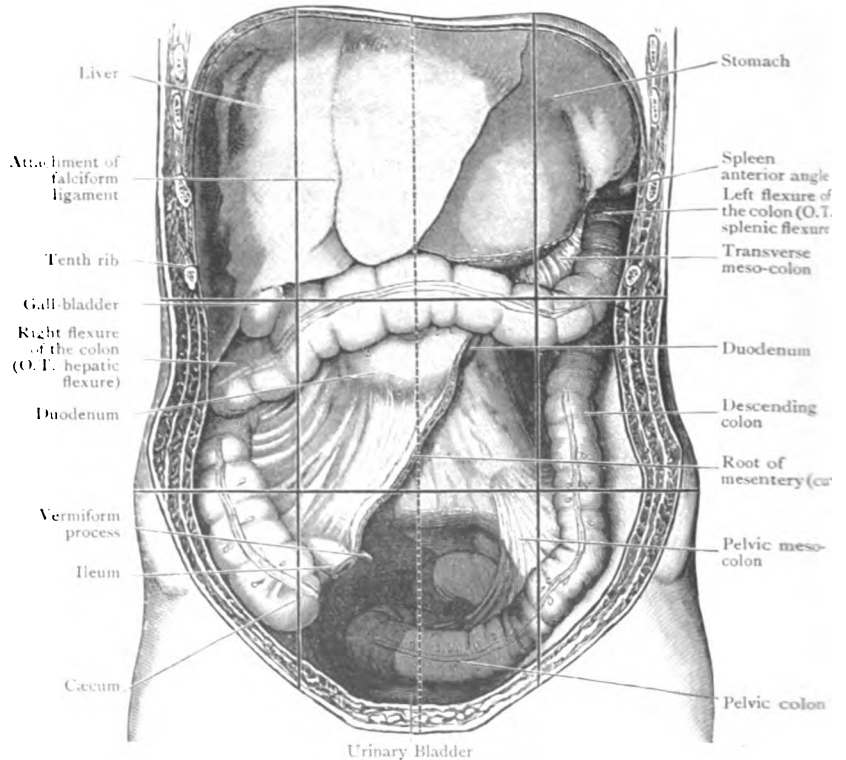


FIG. 175. Abdominal viscera after removal of jejunum and ileum. (Birmingham.)

posterior portion of the great sac terminates below at the union of the ileum with the large intestine (see Fig. 175): and the lateral gutter on the left side is continued downwards into the pelvis between the mesentery of the small intestine and the mesentery of the pelvic colon.

The lower portion of the posterior part of the cavity of the great sac lies upon the floor of the pelvis and, in the male,

forms three definite pouches: a median, recto-vesical pouch, bounded in front by the bladder and behind by the rectum and laterally, on each side, by a sacro-genital fold of peritoneum, which passes from the region of the fundus of the bladder, past the side of the rectum, to the sacrum. Each of the two lateral pouches is bounded medially by the side of the bladder and the sacro-genital fold, and laterally by the side wall of the pelvis. In the female, by the interposition of the uterus and the upper part of the vagina, between the bladder and the rectum, two median pouches are formed —a larger posterior pouch, the recto-uterine pouch (*pouch of Douglas*), and a smaller anterior pouch, the utero-vesical pouch; and the broad ligament, which connects the lateral border of the uterus with the side wall of the pelvis, divides each of the single lateral pouches present in the male into an anterior or paravesical part, and a posterior part, the lateral pouch of Douglas, in which the ovary and the termination of the oviduct are situated.

**Peritoneum.** — The peritoneum is the great serous membrane which forms the wall of the peritoneal cavity. Externally it is blended with the subserous or extra-peritoneal tissue of the abdomen, through which the vessels and nerves of the abdomen pass to their terminations. Internally it is covered with a flat, glistening epithelium. In the male, the cavity of the peritoneal sac is closed; that is, it does not communicate with the exterior of the body. In the female, on the other hand, it does communicate with the exterior through the female genital passages, viz., the oviducts, the uterus, and the vagina. In neither sex, however, is it an entirely closed sac, for in both it is in direct communication with the lymph vessels, by numerous minute openings which exist on the lower surface of the diaphragm, and in other regions of the wall of the sac, and it is on this account that fluids, and fluid-borne micro-organisms which have gained entrance into the cavity of the peritoneum, pass so readily into the lymph, and thence into the general blood stream.

When the abdomen was opened the cavity of the peritoneum also was opened, and the dissector's attention was drawn to the smooth and glistening appearance of the inner surface of the serous membrane which is due to the lining epithelium. He must have noted, as the examination of the cavity proceeded, that the peritoneum gave more or

less complete coverings to the various abdominal viscera, and that its posterior wall was raised into numerous complicated folds. The folds are due to the invagination of the wall of the sac by the adjacent viscera, and the complication of the folds has been produced by changes in form and position of the viscera, and by the fusion and partial disappearance of some of the primitive folds.

The portion of the peritoneum which lines the inner surface of the abdominal wall is called *parietal peritoneum*. The portion which covers the viscera is termed *visceral peritoneum*; and the folds which connect the viscera with each other or with the wall of the abdomen are defined as omenta, mesenteries, and ligaments.

The term *mesentery* is *generally* applied to folds of peritoneum which connect portions of the alimentary canal with the posterior wall of the abdomen.

The term *omentum* has usually been applied, in English terminology, to folds of peritoneum which connect the stomach with other viscera. The term *ligament* was limited to any fold which did not fall into either of the two first divisions; now, however, it is becoming customary to extend the term to folds and portions of folds which connect the stomach to adjacent viscera; thus the lesser omentum is said to consist of the *hepato-gastric* and the *hepato-duodenal ligaments*, the two terms being applied respectively to the parts which connect the liver to the stomach and the liver to the duodenum. The gastro-splenic omentum becomes the *gastro-splenic ligament*, and the greater omentum is sometimes spoken of as the *gastro-colic ligament*.

The relations of the layers of the visceral and parietal peritoneum to each other, and the relations of the layers which bound the omental bursa to those which limit the cavity of the great sac can be easily followed in Figs. 171, 172, 173, and 174. The dissector should study the figures and confirm their accuracy by following the peritoneum at the levels, and in the planes, indicated in them.

*Dissection.*—After examining the various parts of the peritoneal cavity, and the different folds of the peritoneal membrane, the dissector should remove the peritoneum of the posterior wall of the omental bursa, above the level of the root of the transverse meso-colon. Commence immediately above the line of attachment of the transverse meso-colon to the lower border of the pancreas, which can be seen through the thin peritoneum, and work upwards, taking care not to injure either the pancreas itself or

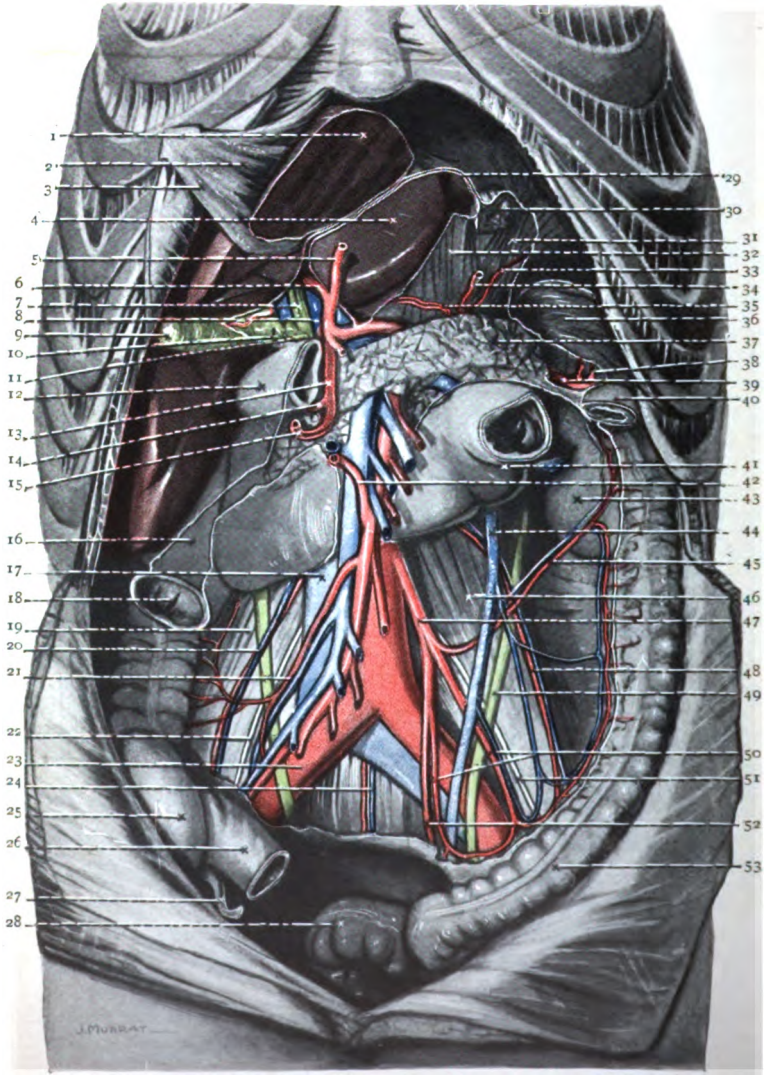


*To face page* 459.

FIG. 176.—Further Stage of the Dissection of the Abdomen.

The œsophagus and the gastro-phrenic ligament have been divided close to the diaphragm.

The gastro-splenic ligament has been divided close to the hilum of the spleen.

The transverse meso-colon has been divided close to its attachment to the duodenum and the pancreas.

The transverse colon has been divided immediately medial to the right and left colic flexures and the stomach and the transverse colon, with the greater omentum and its contained part of the omental bursa, have been removed.

The jejunum has been divided close to the duodeno-jejunal flexure, and the ileum close to the cæcum, and the intervening part of the small intestine and its mesentery have been removed. The peritoneum has been taken away from the upper part of the posterior wall of the pelvis minor, and from the area on posterior wall of the abdomen which is bounded by the cæcum and the ascending colon on the right, and the descending and iliac portions of the colon on the left.

The peritoneum of the posterior wall of the upper part of the omental bursa has also been removed.

By the removal of the posterior wall of the upper part of the omental bursa, the body and tail of the pancreas, the crura of the diaphragm, the left inferior phrenic artery and a portion of the splenic artery have been displayed.

By the removal of the transverse colon and the greater part of the small intestine, the third and fourth parts of the duodenum have been brought into view; and, by the removal of the peritoneum from the posterior wall of the lower part of the abdomen, the ureters, and the vessels, nerves, and muscles lying immediately behind the peritoneum in that region, have been exposed.

1. Cut surface of left lobe of liver.
2. Falciform ligament.
3. Ligamentum teres.
4. Caudate lobe.
5. Left hepatic artery.
6. Right hepatic artery.
7. Hepatic duct.
8. Portal vein.
9. Fundus of gall-bladder.
10. Cystic duct.
11. Bile duct.
12. Duodenum, 1st part.
13. Gastro-duodenal artery.
14. Sup. pancreatico-duodenal artery.
15. Right gastro-epiploic artery.
16. Right kidney.
17. Inferior vena cava.
18. Right flexure of the colon.
19. Psoas major muscle.
20. Spermatic vessel crossing ureter.
21. Common trunk of ileo-colic and right colic arteries.
22. Genito-femoral nerve.
23. Right common iliac artery.
24. Middle sacral vessels.
25. Cæcum.
26. Ileum.
27. Vermiform process.
28. Pelvic colon.
29. Cut edge of lesser omentum.
30. Œsophagus.
31. Left crus of diaphragm.
32. Right crus of diaphragm.
33. Left inferior phrenic artery.
34. Left gastric artery.
35. Right inferior phrenic artery.
36. Spleen.
37. Pancreas.
38. Left gastro-epiploic artery.
39. Splenic artery.
40. Left flexure of the colon.
41. Duodeno-jejunal flexure.
42. Middle colic artery.
43. Left kidney.
44. Inferior mesenteric vein.
45. Left colic artery.
46. Psoas major muscle.
47. Inferior mesenteric artery.
48. Spermatic vessels.
49. Ureter.
50. Sigmoid arteries.
51. Genito-femoral nerve.
52. Superior hæmorrhoidal artery.
53. Iliac colon.

the blood-vessels which lie behind the posterior wall of the upper part of the omental bursa. Remove also the medial layer of the gastro-splenic ligament, and the medial layer of the lieno-renal ligament. The object of this dissection is to display—(1) the anterior surface of the body, the neck, and part of the head of the pancreas; (2) a part of the anterior surface of the left kidney; (3) the anterior surface of the left suprarenal gland; (4) the left cœliac ganglion and the left greater splanchnic nerve; (5) the upper part of the abdominal portion of the aorta; (6) the cœliac artery and its branches, the hepatic, the splenic, and the left gastric artery, and their branches; (7) the inferior phrenic arteries; (8) the upper parts of the crura of the diaphragm; (9) the terminal part of the right vagus nerve. Clean the pancreas first, and do not disturb it from its position. At the upper border of the pancreas, in the median plane, and below the caudate lobe of the liver, find the termination of the cœliac artery, dividing into its three terminal branches: the hepatic, running to the right; the splenic, to the left along the upper border, or immediately behind the upper border, of the pancreas; and the left gastric, running upwards and to the left to the junction of the œsophagus with the stomach. Trace the first portion of the hepatic artery, through the right gastro-pancreatic fold, to the right free margin of the omentum, where it has already been exposed, and, if possible, preserve the sympathetic nerve filaments which surround it. Secure its *gastro-duodenal branch*, which descends behind the first part of the duodenum and in front of the neck of the pancreas, and trace it to its division into the superior *pancreatico-duodenal* and the *right gastro-epiploic arteries*. Trace the latter to the left to the point where the stomach was divided. Trace the *splenic artery* to the left, to the anterior surface of the left kidney, and then forwards, along the left layer of the lieno-renal ligament, which is still *in situ*, to the spleen, and note that before it reaches the spleen it gives off a number of *small gastric branches*, and the *left gastro-epiploic artery*, which run forwards to the stomach, along the left layer of the gastro-splenic ligament, which is also still in position. Note, further, that the splenic artery breaks up into branches before it reaches the spleen. In many cases the small gastric branches and the left gastro-epiploic artery spring from the terminal branches, and not from the trunk of the splenic artery. Secure also the branches from the splenic artery to the pancreas, and, if possible, preserve the sympathetic nerve plexus which surrounds the artery. Follow the *left gastric artery*, through the left gastro-pancreatic fold, to the junction of the œsophagus with the stomach, where the artery gives off its œsophageal branch or branches; secure also the accompanying vein, *the coronary vein of the stomach*, and trace it, across the median plane, to its union with the portal vein at the lower end of the right free margin of the lesser omentum. Trace the *cœliac artery* backwards to its origin from the front of the aorta, and do not injure the plexus of sympathetic nerve filaments which surrounds it. Immediately to the left of the cœliac artery, and at the upper border of the pancreas, find the *left cœliac ganglion*, which is connected with the plexus of nerves round the root of the cœliac artery. Follow the ganglion upwards and backwards to its union with the left greater splanchnic nerve. Immediately to the left of the ganglion find the *left suprarenal gland*, and, below it, the upper and medial part of the anterior surface of the *left kidney*. Find the inferior phrenic arteries, one on each side, immediately above the level of the cœliac artery; trace each medially to the aorta, and laterally across the surface of the corresponding crus; note that the left passes behind the œsophagus; the right passes behind the inferior vena cava, but this fact cannot be demonstrated until a later period. Clean the posterior surface of the abdominal part of the œsophagus and secure the *right vagus*

*nerve*; trace its branches along the wall of the stomach and towards the spleen. Finally, clean the crura of the diaphragm to the level of the orifice through which the œsophagus enters the abdomen.

When the dissection is completed the dissector is in a position to study the cœliac artery and its branches, the blood supply of the stomach, and the bed of the stomach.

**Arteria Cœliaca** (O.T. **Cœliac Axis**).—The cœliac artery is a short, wide vessel, which springs from the front of the aorta, between the two crura of the diaphragm, immediately above the upper margin of the pancreas. It is directed horizontally forwards, and, after a course of little more than half an inch, divides into three large branches, viz.—(1) the left gastric;

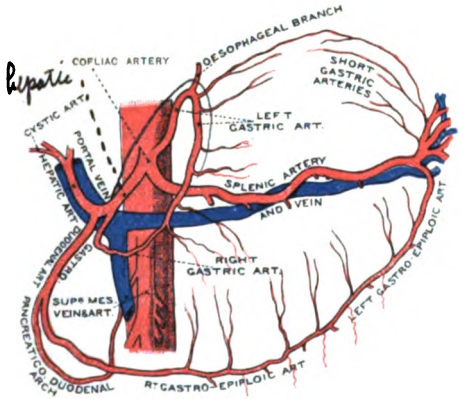


FIG. 177.—The Cœliac Artery and its branches.

(2) the hepatic; and (3) the splenic—which radiate from each other like the spokes of a wheel. The cœliac artery is surrounded by a thick, matted plexus of nerves, called the *cœliac plexus*, which sends numerous nerve twigs with the three branches of the artery.

**Arteria Gastrica Sinistra** (O.T. **Coronary Artery**).—The left gastric artery is the smallest of the three branches of the cœliac artery; it proceeds upwards and to the left, behind the omental bursa and through the left gastro-pancreatic fold, to the œsophageal opening of the stomach, where it changes its direction, enters between the two layers of the lesser omentum, and runs, from above downwards and to the right, along the lesser curvature of the stomach. Near the pylorus it ends by

anastomosing with the *right gastric branch* of the hepatic artery.

The branches of the left gastric artery are:—

1. Œsophageal.
2. Gastric.

**Rami Œsophagei.**—Two or three œsophageal branches may arise separately, or by a common trunk, from the left gastric artery at the point where it reaches the stomach. They pass upwards, through the œsophageal opening of the diaphragm, upon the posterior aspect of the gullet, and anastomose with the œsophageal branches of the thoracic aorta.

The *gastric branches* take origin from the trunk, as it runs along the lesser curvature of the stomach, and are distributed to both surfaces of this viscus.

**Vena Coronaria Ventriculi.**—The coronary vein of the stomach accompanies the left gastric artery, along the lesser curvature of the stomach and behind the omental bursa, to the cœliac artery; then, continuing to the right, it crosses in front of the aorta and joins the portal vein at the lower border of the epiploic foramen.

**Arteria Hepatica.**—The hepatic artery, intermediate in size between the left gastric and the splenic, at first takes a transverse course, to the right, along the upper border of the pancreas. At the pylorus it changes its direction, and, turning forwards, below the epiploic foramen, in the right gastro-pancreatic fold, it ascends between the two layers of the lesser omentum. Near the porta hepatis it ends by dividing into *right* and *left hepatic arteries*. The hepatic artery is accompanied by numerous large nerve twigs derived from the cœliac plexus, and, as it passes upwards to the liver, it is in close relationship with the bile duct and the portal vein. The duct lies upon the right side of the artery, and the vein lies behind both. (Fig. 170, p. 449, and Fig. 172, p. 453.)

The following are the branches of the hepatic artery:—

1. A. gastrica dextra.
2. A. gastro-duodenalis. { A. pancreatico-duodenalis superior. / A. gastro-epiploica dextra.
3. A. hepatica propria. { Dextra. { A. Cystica. / Sinistra.

The *right gastric artery* is a small artery which springs

from the hepatic at the pylorus, and then runs from right to left, along the lesser curvature of the stomach, between the two layers of the lesser omentum. It ends by inosculating with the left gastric; the accompanying vein terminates in the portal vein.

The *gastro-duodenal artery* arises close to the pyloric artery, and is directed downwards, behind the first part of the duodenum, in a groove on the anterior aspect of the neck of the pancreas. At the lower border of the duodenum it ends by dividing into the superior pancreatico-duodenal and right gastro-epiploic branches (Fig. 170).

The *superior pancreatico-duodenal artery* runs first to the right and then downwards between the head of the pancreas and the duodenum. It anastomoses with the *inferior pancreatico-duodenal branch* of the superior mesenteric artery, forming an arch round the head of the pancreas. It gives branches to both the duodenum and the pancreas. The pancreatico-duodenal veins join the superior mesenteric vein.

The *right gastro-epiploic artery* is directed from right to left, along the greater curvature of the stomach, and between the anterior two layers of the greater omentum. It gives branches upwards to both surfaces of the stomach, and downwards to the greater omentum; and it ends by anastomosing with the *left gastro-epiploic* branch of the splenic. The right gastro-epiploic vein joins the superior mesenteric vein.

The *right* and *left hepatic arteries*, the terminal branches of the hepatic, diverge from each other, and sink into the liver at the two extremities of the porta hepatis. From the right hepatic a small branch, called the *cystic*, is given to the gall-bladder. This divides into two twigs, one of which ramifies in the areolar tissue between the liver and gall-bladder and the other upon the inferior surface of the gall-bladder, between it and its peritoneal covering.

The *cystic vein* joins the vena portæ or its right branch.

**Arteria Lienalis.** — The splenic artery is the largest branch of the cœliac artery. It takes a wavy or tortuous course, along the upper border of the pancreas, behind the omental bursa, towards the left side; and it ends, in front of the left kidney, by dividing into five or six branches, which enter the hilum of the spleen.

It is accompanied by the splenic vein, which, however,

lies at a lower level, and therefore altogether behind the pancreas.

The following are the branches of the splenic artery:—

1. Arteriæ pancreaticæ.
2. Aa. gastricæ. { Aa. gastricæ breves. / A. gastro-epiploica sinistra.
3. Rami lienales.

The *pancreatic arteries* are small twigs which come off at various points for the supply of the pancreas.

The *pancreatica magna branch*, which is sometimes described as accompanying the duct from left to right in the substance of the pancreas, is not present as a rule.

The *short gastric arteries* (O.T. *Vasa Brevia*) are five or six small arteries, of which some arise directly from the splenic, whilst others take origin from its terminal branches. They run towards the stomach, between the two layers of the gastro-splenic ligament, and are distributed to the cardiac end of the viscus, anastomosing with the left gastric and left gastro-epiploic arteries.

The *left gastro-epiploic artery* takes origin from the splenic, or one of its terminal branches near the spleen; it runs forwards, in the gastro-splenic ligament, and then turns to the right, along the greater curvature of the stomach, between the anterior two layers of the greater omentum. It gives branches which ascend to supply both surfaces of the stomach, and others which descend into the greater omentum, and it ends by anastomosing with the right gastro-epiploic artery.

The *splenic* or *terminal branches* of the splenic artery reach the spleen by passing between the two layers of the lieno-renal ligament.

From the above description of the branches of the cœliac artery it will be seen that the stomach is remarkably rich in blood-vessels. *Two* proceed from *left to right*—viz., the *left gastric*, along the lesser curvature, and the *left gastro-epiploic*, along the greater curvature; *two*, both branches of the hepatic, are directed from *right to left*—viz., the *right gastric*, in relation to the lesser curvature; and the *right gastro-epiploic*, in relation to the greater curvature. The arterial circle is completed on the left by the *short gastric arteries*, which connect the left gastric artery with the left gastro-epiploic.

The splenic vein, the portal vein, the bile duct, and the inferior phrenic arteries will be considered at a later stage of the dissection.

**Ventriculus.**—The stomach is the most dilated part

of the alimentary canal, and it constitutes the receptacle for the food after it has been masticated and swallowed. The gullet or œsophagus opens into the stomach above and to the left, whilst below and to the right the stomach becomes continuous with the duodenum, or first part of the small intestine. The form and the position of the organ within the abdomen are greatly influenced not only by the amount of food it contains but also by the empty or distended condition of the other hollow viscera in its vicinity. It is convenient to describe it as it appears when moderately distended. It then assumes a pyriform shape and is strongly curved upon itself. It is customary to recognise in connection with the stomach: (1) a blunt, left extremity or fundus; (2) a narrow, right extremity or pylorus; (3) two orifices, a cardiac and a pyloric; (4) two surfaces, a superior and an inferior; and (5) two borders or curvatures, a greater and a lesser.

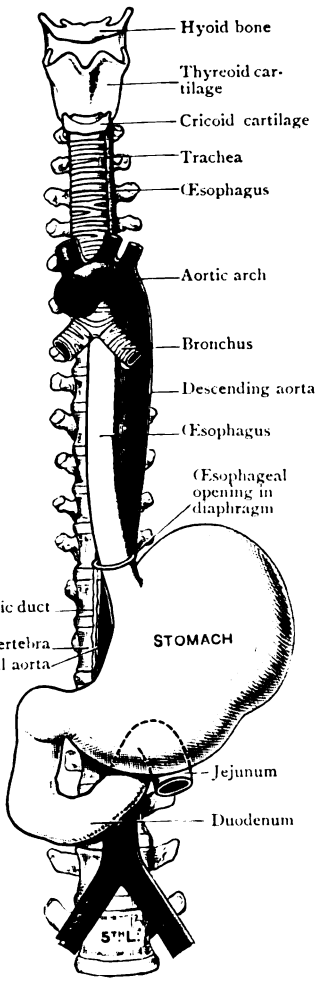


FIG. 178.—The Œsophagus, Stomach, and Duodenum.

The *fundus*, or left, or cardiac end, is full and rounded, and forms a marked bulging directed upwards and backwards. It occupies the back part of the left cupola of the diaphragm, from which it is separated, in part, by the spleen and the liver. To the right of the fundus, and about two inches below its summit, is the œsophageal or *cardiac orifice*. This is placed on the upper part or com-

mencement of the lesser curvature, but in certain conditions of the stomach it appears to be partly on the upper surface. At this point the organ is joined by the gullet. The *pylorus*, or narrow right extremity of the stomach, is, as a rule, directed backwards, and becomes continuous with the duodenum or commencement of the small intestine; and the junction is marked on the surface by a slight but obvious constriction, termed the *duodeno-pyloric constriction*.

The two surfaces of the stomach, as a general rule, look for the most part upwards and downwards. The *upper surface*

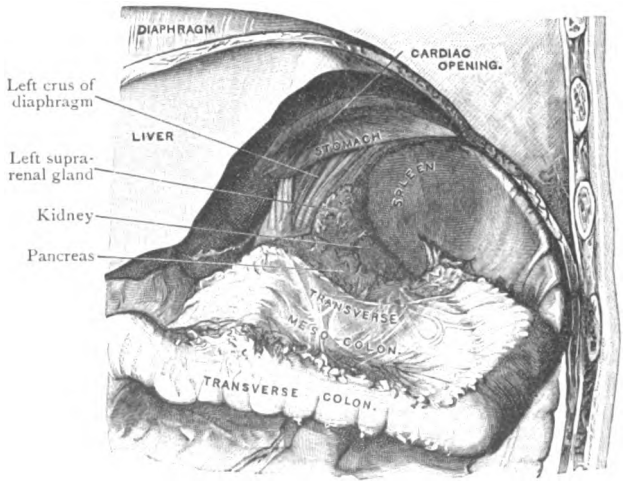


FIG. 179.—The Stomach has been removed from its bed so as to display the recess in which it lies.

is fuller and more convex than the lower surface. To some extent it is directed forwards, as well as upwards, and it is covered to a large extent by the left lobe of the liver. Below and to the left of the sharp margin of the liver, however, a considerable portion of this surface of the stomach is in apposition with the diaphragm, and also with the posterior aspect of the anterior abdominal wall.

The *inferior surface* of the stomach is flatter than the superior surface, and is supported by a slightly curved and sloping shelf, which projects forwards from the posterior wall of the abdomen. This has been appropriately called, by

Birmingham, the *stomach-bed.* It is formed by the following structures, all of which are related to the lower surface of the organ: (1) the gastric surface of the spleen; (2) the left suprarenal gland and a varying amount of the upper part of the left kidney; (3) the anterior surface of the pancreas; (4) the transverse meso-colon; and (5) the transverse colon. A niche of the great sac of the peritoneum intervenes between the stomach and the spleen, and the omental bursa separates it from the left suprarenal gland, the kidney, the pancreas,

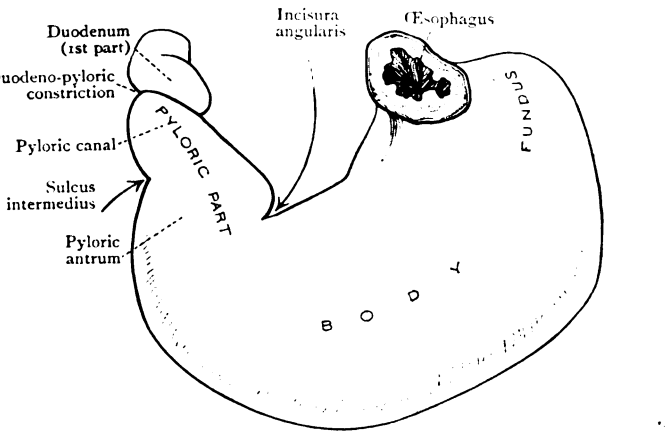


FIG. 180.—Outline of the upper aspect of the Stomach of a Child which has been hardened *in situ* by formalin injection. It is the same stomach as is figured on p. 434.

and colon, whilst the transverse meso-colon intervenes between it and the coils of the small intestine.

The right, upper, or posterior border of the stomach is termed its *lesser curvature.* It extends from the cardiac orifice to the pylorus, and curves round the base of an eminence on the lower surface of the left lobe of the liver, called the tuber omentale, and also, to a smaller extent, round a corresponding prominence of the pancreas. It is therefore concave, and from it proceeds a fold of peritoneum, called the lesser omentum, which connects the stomach to the liver and, to a slight extent, to the diaphragm. The left, lower, or anterior border of the stomach, called the *greater curvature,* on account of its great length, is convex and is directed to the left and

forwards; to its uppermost segment is attached the gastro-phrenic ligament; to its left lateral segment, the gastro-splenic ligament; and to its lowest or anterior segment, the greater omentum.

The stomach is not only curved from one end to the other but it is also bent upon itself more or less acutely so that a notch or angular depression, the *incisura angularis*, is produced in the lesser curvature (Fig. 180). Advantage is taken of the presence of this notch to divide the organ, for descriptive purposes, into a large *cardiac part*, which lies to the left, and a much smaller *pyloric part*, which lies to the right of the incisura.

The cardiac part of the stomach is generally considered to consist of a *fundus* and a *body*. An imaginary line drawn around the organ from the cardiac orifice to a point on the greater curvature diametrically opposite is taken as separating these portions of the stomach from each other.

The short pyloric part of the stomach is composed of a pyloric canal and a pyloric antrum. The *pyloric canal* is a short, narrow, usually cylindrical part, about one inch or one inch and a quarter long, which immediately adjoins the duodeno-pyloric constriction. It constitutes the right extremity of the stomach, and its thick muscular walls and its cylindrical form give it a special character of its own. The pyloric canal is, as a rule, directed backwards, and it is marked off from the pyloric antrum by a slight notch in the greater curvature, termed the *sulcus intermedius*. The *pyloric antrum* lies to the left of the pyloric canal and the sulcus intermedius. It is wider than the pyloric canal, and its walls are not so thick.

But there is also a physiological subdivision of the stomach. During the process of active digestion the right half of the body of the stomach and the whole of the pyloric portion, by the firm contraction of their walls, assume a tubular form. In this tube a thorough mixture and trituration of the food is effected by means of constriction waves which pass over it in regular procession from left to right. The fundus and left half of the body of the stomach maintain a saccular form, and constitute a passive reservoir from which food is squeezed into the more active tubular part to take the place of the material which intermittently escapes from the stomach into the small intestine.

When the stomach is empty it is questionable if it ever assumes, during life, the flaccid, relaxed, and flattened form which is so frequently seen in the dissecting-room, in subjects which have not been specially hardened. In life, the healthy stomach, by contraction of its muscular coat, adapts itself to its contents whether they are liquid, gaseous, or solid, and when empty and contracted its walls are thick and firm.

**Position of the Stomach.**—When *empty* and *contracted* the stomach lies more or less horizontally within the abdominal cavity; it is placed within the left hypochondrium and the left portion of the epigastrium. The organ is bent on itself like a sickle and the fundus sinks downwards so that it comes to look directly backwards; the surfaces are directed upwards and downwards and the curvatures forwards and backwards —the greater curvature being at a slightly higher level than the lesser curvature; lastly, there is a gradual but decided downward slope of the upper surface from the fundus to the pylorus.

The pyloric extremity of the empty stomach lies in the transpyloric plane (Addison), either where the latter cuts the median plane, or from half an inch to an inch to the right of the median plane. The transpyloric plane is situated midway between the upper margin of the manubrium sterni and the upper margin of the symphysis pubis.

The conditions which give rise to the position and form of the empty stomach as described above are sufficiently obvious when the nature of the

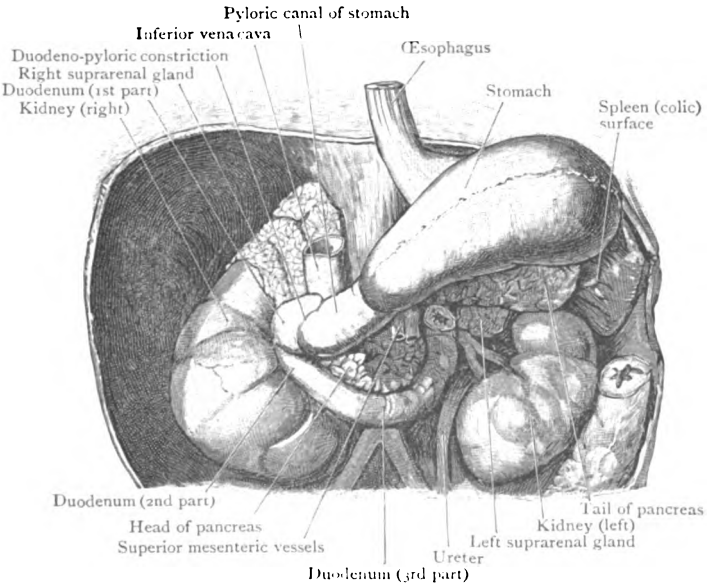


FIG. 181. — Horizontal position of the Stomach in a Child two years old; viscera hardened by formalin injection.

chamber within the abdomen which is occupied by the organ is considered. The roof of this chamber, formed by the liver and diaphragm, is more resistant, more unyielding, than the floor, which is formed chiefly by the transverse meso-colon, buoyed up by the movable coils of small intestine. As the stomach becomes empty and contracted, the intestine, acted on by the abdominal wall, rises up and presses it against the sloping visceral surface of the liver, and the slope or gradual descent to the right, which is so characteristic a feature of the upper surface of the empty stomach, is the result.

When the stomach becomes *full*, it may either retain the horizontal position, which is characteristic of the organ when it is empty, or it may assume a more or less oblique position.

In both cases, it acquires more space within the abdomen by displacing neighbouring viscera, and the *pylorus* moves to the right, but not as a rule more than an inch and a half, or at most two inches, from the median plane. The pylorus does not alter its position in a vertical direction; it maintains the same level within the abdomen. The position of the *cardiac opening* is only slightly affected by the emptying or the distension of the stomach. It is placed opposite the body of the tenth thoracic vertebra, and on the surface of the body its situation may be indicated by placing the finger on the seventh costal cartilage of the left side about one inch from the median plane.

As the stomach fills it becomes more rounded in general outline, and, should it assume the oblique position when full, the fundus is directed upwards, whilst the surfaces look forwards and backwards; further, the part of the greater curvature opposite the incisura angularis takes a median position and occupies a lower level than any other part of the stomach. It follows from this that the pyloric part of the organ courses upwards and to the right to reach its termination.

While the various conditions which determine the position and form of the full stomach are under consideration, it is necessary to take into account the state of the movable, and as a rule yielding, floor of the stomach chamber. It is possible that the easiest and most natural way for the stomach to expand, under ordinary circumstances, is in a downward direction by intestinal displacement, and when this occurs the oblique portion of the organ is the result. But when the intestines are distended the stomach cannot acquire the necessary space in this manner, and the liver, which forms so large a part of the roof of the stomach chamber, has to give way before it. The obvious result of such a change in the position and form of the pliant liver is that the full stomach retains the horizontal position.

The dissector must remember that the description given above refers to the appearance presented by the stomach fixed and hardened after death when the body is lying on its back. It probably has a very similar form and similar relations during life when the body is recumbent; but when the body is erect the œsophageal orifice and the fundus retain their close relationships to the diaphragm and the pylorus remains at the level of the transpyloric plane, but the lowest part of the greater curvature descends to, or below, the level of the umbilicus, and the upper two-thirds of the organ becomes more tubular and lies more in a vertical plane.

**The Abdominal Part of the Œsophagus.**—The abdominal

part of the gullet is very short—probably never more than one inch in length. It lies in the upper and posterior part of the epigastric region, behind a groove in the posterior aspect of the left lobe of the liver, and in front of the left crus of the diaphragm. Its right border passes uniformly and gradually into the lesser curvature of the stomach, without the formation of an angle, but a very definite angle is formed between its left border and the fundus.

**Relations between Thoracic and Abdominal Organs.**—At this stage it is useful to consider the relations between the abdominal and thoracic organs which lie upon the different aspects of the diaphragm. It has been noted that the right lobe of the liver occupies the right vault of the diaphragm, whilst the left lobe of the liver, the fundus of the stomach, and the spleen occupy the left vault. The base of the right lung is in relation to the right lobe of the liver. The pericardium, in by far the greater part of its extent, lies above the left lobe of the liver, which therefore intervenes between it and the stomach; only a limited portion of the apex of the heart extends over the region of the stomach. The base of the left lung lies over the left lobe of the liver, the fundus of the stomach, and the spleen.

**Intestinum Tenue.**—The small intestine is that part of the alimentary canal which succeeds the stomach. It begins in the epigastric region at the pylorus, and ends in the lower part of the right iliac region by joining the large intestine. Its average length is somewhere about twenty-three feet; and as it is traced towards its termination it will be seen to diminish slightly in calibre. It is divided into three portions, viz.:—

1. The duodenum.
2. The jejunum.
3. The ileum.

The *duodenum* is the name which is given to the first part of the small intestine. It is about ten inches long, and extends from the pylorus to the left side of the body of the second lumbar vertebra. As it lies deeply in the greater part of its extent, and as further dissection is necessary to display its relations, it would not be convenient to consider it at present.

The *jejunum* and *ileum* constitute the coils of the small intestine, and are more or less completely concealed by the

greater omentum. The jejunum begins where the duodenum ends, viz., on the left side of the body of the second lumbar vertebra; and the ileum ends in the lower part of the right iliac region by joining the cæcum or commencement of the large intestine. The subdivision of the small intestine is of the most arbitrary kind. It is customary for anatomists to look upon the upper two-fifths of the small intestine beyond the duodenum as being jejunum, and the lower three-fifths as being ileum. There is no hard-and-fast line of demarcation between the lower two divisions—the one passes insensibly into the other; and, as the chief distinction is to be found by an examination of the interior of the tube, the student will not in the meantime see much difference between them.

To expose the commencement of the jejunum, the greater omentum, with the enclosed transverse colon, should be thrown upwards over the lower margin of the thoracic wall. The coils of the small intestine should then be drawn over to the right. The junction between the duodenum and the jejunum will now be seen on the left side of the vertebral column, at the level of the second lumbar vertebra. The termination of the duodenum is fixed, partly by its relation to the peritoneum and partly by the suspensory muscle of Treitz, which will be described later (p. 500); and the commencement of the jejunum bends suddenly forwards and downwards upon it, forming the *duodeno-jejunal flexure*. To bring the termination of the ileum into view, the coils of the intestine should be turned over to the left. The terminal part of the ileum, which almost invariably lies in the pelvis, has no great latitude of movement. It passes upwards, across the iliac vessels and upon the psoas muscle, to join the cæcum at the level of the intertubercular plane, and close to the right lateral plane.

The coils formed by the jejunum and ileum are suspended from the posterior wall of the abdomen by a wide fold of peritoneum, called *the mesentery*. They are thus freely movable within the cavity. Owing to the manner in which the mesentery is attached to the posterior wall of the abdomen (Fig. 183, p. 475), they tend to lie more in the left than in the right portion of the cavity, and they occupy the umbilical, hypogastric, lumbar, and iliac regions, filling up the greater part of the abdominal cavity below the transverse colon and its mesentery. Some of the coils extend downwards

into the pelvis, and not uncommonly one or more coils of the jejunum may be found in the left hypochondrium.

**Meckel's Diverticulum.**—In about 2 per cent. of subjects dissected a blind, hollow protrusion, termed Meckel's diverticulum, juts out at a right angle from the wall of the ileum, at a point rather less than three feet from the junction of the small intestine with the cæcum. It represents a persistent portion of the vitelline duct of the embryo, and under certain circumstances it may lead to conditions which require surgical interference.

FIG. 182.—The Mesentery in a subject which was hardened by formalin injection. The jejunum and ileum have been removed, and the foldings of the mesentery are displayed.

**The Mesentery of the Small Intestine.**—The mesentery of the small intestine is an extensive fold of peritoneum by which the jejunum and ileum are attached to and suspended from the posterior wall of the abdomen. Its posterior border or *root* is attached along an oblique line which extends, from above downwards and to the right, from the left side of the

second lumbar vertebra to the right iliac fossa, crossing in its course the third part of the duodenum, the abdominal aorta, the inferior vena cava, the right ureter, and the right psoas major muscle. Its total length is about six inches. Its anterior border, which is attached to the intestine, is necessarily as long as the part of the gut to which it is attached, that is, about twenty-two feet; but this great length is not at first apparent because the mesentery is thrown into folds like a frill (Fig. 182) and the coiled condition of the gut is due to this arrangement. Thus, the mesentery is markedly fan-like, and its length, from its root to its intestinal attachment, at its longest part, is about six inches after death and when the body is hardened, but it may be considerably longer during life.

The two layers of the peritoneum of the mesentery are not in apposition. They are separated by a variable amount of fat and areolar tissue in which lie the superior mesenteric artery and its branches to the jejunum and ileum, the corresponding veins, the accompanying nerves, the lymph vessels, called lacteals, passing from the gut and numerous lymph glands. The jejunum and ileum lie in the free border of the fold.

**Occasional Peritoneal Fossæ.**—Before the dissection of the mesentery is commenced the dissector should look for certain peritoneal fossæ which are occasionally present. Some of these fossæ lie near the terminal part of the duodenum, others near the termination of the ileum, and one is associated with the root of the pelvic meso-colon.

The chief fossæ in the region of the duodenum are the *duodeno-jejunal*, the *superior duodenal*, the *inferior duodenal*, the *para-duodenal*, and the *retro-duodenal*.

The *duodeno-jejunal* or meso-colic *fossa* lies immediately above the duodeno-jejunal flexure of the small intestine and passes upwards into the root of the transverse meso-colon. The *superior* and the *inferior duodenal fossæ* lie at the left side of the terminal portion of the duodenum, the upper passing upwards towards the upper end and the lower passing downwards towards the lower end. The *para-duodenal fossa* lies a little more to the left. It is a pouch of peritoneum pushed laterally behind the inferior mesenteric vein, and its mouth looks towards the terminal part of the duodenum. The *retro-duodenal fossa* passes upwards behind the terminal part of the duodenum.

The fossæ in the region of the ileo-cæcal junction are the *anterior ileo-cæcal*, the *posterior ileo-cæcal*, and the *retro-cæcal* or retro-colic. The anterior ileo-cæcal fossa lies behind a small fold of peritoneum which crosses the front of the ileo-cæcal junction. Its mouth is directed downwards and to the left. The inferior ileo-cæcal fossa also opens towards the left. It is bounded to the right by the cæcum, in front by the terminal part of the ileum and the adjacent part its mesentery, behind by the mesentery of the vermiform process, and below by the plica ileo-cæcalis, a

fold of peritoneum which passes from the lower border of the ileum to the anterior surface of the mesentery of the vermiform process or, sometimes, to the process itself. The *retro-cæcal* or retro-colic fossa passes upwards behind the upper part of the cæcum and the lower part of the ascending colon; when this fossa is present the vermiform process usually lies in it.

The *inter-sigmoid fossa* also should be looked for at this stage, in order that, if it is present, its boundaries may be examined before they are interfered with by dissection. It runs upwards behind the root of the

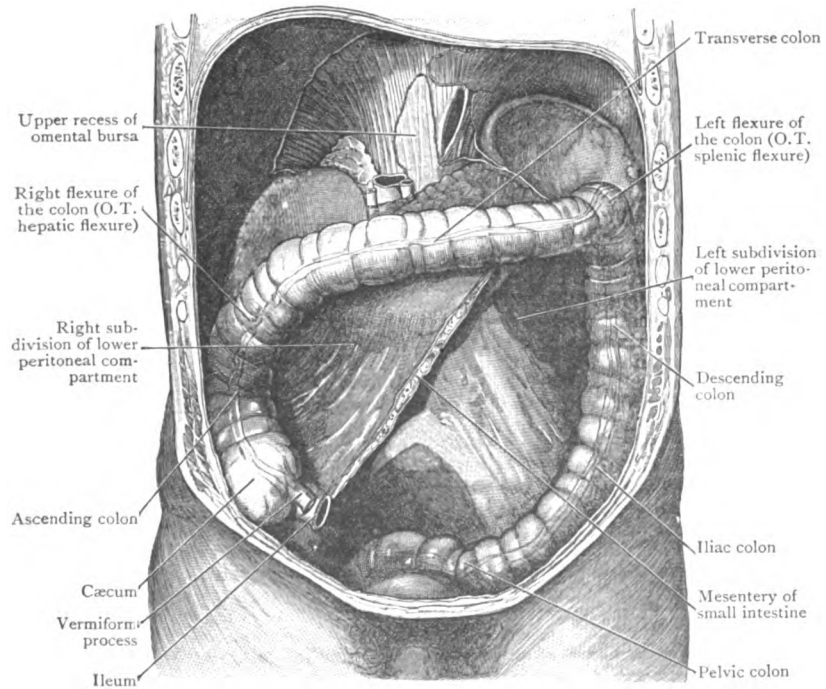


FIG. 183.—Abdomen after removal of Liver, Stomach, Jejunum and Ileum.

pelvic meso-colon, at the left side of the last lumbar vertebra. To find it, turn the pelvic part of the colon upwards.

*Dissection.*—After the dissector has examined any of the occasional peritoneal fossæ which happen to be present he should remove the right layer of the peritoneum of the mesentery, the inferior layer of the transverse meso-colon, and the peritoneum of the posterior wall of the abdomen between the root of the mesentery and the ascending colon. Commence at the upper end of the jejunum and pass downwards to the lower end of the ileum, then upwards along the right side of the posterior wall of the abdomen; finally take away the lower layer of the transverse meso-colon.

As the peritoneum of the right side of the mesentery is removed take away the fat lying between the two layers and clean the structures exposed. They will be—(1) the trunk of the superior mesenteric artery, lying along the root of the mesentery; (2) the accompanying vein, which lies usually to the right of the artery; (3) the intestinal branches of the superior mesenteric artery, passing forwards to the wall of the gut; (4) the accompanying veins, nerves, and lymph vessels; and (5) scattered at varying distances from the border of the gut to the superior mesenteric trunk in the root of the mesentery, the mesenteric lymph glands, which lie in the intervals between the blood vessels.

After the peritoneum has been removed from the posterior part of the abdomen, between the root of the mesentery and the ascending colon, and the extra-peritoneal fat has been cleaned away, a large number of structures will be exposed. Most superficially, immediately behind the peritoneum, will be found the right colic and ileo-colic branches of the superior mesenteric artery, with the accompanying veins, nerves, lymph vessels and glands. In the upper part of the region, directly below the root of the transverse meso-colon, the lower part of the second portion and the right part of the third portion of the duodenum will be found, with the superior mesenteric artery and vein crossing in front of the latter and a small part of the head of the pancreas in the angle between the vessels and the duodenum. Behind the superior mesenteric artery is a part of the aorta, and to the right of the aorta is the inferior vena cava. Partly behind the duodenum and partly to the right of it, on a posterior plane, is the lower pole of the right kidney. The right ureter emerges from behind the duodenum and passes downwards along the medial border of the lower pole of the kidney, and then behind the ileo-colic and the superior mesenteric arteries, on its way to the brim of the pelvis. The internal spermatic vessels cross in front of the ureter (Fig. 184), and the genito-femoral nerve passes downwards and laterally, behind the ureter, on the anterior surface of the psoas major muscle. Beyond the lateral border of the psoas major the fascia on the anterior surface of the quadratus lumborum will be exposed.

As the lower layer of the transverse meso-colon is removed the trunk and branches of the middle colic artery and their anastomoses with branches of the right and left colic arteries will be exposed, with the accompanying veins, nerves, lymph vessels, and glands.

When all the structures mentioned above have been secured and cleaned, the dissector should throw the small intestine over to the right side and should then strip the peritoneum from the posterior wall of the abdomen, between the root of the mesentery to the right, and the descending and the iliac colon to the left. He should remove also the lower layer of the left part of the transverse meso-colon. As he takes away the extra-peritoneal fat, after the removal of the peritoneum, he will bring into view a larger number of structures than on the right side. In the median plane, below the root of the mesentery, lies the lower part of the abdominal portion of the aorta, dividing, opposite the fourth lumbar vertebra, into the two common iliac arteries, each of which is continued downwards into the corresponding external iliac artery. On the surface of the aorta is the aortic plexus of nerves, which must be carefully preserved. To the right of the aorta is the lower part of the inferior vena cava, and to the right of and below the left common iliac artery is the left common iliac vein. Springing from the front of the aorta, about one and a half inches above its bifurcation and to the left of the median plane, is the inferior mesenteric artery. The inferior mesenteric artery runs downwards on the left of the

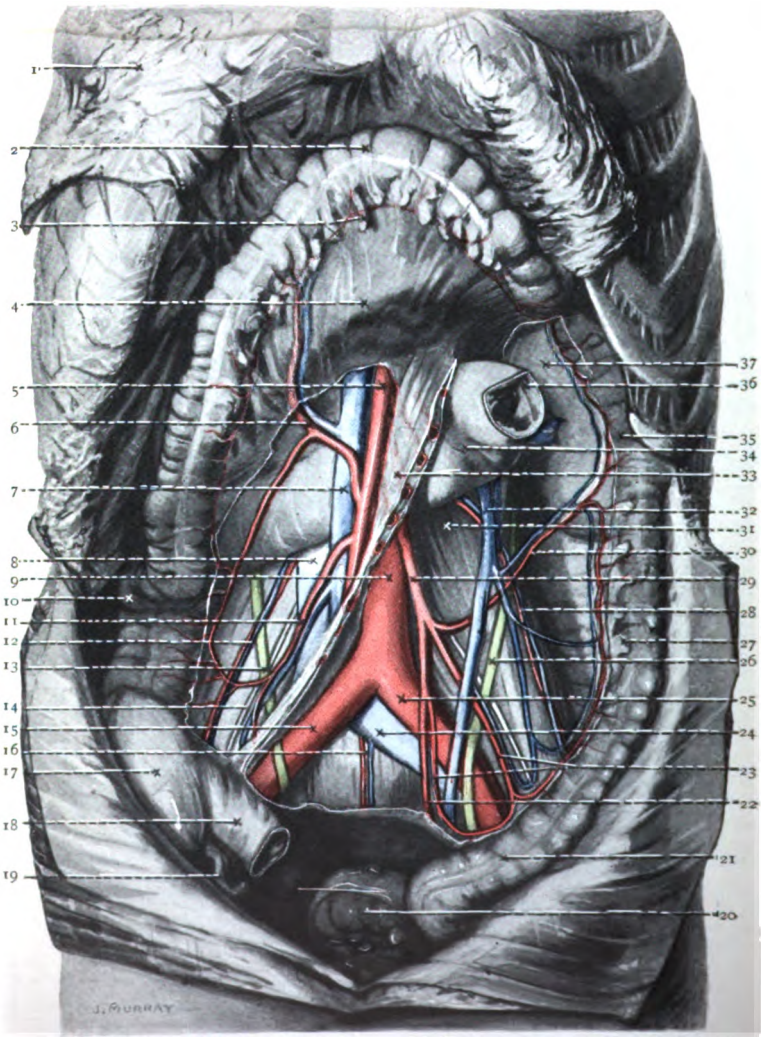


*To face page 477.*

FIG. 184.—Dissection of the lower part of the Abdomen.

The greater omentum and the transverse colon have been turned upwards.

The small intestine has been removed, and the peritoneum and extra-peritoneal fat have been dissected away from the structures on the posterior wall of the abdomen below the level of the transverse meso-colon.

1. Greater omentum.
2. Transverse colon.
3. Appendices epiploicæ.
4. Transverse meso-colon.
5. Superior mesenteric artery.
6. Middle colic artery.
7. Superior mesenteric vein.
8. Inferior vena cava.
9. Aorta.
10. Right flexure of the colon.
11. Common trunk of right and ileo-colic arteries.
12. Internal spermatic vessels.
13. Ureter.
14. Genito-femoral nerve.
15. Right common iliac artery.
16. Middle sacral vessels.
17. Cæcum.
18. Ileum.
19. Vermiform process.
20. Pelvic colon.
21. Iliac colon.
22. Superior hæmorrhoidal artery.
23. Sigmoid arteries.
24. Left common iliac vein.
25. Left common iliac artery.
26. Ureter.
27. Descending colon.
28. Internal spermatic vessels.
29. Inferior mesenteric artery.
30. Left colic artery.
31. Psoas major muscle.
32. Inferior mesenteric vein.
33. Mesentery of small intestine (cut).
34. Duodena-jejunal flexure.
35. Left flexure of the colon.
36. Jejunum.
37. Left kidney.

aorta to the left common iliac artery, where it becomes the superior hæmorrhoidal artery. Before it becomes the superior hæmorrhoidal it gives off the left colic branch, and one or more sigmoid branches. The left colic branch passes to the left, towards the descending colon, and divides into an ascending and a descending branch, which run towards the upper and the lower parts of the descending colon, respectively. The sigmoid branches run downwards and laterally towards the lower part of the iliac colon. To the left of the inferior mesenteric artery is the inferior mesenteric vein, which ascends, crossing behind the left colic artery, to the root of the transverse meso-colon, where it disappears behind the lower border of the pancreas, which is exposed in the upper part of the area under consideration. To the left of the inferior mesenteric vein are the internal spermatic vessels, which pass behind the sigmoid and left colic arteries, or their branches, and also disappear above, behind the pancreas. In the upper and left angle of the area, in the concavity of the left flexure of the colon, is the lower part of the left kidney, and, descending along its medial border, the left ureter, which passes downwards, behind the internal spermatic vessels and the left colic and sigmoid arteries, to the lower end of the left common iliac artery. Running downwards and laterally behind the left ureter, on the front of the left psoas major muscle, is the left genito-femoral nerve, and beyond the lateral border of the left psoas is the fascia on the front of the medial part of the left quadratus lumborum. Along the anterior border of the psoas, at the left of the aorta, is the left sympathetic trunk. The right sympathetic trunk is concealed by the inferior vena cava.

When the dissector has found and defined all the structures mentioned, he should commence the study of the superior and the inferior mesenteric arteries and their branches. He will find that the superior mesenteric supplies the terminal portions of the duodenum, the whole of the jejunum and the ileum, the cæcum, the ascending colon and the greater part of the transverse colon; that the inferior mesenteric supplies the left part of the transverse colon, the left flexure of the colon, the descending colon, the iliac colon, and the pelvic colon, and that it furnishes also the greater part of the blood supply of the rectum, by means of its continuation—the superior hæmorrhoidal artery. He will find also that there is a very free anastomosis between the left colic branch of the inferior mesenteric artery and the middle colic branch of the superior mesenteric artery. At a later period he will find that an inferior pancreatico-duodenal branch of the superior mesenteric anastomoses with the superior pancreatico-duodenal branch of the gastro-duodenal artery, and when he recalls to mind the fact that the gastro-duodenal artery is a branch of the hepatic, and that it furnishes the right gastro-epiploic, which passes to the stomach and anastomoses on its surfaces with the other arteries which supply that viscus, he will recognise that a complete chain of arterial anastomoses runs along the wall of the abdominal part of the alimentary canal, providing for the continuance of the blood supply to the wall of the gut in the event of one or more of the bigger trunks being temporarily or permanently occluded.

**Arteria Mesenterica Superior.**—The superior mesenteric artery springs from the front of the abdominal aorta about a quarter of an inch below the cœliac artery. At its origin it is covered by the neck of the pancreas, and crossed by the splenic vein. Emerging from under cover of the pancreatic neck, it proceeds downwards, in front of the lower portion of the head of the pancreas, crosses the third part of

the duodenum, close to the duodeno-jejunal flexure, and enters the root of the mesentery proper, along which it proceeds to the right iliac fossa, where it ends by anastomosing with one of its own branches. Between its extremities it

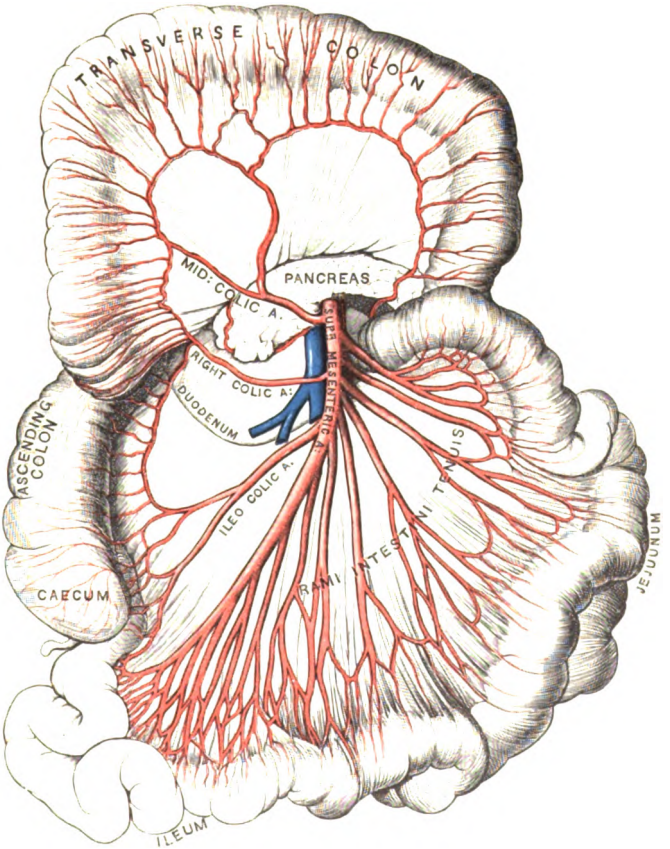


FIG. 185.—Dissection of the Superior Mesenteric Artery.

is slightly curved, the convexity of the curve being directed to the left. It is accompanied by the superior mesenteric vein, which lies upon its right side, and by the superior mesenteric plexus of nerves, which surrounds it closely.

It gives off the following branches :—

Aa. Intestinales
- A. pancreatico-duodenalis inferior.
- Aa. jejunales, Aa. ileæ — to jejunum and ileum.
- A. ileocolica, A. colica dextra, A. colica media — to larger intestine.

**The Inferior Pancreatico-duodenal Artery.**—The inferior pancreatico-duodenal branch takes origin from the upper part of the superior mesenteric artery, or from its first intestinal branch, and passes upwards and to the right behind the head of the pancreas. It gives branches both to the duodenum and to the pancreas, and anastomoses with the superior pancreatico-duodenal artery.

The **jejunal and ileal arteries** spring from the convexity or left side of the superior mesenteric, and proceed obliquely downwards and to the left, between the layers of the mesentery, to supply the jejunum and ileum. They are very numerous—from twelve to fifteen, or even more, in number—and, by their mutual inosculations, they form a very remarkable succession of arches before they finally reach the bowel. At first they run parallel to one another; but soon each divides into two branches which join the immediately adjacent branches of the neighbouring stems, and in this way a series of *arterial arcades* is formed. From these smaller vessels proceed, which divide and unite, in a similar manner, to form a second series of arches; and so on, until three, four, or perhaps even five, tiers of arterial arcades are produced. From the most peripheral arches numerous small branches pass directly to the wall of the intestine. There, along the line of mesenteric attachment, they divide, and the minute twigs, thus derived, pass transversely round the gut so as to encircle it. At first they lie subjacent to the peritoneal coat, but soon they seek a deeper plane in the wall of the intestine, and ultimately after passing through the muscular coats they reach the submucous coat.

The **ileo-colic artery** springs from the middle of the concavity of the superior mesenteric, and proceeds downwards and laterally towards the right iliac fossa. It is placed behind the parietal peritoneum, and divides into an ascending and a descending or ileo-cæcal branch. The *ascending branch* turns upwards, inosculates with a branch of the right colic, and from the arterial arch thus formed branches are given to the ascending colon. The *descending branch*, sometimes called the *ileo-cæcal artery*, proceeds to the upper part of the ileo-

cæcal junction and sends branches in different directions. Two, termed the *anterior* and *posterior cæcal arteries*, pass respectively to the front and back of the cæcum; one, a long slender vessel, the *artery to the vermiform process*, runs downwards behind the terminal part of the ileum and supplies the vermiform process, which it reaches by passing through the mesentery of the process, whilst a fourth, the *ileal artery*, turns to the left along the ileum, and forms a loop with the termination of the superior mesenteric trunk.

**The Right Colic Artery** arises together with, or above, the ileo-colic, and passes to the right, behind the parietal peritoneum on the posterior wall of the abdomen. It divides into two branches, a superior and an inferior. The *superior branch* ascends between the two layers of the transverse meso-colon to inosculate with the middle colic; whilst the *inferior branch* joins the ascending part of the ileo-colic. From the convexity of these arches twigs proceed to the ascending colon, the right flexure of the colon, and part of the transverse colon.

**The Middle Colic Artery** springs from the upper end of the superior mesenteric. It passes between the two layers of the transverse meso-colon, and divides into a right and a left branch. The *right branch* joins the superior part of the right colic, whilst the *left branch* inosculates with the ascending part of the *left colic artery*, which is derived from the inferior mesenteric. Arterial arcades are thus formed in the transverse meso-colon, from which branches proceed for the supply of the transverse colon.

**Vena Mesenterica Superior.**—The superior mesenteric is a large vein which lies to the right of the superior mesenteric artery, and receives tributaries which come from those parts of the intestinal canal supplied by branches from the superior mesenteric artery, and also the right gastro-epiploic vein, from the greater curvature of the stomach, and the pancreatico-duodenal vein. It passes upwards, in front of the third part of the duodenum, and, leaving the root of the mesentery, disappears under cover of the neck of the pancreas, where it unites with the splenic vein to form the *vena portæ*.

**Plexus Mesentericus Superior.**—This is a dense plexus of sympathetic nerve twigs which surrounds the superior mesenteric artery like a sheath. From it filaments are prolonged to the intestine along the various branches of the artery. As the nerves approach the bowel, some of the twigs

leave the vessels and effect a series of communications with each other in the intervals between the arteries.

The superior mesenteric plexus is an offshoot from the *cœliac plexus*, and it distributes twigs to the jejunum, ileum, and to the right half of the large intestine.

**Lymphoglandulæ Mesentericæ.**—The mesenteric lymph glands are very numerous—indeed, considerably over a hundred in number. In health they rarely attain a size greater than that of a small bean or a pea, and they are scattered between the two layers of the mesentery. The larger glands lie along the superior mesenteric artery, whilst the others are placed in the intervals between its branches. It should be noted that they are most numerous opposite the jejunum, and that the mesentery in the immediate vicinity of the intestine is free from them.

A few lymph glands will be noticed in connection with the large intestine also.

The *lacteal vessels* enter the mesentery from the walls of the intestine in enormous numbers. As they proceed upwards they pass through the succession of glands which they meet, and, greatly reduced in number although considerably enlarged in calibre, they terminate usually, near the origin of the superior mesenteric artery, in one or perhaps more trunks which pour their contents into the cisterna chyli of the thoracic duct.

**Arteria Mesenterica Inferior.**—The inferior mesenteric artery, considerably smaller than the superior mesenteric, springs from the left side of the front of the abdominal aorta, about an inch and a half above its termination. It descends, with a slight inclination to the left, to the brim of the pelvis, where it crosses the left common iliac artery and becomes the *superior hæmorrhoidal*, which descends into the pelvis. Before it reaches the left common iliac artery it gives off the left colic and the sigmoid branches.

**The Arteria Colica Sinistra.**—The left colic artery runs to the left and divides into two branches, of which one ascends in front of the lower part of the left kidney to the transverse meso-colon, where it inosculates with the middle colic, whilst the other descends behind the peritoneum of the posterior wall of the abdomen, to unite with the superior sigmoid artery. From the arches thus formed twigs are supplied to the transverse colon, the left flexure of the colon,

and the descending colon. The point of division into upper and lower branches is very variable.

**Arteriæ Sigmoideæ.**—The sigmoid arteries, two or three in number, are distributed to the lower part of the descending

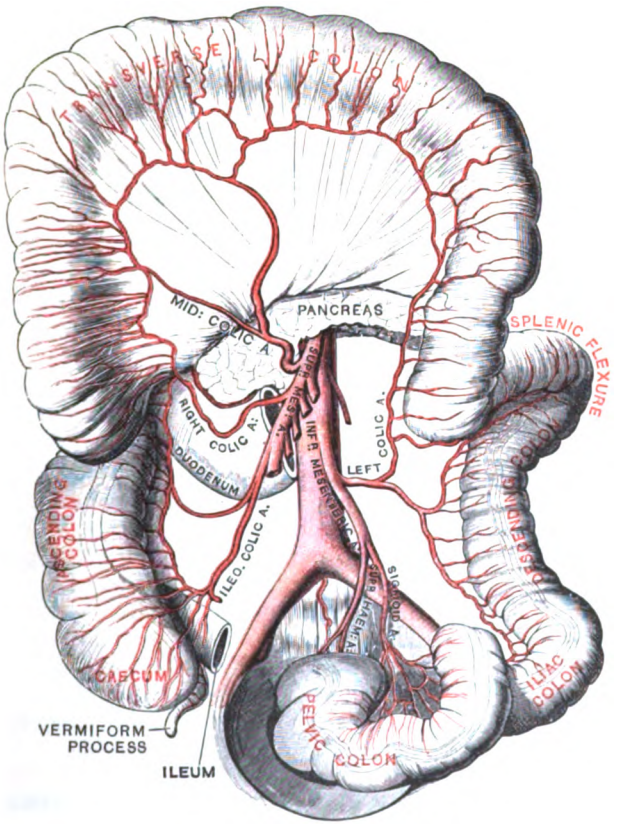


FIG. 186.—Dissection of the Inferior Mesenteric Artery.

colon, the iliac colon, and the pelvic colon. The highest branch enters the left iliac fossa, behind the parietal peritoneum. It sends a branch upwards to form an arch with the descending branch of the left colic, and another downwards, which ultimately enters the pelvic meso-colon and joins the other sigmoid branches. The lower sigmoid

arteries pass into the pelvic meso-colon, and there form a series of arcades, varying in number according to the length of that mesentery; from these arches the twigs for the supply of the pelvic colon are given off.

The *superior hæmorrhoidal artery* will be followed out in the dissection of the pelvis.

**Vena Mesenterica Inferior.**—The inferior mesenteric vein receives tributaries corresponding with the branches of the inferior mesenteric artery. It passes upwards, upon the psoas major muscle, under cover of the peritoneum, to the left of, and at some distance from, the artery, and, disappearing behind the pancreas, it ends in the splenic vein.

**Plexus Mesentericus Inferior.**—This *plexus of nerve fibres* is an offshoot from the left side of the aortic plexus. It closely surrounds the artery, and sends twigs along the branches of the vessel to supply the left half of the large intestine.

**Plexus Aorticus Abdominalis.**—The aortic nerve plexus is placed upon the aorta, between the origins of the two mesenteric arteries. It is more strongly marked upon the sides of the artery than in front of it. Superiorly, it is continuous with the cœliac and renal plexuses, but this fact must be demonstrated at a later stage of the dissection; whilst, inferiorly, it sends several large branches downwards, in front of the common iliac arteries, to join the hypogastric plexus—a plexus which is situated in front of the fifth lumbar vertebra. Upon each side the aortic plexus will be observed to be reinforced by several small twigs from the gangliated trunk of the sympathetic. The *inferior mesenteric plexus*, accompanying the artery of that name, and the *internal spermatic* (or *ovarian*) *plexus* of nerves, which accompanies the internal spermatic (or *ovarian*) artery, are offsets from the aortic plexus.

**Removal of the Jejunum and Ileum.**—Apply two ligatures round the jejunum about an inch below the duodeno-jejunal flexure, and divide the gut between them; next, place two ligatures round the ileum, about six inches above its union with the large intestine, and divide it in like manner; then cut through the blood-vessels and the remains of the mesentery close to the wall of the gut, and remove the separated portion. Take the detached portion of gut to the sink, where the ligatures should be removed, and the cavity of the gut should be thoroughly cleaned by allowing water from the tap to run through it.

The coats of the small intestine should be dissected under water. Take a few inches from the upper end of the jejunum, and, having opened it up with the scissors along the line of mesenteric attachment, pin it out, with

its mucous surface downwards, upon the bottom of a cork-lined tray which has been previously filled with clean water. The jejunum is chosen because its wall is thicker than that of the ileum, and consequently is more easily dissected. Carefully remove the thin serous coat, in order that the subjacent layer of longitudinal muscular fibres may be studied. Then turn the specimen round and pin it down with its mucous surface uppermost. Now remove the mucous membrane with the subjacent flocculent submucous coat, with the scissors, in one layer. The circular muscular fasciculi will come into view.

**Coats of the Small Intestine.**—The small intestine has five coats or strata entering into the formation of its walls, viz. :—

1. Serous.
2. Subserous.
3. Muscular.
4. Submucous.
5. Mucous.

The *serous coating* of the jejunum and ileum is complete, except along the line of the mesenteric attachment. It is exceedingly thin—much thinner than the layers of the mesentery with which it is continuous. Unless great care is taken in stripping it off, some of the subjacent muscular fibres will be taken away with it. The *subserous coat* is a scarcely appreciable amount of areolar tissue which intervenes between the peritoneum and the muscular coat. It need not be taken into account in this dissection. The *muscular coat* is composed of involuntary, non-striated muscular fibres. These are disposed in two layers, viz., an *external stratum* of longitudinal fibres, and an *internal stratum* of circular fibres. Of these the circular layer is the thicker and more distinct of the two. The external longitudinal fibres are spread out, in the form of a thin continuous layer, all round the circumference of the intestine. In that part of the wall opposite the mesenteric attachment the fibres are more thickly disposed than elsewhere. The *submucous coat* is composed of loose areolar tissue which binds the muscular to the mucous coat. It is more firmly connected with the latter. The *mucous coat* must be examined throughout the whole length of the jejunum and ileum.

*Dissection.*—The student has noticed that externally little distinction can be drawn between the jejunum and ileum, but that as the intestine descends it diminishes slightly in its calibre and in the thickness of its walls. It is necessary, therefore, that he should open it up along its whole length, with the view of determining what differences exist internally. Before this is done, about twelve inches of the upper part of the jejunum should be removed and inflated with air. It should then be hung up to dry, in order that the folds of mucous membrane, called plicæ circulares, may be studied in their continuity. The best way to open the

remainder of the intestine is to tie a ligature around the lower cut end of the ileum, and fill the intestine as full as possible with water. The scissors can now be easily carried along the *line of the mesenteric attachment*, and the intestine slit open in its entire length. The intestine can be laid open with much greater ease if a piece of costal cartilage be impaled upon that blade of the scissors which is introduced into the bowel.

**Mucous Membrane of the Small Intestine.**—The *plicæ circulares* (O.T. *valvulæ conniventes*) are the most conspicuous objects on the inner wall of the small intestine. These are folds of the mucous membrane placed more or less transversely to the long axis of the intestine. Note particularly that they are *permanent folds*, and that no amount of stretching or distension of the walls will cause their obliteration. On careful study of the dried specimen three main varieties of plicæ circulares may be recognised. The great majority are in the form of crescentic folds, which extend for a variable distance round the wall of the intestine; others form complete rings around the interior of the intestine; whilst the third variety, and usually the least numerous, are arranged in a spiral manner, and take from one to three spiral turns around the wall of the intestine. Each fold consists of two layers of mucous membrane, with a little intervening areolar tissue derived from the submucous coat. The other coats of the intestine take no part in the formation of the plicæ circulares. In the upper part of the jejunum the plicæ circulares are strongly developed, and placed so closely together that the intervals between them are hardly greater than the thickness of one of the folds. Lower down, however, they gradually diminish in numbers, become more widely separated, more oblique in their direction, and not nearly so large. Towards the middle of the ileum, they become exceedingly sparse and far between, and a little beyond that they usually disappear altogether.

The chief function of the valvulæ conniventes is to increase the absorbing and secreting surface of the small intestine.

Another characteristic of the mucous lining of the small intestine is the presence of *villi*. These are minute projections of the mucous membrane, varying in length from about $\frac{1}{30}$th to $\frac{1}{40}$th of an inch. They occur in enormous numbers over the entire extent of the inner surface of the intestine, not only upon the plicæ circulares, but also in the intervals between them, and they give to the mucous membrane a velvety or fleecy appearance.

To obtain a proper view of these minute villous processes it is necessary to float out a portion of the small intestine in water, after it has been carefully cleansed from adhering mucus, and examine it with an ordinary pocket-lens. If a portion of the upper end of the jejunum is placed side by side with a portion of the lower part of the ileum, and inspected in this manner, the student will readily detect that the villi are, if anything, larger in the jejunum than in the ileum, and that they are decidedly more numerous. They diminish gradually in number and in size from above downwards.

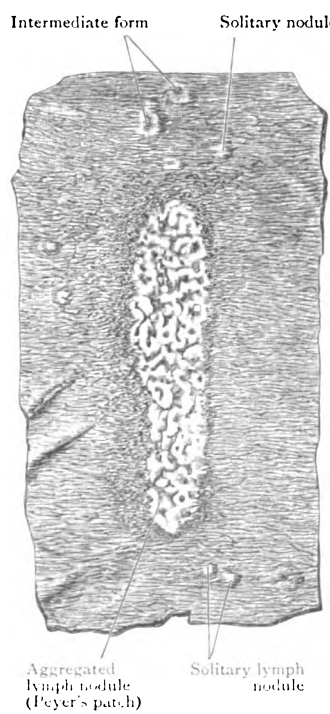


FIG. 187.—Aggregated Lymph Nodule and Solitary Lymph Nodules from the intestine of a child of two years old. (Birmingham.)

*Aggregated lymph nodules* (O.T. *Peyer's patches*) and *solitary lymph nodules* must also be looked for. Frequently they are difficult to find, but when the bowel is held up to the light they can generally be detected. When seeking aggregated lymph nodules it is best to examine the ileum from below upwards.

An *aggregated lymph nodule* consists of a large number of lymph follicles grouped together so as to present to the eye a patch of an elongated, oblong outline. The patches are placed upon that aspect of the intestine which is opposite to the line of the mesenteric attachment, and the long axis of each corresponds in its direction with that of the intestine itself.

In the lower part of the ileum the patches may present a length of one, two, or even four inches, and a breadth of about half an inch, but higher in the ileum they become much smaller and not nearly so numerous, and they are few in number, or entirely absent, in the jejunum. The total

number varies much, but the average number may be stated to be about thirty. They are more numerous in the young, and not so abundant nor so distinctly marked out in later periods of life. Indeed, in very old subjects they may disappear almost entirely.

The *solitary lymph nodules* are isolated lymph follicles, scattered everywhere over the mucous membrane of the small intestine. They are minute, rounded or ovoid, opaque white bodies, about the size of a millet seed, and they usually cause a slight bulging of the mucous membrane at the points where they occur.

The *plicæ circulares*, the *villi*, and *aggregated lymph nodules* are the only special peculiarities of the mucous membrane of the jejunum and ileum which are visible to the naked eye; and, from what has been said regarding them, the dissector will understand that, although they are not arranged in such a way as to mark off the jejunum from the ileum by a clear line of demarcation, they are sufficient to enable him to distinguish between characteristic portions of each—*i.e.*, between portions taken at some distance from the arbitrary line of division. The following are the essential points of difference which should guide him in deciding which is ileum and which jejunum:—

| JEJUNUM. | ILEUM. |
|---|---|
| *Plicæ Circulares.* | |
| Numerous and well marked. | Few in number and poorly developed, and, in its lower part, absent altogether. |
| *Villi.* | |
| Numerous and large. | Not so numerous and not so large. |
| *Aggregated Lymph Nodules.* | |
| Few in number, small in size, and, as a rule, nearly circular in outline. | More numerous, of large size, and oblong in form. |

The general position and the constituent portions of the large intestine have already been noted (p. 439); the positions and relations of the individual parts must now be studied more completely.

**Intestinum Cæcum.**—The cæcum forms the commencement of the large gut. It has the appearance of a sacculated pouch, 2½ inches long and 3 inches broad, continuous above with the ascending colon, and on the left, with the ileum

and the vermiform process. It is completely clothed with peritoneum, and is supplied with blood by branches derived from the loop between the termination of the superior mesenteric artery and its ileo-colic branch.

**Processus Vermiformis.**—The vermiform process springs from the medial and posterior aspect of the cæcum, about an inch below the ileo-cæcal junction, and passes either upwards and to the left, towards the left hypochondrium, or downwards into the pelvis across the right external iliac artery, or upwards behind the cæcum and the ascending colon. It

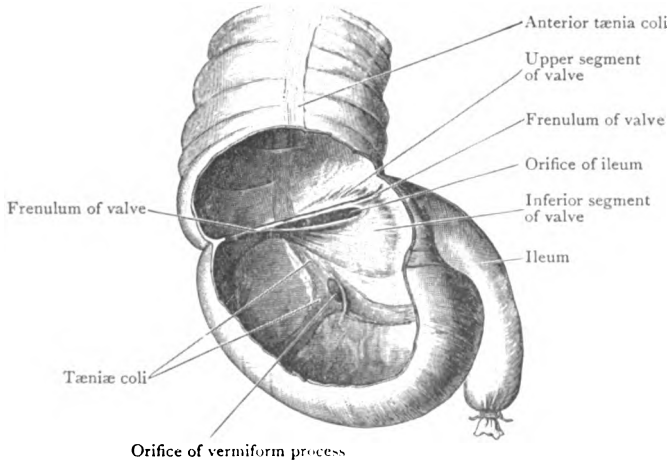


FIG. 188.—Cæcum which has been distended with air and dried, and then opened to show Ileo-Cæcal Opening and Colic Valve. (Birmingham.)

usually occupies the last position if a retro-colic pouch is present. It is attached by the *mesentery of the vermiform process* to the posterior surface of the lower part of the mesentery of the ileum.

*Dissection.*—Turn the cæcum upwards; remove the peritoneum from the wall of the iliac fossa behind it, and take away the extra-peritoneal fat. Note that the peritoneum and fat separate the cæcum from the right psoas and iliacus muscles, and from the femoral nerve (O.T. anterior crural) in the angle between the muscles. The anterior surface of the cæcum is in relation with the anterior wall of the abdomen, or is separated from it by the lower part of the greater omentum.

Cut away a portion of the right lateral wall of the cæcum and examine the ileo-cæcal orifice and the orifice of the vermiform process from the interior of the intestine.

**The Ileo-Cæcal Orifice** is an antero-posterior slit, bounded above and below by a protruding lip, formed by the partial invagination of the lower end of the ileum into the cæcum. The two lips are the two segments of the *valve of the colon* (O.T. *ileo-cæcal valve*). At the extremities of the orifice the segments of the valve unite together and become continuous with a ridge of the wall of the gut which is prolonged around the cavity. The anterior and posterior parts of the ridge, immediately adjacent to and connected with the lips of the valves, are spoken of as the *frenula of the valve.*

The peritoneum and the longitudinal muscular bands are in no way involved in the infoldings which form the valve-flaps; but the other

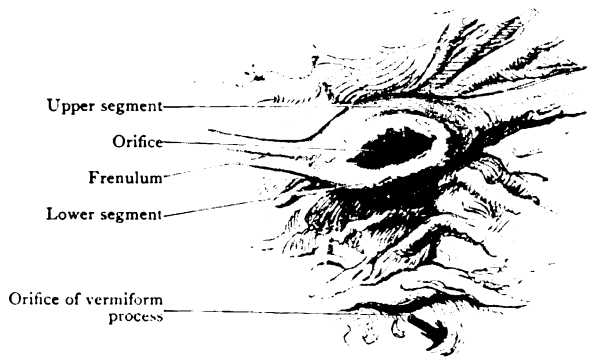


FIG. 189.—Ileo-Cæcal Opening and Valve of the Colon from a subject hardened by formalin injection. (Birmingham.)

constituents of the gut-wall (viz., the mucous membrane, the submucous coat, and the circular muscular fibres) take part in their formation. Villi are present on the ileal but not on the cæcal aspect of each valve-flap.

The function of this valve is obvious. It is so arranged that the free passage of materials from the ileum into the cæcum is in no way impeded; but when the cæcum becomes distended, and there is, consequently, a tendency to regurgitation, the frenula of the valve are put upon the stretch, and the free borders of the segments are brought into firm contact. In this way reflux of the contents of the cæcum into the ileum is prevented, although it is well to note that the obliquity of the entrance of the ileum into the cæcum also exercises a very important influence in the same direction.

The position of the ileo-cæcal orifice is marked on the anterior surface of the abdomen by the medial angle between the intertubercular and the right lateral lines. About an inch below the ileo-cæcal orifice, and on a posterior plane, is the

orifice of the vermiform process, which may be quite open, or it may be partly guarded by a semilunar fold of mucous membrane, the *valve of the vermiform process.*

**Colon Ascendens.**—The ascending colon passes upwards from the cæcum, in the iliac region, through the right lumbar region to the right flexure of the colon in the right hypochondriac region. It varies from about six to eight inches in length. It is covered in front and at the sides by peritoneum which binds it to the posterior wall of the abdomen. Occasionally it is attached to the posterior abdominal wall by an *ascending meso-colon.* Anteriorly, it is either in contact with the anterior wall of the abdomen or it is separated from the abdominal wall by coils of small intestine and the right free margin of the greater omentum.

*Dissection.*—Turn the ascending colon upwards and take away the fatty areolar tissue from behind it; then note that it lies anterior to the upper part of the iliacus, the crest of the ilium, and, above the crest, in front of the fascia covering the quadratus lumborum and the medial part of the aponeurosis of origin of the transversus abdominis. It is separated from the quadratus lumborum, however, not only by the anterior lamella of the lumbar fascia, but also by the last thoracic, the ilio-hypogastric and ilio-inguinal nerves. It is possible that the dissector will not be able to display the last thoracic nerve at this stage of the dissection.

**Flexura Colica Dextra** (O.T. **The Hepatic Flexure**).—The right flexure of the colon lies in the right hypochondrium, below and somewhat behind the anterior part of the lower surface of the right lobe of the liver, to the right of the gall-bladder, and in front of the lower part of the right kidney. It is covered by peritoneum except on its posterior surface, which is attached to the kidney by loose areolar tissue.

**Colon Transversum.**—The transverse colon extends first downwards and forwards and then upwards and backwards, from the under surface of the right lobe of the liver, in the right hypochondriac region, to the lower extremity of the spleen, in the left hypochondriac region. The lowest part of the curve usually crosses through the upper half of the umbilical region, and a small but acute secondary curve, which is developed upon the left extremity of the main curve, lies against the medial border of the upper part of the descending colon. In the greater part of its extent it is enclosed in the posterior wall of the omental bursa, its lower border being attached to the greater curvature of the stomach by the greater omentum, whilst

the posterior part of its upper border is attached to the pancreas by the transverse meso-colon. It is in relation anteriorly, from right to left, with the inferior surface of the right lobe of the liver, the lower part of the posterior surface of the gall-bladder, the cavity of the omental bursa and the anterior two layers of the greater omentum, which separate it from the abdominal wall and the abdominal surface of the

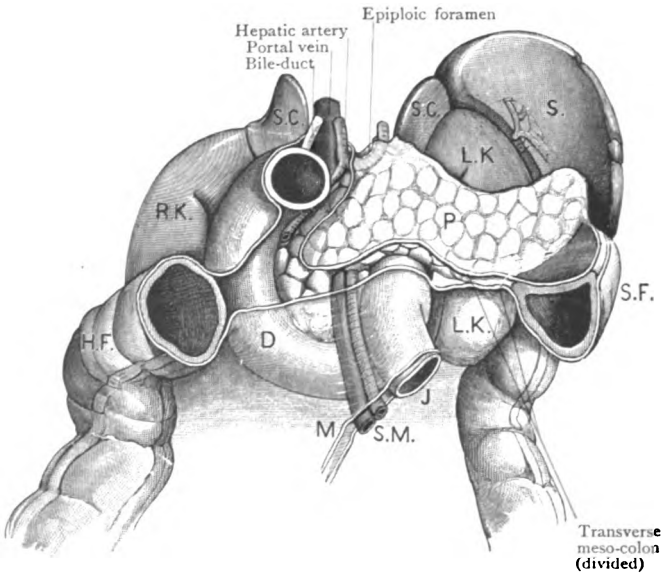


FIG. 190.—Duodenum, Pancreas, and Kidneys. (From the model by His.)

| | |
|---|---|
| D. Duodenum. | R.K. Right kidney. |
| H.F. Right flexure of the colon. | S. Spleen. |
| J. Jejunum. | S.G. Suprarenal gland. |
| L.K. Left kidney. | S.F. Left flexure of the colon. |
| M. Mesentery. | S.M. Superior mesenteric vessels. |
| P. Pancreas. | |

diaphragm. Before it enters the posterior wall of the omental bursa its posterior surface is in direct relation with the anterior surface of the second part of the duodenum; then it lies in front of the third part of the duodenum, the upper end of the mesentery of the small intestine, the duodeno-jejunal flexure, and in front of coils of jejunum, which separate it from the lower pole of the left kidney. Its lower border is attached to

the posterior two layers of the greater omentum. The right extremity of its upper border is in relation to the inferior surface of the liver and the posterior surface of the gall-bladder, and, in the remainder of its extent, it is attached posteriorly by the transverse meso-colon to the pancreas, and anteriorly it embraces the lower part of the greater curvature of the stomach, behind the line of attachment of the greater omentum to the lower border of that viscus.

**The Transverse Meso-colon** is a fold of peritoneum which connects the posterior part of the upper border of the transverse colon to the front of the head and to the anterior border of the body of the pancreas. It is not so extensive as the transverse colon, and is absent to the right of the head of the pancreas where the transverse colon is in direct contact with the second part of the duodenum. The lower layer of this fold has already been removed, but the upper layer and the arteries which lie between the two layers are still in position and will enable the dissector to verify the attachments of the fold, which contains the middle colic artery and its branches, the accompanying veins, nerves, and lymph vessels, and the terminal portions of the upper branches of the right and left colic vessels and their anastomoses with the middle colic vessels.

Before removing the ascending colon and the transverse colon, the dissector should again examine the longitudinal muscle fibres of the walls of the large intestine. They are arranged in the form of three longitudinal bands (*tæniæ coli*). The bands converge together on the medial and posterior aspect of the cæcum and fuse into a continuous layer on the vermiform process. At the other end of the large gut they converge again, on the wall of the rectum, first into two bands and then into a continuous layer, but in the intervening parts of the large intestine the bands are widely separated, one running along the anterior border (*tænia libera*), one along the posterior border (*tænia mesocolica*), whilst the third lies along the medial borders of the ascending and descending portions of the colon, and along the lower border of the transverse colon (*tænia omentalis*).

*Dissection.*—Place two ligatures round the upper part of the ascending colon, immediately below the right flexure of the colon; divide the intestine between the ligatures and remove the cæcum and ascending colon. Place two ligatures round the transverse colon, to the left of the right flexure of

the colon, and another pair of ligatures round the left part of the transverse colon near the left flexure of the colon. Divide the transverse colon between the ligatures at each end; then cut the transverse colon away from the remains of the transverse meso-colon and its contents. Take the separated portions of the large intestine to the sink, remove the ligatures and wash out the cavity of each part with running water. In one piece carefully divide the longitudinal bands of muscle in the intervals between the sacculi of the wall, then pull on the extremities and note—(1) that the intestine lengthens, (2) that to a great extent the sacculi disappears, and (3) that when the tension is removed the piece of intestine does not return to its former length. This simple experiment shows that it is the shortness of the longitudinal bands which causes the puckered condition of the wall of the large gut. Open both the separated portions and note that the mucous membrane is devoid both of plicæ circulares and of villi. Hold the wall of the intestine to the light and note that whilst solitary lymph nodules are present there are no aggregated lymph nodules.

**Structure of the Vermiform Process.**—The *serous coat* is complete, and the subjacent *external longitudinal layer* of the muscular coat forms a continuous and uniform covering, which at the base of the process becomes divided into the three bands or tæniæ coli of the cæcum. The *internal circular fibres* of the muscular coat are likewise spread uniformly and continuously over this part of the intestine. The distinguishing and important structural feature of the vermiform process is found in the *submucous coat*. This coat is loaded with lymph tissue which is arranged in numerous nodular masses, like solitary lymph nodules, placed so closely together that adjacent nodules in many cases become confluent with each other. When the process is cut across and examined under a low power of the microscope, these lymph follicles, arranged in this manner, present a strong resemblance to what is seen in a cross-section through an aggregated lymph nodule.

**Intestinum Crassum (Large Intestine).—Structure of Large Intestine.**—Transverse and oblique ridges or folds, corresponding to the constrictions which separate the sacculi, are everywhere apparent on the inner surface of the large intestine. If the longitudinal bands of muscular fibres are removed or divided at short intervals, and the intestine stretched, both sacculi and constrictions disappear, and the wall of the intestine becomes uniform. The mucous membrane of the large intestine is destitute of *villi*, but *solitary lymph nodules* are present in considerable numbers. If the mucous surface is examined with a lens, it will be seen to be studded over with the round mouths of tubular glands—intestinal glands—which are embedded in the mucous membrane (*crypts of Lieberkühn*). The same glands are present in the mucous membrane of the small intestine, but they are not so large.

*Dissection.*—The coats of the large intestine must be dissected in the same manner as in the case of the small intestine.

**Coats of the Large Intestine.**—In connection with the *serous coat*, the student has already taken notice of the *appen-*

*dices epiploicæ.* The *external, longitudinal* muscular fibres have also been observed to be disposed in three flat bands. These begin on the cæcum at the base of the vermiform process. From this they diverge, so as to take up positions on different aspects of the gut. They are placed as follows:—(1) One in relation to the attached surface (tænia mesocolica); (2) the second upon the anterior aspect (tænia libera); (3) and the third along the medial aspect of the gut, but, in the case of the transverse colon, the latter band is in relation to the inferior aspect of the tube (tænia omentalis). The *internal circular* muscular fibres constitute a thin uniform layer over the entire extent of the gut, but are most distinct in the constrictions between the sacculi. The *submucous coat* is in no respect different from the corresponding coat in the small intestine.

**Flexura Colica Sinistra** (O.T. **The Splenic Flexure of the Colon**).—The left flexure of the colon is situated in the left hypochondriac region in close relation with the lower end of the spleen, the tail of the pancreas, and the lateral border of the left kidney. It is closely attached—(1) to the left extremity of the anterior border of the pancreas, by the left portion of the transverse meso-colon; (2) to the stomach, by the upper end of the left border of the greater omentum; (3) and to the abdominal surface of the diaphragm, opposite the eleventh rib in the mid-axillary line, by the phrenico-colic ligament. It is therefore a more fixed, and it is also a more acute, flexure than the right flexure of the colon.

**Colon Descendens.**—The descending colon commences at the left flexure of the colon, in the left hypochondriac region, descends along the lower part of the lateral border of the left kidney, turns slightly medially to the apex of the lower pole of the kidney, and then descends, vertically, to the left iliac crest, where it becomes the iliac colon. Its length varies from four to six inches. Like the ascending colon it is covered in front and on each side by peritoneum, and its posterior surface is in relation with the extra-peritoneal fat which separates it from the fascia in front of the quadratus lumborum and the medial part of the aponeurosis of origin of the transversus abdominis. Its posterior and anterior relations are similar to those of the ascending colon (see p. 491).

**The Iliac Colon.**—This portion of the colon commences

at the termination of the descending colon, at the level of the upper and posterior part of the iliac crest. It passes downwards and forwards to the region of the anterior superior iliac spine, and then turns medially, along the line of the inguinal ligament, to the brim of the pelvis minor, where it becomes the pelvic colon. Its length is variable, but averages about six inches. It does not possess a mesentery, but is covered with peritoneum anteriorly and along its sides. Posteriorly, it is separated by the extra-peritoneal fat from the iliacus, the psoas major, the femoral nerve (O.T. anterior crural), which lies in the groove between the two muscles, and its termination is in front of the left external iliac artery.

The remaining portions of the large intestine will be considered in association with the dissection of the pelvis.

*Dissection.*—Place two ligatures round the descending colon, below the left flexure, and two more ligatures round the junction of the iliac with the pelvic colon; divide the intestine between each pair of ligatures and remove the descending and the iliac portions of the colon. Take the detached intestine to the sink, wash it thoroughly, open it, and note that, as in the other parts of the large intestine previously examined, the mucous membrane is devoid of villi and of plicæ circulares. After the separated part of the intestine has been examined, clean the posterior wall of the abdomen in the regions from which it was removed and thus expose the structures which form its posterior relations. After these have been displayed, clear away the remains of the transverse meso-colon from the front of the pancreas and proceed to the examination of the duodenum.

**Duodenum.**—It has already been noted that the duodenum is the first part of the small intestine; and it would have been examined, in proper sequence, immediately after the examination of the stomach, had it not been that a complete examination of it at that time would have interfered too much with the relations of other portions of the intestine which have now been removed.

The duodenum is from ten to twelve inches in length; it is the widest and the most fixed of the three parts of the small intestine, and its walls are thicker than those of the other two parts. It extends from the pylorus, which lies in the transpyloric plane half an inch to the right of the median plane, to the duodeno-jejunal flexure, situated at the left side of the second lumbar vertebra, slightly below the transpyloric plane and about an inch to the left of the median plane. Whilst passing from its commencement to its termination the duodenum describes a C-shaped curve, the concavity of the curve, which embraces the head of the pancreas, being directed upwards and to the left.

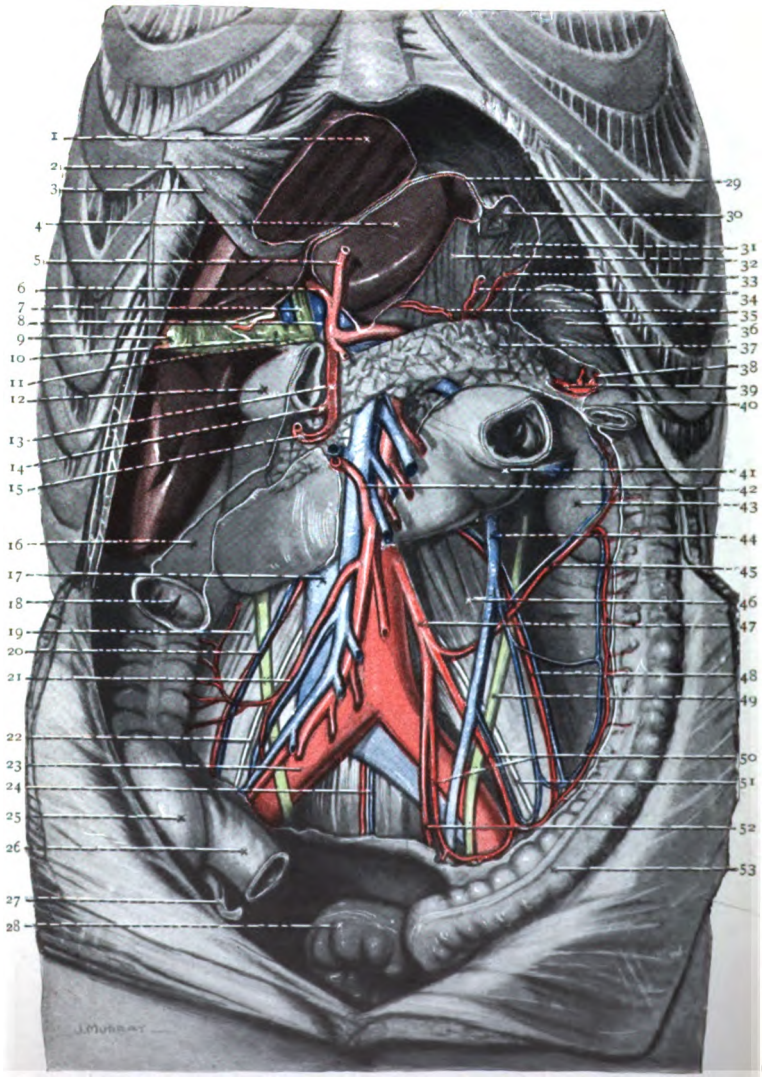


*To face page* 497.

FIG. 191.—Dissection of the Abdomen.

The left lobe of the liver, the stomach, the lesser omentum, the greater omentum, and the transverse colon have been removed.

The greater part of the posterior wall of the omental bursa has been dissected away, and the peritoneum and extra-peritoneal fat have been removed from the posterior wall of the lower part of the abdomen.

1. Cut surface of left lobe of liver.
2. Falciform ligament.
3. Ligamentum teres.
4. Caudate lobe.
5. Left hepatic artery.
6. Right hepatic artery.
7. Hepatic duct.
8. Portal vein.
9. Fundus of gall-bladder.
10. Cystic duct.
11. Bile duct.
12. Duodenum, 1st part.
13. Gastro-duodenal artery.
14. Superior pancreatico-duodenal artery.
15. Right gastro-epiploic artery.
16. Duodenum, 2nd part.
17. Kidney.
18. Right flexure of the colon.
19. Psoas major muscle.
20. Spermatic vessel crossing ureter.
21. Common trunk of ileo-colic and right colic arteries.
22. Genito-femoral nerve.
23. Right common iliac artery.
24. Middle sacral vessels.
25. Cæcum.
26. Ileum.
27. Vermiform process.
28. Pelvic colon.
29. Cut edge of lesser omentum.
30. Œsophagus.
31. Left crus of diaphragm.
32. Right crus of diaphragm.
33. Left inferior phrenic artery.
34. Left gastric artery.
35. Right inferior phrenic artery.
36. Spleen.
37. Pancreas.
38. Left gastro-epiploic artery.
39. Splenic artery.
40. Left flexure of the colon.
41. Duodeno-jejunal flexure.
42. Middle colic artery.
43. Left kidney.
44. Inferior mesenteric vein.
45. Left colic artery.
46. Psoas major muscle.
47. Inferior mesenteric artery.
48. Spermatic vessels.
49. Ureter.
50. Sigmoid arteries.
51. Genito-femoral nerve.
52. Superior hæmorrhoidal artery.
53. Iliac colon.

For convenience of description the duodenum is divided into four parts—(1) superior, (2) descending, (3) inferior, (4) ascending. The greater portion of the first part is surrounded by peritoneum which is continuous below with the greater omentum, and above with the lesser omentum, but its terminal portion is devoid of peritoneum posteriorly and inferiorly. The second part is covered by the peritoneum in front, and on the right side, except where it is crossed by the transverse colon. The third part is covered in front and below; and the fourth part is covered in front and on the left side. The remaining surfaces of the second, third, and fourth parts of the duodenum are devoid of peritoneum, and they lie in relation either with other viscera, or with large blood-vessels, or with the posterior wall of the abdomen.

*Pars Superior.*—The first part of the duodenum is two inches in length; it lies in the epigastric region, and for about an inch or more from the pylorus it is enveloped by the same two layers of peritoneum which invest the stomach; consequently, it enjoys a limited degree of movement. In its terminal part it is covered by the peritoneum only on its anterior and superior surfaces. Its position and relations are dependent upon the degree of distension of the stomach. When that viscus is empty, and the pylorus, in consequence, lies close to the median plane, the first part of the duodenum passes backwards and to the right, with a slightly upward inclination, in correspondence with the slope of the visceral surface of the liver, until it reaches the neck of the gall-bladder. Here it ends by bending suddenly downwards into the second part. Under these circumstances the superior part of the duodenum lies in close apposition with the lobus quadratus of the liver. When the stomach, on the other hand, is distended, the pylorus comes into relation with the lobus quadratus, and the superior part of the duodenum is somewhat shortened and proceeds straight backwards. It then occupies only the posterior part of its original situation, and its termination is lodged in a depression at the right end of the porta hepatis. The relations of the first part of the duodenum are as follows: *above* and *in front*, the under surface of the liver; *below*, the pancreas; *behind*, the vena cava bile-duct, the gastro-duodenal artery, the upper part of the neck of the pancreas, and the portal vein.

*Pars Descendens.*—The second part of the duodenum is

usually from three to four inches in length, and takes a downward course from the inferior surface of the liver. At its commencement it is placed in the epigastric region, and it descends into the umbilical region, lying close to the medial side of the right lateral plane. Reaching the level of the third lumbar vertebra, it turns towards the median plane and enters upon the third stage of its course. This second stage of the duodenum is immovably fixed in its position. It is covered by peritoneum only on its anterior and lateral surfaces, and it is crossed by the commencement of the transverse colon, which, in this part of its course, does not possess a mesentery (Fig. 170). *Posteriorly*, it rests upon the right border of the inferior vena cava and presents a variable relation to the renal vessels and the anterior surface of the right kidney, in the neighbourhood of the hilum. *To the right* is the right flexure of the colon; and *to the left* is the head of the pancreas, which is moulded upon the medial side of this part of the duodenum.

The bile-duct and the pancreatic duct open into the second part of the duodenum a little below its middle, at the junction of its medial and posterior aspects.

*Pars Horizontalis.*—The third part of the duodenum crosses the posterior wall of the abdomen at the level of the third lumbar vertebra, its direction being from right to left and slightly upwards. To the right of the median plane it lies in the upper part of the umbilical region, but near its termination it rises above the subcostal plane into the epigastric region. Its anterior and inferior surfaces are covered by peritoneum. It lies behind the transverse colon; and it is crossed by the upper part of the root of the mesentery of the small intestine, containing the superior mesenteric artery and vein. Posteriorly, it rests against the right ureter, the right psoas major muscle, the right internal spermatic artery, the inferior vena cava, and the abdominal part of the aorta. Its upper border is in relation with the head of the pancreas and the inferior pancreatico-duodenal artery; and its lower border is in relation with coils of the jejunum.

*Pars Ascendens.*—The fourth part of the duodenum passes upwards from the level of the upper part of the third lumbar vertebra to the duodeno-jejunal flexure. In front and on the left it is covered by peritoneum, and is in relation with the upper part of the jejunum. To the right it is in

relation, anteriorly, with the head of the pancreas and, posteriorly, with the aorta. Behind it lie the anterior border of the right psoas major muscle, and the right sympathetic trunk; and the left renal vein crosses behind it, unless the vein lies at a somewhat relatively higher level, behind the lower surface of the pancreas.

*Dissection.*—Cut through the peritoneum as it passes from the duodenum to the right kidney on the right, and from the duodenum to the posterior wall of the abdomen below and to the left; then turn the second part medially, and the third and fourth parts upwards, to examine the posterior relations noted above. The first part of the duodenum and the attached portion of the pyloric end of the stomach can be turned to the right for the examination of the posterior relations of the first part of the duodenum.

**Suspensory Muscle of the Duodenum and the Root of the Mesentery.**—The duodeno-jejunal flexure and the root of the mesentery are held in position and prevented from slipping downwards on the posterior wall of the abdomen by a band of involuntary muscular fibres which fixes them to the diaphragm. This band is called the suspensory muscle of Treitz. It is attached above to the diaphragm, on the right side of the œsophageal aperture. From this it proceeds downwards, on the left side of the cœliac artery, to the duodeno-jejunal flexure, into which a large number of its fibres are inserted. The remaining fibres enter the mesentery and find attachment to the peritoneum. In the child the suspensory muscle is well marked and easily isolated, but in the adult it loses its distinctly muscular character and becomes more or less blended with neighbouring tissues.

**Pancreas.**—The pancreas is an elongated gland which stretches across the posterior wall of the abdomen behind the stomach. For the most part it is situated in the epigastric region, only a small portion of its left extremity being placed in the left hypochondriac region. As in the case of the other solid organs contained within the abdominal cavity, its form is greatly modified by the condition of the hollow viscera in its immediate vicinity, and its true shape can be ascertained only by fixing it *in situ* by injections of some hardening reagent. It may be described as consisting of a *head*, a *neck*, a *body*, and a *tail*.

The *head of the pancreas* is the flattened portion of the gland which lies in front of the vertebral column and occupies the concavity of the duodenum. It rests upon the

inferior vena cava and to some extent also upon the aorta, whilst its anterior surface is crossed by the transverse colon. As a rule its marginal lobules show a tendency to extend over the anterior surface of the second and third parts of the duodenum so as to overlap the gut in the vicinity of its concavity. Certain other relations may be noticed in connection with the head of the pancreas, viz.: (1) the bile-duct passes down behind it, in close relation to the second part of the duodenum; (2) the pyloric part of the stomach lies in front of it, above the transverse colon; (3) its lower part, the *uncinate process*, is prolonged to the left, along the upper border of the third part of the duodenum, behind the superior mesenteric vessels, and then upwards behind the neck; (4) the vena portæ is formed in front of the upturned part of the uncinate process and behind the neck.

The *neck of the pancreas* (Symington) is a narrow, constricted portion of gland-substance which springs from the anterior aspect of the head, nearer its upper than its lower margin. It constitutes the link of connection between the head and the body of the pancreas, and, as it proceeds to the left and forwards, it lies in front of the commencement of the vena portæ and of the termination of the superior mesenteric vein. These vessels intervene between the neck and the anterior surface of the upper part of the uncinate process. The anterior part of the anterior surface of the neck is covered by the layer of peritoneum which forms the posterior wall of the omental bursa; it is usually somewhat depressed by the pyloric end of the stomach, which rests upon it. The posterior part of the anterior surface is separated from the first part of the duodenum by the gastro-duodenal artery.

The *body of the pancreas* extends from the anterior and left extremity of the neck, backwards and to the left, across the lower part of the left suprarenal gland, and the front of the left kidney, to the short *tail*, which lies in relation with the spleen. It presents *anterior*, *inferior*, and *posterior surfaces*, which are separated from each other by *superior*, *anterior*, and *inferior borders*. The *anterior surface* looks forwards and upwards, and is covered by the peritoneum of the posterior wall of the omental bursa. This surface of the pancreas, in the greater part of its extent, supports the postero-inferior surface of the stomach, and is hollowed for its reception.

Immediately adjoining the neck a smooth rounded prominence projects upwards and forwards from the junction of the anterior surface and the upper border, above and to the left of the lower part of the lesser curvature of the stomach. This process is the *tuber omentale* (His). It abuts against the lesser omentum, which separates it from the omental tubercle of the liver. The *inferior surface* of the body of the pancreas looks downwards and rests upon the duodeno-jejunal flexure, coils of the small intestine, and the transverse colon close to the left flexure of the colon. It is completely covered by peritoneum which is continuous with the posterior

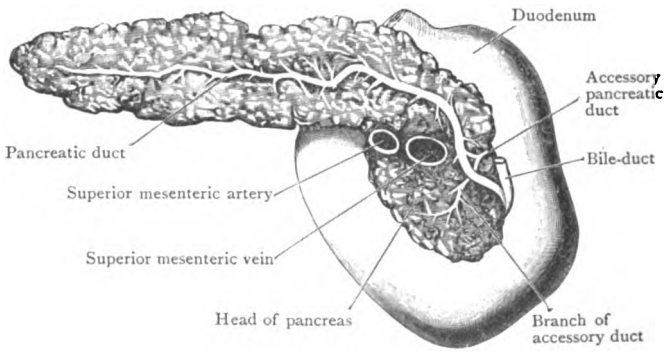


FIG. 192.—Dissection of the posterior surface of the Pancreas to show its Ducts. (Birmingham.)

layer of the transverse meso-colon; and it varies greatly in extent, in association with the varying degrees of intestinal pressure to which it is subjected from below.

The gastric pressure exerted on the pancreas from above, and the counter-pressure which is exerted by the intestine on the inferior surface of the organ from below, varying, as they do in the same subject, according to the condition of these hollow viscera, determine, in a great measure, the shape of the body of the pancreas. The body of the pancreas has the appearance of being wedged in between the two layers of the transverse meso-colon at its root.

The splenic artery pursues a wavy course along the superior border of the pancreas, whilst the transverse meso-colon is attached to its anterior border.

The *tail of the pancreas* abuts against the visceral aspect of the spleen, and usually rests upon a small depression on the

lower and medial part of the gastric concavity of that organ (Fig. 197, p. 512).

*Dissection.*—To display the posterior relations of the body and neck of the pancreas, raise the tail from the spleen; then, working from left to right, carefully separate the body and the neck from the structures which lie behind them.

The *posterior surface* of the body of the pancreas lies in front of the middle portion of the left kidney; in front of the hilum of the kidney and the structures which pass through it; in front of the lower part of the left suprarenal gland; in front of the left crus of the diaphragm; and it joins the left and anterior end of the neck in front of the left border of the aorta. The splenic vein runs behind its upper border, between it and the kidney and the left suprarenal gland, to reach the back of the neck, where it joins with the superior mesenteric vein to form the portal vein. The inferior mesenteric vein passes behind the right end of the posterior surface to join the splenic vein, and the left internal spermatic vein also ascends behind it to join the left renal vein, which issues from the hilum of the kidney and passes to the right to join the inferior vena cava behind the head of the pancreas.

**Ducts of the Pancreas.**—The ducts of the pancreas are, as a rule, two in number—a main duct and an accessory duct. Both run within the gland substance.

The main *pancreatic duct of Wirsung* begins at the tail of the gland by the union of the small ducts issuing from the lobules in that region, and it proceeds towards the right. During its course it gains considerably in size being joined by numerous small ducts which issue from the various groups of lobules. Reaching the neck of the gland it bends downwards into the substance of the head. If the gland substance is carefully divided, little difficulty will be experienced in discovering the main duct. The extreme whiteness of its walls is a help to the student in this dissection. Close to the duodenum the pancreatic duct comes in contact with the bile-duct, and, in company, both pierce the coats of the descending part of the duodenum upon its posterior and medial aspect, and terminate in its wall in a dilatation, the *ampulla of Vater*, which opens into the cavity of the duodenum at the apex of a papilla, called the *papilla duodeni*.

The *accessory duct of Santorini* is small, and arises in the lower part of the head of the gland. It usually has an

independent opening into the duodenum, above and anterior to the opening of the main duct.

The dissector is now in a position to study the *biliary ducts* and the *portal vein.*

**The Biliary Ducts.**—The ducts which carry the bile, secreted by the liver, from the liver and the gall-bladder to the duodenum are—(1) the right and left hepatic ducts, (2) the common hepatic duct, (3) the cystic duct, and (4) the bile-duct. Bile flows only in one direction through the hepatic ducts and the bile-duct, that is, towards the duodenum; but through the cystic duct it flows sometimes to and sometimes from the gall-bladder.

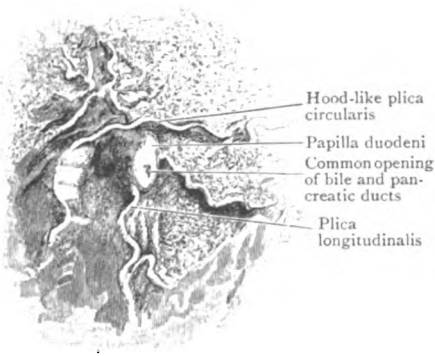


FIG. 193.—The Papilla Duodeni. (Birmingham.)

The *right* and *left hepatic ducts* issue from the corresponding lobes of the liver into the porta hepatis, and unite within it to form the *common hepatic duct.* The latter, which is about one inch (2.5 cm.) in length, descends into the upper part of the lesser omentum, where it unites with the cystic duct (which has already been examined p. 447), to form the bile-duct. As it descends, the common hepatic duct passes either anterior to or posterior to the right branch of the hepatic artery.

**Ductus Choledochus** (O.T. **Common Bile-Duct**).—The bile-duct is from three and a half to four inches long (8.7 to 10 cm.). In the first part of its course it lies in the right free border of the lesser omentum, to the right of the hepatic artery, and in front of the epiploic foramen, from which it is separated by the right border of the portal vein and the posterior layer of the lesser omentum. In the second part of its course it passes behind the first part of the duodenum, with the gastro-duodenal artery, close to the posterior end of the neck of the pancreas; then, entering on

the third part of its course, it dips behind the right border of the head of the pancreas, and, coming into relation with the main duct of the pancreas, it accompanies that duct into the wall of the second part of the duodenum, where they both enter the ampulla of Vater. The ampulla opens into the cavity of the gut by a single orifice, which is situated on the duodenal papilla.

*Dissection.*—Make a vertical incision in the anterior wall of the second part of the duodenum, nearer its right than its left border. At the upper and lower ends of the vertical incision make short transverse incisions, and turn the flaps, so formed, aside. Clean the interior of the duodenum with a sponge, and then examine the mucous membrane. Note that the mucous membrane of the second part is thrown into numerous and large plicæ circulares, and that, as a rule, it is deeply stained by bile. Look for a longitudinal fold of the mucous membrane, which lies at the junction of the medial and posterior walls, nearer the lower than the upper end; this is the *plica longitudinalis*. It serves as a guide to the duodenal papilla, which lies at its upper extremity, usually concealed by one of the largest of the plicæ circulares. Pass a small probe through the opening on the apex of the papilla into the ampulla. Make an opening in the lower part of the bile-duct, and pass a small probe along the duct into the ampulla; perform the same operation on the main pancreatic duct; then cut down through the medial wall of the gut and open up the lumina of the ducts, the cavity of the ampulla of Vater, and its orifice of communication with the interior of the duodenum.

**Vena Portæ (Portal Vein).**—Blood is carried to the liver both by the hepatic artery and by the portal vein. The hepatic artery, which carries arterial blood, has already been examined, p. 445. The portal vein, which carries the venous blood from the whole of the abdominal part of the alimentary canal, except the anal canal, and from the spleen, the pancreas, and the gall-bladder, must now be studied. It is a wide vessel, about three inches in length (7.5 cm.), which is formed by the union of the superior mesenteric and splenic veins, behind the neck of the pancreas, between it and the upturned uncinate process of the head of the pancreas. It ascends, behind the first part of the duodenum and in front of the inferior vena cava, to the lower margin of the epiploic foramen, where it leaves the vena cava, enters the lesser omentum, and continues upwards, in front of the epiploic foramen and behind the bile-duct and the hepatic artery, to the right extremity of the porta hepatis; there, after enlarging slightly, it divides into a wide, short right branch, and a longer and narrower left branch. The right branch receives the cystic vein and then enters the right

lobe of the liver. The left branch runs to the left along the porta, crosses the fossa for the umbilical vein, and enters the left lobe of the liver. As it crosses the umbilical fossa it is joined, anteriorly, by the ligamentum teres and some small para-umbilical veins, and, posteriorly, by the ligamentum venosum. In addition to its two main tributaries, viz., the superior mesenteric and the splenic veins, the vena portæ receives the coronary vein of the stomach and the right gastric vein. Occasionally the inferior mesenteric vein joins its commencement, instead of opening into the splenic vein. The cystic vein, as already stated, opens into its right branch. The small para-umbilical veins, which join the left branch, run along the ligamentum teres of the liver, and communicate, at the umbilicus, with the superficial veins of the abdominal wall.

**Vena Lienalis.** — The splenic vein commences by the union of a number of tributaries which issue from the hilum on the gastric surface of the spleen. It runs backwards through the lieno-renal ligament, and then passes to the right, to its union with the superior mesenteric vein between the neck and head of the pancreas. As it runs from left to right it lies behind the upper part of the posterior surface of the pancreas and in front of the left kidney, the left suprarenal gland, and the abdominal aorta, crossing the aorta between the origins of the cœliac and the superior mesenteric branches. It conveys blood not only from the spleen, but also from the stomach and the pancreas. The blood from the stomach is conveyed to it by the left gastro-epiploic and the short gastric veins, which join its commencing tributaries; and as it passes along the pancreas it receives tributaries from that gland.

*Dissection.* — Cut through the œsophagus immediately below the diaphragm; detach the stomach from the diaphragm by severing the gastro-phrenic ligament, and from the spleen by cutting through the remains of the gastro-splenic ligament and dividing the short gastric arteries and the left gastro-epiploic artery. Remove the separated portion of the stomach and examine its structure.

**Coats of the Stomach.**—The coats of the stomach are five in number, viz. :—

1. Peritoneal, or serous.
2. Subserous.
3. Muscular.
4. Submucous.
5. Mucous.

The *serous coat*, consisting of the peritoneal membrane, can be stripped off best by the fingers. The *subserous coat* is composed of a little areolar tissue which intervenes between the muscular and serous strata. The branches of the two vagi nerves can now be followed, as they spread out upon the two surfaces of the stomach.

The *muscular coat* consists of involuntary or unstriped muscular fibres, and these are disposed in three incomplete layers—each layer being distinguished by the direction of its fibres. The *stratum longitudinale* (O.T. external layer) is composed of fibres which run for the most part in the longitudinal direction. The longitudinal fibres of the œsophagus, on reaching the cardiac orifice, radiate over the stomach in all directions, but more particularly along the lesser curvature, and they disappear (with the exception, perhaps, of some on the lesser curvature) before they reach the pyloric part of the organ. On the body of the stomach a new and independent set of longitudinal fibres take origin, and these gradually form a continuous layer which gains in strength and thickness as it sweeps onwards towards the pylorus. The *stratum circulare* (O.T. middle layer) is composed of circular fibres, which are continuous with the more superficial circular fibres at the lower end of the œsophagus. They do not form a continuous coating for the stomach (Birmingham). Beginning as a series of loops immediately to the right of the œsophageal opening, they gradually increase in length as the layer is followed towards the pylorus, and soon they completely encircle the organ and form a continuous stratum. No fibres of this layer encircle the fundus. At the pylorus the circular

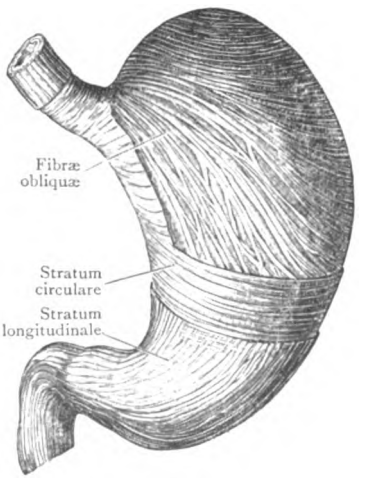


FIG. 194.—Dissection of the three layers of Muscular Fibres in the Wall of the Stomach.

fibres undergo a marked increase in number, and at the duodeno-pyloric constriction they are aggregated together into a thick circular ring, called the *pyloric sphincteric ring* (Fig. 196). The *fibræ obliquæ*, or fibres of the internal layer, are oblique fibres which give a partial covering to the stomach. They are continuous with the deeper circular fibres of the gullet, and are seen best immediately to the left of the cardiac opening. From this they spread out in a series of loops which embrace the œsophageal opening and proceed obliquely to the right over both surfaces of the viscus. As these muscular loops are traced towards the fundus, they gradually assume the form of a complete coating of circular fibres for this part of the organ (Birmingham).

The *submucous coat* is composed of lax areolar tissue. It intervenes between the muscular and mucous tunics, binding them loosely to each other and in such a manner that the mucous membrane can glide freely upon the internal surface of the muscular coat.

The *mucous coat* must be studied from the inside of the stomach. Open up the viscus by running the scissors along the lesser curvature. The gastric mucous membrane will now be seen to be thick, soft, and pulpy. In the dissecting-room the student cannot obtain a proper idea of its natural colour. In infancy it is rosy red, but as life advances it gradually becomes paler, and in old age it presents a brownish hue owing to the presence of pigment. When the mucous membrane is cleansed and examined with a pocket-lens, its surface is observed to present a pitted appearance. Innumerable polygonal depressions are brought into view, and these are larger and better marked near the pylorus than in the vicinity of the fundus. At the bottom of these pits are the mouths of the minute tubular glands of the gastric mucous membrane.

The mucous membrane has little elasticity, and, consequently, when the stomach contracts and becomes empty the membrane is thrown into projecting folds or rugæ which, for the most part, run in the longitudinal direction and occupy the cavity of the organ. As the stomach expands these folds open out, and finally they disappear when complete distension is attained.

*Dissection.*—Extend the incision already made in the second part of the duodenum upwards into the first part, to within a short distance of the

pyloric constriction, and examine the pyloric orifice and the pyloric canal. Then remove a segment of the wall of the first part of the duodenum, and dissect it to display its structure.

**Pyloric Orifice and Pyloric Canal.**—The extremity of the pyloric canal protrudes into the commencement of the duodenum, so that, when viewed from the duodenal side, it presents the appearance of a smooth, rounded knob, surrounded by a shallow furrow or fornix, and having a small puckered orifice, the *pyloric opening*, in its centre. Its resemblance to the external orifice of the uterus is very striking. When the stomach has been properly hardened *in situ* the pyloric orifice is almost invariably found tightly closed. It is only on rare occasions that the opening is patent. In such cases it is circular, and surrounded by a ring-like ledge

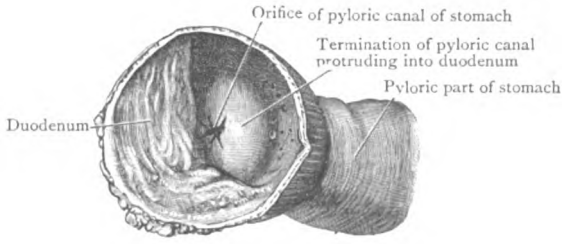
Orifice of pyloric canal of stomach
Termination of pyloric canal protruding into duodenum
Pyloric part of stomach
Duodenum

FIG. 195.—Small portion of the Pyloric part of the Stomach with part of the Duodenum attached.

which has been called the pyloric valve ; but it is doubtful if this is a natural condition. During life the pyloric opening may be regarded as being always rigidly closed, except during digestion, when it opens intermittently, and at irregular intervals, to allow material to be squirted from the stomach into the duodenum.

The muscular coat of the pyloric canal is modified to suit the requirements of this section of the stomach. It is provided with a powerful sphincteric apparatus. Both the circular and longitudinal muscular fibres are present in greater mass than in any other part of the organ. The circular fibres are disposed in the form of a thick sphincteric muscular cylinder which surrounds the entire length of the pyloric canal. At the duodeno-pyloric constriction the margin of this cylinder becomes increased in thickness, forming thereby the massive muscular ring which encircles the pyloric orifice and con-

stitutes the *pyloric sphincteric ring.* The knob-like appearance presented by the extremity of the pyloric canal, when viewed from the interior of the duodenum, is produced by the presence, beneath the mucous membrane, of this muscular ring. The sphincteric cylinder which surrounds the pyloric canal varies much in its thickness in accordance with different degrees of contraction of the canal.

The longitudinal muscle-fibres likewise form a thick layer on the superficial aspect of the sphincteric cylinder and ring. They are uniformly disposed around the pyloric canal, but

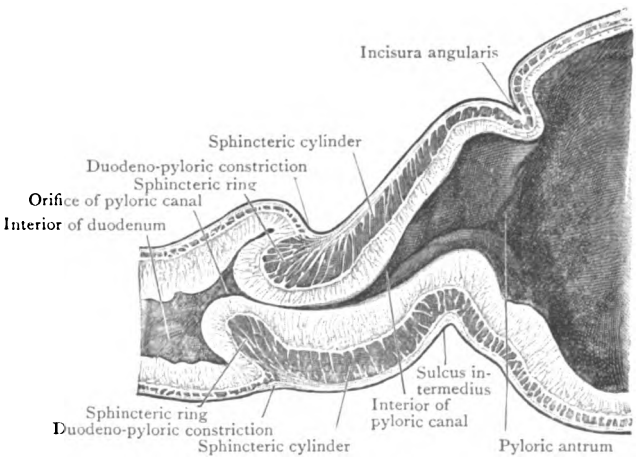


FIG. 196.—Pyloric Canal and Pyloric Antrum of the Stomach opened up by section in the plane of the two curvatures.

comparatively few of these fibres pass superficially over the duodeno-pyloric constriction to become continuous with the corresponding fibres of the muscular coat of the duodenum. As they approach the duodenum the deeper longitudinal fibres of the pyloric canal leave the surface and penetrate the substance of the pyloric sphincteric ring. There can be little doubt that by this arrangement an effective apparatus, antagonistic to the pyloric sphincteric ring, is provided, by means of which, when the sphincter relaxes, the pyloric orifice may be dilated. There is thus a constrictor and a dilatator of the pylorus.

In suitable specimens this arrangement of the muscle

fibres may be seen by the naked eye when a longitudinal section is made through the pyloric canal in the plane of the two curvatures of the stomach (Fig. 196).

**Coats of the Duodenum.**—In connection with the duodenum, note that the plicæ circulares begin about the commencement of its second part one or two inches beyond the pylorus; that the mucous membrane is covered with villi; and that no solitary lymph nodules are to be seen.

A segment of the wall of the first part of the duodenum should now be pinned down, with its mucous surface undermost, to the bottom of a cork-lined tray filled with water. Its coats may then be dissected. They are in all respects similar to those already examined in connection with the jejunum (p. 485). If the dissection is carried on until the deep surface of the submucous coat is exposed by the removal of the entire muscular coat, a view of the duodenal glands may be obtained. They appear as whitish specks, about the size of hemp-seed, in the submucous tissue. They are most numerous close to the pylorus, and gradually disappear about two inches beyond this.

**Lien (Spleen).**—The spleen is a solid organ which lies deeply in the left part of the costal zone, and is altogether out of sight in the undisturbed condition of the viscera, but it is exposed when the stomach is removed. It lies very obliquely in the abdominal cavity, its upper end being much nearer the median plane and much further back than its lower end. Its long axis is directed from above downwards and laterally, and also to some extent forwards. For the most part it lies in the left hypochondrium, but its upper end extends medially beyond the left lateral plane, so that fully a third of the organ is situated in the epigastric region.

The spleen, when properly hardened *in situ*, has the shape of an irregular tetrahedron. The *upper extremity* is curved forwards on itself to some extent, and approaches close to the left suprarenal gland.

Of the four surfaces the most extensive is the *diaphragmatic*, which is convex and looks backwards and laterally. It rests upon the posterior part of the diaphragm, to the curvature of which it is adapted, and it is separated by the diaphragm from the ninth, tenth, and eleventh ribs. It is necessary to remember also that the pleura descends between this portion of the chest wall and the diaphragm, and comes to lie superficial to the greater part of the diaphragmatic surface of the spleen. The thin basal margin of the lung, which occupies the upper part of the pleural

recess, likewise intervenes between the upper part of the spleen and the surface of the body.

The remaining three surfaces are turned towards the cavity of the abdomen, and are closely applied to the viscera which support the organ in its place. These three surfaces, which may be grouped together under the one term "*visceral*," are separated from each other by three ridges which radiate from a blunt and often inconspicuous prominence which may be termed the *intermediate angle*, and represents the apex of the tetrahedron. One of these ridges, a salient and prominent

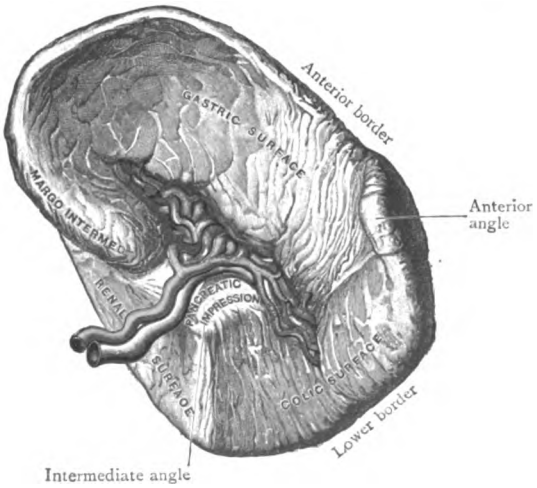


FIG. 197.—The Spleen (visceral aspect).

border (margo intermedius), ascends to the upper end of the spleen and separates an extensive, anterior gastric area from a narrower, posterior renal area; a second short ridge or border passes backwards to the *posterior angle* and intervenes between the renal and the colic surfaces; whilst the third ridge, less distinctly marked, proceeds forwards to the *anterior angle* and separates the gastric and the colic surfaces from each other. The term colic surface is applied to a triangular area which is bounded by the two last-named ridges, together with the lower border of the organ.

The *gastric surface* is the most extensive of the three visceral districts. It is deeply concave and moulded upon

the fundus of the stomach. Within its area, and about an inch in front of the margo intermedius there is a longitudinal slit, the *hilum lienis*, frequently broken up into two or more pieces. This gives passage to the vessels and nerves which enter and leave the organ. Behind the hilum and immediately in front of the intermediate angle, there is a *pancreatic impression*, of variable extent and depth, into which the tail of the pancreas is received.

The *renal surface* is concave, and varies somewhat in its extent. It is applied to the anterior surface of the upper part of the kidney, close to its lateral border.

The peritoneal relations of the spleen are such that the renal surface cannot be studied unless the posterior border of the organ is pulled forwards, and the fingers are passed behind it (see p. 435). The gastro-splenic and lieno-renal ligaments, which connect it with the stomach and left kidney respectively, are attached to the margin of its hilum.

The *colic surface* is smaller than the other two visceral areas. It is triangular in form, and looks downwards and medially. It is in contact with the left colic flexure and the phrenico-colic ligament.

Of the several borders which separate the different surfaces of the spleen from each other, the anterior, the inferior, and the posterior are the most prominent and conspicuous. The *anterior border* is notched or crenated, and intervenes between the diaphragmatic surface and the gastric surface. The *inferior border* separates the diaphragmatic surface from the colic surface; whilst the *posterior border* intervenes between the renal and diaphragmatic surfaces. The margins which separate the visceral areas radiate from the intermediate angle, and have been noticed already.

The anterior angle is the most prominent and the most anteriorly placed part of the spleen.

The form of the spleen varies very greatly with the varying degrees of distention of the hollow viscera which are related to its visceral aspect. There is good reason to believe that the tetrahedral form which is described above is associated with an empty or only slightly distended stomach and a well-distended intestine. When, however, the stomach is distended and the intestine is more or less empty, the basal surface partially or even entirely disappears, and then the spleen assumes a form similar to that of the segment of an orange (Shepherd).

**Structure of the Spleen.**—As the spleen will be required when the relations of the left kidney are studied, the dissector should obtain a sheep's spleen for the purpose of studying the structure of the organ. He will find that it is enveloped by two coats—(1) serous; (2) fibro-elastic.

The *peritoneal investment* adheres so closely to the subjacent fibrous coat that it can be removed only with difficulty. With regard to the *fibro-elastic tunic* (tunica propria), it should be noted that processes proceed from its deep surface and dip into the substance of the organ. These are the *trabeculæ*, and they constitute the supporting framework of the *gland-pulp*. On account of this arrangement, it will be found impossible to strip off the fibrous coat of the spleen without at the same time lacerating its surface. Make a section through the organ, and carry a portion of it to the tap. By squeezing it and allowing the water to run freely over it, a view of the trabecular framework may be obtained.

*Dissection.*—The sympathetic plexuses in the upper part of the abdomen may now be studied with advantage. Throw the tail and body of the pancreas and the first part of the duodenum over to the right. Next, turn to the left cœliac ganglion, which was displayed when the posterior wall of the omental bursa was removed, lying between the left border of the cœliac artery and the medial border of the left suprarenal gland (see p. 460). From the medial border of the left cœliac ganglion trace sympathetic nerve fibres across the front of the aorta, round the root of the cœliac artery, to the opposite ganglion, which lies behind the inferior vena cava. To expose the right cœliac ganglion, therefore, it is necessary to displace to the right the portion of the inferior vena cava which lies behind the first part of the duodenum and to fix it out of the way with hooks or pins. Follow each cœliac ganglion upwards and backwards to its union with the greater splanchnic nerve of the same side, and follow the splanchnic nerve to the point where it passes into the abdomen by piercing the crus of the diaphragm of the corresponding side.

**Sympathetic Plexuses.**—In connection with the sympathetic nervous system three large plexuses are formed in front of the vertebral column: they are the cardiac plexus, in the thorax; the cœliac plexus, in the upper part of the abdomen proper; and the hypogastric plexus, in the lower part of the abdomen proper.

*The cœliac plexus* (O.T. *solar plexus*), which is by far the largest of the three, consists of the two cœliac (O.T. semilunar) ganglia and the numerous nerve bundles which connect the ganglia together.

It lies at the level of the lower part of the last thoracic and the upper part of the first lumbar vertebra, in front of the crura of the diaphragm and the uppermost part of the abdominal portion of the aorta, between the medial margins of the suprarenal glands, and around the cœliac artery. Numerous offshoots arise from it and pass either along the adjacent arteries, or to the suprarenal glands and the kidneys; these constitute secondary plexuses.

*Ganglia Cœliaca* (O.T. *Semilunar Ganglia*).—The cœliac ganglia are of irregular shape, and they are so large that they are frequently mistaken by students for lymph glands.

The upper extremity of each ganglion is joined by the great splanchnic nerve of the same side, whilst the lower part, which is often more or less detached, is connected with the lesser splanchnic nerve.

**Plexus Gastricus Superior.**—The superior gastric plexus springs from the front of the cœliac plexus. It accompanies the left gastric artery to the lesser curvature of the stomach and distributes twigs to both surfaces of the viscus.

**Plexus Hepaticus.**—The hepatic plexus also springs from the front of the central part of the cœliac plexus. It is joined by twigs from the left vagus nerve, and accompanies the hepatic artery, the portal vein, and the bile-duct, to the liver. At the lower margin of the lesser omentum, it gives off twigs which accompany the gastro-duodenal artery and its right gastro-epiploic branch; these constitute the *inferior gastric plexus.*

**Plexus Lienalis.**—The splenic plexus, like the superior gastric and the hepatic plexuses, springs from the median and anterior part of the cœliac plexus. It accompanies the splenic artery to the spleen, and is joined by twigs from the right vagus nerve. It gives offshoots along the various branches of the artery.

**Plexus Renalis.**—Each renal plexus consists of numerous nerves which spring chiefly from the medial and lateral part of the corresponding cœliac ganglion. Some will be found, however, coming from the strands of the cœliac plexus and others from the aortic plexus. The *lowest* or *third splanchnic nerve*, when it is present, joins this plexus. Thus constituted, the filaments of the renal plexus run with the renal artery to the hilum of the kidney, and are distributed within the gland substance. Several twigs are given also to the spermatic plexus. A few scattered ganglia are usually found in connection with the renal plexus.

**Plexus Suprarenalis.**—The dissector will be struck with the large number of nerves which supply the suprarenal glands. They are derived chiefly from the cœliac ganglion of the same side, but many come from the strands of the cœliac plexus. Below, each suprarenal plexus is directly continuous with the renal plexus, and above, it is connected with the diaphragmatic plexus. The lowest splanchnic nerve usually contributes a branch to this plexus, and the point at which it joins is marked by a small ganglion.

**Plexus Phrenicus.**—The filaments composing each phrenic plexus take origin from the upper part of the cœliac ganglion of the same side, and are distributed with the inferior phrenic artery to the inferior surface of the diaphragm, but they do not follow rigorously the branches of this vessel. At first they lie subjacent to the peritoneum, but soon they penetrate between the fleshy fasciculi and establish communications with the phrenic nerve. On the right side a small ganglion is formed on the inferior surface of the diaphragm at the point of junction between this plexus and the phrenic. In addition to its diaphragmatic branches the phrenic plexus contributes filaments to the suprarenal plexus, and, on the right side, to the hepatic plexus.

**Plexus Mesentericus Superior.**—The superior mesenteric plexus springs from the lower part of the central portion of the cœliac plexus and descends, with the superior mesenteric artery, in the root of the mesentery of the small intestine. It sends offsets along the branches of the artery.

**Plexus Aorticus Abdominalis.**—The abdominal aortic plexus is formed mainly by branches derived from the ganglia of the abdominal parts of the sympathetic trunks, but it is connected, above, with the cœliac and superior

mesenteric plexuses, and, below, branches which issue from it are prolonged downwards across the fronts of the common iliac arteries into the hypogastric plexus.

**Plexus Spermaticus.**—Each spermatic plexus receives filaments from the aortic plexus and from the renal plexus of the same side. It accompanies the corresponding internal spermatic artery and gives branches to the ureter as well as to the testis. In the female the corresponding plexus is called the *ovarian plexus* and accompanies the ovarian vessels.

**Plexus Mesentericus Inferior.**—The inferior mesenteric springs from the aortic plexus. It accompanies the inferior mesenteric artery and gives secondary offshoots along the branches of the artery.

**Removal of the Spleen, Pancreas, and Duodenum.**—The dissector should now proceed to the removal of the spleen, the pancreas, and the duodenum, which should be kept together and preserved, so that they can be replaced in position when the relations of the kidneys are being studied.

Cut through—(1) the splenic artery, about three-quarters of an inch from its origin from the coeliac trunk; (2) the portal vein, about one inch above the union of the superior mesenteric and splenic veins; (3) the superior mesenteric artery, half an inch below its origin from the aorta; (4) the gastro-duodenal branch of the hepatic artery. Fix the splenic vein to the posterior surface of the pancreas with a few stitches. Pull the spleen over towards the right side and cut through the left layer of the lieno-renal ligament, which is still in position; then remove the spleen, the pancreas, and the duodenum from the abdomen.

**Removal of the Liver.**—The general position and connections of the liver have been considered, and the left lobe has been detached and laid aside (see p. 444). The right lobe must now be separated from the parts of which it is connected. Strip the peritoneum from the anterior surface in the inferior vena cava, from the point where it was exposed by the removal of the first part of the duodenum to the point where it disappears into the fossa venæ cavæ on the posterior surface of the liver. Raise the liver as much as possible, and, to the right of the inferior vena cava, cut through the layer of the peritoneum which is reflected from the lower part of the posterior surface of the liver to the diaphragm. This layer is the *lower layer of the coronary ligament*. At the base of the liver the lower layer of the coronary ligament becomes continuous with the right triangular ligament which must also be divided. After the right triangular ligament is divided, pull the liver downwards as far as possible, and cut through the falciform ligament, which connects the anterior and superior surfaces of the liver to the anterior abdominal wall and to the diaphragm. Divide this ligament from before backwards, and note, as its posterior extremity is approached, that its right lateral layer becomes continuous with the *upper layer of the coronary ligament*, which passes from the posterior border of the upper surface of the liver to the diaphragm. Divide this layer from right to left, and be careful not to injure the upper part of the abdominal portion of the inferior vena cava, which lies immediately behind it, a little to the right of the line of attachment of the falciform ligament. Now, with the right hand, pull the right lobe of the liver forwards and to the left, detaching its posterior surface from the diaphragm with the fingers of the left hand, until the right border of the fossa for the inferior vena cava is reached; then separate the vena cava from the fossa, with the fingers, from below upwards, until the large hepatic veins are reached as they pass out of the upper part of the posterior surface of the liver into the anterior wall of the inferior vena cava, immediately below the diaphragm. Divide these veins carefully with the knife and remove the right lobe of the liver from the abdomen.

After the right lobe of the liver has been removed from the abdomen, attach the left lobe to it with long pins, and study the various surfaces and parts of the gland with the utmost care.

**The Surfaces of the Liver.**—The anterior surface, and the base or right lateral surface, are smooth, convex, and covered with peritoneum. They are separated from each other by a rounded and indistinct border.

**The Base** is in relation with the right part of the diaphragm, from the level of the seventh to the level of the eleventh rib,

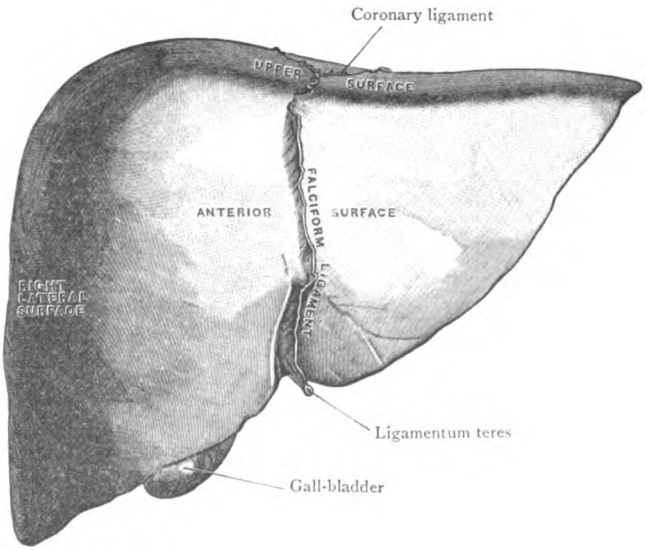


FIG. 198.—Anterior Surface of the Liver.

in the mid-axillary line; and it is separated by the diaphragm from the lower part of the right pleural sac and right lung.

**The Anterior Surface** is in relation with the anterior part of the diaphragm, on each side of the sub-costal angle, and, opposite the sub-costal angle, with the posterior surfaces of the sheaths of the recti muscles; and the lower border of the falciform ligament is attached to it nearer to its left than to its right extremity.

**The Superior Surface** also is smooth and covered with peritoneum. On the right and on the left, where it fits into the corresponding cupolæ of the diaphragm, and is separated

by the diaphragm from the lungs and pleural sacs, it is convex, and more convex on the right side than on the left. In the intermediate area, where the diaphragm separates it from the pericardium and the heart, it is slightly concave, and running antero-posteriorly across the depressed area is the line of attachment of the falciform ligament, which separates the upper surface of the right lobe from the upper surface of the left lobe. The line of attachment of the falciform ligament to the upper surface terminates, posteriorly,

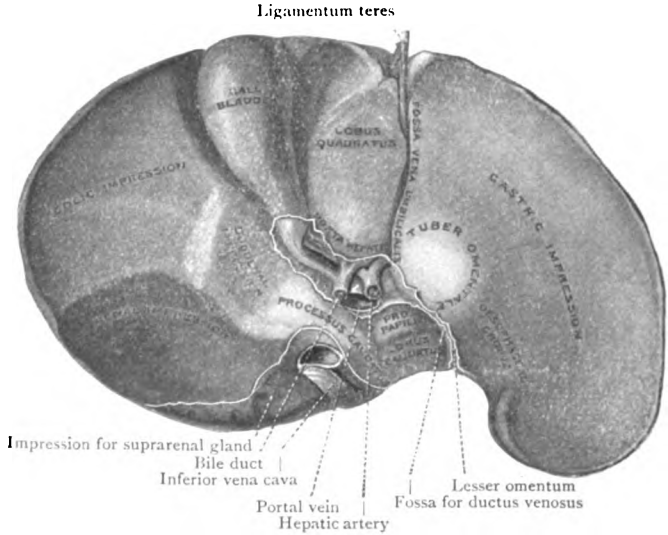


FIG. 199.—The Inferior or Visceral Surface of the Liver.

at the upper end of the fossa for the ductus venosus, and from that point the line of attachment of the left triangular ligament extends to the left, on the posterior part of the upper surface of the left lobe. A short distance to the right of the posterior end of the line of attachment of the falciform ligament, the posterior border of the upper surface is notched by the upper end of the fossa for the inferior vena cava. The portion of the posterior border of the upper surface which lies between the upper ends of the fossa for the ductus venosus and the fossa for the inferior vena cava is the upper end of the caudate lobe.

*The inferior* and *posterior surfaces* are each divided into segments by a right and a left pair of fossæ, which run parallel with the sagittal plane. The left pair of sagittal fossæ, which separate the lower and the posterior surfaces into right and left lobes, are the *fossa for the umbilical vein*, on the inferior surface, and the *fossa for the ductus venosus*, on the posterior surface. The right pair of sagittal fossæ, which segment the lower and posterior surfaces of the right lobe, are the *fossa for the gall-bladder*, on the lower surface and the *fossa for the inferior vena cava*, on the posterior surface.

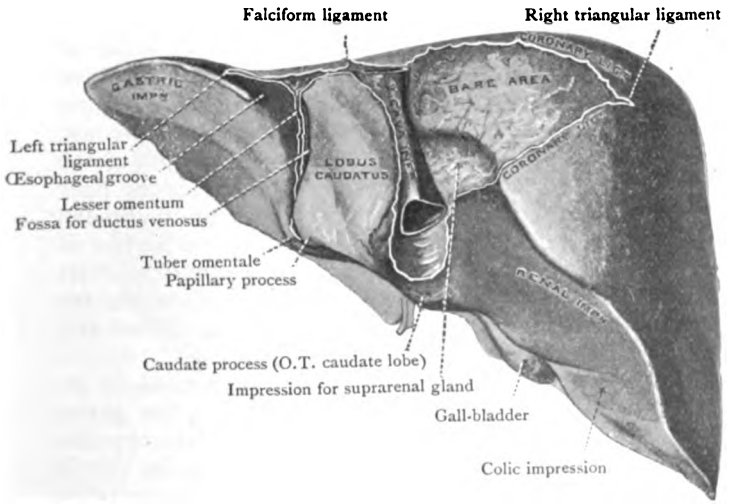


FIG. 200.—Posterior Surface of the Liver.

**The Inferior Surface of the Liver** looks downwards and backwards, and rests either upon viscera situated at a lower level in the abdomen or upon the front of the lesser omentum. It is separated into a larger right and a smaller left segment or lobe by the fossa for the umbilical vein. On the inferior surface of the right lobe, close to its posterior border and at its left extremity, is the *porta hepatis* or hilum of the liver, through which the hepatic artery and the portal vein pass into the liver, and the hepatic-ducts and the lymph vessels pass out. It connects the posterior part of the fossa for the umbilical vein with the posterior part of the fossa for the gall-bladder.

The portion of the right lobe which lies in front of the porta, and between the fossa for the gall-bladder on the right and the fossa for the umbilical vein on the left, is the quadrate lobe, which frequently bears impressions made by the pylorus and the first part of the duodenum. Behind the porta hepatis, and between the lower ends of the fossa for the ductus venosus and the fossa for the inferior vena cava, is the lower end of the caudate lobe, which is usually divided, by a shallow sulcus, into a nodular left or *papillary process*, which projects downwards into the cavity of the omental bursa, and a right, band-like or *caudate process*, which connects the lower end of the caudate lobe with the main part of the inferior surface of the right lobe. The remainder of the inferior surface of the right lobe is marked by three shallow impressions: (1) at the right extremity of the porta hepatis is an antero-posterior sulcus, the *duodenal impression*, for the second part of the duodenum; (2) to the right of the fossa for the gall-bladder is the *colic impression*, for the right flexure of the colon; (3) behind the colic impression is the *renal impression*, for the upper part of the anterior surface of the right kidney. Occasionally a fourth impression exists behind the duodenal impression; this is the *suprarenal impression*, which is always present on the posterior surface and may extend on to the inferior surface.

The inferior surface of the left lobe is marked by an elevation, the *tuber omentale*, and a depression, the *gastric impression*. The tuber omentale lies immediately opposite the left extremity of the porta hepatis and, when the liver is in position, it rests against the lesser omentum, immediately above the lesser curvature of the stomach. The gastric impression occupies the remainder of the lower surface of the left lobe lying in front and to the left of the tuber omentale.

**The Posterior Surface of the Liver** (Figs. 200 and 201).—This is moulded upon the front of the vertebral column, from which it is separated by the diaphragm and the lower part of the descending thoracic aorta. It presents, therefore, a deep hollow corresponding to the bodies of the vertebræ and the structures in front of them. Immediately to the left of the fossa of the ductus venosus there is a smooth notch or groove, the *œsophageal impression* which leads downwards into the gastric impression on the under surface of the left lobe. This groove lies anterior to the œsophagus. Beyond the œsophageal

groove the posterior surface of the left lobe merges with the sharp margin of the organ.

It has been pointed out that the œsophageal groove in the liver is usually occupied by the prominent anterior margin of the œsophageal opening of the diaphragm, which, in the first instance, must be regarded as being responsible for the depression (Birmingham).

On the posterior surface of the right lobe there may be recognised—(1) the lobus caudatus (O.T. lobus Spigelii);

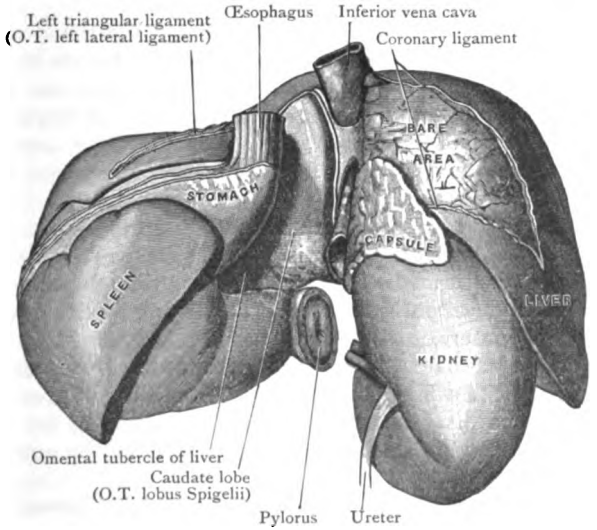


FIG. 201.—Liver, Right Kidney, Spleen, and Stomach, as seen from behind. Drawing made from a model prepared by the reconstruction method.

(2) the fossa for the inferior vena cava; and (3) an extensive "bare area" devoid of peritoneum.

The *lobus caudatus* (O.T. *lobus Spigelii*) is the portion of liver substance which lies between the fossa of the ductus venosus and the fossa of the inferior vena cava. Its lower end appears on the inferior surface of the liver immediately behind the porta hepatis. It is divided into the papillary process, on the left, and the caudate process, on the right (Fig. 200). The caudate lobe forms the bottom of the vertebral hollow, and is separated from the bodies of the tenth, eleventh, and twelfth thoracic vertebræ by the diaphragm and the lower part of the descending thoracic aorta.

*Fossa Venæ Cavæ.*—The *fossa for the inferior vena cava* is a deep groove placed on the right side of the caudate lobe. It ascends almost perpendicularly, and sometimes it is converted into a tunnel by a bridge of liver substance which passes over the vein from the one side to the other.

The *bare area* of the posterior surface of the liver is triangular in form, and lies to the right of the fossa for the vena cava. It forms the greater part of the posterior surface of the right lobe, and is bounded above and below by the lines of reflection of the coronary ligament. For the most part it is convex, and it is connected with the diaphragm by loose areolar tissue, and some minute veins which unite the portal vessels of the liver with the systemic vessels of the diaphragm; but close to the lower end of the fossa for the vena cava there is a well-marked depression, the *suprarenal impression* which lodges the upper part of the right suprarenal gland.

**Porta Hepatis** (O.T. **Transverse Fissure**).—The porta hepatis, or hilum of the liver, is the cleft on the posterior part of the lower surface of the right lobe through which the vessels and ducts enter and leave the liver. It lies near the posterior border of the lower surface, between the lower end of the caudate lobe posteriorly and the quadrate lobe anteriorly, extending, transversely, from the upper and posterior end of the fossa for the gall-bladder, on the right, to the upper and posterior end of the fossa for the umbilical vein, on the left.

In the upper part of the lesser omentum, immediately below the porta, the bile-duct, the hepatic artery, and the portal vein are in close relation to each other, the artery lying to the left, the duct to the right, and the portal vein behind and between them. The branches of the three structures enter the porta in the same relative positions, and, as they pass into it, they become enclosed in a sheath of the fibrous capsule of the liver (O.T. Glisson's capsule). Trace them for a short distance into the substance of the liver and note that the portal vein branches like an artery, and wherever it divides, there also will the hepatic artery and hepatic duct be found to divide. The branches of these three structures, therefore, traverse the liver substance in company, and the fibrous capsule is prolonged into the liver with them, and follows them in their ramifications. The student is now in a position to understand the meaning of the term "*portal*

*canal.*" It is employed to denote a channel in the liver substance, lined by a prolongation of the fibrous capsule, and holding in its interior a branch of the portal vein, a branch of the hepatic artery, and a branch of the hepatic duct.

**Vessels of the Liver.**—Blood enters the liver—(1) by the *hepatic artery*, (2) by the *portal vein*; whilst it is led away from the liver by the *hepatic veins.*

The *hepatic artery* is a branch of the cœliac artery. It carries arterial blood for the nourishment of the liver substance and divides into two branches which enter the liver at the extremities of the porta hepatis (p. 462).

The *portal vein* carries venous blood which it has gathered from the spleen, pancreas, and gall-bladder, and from the entire length of the abdominal portion of the alimentary canal (with the exception of the anal canal of the rectum). It reaches the inferior surface of the liver at the right extremity of the porta hepatis, where it divides into its two terminal branches. The terminal part of the portal vein, just before it divides, is slightly expanded, forming the *sinus of the portal vein.* The *right branch* is a short wide vessel which immediately sinks into the liver; the *left branch*, much longer and considerably smaller, extends to the left along the bottom of the porta hepatis, and at the left extremity of that furrow it crosses the fossa for the umbilical vein and enters the liver substance. As it crosses the fossa for the umbilical vein the coats of the left branch of the portal vein are joined in front by the ligamentum teres, whilst behind it has attached to it also the ligamentum venosum.

The *hepatic veins*, which lead the blood out of the liver, have an arrangement altogether different from the vessels which enter at the porta hepatis. They converge towards the fossa for the vena cava, on the posterior surface of the liver, and cannot be said to have any course outside the liver, as they open at once into the vena cava inferior. Their gaping mouths will be found at the upper end of the fossa for the vena cava. Trace these veins for a short distance into the substance of the gland. They are remarkable for the tenuity of their walls, and also for the very small quantity of areolar tissue which separates them from the hepatic substance; indeed, this is so scarce that it is hardly appreciable to the naked eye. In the case of the smaller veins it is

altogether absent, and the hepatic lobules rest directly upon their walls.

A section should now be made through the liver substance and the cut surface examined. The portal veins can be readily distinguished from the hepatic veins. The following are the points of difference:—

| Portal Veins. | Hepatic Veins. |
|---|---|
| 1. Are always accompanied by a branch of the duct and a branch of the hepatic artery. | 1. Are solitary and not accompanied by any other vessel. |
| 2. Mouths usually collapsed. | 2. Mouths usually open and gaping. |
| 3. Walls thicker. | 3. Walls exceedingly thin. |
| 4. Walls separated from the liver substance by the fibrous capsule. | 4. Walls apparently in direct apposition with the liver substance. |

**Structure of the Liver.**—Very little of the structure of the liver can be learned in the dissecting-room. It is completely enveloped by a fibrous capsule (O.T.Glisson's). This is thick where the peritoneum is absent, but very thin where that membrane is spread over the gland. The liver substance presents a mottled appearance, and when torn or ruptured the surface exhibits a granular aspect. The minute particles which give rise to this appearance are the hepatic lobules. In the human liver these are not completely separated from each other. Each lobule may be regarded as a miniature liver; they are all built up of the same constituents, but these can be made out only by the aid of the microscope.

**Glandulæ Suprarenales** (O.T. **Suprarenal Bodies or Capsules**).—The suprarenal glands are two small, flattened bodies, each of which is placed upon the upper end of the corresponding kidney. They surmount the kidney after the fashion of a helmet, and are prolonged downwards for a short distance upon its anterior surface and its medial border. The suprarenal glands lie in the epigastric region, and rest upon the diaphragm.

**The Right Suprarenal Gland** is, as a rule, triangular in form, and rests, by its base, upon the anterior and medial aspect of the upper end of the right kidney. It is placed between the posterior surface of the right lobe of the liver and that portion of the diaphragm which covers the side of the vertebral column.

The *anterior surface*, which looks laterally as well as forwards, presents two impressions—(1) The one is a narrow

flattened strip, adjoining the anterior border of the gland, and is overlapped by the inferior vena cava; (2) the second impression comprises the remainder of the anterior surface, and is in contact with the liver. Only a small and variable part of the lower portion of the anterior surface of the right suprarenal gland is covered with peritoneum. On the upper part of the impression for the vena cava, not far from the apex of the gland, a short fissure, termed the *hilum*, may be observed. From it issues a short wide vein which immediately enters the inferior vena cava. The *posterior surface* of the right suprarenal gland is divided by a salient, curved ridge into an upper, flat part, which is applied to the diaphragm, and a concave, lower part, which is occupied by fat and rests upon the kidney.

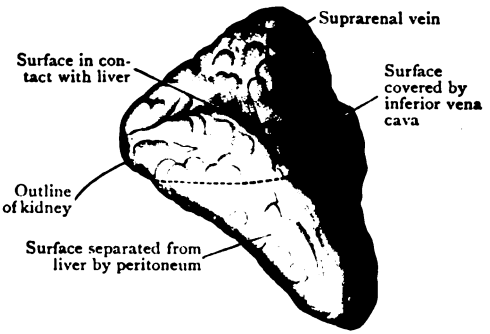
Suprarenal vein
Surface in contact with liver
Surface covered by inferior vena cava
Outline of kidney
Surface separated from liver by peritoneum

FIG. 202.—Anterior Surface of Right Suprarenal Gland.

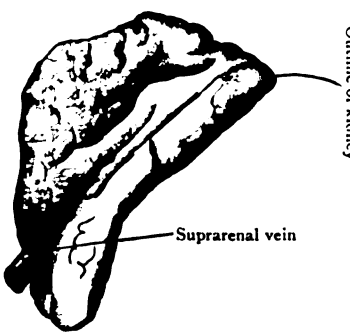


FIG. 203.—Anterior Surface of Left Suprarenal Gland.

**The Left Suprarenal Gland** is semilunar in form, and, as a rule, is slightly larger than the right. Its position on the kidney is also somewhat different. It is usually placed on its medial border immediately above the hilum.

The *anterior surface* presents, not far from its lower end, a very obvious *hilum* with a large emerging vein. The greater part of this surface is separated from the postero-inferior surface of the stomach by the posterior wall and the cavity of the

omental bursa, and it forms a portion of the stomach bed. The lower portion of the anterior surface is covered by the pancreas and crossed by the splenic vessels, and is not in relation to the peritoneum. Occasionally the spleen extends so far medially that it lies in relation to the upper part of the anterior surface of the left suprarenal gland, but that condition is rare. The *posterior surface* is subdivided into two areas by a curved ridge, as on the right side. The upper area is flat, and applied to the left crus of the diaphragm; the lower area is hollowed out and is in relation to the kidney, a considerable amount of fat intervening.

The student has already observed the abundant nerve supply to the suprarenal glands from the cœliac plexus. Their blood supply is equally rich. No fewer than three arteries enter the substance of each, viz.—the *superior*, *middle*, and *inferior suprarenal arteries*.

When a section is made through the suprarenal gland it is seen to consist of an external, firm portion, termed the *cortex*, and of a soft, pulpy, dark-coloured internal substance, called the *medullary part*.

**Renes (Kidneys).**—The kidneys are situated behind the peritoneum, against the posterior wall of the abdomen—one on each side of the vertebral column. They are enveloped by a capsule of loose areolar tissue, the meshes of which are, at certain points, loaded with soft, pliable fat. Take this away, and be careful to preserve the *suprarenal gland*, which lies upon the upper end of each kidney.

Each *kidney* is placed opposite the bodies of the last thoracic and the upper three lumbar vertebræ. It extends from the upper border of the last thoracic vertebra to the middle of the body of the third lumbar vertebra; and it lies obliquely—its upper end being somewhat nearer the median plane than its lower end. The kidneys lie for the most part in the hypochondriac and epigastric regions. As a rule the left kidney is confined entirely to those districts; but the right kidney, which generally occupies a slightly lower level, crosses the subcostal plane, and a small portion of its inferior extremity lies in the right lumbar and the adjoining part of the umbilical region. The difference between the two sides is probably due to the great bulk of the right lobe of the liver. On each side the twelfth rib lies behind the kidney, and the right kidney does not, as a rule, extend beyond the upper border of that rib, but the left kidney may reach the lower border of the eleventh rib. The lower end of each kidney is separated by a short, but variable interval from the crest of the ilium.

The average length of a kidney is four inches ; its breadth, two and a half inches ; and its average weight is four and a half ounces in the male, but somewhat less in the female. It is a solid organ, very pliable, and of a brownish-red colour. The left kidney is, as a rule, slightly longer and narrower than the right kidney.

**Form of the Kidney.**—This is so characteristic that the term "reniform," or "kidney-shaped," has become common in descriptive language. The *anterior surface* looks laterally and forwards, and presents impressions corresponding to the viscera in contact with it ; whilst the *posterior surface* is directed medially and backwards, and is moulded accurately upon the parts which support it. The *extremities* are rounded, and the superior end is usually thicker and more massive than the inferior. The *lateral border*, smooth and convex, is directed backwards and laterally ; whilst the *medial border* is concave, and looks medially and forwards. The true form of the kidneys can be seen only in cases where they have been carefully hardened *in situ*.

The kidneys present many changes in form, according to the amount and the kind of pressure which is exerted upon them by contiguous viscera. In most cases, however, and on both sides, there is on the anterior surface of the organ a point of maximum convexity—a place where the kidney substance is raised in the form of a marked prominence or bulging. Above and below this eminence the anterior surface falls away towards each extremity, in the form of an inclined or sloping plane of greater or less obliquity. These impressed districts indicate pressure exercised on the anterior surface of the kidney in two directions, and the intervening eminence is the result of this pressure and counterpressure. This characteristic is more constant and better marked in the case of the left kidney.

Upon the upper inclined plane of the anterior surface of the *left kidney* are placed the left suprarenal gland, the stomach, the spleen, and the pancreas. These exercise a downward and backward pressure, chiefly through changes in the condition of the stomach. Upon the inferior inclined plane of the left kidney the counterpressure is produced by the intestinal canal, which, as a rule, presses upwards and backwards.

Resting upon the upper inclined plane of the *right kidney* is the liver, whilst in contact with the lower inclined area is the colon. The colon presses on the kidney in an upward and backward direction. To this pressure the liver offers a passive resistance, except perhaps in the case of the slight influence which it conveys in a downward direction from the

diaphragm, and in a backward direction from the anterior abdominal wall.

This pressure and counterpressure, which produce so marked a conformation of the anterior surface of each kidney, must exercise also an important influence in maintaining the organ in its place, and securing it in that part of the abdominal cavity in which it lies. Still, it is doubtful if these influences have so potent an effect on the right as on the left side. The right kidney is embedded to a greater or less extent in the liver, and this no doubt exerts an influence in fixing the organ in position.

Ligaments fixing the kidney to the abdominal wall are described, and it is easy to demonstrate that the extra-peritoneal tissue in which it lies becomes condensed in the regions above and below into indefinite ligamentous lamellæ, but it is doubtful if these can have much effect in maintaining the kidney in its place.

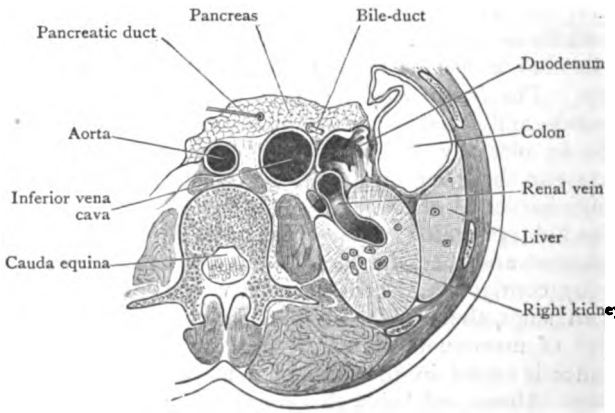


FIG. 204.—Section through Abdomen at the level of the second lumbar vertebra.

**Hilum of the Kidney.**—The medial border of each kidney presents a longitudinal fissure called the *hilum*, for the admission and egress of the vessels, nerves, lymph vessels, and duct (Fig. 209). This is bounded anteriorly and posteriorly by thick lips, and leads into a deep recess or cavity in the kidney, which is termed the *renal sinus*. The ureter and the renal vessels pass between the lips of the hilum. They will be found to have the following general relations from before backwards: (1) branches of the renal vein; (2) branches of the renal artery; (3) ureter or renal duct.

**Anterior Surface of the Right Kidney.** — The anterior surface of the right kidney may present three impressions, viz., a hepatic, a colic, and a duodenal. The *hepatic impression*,

which indicates the area of contact with the inferior surface of the right lobe of the liver, occupies almost the whole of the upper two-thirds of the anterior surface, and corresponds to the upper inclined plane. Over that district the kidney is sometimes sunk deeply into the liver. The right suprarenal gland, which rests, as a rule, on the upper extremity of the right kidney, extends downwards, for a very short distance, on the anterior surface of the organ, between it and the liver. With the exception of this narrow strip immediately adjoining the

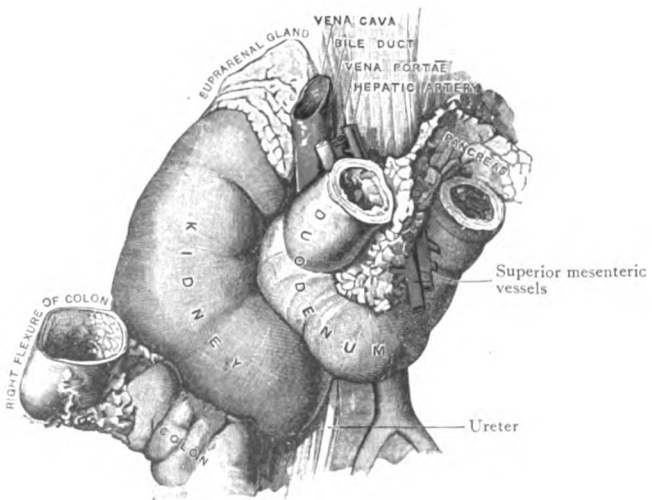


FIG. 205.—Right Kidney and Duodenum.

superior extremity, the hepatic impression on the anterior surface of the kidney is covered with peritoneum. The *colic impression* corresponds to the inferior inclined plane, and sometimes it exhibits a marked degree of obliquity. The right colic flexure and the commencement of the transverse colon are in contact with this area. The posterior surfaces of these portions of large intestine are devoid of peritoneum, and are bound to the kidney by areolar tissue. The *duodenal impression*, or area of contact with the second part of the duodenum, is in the neighbourhood of the hilum, and varies greatly both in position and extent (Fig. 205).

**Anterior Surface of the Left Kidney.**—The left suprarenal

gland, the spleen, the stomach, and the pancreas are in contact with the upper inclined plane on the anterior surface of the left kidney. The left *suprarenal gland*, as a rule, occupies a narrow district along the medial border, from the level of the hilum to the summit of the organ. The *spleen* is in contact over an area immediately adjoining the lateral convex border. The extent of this splenic field varies considerably in different subjects. The *pancreas* stretches across the left kidney either immediately above, or perhaps exactly over, the eminence which intervenes between the two sloping surfaces on the

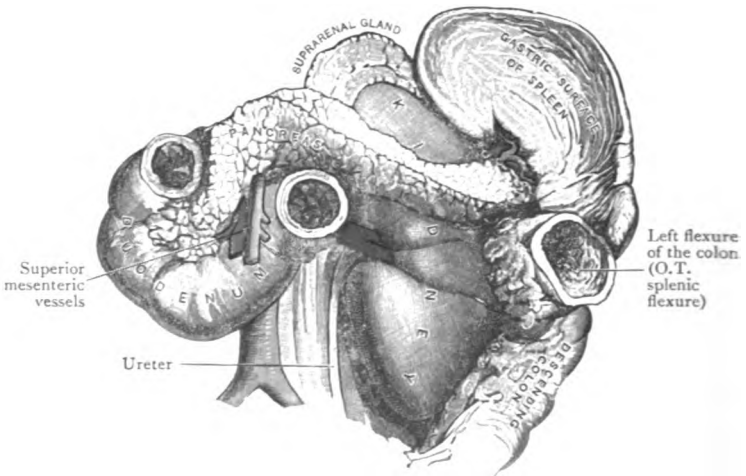


FIG. 206.—Relations of the Left Kidney and the Pancreas.

anterior aspect of the kidney. The *stomach* is in contact with the left kidney over the triangular interval which is left between the left suprarenal gland, the spleen, and the pancreas, and that portion of the surface is covered with peritoneum of the omental bursa.

The inferior sloping surface on the anterior aspect of the left kidney presents a varying relation to the intestinal canal. Towards the lateral border of the organ is the *descending colon*, whilst the remainder of the inferior slope is in relation to coils of the *small intestine*.

**Posterior Surface of the Kidney.**—This surface is mapped out into a medial and a lateral district. The *medial*

*district* is the narrower of the two, and looks medially and backwards. It is in apposition with the psoas muscle and the crus of the diaphragm, and a rounded ridge, which corresponds to the angle between the planes of the psoas and quadratus lumborum muscles, separates it from the lateral district. The *lateral district* looks backwards. In its upper third it rests on the diaphragm, and in its lower two-thirds, upon the quadratus lumborum and the aponeurosis of origin of the transversus muscle. The upper end of the kidney curves slightly forwards in correspondence with the diaphragm, on

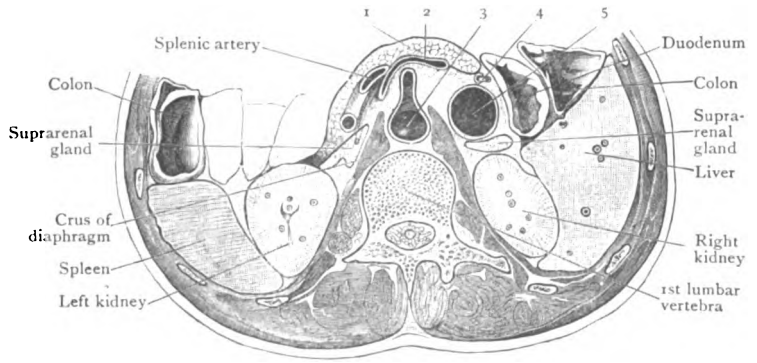


FIG. 207.—Transverse section through Abdomen at the level of the first lumbar vertebra.

1. Pancreas.
2. Splenic vein, joining the portal vein.
3. Aorta, giving off the superior mesenteric artery.
4. Rod in bile-duct.
5. Inferior vena cava.

which it lies; and it should be borne in mind that between the diaphragm and the last rib the pleural cavity descends behind the kidney for a short distance (Fig. 208).

In spare subjects, when the kidneys have been hardened *in situ*, dimples, corresponding to the tips of the transverse processes of the first, second, and third lumbar vertebræ, and a shallow groove for the last rib, may sometimes be detected on the posterior surface of the kidney. A furrow corresponding to the lateral lumbo-costal arch is sometimes to be seen on the posterior aspect of the kidney.

The student should never experience any difficulty in determining the side to which a given kidney belongs. Even allowing that the upper end cannot be distinguished from the lower end, or the anterior surface from the posterior surface, by differences in their appearance (which is frequently the case in a dissecting-room kidney), the ureter

alone is sufficient for the purpose. It lies next the posterior lip of the hilum, and it curves downwards towards the lower end of the kidney.

**Kidney Capsule and Kidney Substance.**—The kidney is invested by a strong fibrous coat, which can be easily stripped from its surface. Divide this capsule along the lateral margin of the organ and peel it off towards the hilum. There it

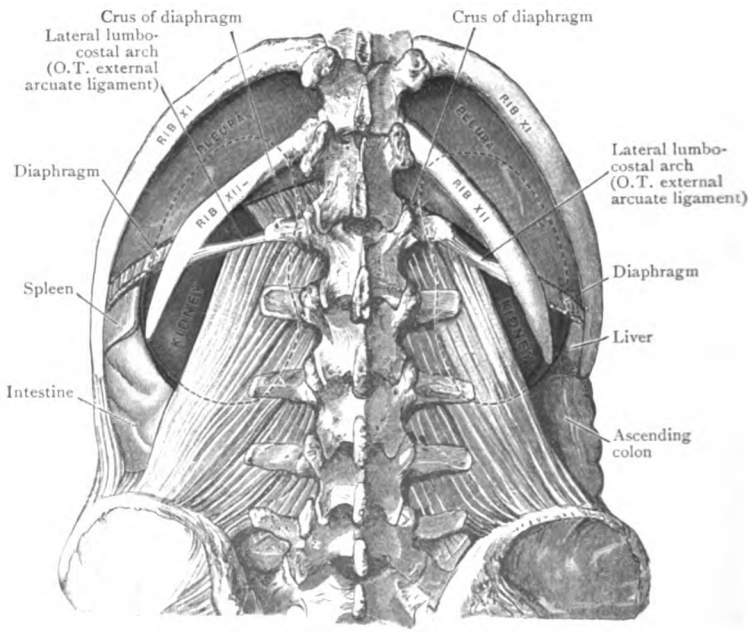


FIG. 208.—Dissection from behind to show the relation of the two Pleural Sacs to the Kidneys. Outline of upper portions of kidneys indicated by dotted lines.

enters the renal sinus, lines its wall, and becomes continuous with the sheaths of the vessels entering the gland, and also with the external coat of the ureter.

Examine the manner in which the ureter or duct is connected with the kidney. As it approaches the hilum it expands into a wide funnel-shaped portion called the *pelvis* (Fig. 209).

The pelvis enters the sinus and divides into two, or perhaps three, large primary branches, and those again break up into a large number of short, stunted secondary divisions

called *calyces* or *infundibula*, which are attached to the walls of the sinus.

The kidney should now be cut into two in the longitudinal direction. Use a large knife, and, entering it at the lateral border, carry it steadily through the gland substance to the hilum.

An examination of the cut surface of the kidney will show that its substance is arranged in two parts — a medullary and a cortical. The *medullary portion* is seen to consist of dark-coloured, faintly striated pyramidal masses, the bases of which are directed towards the periphery, whilst their apices are free and project into the sinus. On the sinus wall each of these appears in the form of a prominent mamillary projection, called a *renal papilla*, which projects into one of the calyces of the pelvis of the ureter (Fig. 210). If the kidney is squeezed, fluid will be seen to exude from these papillæ, showing that the tubuli uriniferi open upon their surface. The number of pyramids and renal papillæ vary from eight to twenty. Usually there are more than twelve. A single calyx of the ureter may surround one, two, or even three renal papillæ, and receives the urine as it issues from the

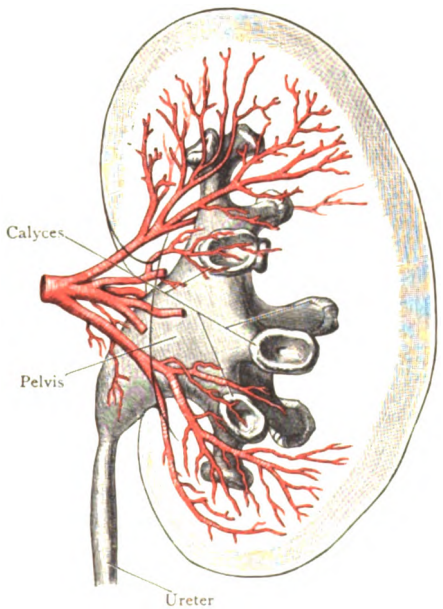


FIG. 209.—From a figure by Max Brodel to show the form of the Pelvis of the Ureter and the Calyces, as well as the relation of the main branches of the Renal Artery to these. The ureter, pelvis, calyces, and arteries were injected with celloidin, and then the kidney substance was removed by means of a digesting fluid. It is, thus, a cast of the pelvis and calyces which is represented, and the cupped appearance of each calyx shows the manner in which the corresponding renal papilla projects into the calyx.

papillary ducts which open on their surfaces. The *cortical substance* constitutes the peripheral part of the gland, and also sends prolongations inwards between the pyramids. These are called the *columnæ renales* (O.T. *columns of Bertin*).

**Ureter.**—This is the duct which carries the urine from the kidney to the bladder. The relations of its expanded upper end or pelvis at the hilum of the kidney have already been noted. Leaving the gland, it turns downwards and becomes contracted, so that when it reaches the level of the lower end of the organ it has acquired the appearance of a cylindrical tube.

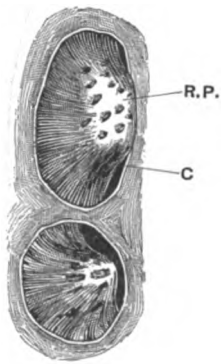


FIG. 210.—Diagram of two Renal Papillæ.

R.P. Renal papilla.

C. Cut edge of a calyx of the pelvis of the ureter.

Each ureter extends downwards and medially, on the anterior surface of the psoas major muscle of the same side, to the lower end of the common iliac artery, or the upper end of the external iliac artery; there it leaves the abdomen proper and enters the pelvis, where its relations will be studied at a later period. As it dips into the pelvis the right ureter passes behind the termination of the ileum, and the left behind the pelvic colon; and as it lies on the front of the psoas major muscle each ureter crosses obliquely in front of the genito-femoral nerve of the same side. The anterior relations of the abdominal parts of the two ureters differ slightly from each other. The right ureter commences behind the second part of the duodenum, and crosses behind the commencement of the third part; both parts, therefore, separate it from the peritoneum. Below the duodenum it descends behind the peritoneum, from which it is partially separated by the right internal spermatic or ovarian vessels, the right colic and ileo-colic vessels, and the terminal parts of the superior mesenteric artery and vein. The whole of the abdominal portion of the left ureter is in relation, in front, with the peritoneum, except that it is crossed anteriorly, behind the peritoneum, by the left internal spermatic or ovarian vessels, the left colic vessels, and the sigmoid vessels.

*Dissection.*—Having now studied all the viscera within the cavity

of the abdomen proper, the student should, in the next place, direct his attention to the diaphragm—the great muscle which constitutes a movable partition between the thoracic and abdominal cavities. Strip the peritoneum from its lower, concave surface; clean the muscular fibres and the central tendinous expansion towards which they ascend. In making this dissection be careful to preserve the inferior phrenic arteries, which ramify upon this aspect of the diaphragm, and also the nerves which accompany them.

**Diaphragma.**—The diaphragm, after the heart, is the most important muscle in the body. It forms the dome-shaped roof of the abdomen, and the highly arched and convex floor of the thorax. It is the chief muscle of respiration. Each respiratory act is accompanied by its descent and ascent, and in this way the capacity of the thoracic cavity is alternately increased and decreased in the vertical direction. The vault or cupola of the diaphragm is higher on the right side than on the left side of the body. In forced expiration it rises, on the right side, as high as the upper margin of the fourth rib, close to the sternum; whereas, on the left side, it reaches only the upper border of the fifth rib.

The *central portion* of the diaphragm is tendinous. From the tendon the fleshy fibres radiate, and at the same time arch downwards, so as to obtain attachment to the circumference of the lower aperture or outlet of the thorax. *Anteriorly*, the diaphragm takes origin from the posterior surface of the xiphoid process; *posteriorly*, it springs by two powerful, partly fleshy and partly tendinous processes, called *the crura*, from the bodies of the upper three lumbar vertebræ, and, on each side of those, from two ligamentous arches, termed the *lumbo-costal arches* (O.T. *ligamenta arcuata*); *laterally*, it arises from the lower six costal arches.

*Anterior Attachment.*—The sternal origin consists of two slips which spring from the back of the xiphoid process. These are separated from each other by a narrow linear interval filled with areolar tissue, and comparable with the wider interval, in the median plane behind, which separates the two crura of the diaphragm.

*Lateral Attachments.*—The costal origin consists of six pointed and fleshy slips which spring from the deep surfaces of the lower six costal cartilages on each side. These interdigitate with the digitations of the transversus abdominis. The sternal and costal origins of the diaphragm, on each side, are separated by a small triangular interval in which the

pleural and peritoneal membranes are separated from each other merely by some loose areolar tissue. Through this gap the superior epigastric branch of the internal mammary artery descends into the abdominal wall.

*Posterior Attachment.*—The *lateral lumbo-costal arch* (O.T. *ligamentum arcuatum externum*) is a fibrous band which stretches from the last rib to the transverse process of the first lumbar vertebra. It arches in front of the quadratus lumborum, and is merely the thickened upper part of the fascia which covers that muscle, *i.e.*, the anterior

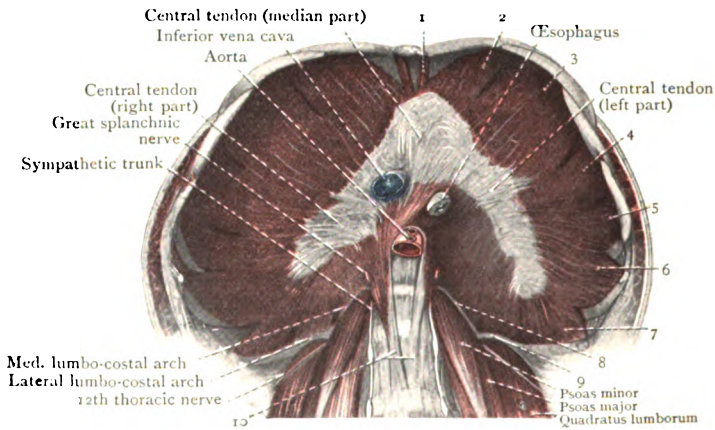


FIG. 211.—Semi-diagrammatic View of the Attachments of the Diaphragm.

1. Sternal origin (left).
2-7. Costal origins (left).
8. Medial lumbo-costal arch (left).
9. Lateral lumbo-costal arch (left).
10. Crura (left and right).

lamella of the lumbar fascia. If the rib is pressed backwards the arch will be rendered more prominent. The last thoracic nerve passes laterally and downwards behind this ligamentous arch. The *medial lumbo-costal arch* (O.T. *ligamentum arcuatum internum*) arches over the psoas major muscle, and, like the lateral arch, is simply a thickening of the fascia which covers the muscle. It is the stronger of the two, and is attached by one extremity to the tip of the transverse process of the first lumbar vertebra, and by the other to the body of the second lumbar vertebra and the tendinous part of the corresponding crus of the diaphragm. Fleshy fibres

arise from both of these arcuate bands; those from the medial arch are more numerous and better marked than those which take origin from the lateral arch, and they are continuous with the fleshy fibres of the crus. Very frequently a gap or interval exists between the fibres which spring from the lateral arch and those which arise directly from the last rib. The anterior, lateral, and posterior attachments of the diaphragm are therefore marked off by intervals from each other.

The *crura* of the diaphragm are two thick fleshy processes which descend upon the bodies of the upper lumbar vertebræ, tapering as they proceed downwards. They end in pointed tendinous extremities. The *right crus* is the larger and longer of the two. It takes origin from the bodies of the upper three lumbar vertebræ, and the intervertebral fibro-cartilages between them. The *left crus* springs from the left side of the bodies of the first two lumbar vertebræ and the intervening fibro-cartilage. It is much smaller, and lies upon a plane posterior to the right crus. Follow the crura upwards; opposite the last thoracic vertebra they are connected across the middle line by a strong fibrous band which arches over the aorta. From the upper border of this fibrous arch fleshy fibres arise which join both crura; and on this account this arch is called the *ligamentum arcuatum medium.*

It may be regarded as a law that wherever an artery pierces the origin or insertion of a muscle, and comes to lie between bone and muscular fibres, it is protected by a fibrous arch. Of this nature is the arch in question, and also the fibrous arch thrown over the profunda artery on the back of the humerus, and the fibrous arches in the adductor magnus for the passage of the perforating arteries, and of the femoral artery itself.

Above the level of the ligamentum arcuatum medium the fleshy fibres of the crura diverge and ascend to join the posterior border of the central tendon. The most medial fibres of each crus, however, decussate so as to separate the aortic from the œsophageal openings. The decussating fasciculus of the right crus is always the larger of the two, and, moreover, it frequently passes behind the decussating fasciculus of the left crus, but may pass in front of it (Fig. 211).

It is the custom of some authors to divide each crus into three parts, a lateral crus, an intermediate crus, and a medial crus. The lateral crus is formed by the fibres which spring from the medial lumbo-costal arch. It is separated from the intermediate crus by the sympathetic trunk. The intermediate crus is separated from the medial crus by the splanchnic nerves. In many cases, however, the subdivisions are not distinct.

**Centrum Tendineum.**—The central tendon is exceedingly strong. It is composed of tendinous bundles running in different directions, and closely woven together so as to give it a plaited appearance. This is well seen in an inspection of its abdominal surface. The central is somewhat semilunar in outline, with a broader and shorter right and a narrower and longer left horn. Upon all sides it is surrounded by muscular fibres of which those attached to the sternum are much the shortest.

**Foramina of the Diaphragm.**—The continuity of the diaphragm is broken by *three* large openings, and by some smaller apertures or fissures for the passage of the splanchnic nerves, and the vena hemiazygos. The three main openings receive the names of the most important objects which they transmit. They are—

1. The aortic.
2. The vena caval.
3. The œsophageal.

*Hiatus Aorticus.—The aortic opening* is in the median plane, in front of the first lumbar vertebra, and between the crura of the diaphragm. It is bounded in front by the fibrous band which arches across the median plane and connects the tendinous portions of the two crura. The structures which pass through the aortic opening are—(1) the aorta, (2) the thoracic duct, and (3) the vena azygos—in that order from left to right.

*Foramen Venæ Cavæ.—The vena caval opening* is at a higher level, being situated opposite the fibro-cartilage between the eighth and the ninth thoracic vertebræ, in front and slightly to the right of the aortic opening. It is placed in the posterior part of the central tendon at the junction between its middle and right segments. Its form is somewhat quadrangular, and its margins are prolonged upon the walls of the vena cava as it passes through it. The contraction of the muscular fibres of the diaphragm will therefore tend to increase the size of this opening and the calibre of the vein which it holds.

In addition to the vena cava, one or two minute twigs from the right phrenic nerve may be transmitted through the vena caval opening.

*Hiatus Œsophageus.—The œsophageal opening* is an oval or elliptical foramen in the muscular part of the diaphragm. It lies in front and slightly to the left of the aortic aperture,

and also at a higher level, being placed opposite the tenth thoracic vertebra. In some cases its upper or anterior border is tendinous, and formed by the posterior margin of the central tendon. Posteriorly, it is separated from the aortic opening by the decussation of the medial fibres of the crura.

The œsophageal opening transmits the œsophagus and the two vagi nerves.

The three large openings of the diaphragm, therefore, present very different features. The *aortic opening* is bounded by a fibrous arch behind the diaphragm, and it can in no way be affected by the contraction of the muscular fibres. The *vena caval opening* is in the central tendon, and its margins are attached to the wall of the vessel which it transmits; contraction of the diaphragm must therefore have a tendency to open this aperture to its widest extent. The *œsophageal opening* is placed in the muscular part, and consequently it is probable that the fibres which surround it are capable of exercising a constricting influence upon the œsophagus, and in that way help to prevent regurgitation of food during the descent of the diaphragm.

Little need be said regarding the smaller foramina. Each crus is pierced by the *three splanchnic nerves*, and the left crus is perforated, in addition, by the *hemiazygos vein*. The *superior epigastric artery* descends in the interval between the sternal and costal attachments of the diaphragm; and the *musculo-phrenic artery* passes between two slips of the costal attachment opposite the eighth or ninth rib.

### Vessels on the Posterior Wall of the Abdomen.

*Dissection.*—The abdominal part of the aorta and its branches and the inferior vena cava must now be cleaned. In doing this, the dissector must take care of the gangliated trunk of the sympathetic, which extends downwards, on the vertebral column, along the anterior border of the psoas major. It is necessary to bear in mind that the lumbar branches of the aorta, as they proceed laterally, pass *behind* the sympathetic trunk. Separate the right crus of the diaphragm from the aorta, and dissect in the interval between them. Here the *cisterna chyli* and the *vena azygos* will be found. A chain of lymph glands, termed the *lumbar glands*, will be noticed in relation to the aorta. The only branches of the aorta which are liable to injury are the *internal spermatic arteries*. These are two slender arteries which spring from the front of the aorta, a short distance below the renal arteries. They are so small that they are apt to be overlooked.

**Aorta Descendens, pars Abdominalis.** — The abdominal part of the aorta is the direct continuation of the thoracic part. It begins in the median plane, in the upper part of the aortic orifice of the diaphragm, in front of the lower border of the last thoracic vertebra; and it ends in front of

the lower part of the body of the fourth lumbar vertebra, a little to the left of the median plane, by dividing into the two *common iliac arteries*. It therefore pursues an oblique course—inclining slightly to the left as it proceeds downwards. A line drawn between the highest points of the iliac crests would indicate the level of the bifurcation of the abdominal aorta; it takes place a little below and to the left of the umbilicus.

Most of the structures which lie *in front of* the abdominal aorta have been removed. In immediate relation to it from above downwards are:—(1) The cœliac plexus and the layer of peritoneum which forms the posterior wall of the omental bursa. (2) The pancreas and splenic vein. (3) The left renal vein and the third part of the duodenum. (4) The root of the mesentery and the superior mesenteric vessels. (5) The peritoneum and the aortic plexus of nerves. Superficial to these it is covered by the liver, the lesser omentum and the stomach, the transverse colon and its mesentery, and by the greater omentum and the coils of the small intestine. *Behind*, the abdominal aorta rests upon the bodies of the lumbar vertebræ and the intervertebral fibro-cartilages, separated from them, however, by the anterior longitudinal ligament and the left lumbar veins. *On each side*, it is related, in its upper part, to the crus of the diaphragm. *On the right side*, the inferior vena cava lies close to the aorta, as high as the second lumbar vertebra, but above that it is separated from the aorta by the fleshy part of the right crus. In the interval between the right crus of the diaphragm and the aorta, the student has already noted the cisterna chyli and the vena azygos. *On the left side*, the left gangliated trunk of the sympathetic is in relation to the artery, below the level of the left crus.

**Branches of the Abdominal Aorta.**—The branches of the abdominal aorta may be described under two heads, viz.—(1) Those which come off *in pairs*. (2) Those which arise *singly*.

| Paired Branches. | Single Branches. |
|---|---|
| 1. Aa. phrenica inferiores. | 1. A. coeliaca. |
| 2. Aa. suprarenalis mediales. | 2. A. mesenterica superior. |
| 3. Aa. renales. | 3. A. mesenterica inferior. |
| 4. Aa. spermaticæ internæ. | 4. A. sacralis media. |
| 5. Aa. lumbales. | |

With the exception of the *middle sacral*, which arises from the back of the extremity of the aorta, between the two

common iliacs, the *single branches* have already been described. The middle sacral artery will be examined when the pelvis is dissected. The *paired branches* may now be examined.

**The Inferior Phrenic Arteries** have already been noticed upon the under surface of the diaphragm. They are two in number, and are the first branches which spring from the abdominal aorta. Diverging from each other, the artery of the right side passes behind the inferior vena cava, whilst the artery of the left side goes behind the œsophagus. Near the posterior border of the central tendon of the diaphragm each divides into a lateral and a medial branch. The *lateral branch* proceeds laterally to anastomose with the intercostal arteries, whilst the *medial branch* curves forwards in front of the central tendon, and ends by anastomosing with its fellow and with the terminal branches of the internal mammary artery. Each phrenic artery, in addition to the branches which it supplies to the diaphragm, gives a twig, called the *superior suprarenal artery*, to the suprarenal gland. On the left side it sends a few minute branches to the œsophagus also.

The *inferior phrenic veins* open into the inferior vena cava.

**The Middle Suprarenal Arteries** (O.T. **Middle Capsular Arteries**) are two small vessels which arise, one from each side of the aorta, at the same level as the superior mesenteric. They run laterally and upwards, in front of the crura of the diaphragm, to the suprarenal glands, into the substance of which they sink. On the right side the middle suprarenal artery passes behind the inferior vena cava. They anastomose freely with the superior and inferior suprarenal arteries.

The *right suprarenal vein* opens into the inferior vena cava, whilst the *left vein* ends in the renal vein or in the phrenic vein.

**The Renal Arteries.**—When compared with the organs which they supply, the renal arteries are disproportionately large. Only a small part of the blood which they carry to the kidneys is used for the nourishment of the gland substance. The kidneys are excretory organs, and it is necessary that the blood should pass to them in large quantity in order that certain materials may be removed from it.

The renal arteries take origin about a quarter of an inch below the superior mesenteric. Each artery proceeds laterally, at right angles to the aorta, and, approaching the kidney,

breaks up into three branches, which enter the hilum, and pass deeply into the renal sinus. It is overlapped by the accompanying vein. The right artery is placed at a slightly lower level than the left, and passes behind the inferior vena cava. At the hilum two of the terminal branches, as a rule, lie between the renal vein and the pelvis of the ureter, whilst the third enters the sinus behind the pelvis of the ureter. In the renal sinus the three terminal branches break up into numerous smaller branches, which penetrate the kidney substance in the intervals between the renal papillæ (Fig. 209, p. 533).

The renal artery gives a small branch—the *inferior suprarenal*—to the suprarenal gland, and also numerous fine twigs to the connective tissue around the kidney.

The *renal veins* join the inferior vena cava. The vein of the left side is the longer of the two. It lies behind the pancreas and crosses in front of the aorta. It receives a tributary from the left suprarenal gland; it is joined also by the left internal spermatic or ovarian vein.

**The Internal Spermatic Arteries** are two long slender vessels which spring from the front of the abdominal aorta, a short way below the renal arteries. Diverging from its fellow, each artery passes obliquely downwards and laterally, behind the peritoneum, to the abdominal inguinal ring, where it joins the other factors of the spermatic cord. As it descends it rests upon the psoas major, and crosses anterior to the ureter and the lower end of the external iliac artery. On the right side the internal spermatic artery passes in front of the vena cava inferior and behind the terminal part of the ileum. On the left side it proceeds downwards behind the iliac colon (Fig. 184).

In the female the corresponding arteries go to the ovaries, and are consequently termed the *ovarian arteries*. Within the abdomen proper they have the same relations as the spermatic arteries, except that they cross the upper ends of the external iliac arteries. In the dissection of the female pelvis they will be followed to their destination.

The *right internal spermatic vein* joins the inferior vena cava directly, whilst the *left vein* terminates in the left renal vein. The *ovarian veins* end in the same manner.

**The Lumbar Arteries** are four in number on each side, and they spring from the posterior aspect of the abdominal aorta, in series with the intercostal arteries. At

present they are seen only in a very short part of their course. They proceed laterally upon the bodies of the upper four lumbar vertebræ, behind the gangliated trunk of the sympathetic, and then disappear under cover of the psoas major muscle and of the series of fibrous arches from which the muscle arises. The upper two arteries pass behind the crura of the diaphragm also, and on the right side they pass behind the inferior vena cava.

The *lumbar veins* join the inferior vena cava, and those of the left side pass behind the aorta.

**Vena Cava Inferior.**—This is the large vein which collects, by means of its tributaries, the venous blood from the lower limbs, the abdominal viscera, and a great part of the abdominal parietes. It is formed in front of the body of the fifth lumbar vertebra, to the right of the median plane, by the union of the two *common iliac veins*. As it ascends it lies at first at the right side of the aorta, in front of the bodies of the vertebræ and the medial part of the right psoas major, but it is separated from the vertebral bodies by the anterior longitudinal ligament and the lower right lumbar arteries, and from the anterior border of the psoas major by the right sympathetic trunk. Above the lower border of the second lumbar vertebra it is separated from the aorta by the right crus of the diaphragm. The right renal artery, the right cœliac ganglion, the right inferior phrenic artery, the right suprarenal artery, and the medial part of the anterior surface of the right suprarenal gland intervene between it and the crus. At its commencement it lies behind the right common iliac artery; then it is crossed by the root of the mesentery and the superior mesenteric vessels. For a short distance above the root of the mesentery it is in direct relation with the peritoneum on the posterior wall of the great sac. At the level of the third lumbar vertebra it is crossed by the third part of the duodenum and the right internal spermatic or ovarian artery. Next, the head of the pancreas and the pancreatico-duodenal arteries are in front of it, and the bile-duct descends in front of its lateral border. Above the head of the pancreas it passes behind the first part of the duodenum, from which it is separated by the portal vein; then it ascends behind the epiploic foramen; and, finally, it lies in the vena caval fossa on the posterior surface of the liver, and the hepatic veins open into the uppermost part of its anterior surface.

It receives the following tributaries :—

1. The common iliac veins.
2. The lumbar veins.
3. The right internal spermatic or ovarian vein.
4. The renal veins.
5. The right suprarenal vein.
6. The inferior phrenic veins.
7. The hepatic veins.

**Arteriæ Iliacæ Communes (Common Iliac Arteries).**—The two terminal branches of the aorta should next be examined. They arise upon the front of the body of the fourth lumbar vertebra, to the left of the median plane, and, diverging from each other, proceed downwards and laterally upon the vertebral column. After a course of about two inches, each vessel ends opposite the sacro-iliac articulation, at the level of the lumbo-sacral articulation, by dividing into an *external iliac* and a *hypogastric* (O.T. *internal iliac*) branch; of these the external iliac is the larger of the two, and appears to be the continuation of the parent trunk, whilst the hypogastric passes downwards into the pelvis.

The common iliac artery of each side is covered by peritoneum, and overlapped by coils of the small intestine; furthermore, it is crossed by the large sympathetic twigs which connect the aortic and hypogastric plexuses, and, close to its termination, by the ureter. On the left side the superior hæmorrhoidal vessels also pass in front of the common iliac artery.

The left common iliac artery is in relation posteriorly with the bodies of the last two lumbar vertebræ, the left sympathetic trunk and the medial margin of the psoas major muscle. The right artery is separated from the vertebræ and the sympathetic trunk by the two common iliac veins and the commencement of the inferior vena cava.

No collateral branches of any consequence proceed from the common iliac artery.

**Venæ Iliacæ Communes (Common Iliac Veins).** — The *left common iliac vein* is much longer than the right, and stands in relation to both common iliac arteries. It first lies along the *medial* or *right* side of its companion artery, and on a posterior plane; then it passes *behind* the upper part of the right artery to reach the vena cava inferior. The *right common iliac vein* lies *behind* its companion artery, and behind the upper part of the artery it joins with the left

vein to form the inferior vena cava. Each common iliac vein is formed by the junction of the external iliac vein and the hypogastric vein.

The common iliac vein of each side is joined by the *ilio-lumbar vein*. The left common iliac vein receives the *middle sacral vein* also.

**Arteria Iliaca Externa.**—The external iliac artery is the first or abdominal portion of the great arterial trunk which carries blood to the lower limb. It begins opposite the sacro-iliac articulation, at the level of the lumbo-sacral articulation, and extends obliquely downwards and laterally, along the brim of the pelvis minor, to the inguinal ligament, behind which it passes into the thigh, and becomes the *femoral artery*. Its course is indicated on the surface by the lower two-thirds of a line drawn from a point a little below and to the left side of the umbilicus to a point midway between the symphysis pubis and the anterior superior spine of the ilium. The upper third of the line indicates the position of the common iliac artery.

The external iliac, like the common iliac artery, is closely covered by peritoneum. The right artery passes behind the terminal part of the ileum, and the left passes behind the pelvic colon. Towards its termination each external iliac artery is crossed by the deep circumflex iliac vein, and the external spermatic nerve (O.T. genital branch of genito-crural). In the male, this part of the artery is crossed also by the ductus deferens and the internal spermatic vessels, and in the female, by the round ligament of the uterus. At first the external iliac artery rests upon the medial margin of the psoas major muscle, but close to the inguinal ligament it comes to lie directly in front of that muscle. The artery is separated from the muscle, however, by the fascia iliaca, to which it is bound down by a condensed part of the extra-peritoneal tissue. The genito-femoral nerve lies along the lateral side of the artery, and the external iliac vein is placed on its medial side; on the right side, however, the vein, as it passes upwards, gradually comes to lie behind the artery.

The external iliac gives off two large branches to the abdominal wall, viz.—(1) the inferior epigastric; (2) the deep circumflex iliac. They arise close to the inguinal ligament, and have both been examined (pp. 404, 405). The veins corresponding to these arteries open into the external iliac vein.

**Vena Iliaca Externa.**—The external iliac vein is the continuation of the femoral vein. It enters the large pelvis by passing upwards behind the inguinal ligament. It lies at first along the medial side of the artery of the same name, but on a plane somewhat posterior to it; and higher up, on the right side, it gets completely behind the artery. At the level of the lumbo-sacral articulation it ends by joining the hypogastric vein in the formation of the common iliac vein. Immediately before its termination it passes to the lateral side of the hypogastric artery—between the artery and the psoas major muscle. Its *tributaries* are the veins corresponding to the deep circumflex iliac artery and the inferior epigastric artery.

**Deep Lymph Glands.**—The dissector has, doubtless, noticed a chain of lymph glands in connection with the external iliac artery, the common iliac artery, and also extending upwards upon the vertebral column in relation to the aorta and inferior vena cava. The *external iliac glands* are in two groups—a lower and an upper. The former consists of three glands placed one on each side and one in front of the external iliac artery, and immediately above the inguinal ligament. The medial gland receives the deep femoral lymph vessels; into the anterior gland is poured the lymph which is drained from the district supplied by the inferior epigastric artery; whilst the lateral gland receives the lymph from the district supplied by the deep circumflex iliac artery. The efferent vessels from the lower group enter the higher group of glands, and from those the lymph is passed on to the common iliac and lumbar glands.

The glands in relation to each side of the aorta and inferior vena cava are both numerous and large, and are called the *median lumbar glands*. Their efferent vessels terminate in two common lumbar lymph trunks, which open into the cisterna chyli.

**Cisterna Chyli** (O.T. **Receptaculum Chyli**).—This is the dilated commencement of the thoracic duct. It is placed upon the bodies of the first and second lumbar vertebræ, in the interval between the right crus of the diaphragm and the aorta. To bring it into view, it is necessary to separate the right crus from the lumbar vertebræ and pull it aside. When fully displayed, the cisterna chyli is seen to be a narrow elongated sac, about two inches in length, which receives at its lower end the two common lumbar lymph trunks, whilst,

superiorly, it contracts and becomes the thoracic duct. About its middle it is joined, anteriorly, by the intestinal trunk. Entering it near its upper end are two lymph trunks which come from the lower intercostal glands; they reach it by passing downwards through the aortic opening. The vena azygos lies along its right side, but the cisterna chyli is easily distinguished from this by the whiteness of its walls. The thoracic duct enters the thorax by passing through the aortic opening of the diaphragm.

**Vena Azygos.**—The *azygos vein* (O.T. *vena azygos major*) takes origin usually in the right ascending lumbar vein (p. 555). It will be found in the interval between the right crus of the diaphragm and the aorta, upon the right side of the cisterna chyli, and it will be noticed to enter the thorax by passing through the aortic opening of the diaphragm.

**Vena Hemiazygos** (O.T. **Vena Azygos Minor Inferior**).—The *hemiazygos vein* is more difficult to discover. It originates on the left side of the vertebral column, in the left ascending lumbar vein. It enters posterior mediastinum of the thorax after piercing the left crus of the diaphragm.

### Fascia and Muscles on the Posterior Wall of the Abdomen.

The muscles on the posterior wall of the abdomen are three in number, viz.—(1) the *psoas major*, an elongated fleshy mass lying on the side of the vertebral column; (2) the *quadratus lumborum*, a quadrate muscle lateral to the psoas, and stretching from the crest of the ilium to the last rib; (3) the *iliacus*, situated in the iliac fossa. The fascia which covers these muscles must be studied first.

**Quadratus Lumborum Fascia.**—Follow this medially and it will be found to be attached to the medial ends of the anterior surfaces of the transverse processes of the lumbar vertebræ. Trace it laterally and it will be noticed to join the posterior aponeurosis of the transversus abdominis muscle. From these connections the dissector will understand that this fascia is simply the anterior lamella of the lumbar fascia. Above, it is fixed to the last rib, and is thickened so as to form the *lateral lumbo-costal arch*, whilst inferiorly it is attached to the ilio-lumbar ligament. The quadratus lumborum muscle, therefore, is enclosed in a sheath formed anteriorly by the

anterior lamella of the lumbar fascia, and posteriorly by the middle lamella of the lumbar fascia (Fig. 148, p. 395).

**Fascia covering the Psoas and Iliacus.**—This is one continuous membranous sheet. *Above* the level of the crest of the ilium, where it is in relation only to the psoas, it is thin and narrow. There it is attached laterally to the fascia covering the quadratus lumborum, whilst medially it is fixed to the vertebral column by a series of fibrous arches which bridge over the lumbar arteries. Superiorly, it has been seen to form the thickened band termed the medial lumbo-costal arch. *Inferiorly*, the fascia expands so as to cover both the psoas and the iliacus, and at the same time it becomes much denser and thicker. There it receives the name of the *fascia iliaca*, and presents most important connections. The external iliac vessels lie upon it, whilst the femoral nerve lies behind it. The genito-femoral nerve pierces it, and comes into relation with the external iliac artery. Laterally, it is firmly fixed to the crest of the ilium; medially, it sweeps over the psoas, and is attached to the brim of the pelvis minor. These attachments can be easily demonstrated by dividing it in the vertical direction, over the iliacus, a short way to the lateral side of the psoas. It is very loosely attached to the subjacent muscles, so that the fingers can readily be passed behind it, first in a lateral and then in a medial direction. Note that no perceptible fascial partition dips backwards from it between the psoas and iliacus.

The inferior connections of this fascia have already been studied (p. 183). On the lateral side of the iliac vessels it has been seen to become continuous with the fascia transversalis, and, at the same time, to be attached to the inguinal ligament; whilst behind those vessels it is carried downwards into the thigh, to form the posterior wall of the femoral sheath.

**Surgical Anatomy.**—The attachments of the ilio-psoas fascia are of high surgical importance. When an abscess forms in connection with the lumbar vertebræ the pus readily passes downwards within the psoas sheath, and in certain cases is conducted behind the inguinal ligament so as to point in the thigh. It cannot enter the pelvis owing to the attachment of the fascia iliaca to the ilio-pectineal line.

*Dissection.*—The muscles should now be cleaned and their attachments defined; but, while this is being done, certain points must be attended to. The medial portion of the fascia iliaca must be preserved, in order that its relation to the pelvic fascia may be afterwards made out. In the case of

the psoas major muscle, care must be taken not to injure—(1) the sympathetic trunk, which lies along its anterior margin; (2) the genito-femoral nerve, which runs downwards on its anterior surface; (3) the ilio-inguinal nerve, and the lateral cutaneous nerve of the thigh, which appear at its lateral border; and (4) the femoral nerve, which lies in the interval between it and the iliacus muscle. In the case of the quadratus lumborum, bear in mind that the last thoracic nerve runs laterally in front of that muscle, close to the lower border of the last rib, and that the ilio-hypogastric and ilio-inguinal nerves cross it obliquely at a lower level.

**M. Quadratus Lumborum.**—This muscle *arises* from the ilio-lumbar ligament and from the crest of the ilium behind it. It receives two or three slips also from the transverse processes of a corresponding number of the lower lumbar vertebræ. Narrowing slightly, as it passes upwards, it is *inserted* into the medial half of the last rib, behind the lateral lumbo-costal arch, and by four tendinous slips into the tips of the transverse processes of the upper four lumbar vertebræ.

**M. Psoas Major.**—This muscle has three distinct series of origins from the side of the vertebral column:—(1) by five fleshy processes from the anterior surfaces and lower borders of the transverse processes of the lumbar vertebræ, close to their roots; (2) by five slips, each of which arises from the intervertebral fibro-cartilage and the contiguous margins of the bodies of two vertebræ — the first slip springing from the last thoracic and the first lumbar vertebræ and the intervening fibro-cartilage, and the last slip from the lower two lumbar vertebræ and their intervening fibro-cartilage; (3) from the tendinous arches which bridge over the lumbar arteries and protect these vessels from the pressure of the contracting muscle.

The psoas major tapers somewhat as it extends downwards along the brim of the pelvis minor, and a tendon appears on its lateral border, which affords attachment to the fibres of the iliacus. Passing behind the inguinal ligament, it is inserted into the lesser trochanter of the femur.

Another muscle, called the *psoas minor*, is occasionally present. This springs from the bodies of the last thoracic and first lumbar vertebræ, and the intervertebral fibro-cartilage between them, and, stretching downwards upon the anterior and medial aspect of the psoas major, it ends in a tendon which is inserted into the ilio-pectineal eminence and ilio-pectineal line.

**M. Iliacus.**—This muscle arises from the upper part of the iliac fossa, the anterior sacro-iliac ligament, and the base of the sacrum. It is inserted into the tendon of the psoas

major. Some of its fibres, however, have a separate insertion into an impression below the lesser trochanter of the femur.

### Nerves on the Posterior Wall of the Abdomen.

The nerves on the posterior wall of the abdomen are the gangliated trunk of the sympathetic and the anterior rami of the spinal nerves, with the branches which proceed from them. These should now be dissected.

**Truncus Sympathicus.**—On each side, the sympathetic trunk enters the abdomen behind the medial lumbo-costal arch, and extends downwards upon the bodies of the lumbar vertebræ along the anterior border of the psoas major muscle. *Superiorly*, it is continuous with the thoracic portion of the trunk, whilst *inferiorly*, it passes behind the common iliac artery and enters the pelvis minor. In the thorax, it is placed upon the heads of the ribs; in the abdomen it lies nearer the median plane, being carried forwards by the psoas major muscle. On the right side it is covered by the inferior vena cava, and on both sides the lumbar vessels pass laterally behind it. As a general rule, a small oval ganglion is formed upon it opposite the body of each lumbar vertebra. *Rami communicantes* and *peripheral branches of distribution* proceed from the gangliated trunk.

The *rami communicantes* connect the ganglia with the anterior rami of the lumbar spinal nerves. One or more will be found accompanying each lumbar artery. Trace them backwards by cutting through the fibrous arches which bridge over these vessels and scraping away the fibres of the psoas muscle. They join the lumbar nerves close to the intervertebral foramina.

The rami communicantes consist of two sets, viz., white and grey. The *white rami communicantes* are composed of medullated fibres which pass from the spinal nerves to the gangliated trunk. In the lumbar region there are only two or at most three of these, and they proceed from the upper two or three lumbar nerves. The *grey rami communicantes* are much more numerous, and are formed of fibres which stream out in an irregular manner from the sympathetic trunk to all the anterior rami of the lumbar nerves.

The *peripheral branches of distribution* consist of a large number of small filaments which arise irregularly from the lumbar gangliated trunk, and pass medially to the aortic plexus.

*Dissection.*—To bring the anterior rami of the lumbar nerves into view, it is necessary to scrape away the psoas major muscle. This was partially done when the connecting sympathetic twigs were followed backwards. An occasional branch, the *accessory obturator*, is liable to injury unless it is secured at once. When present, it will be found descending along the medial border of the psoas major.

**Lumbar Nerves.**—The anterior rami of the lumbar nerves are five in number, and pass laterally in the substance of the psoas major muscle. They increase in size from above downwards, and each nerve is joined by one or more twigs from the sympathetic trunk. Branches are given by them to the psoas and quadratus lumborum muscles.

The first *three* lumbar nerves, with a part of the *fourth*, unite in a loop-like manner to form the *lumbar plexus*, whilst the remaining part of the *fourth* joins the *fifth* to form the *lumbo-sacral trunk*. The fourth lumbar nerve is frequently called the *nervus furcalis*, seeing that it enters into the formation of both the lumbar and sacral plexuses.

**Plexus Lumbalis.**—The lumbar plexus is placed in front of the transverse processes of the lumbar vertebræ, in the substance of the psoas major. *Superiorly*, it is usually connected with the last thoracic nerve by a small twig which descends, in the substance of the psoas, to the first lumbar nerve; *inferiorly*, it is brought into communication with the sacral plexus by the branch of the fourth nerve, which enters into the formation of the lumbo-sacral trunk.

The following are the branches which proceed from the lumbar plexus:—

1. N. ilio-hypogastricus, } derived from 1st lumbar nerve.
2. N. ilio-inguinalis, }
3. N. genito-femoralis, ,, 1st and 2nd lumbar nerves.
4. N. cutaneus femoris lateralis, ,, 2nd and 3rd lumbar nerves.
5. N. obturatorius, ,, 2nd, 3rd, and 4th lumbar nerves.
6. N. femoralis, ,, 2nd, 3rd, and 4th lumbar nerves.
7. Rami musculares to the quadratus lumborum and psoas major muscles; these branches arise somewhat irregularly.

The manner in which these nerves spring from the plexus may now be studied. The *first lumbar trunk* breaks up into three branches, viz., the ilio-hypogastric, the ilio-inguinal, and the upper root of the genito-femoral. The *second*, *third*, and *fourth lumbar trunks* each divide into an anterior and a posterior division. The three anterior divisions are smaller than the others, and they unite to form the obturator nerve; the three large posterior divisions unite to form the femoral

nerve. But other branches come off from certain of these divisions. Thus, the lower root of the genito-femoral springs from the anterior division of the second lumbar nerve, whilst the two roots of the lateral cutaneous nerve of the thigh take origin from the posterior divisions of the second and third lumbar trunks.

The *ilio-hypogastric nerve* emerges from the lateral border of the psoas, and crosses the quadratus lumborum obliquely.

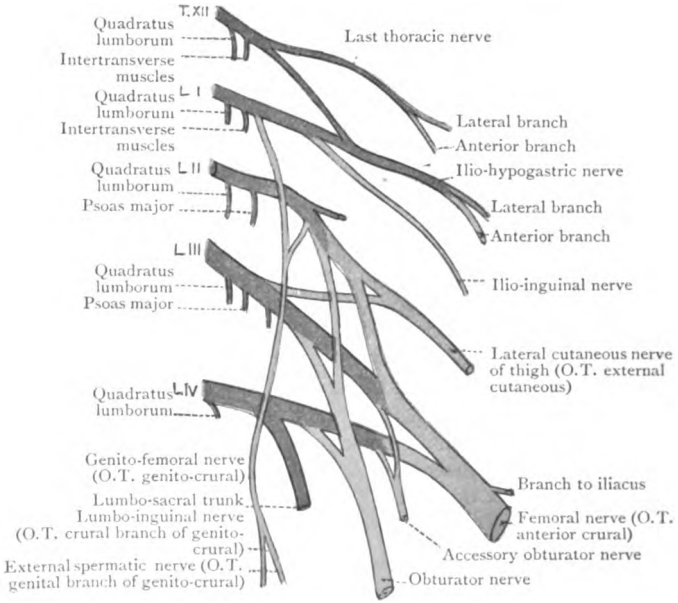


FIG. 212.—Diagram of Lumbar Plexus.

At the crest of the ilium, it leaves the abdomen by piercing the transversus abdominis muscle. Its further course has already been studied (p. 394). It gives off a *lateral cutaneous branch* to the skin of the gluteal region, and an *anterior cutaneous branch* to the skin over the lower part of the abdominal wall.

The *ilio-inguinal nerve* is smaller than the ilio-hypogastric, and leaves the psoas major almost at the same point. It runs obliquely downwards and laterally over the quadratus lumborum and the upper part of the iliacus, and disappears from

view by piercing the transversus abdominis muscle, a little way in front of the ilio-hypogastric. It is distributed to the integument of the scrotum and the medial aspect of the proximal part of the thigh (pp. 174 and 394).

The *genito-femoral nerve* (O.T. *genito-crural nerve*) is directed forwards through the psoas, and, appearing upon its anterior aspect, ends by dividing into a lumbo-inguinal and an external spermatic branch. The *external spermatic branch* proceeds downwards and medially. It crosses the external iliac artery obliquely, and reaches the abdominal inguinal

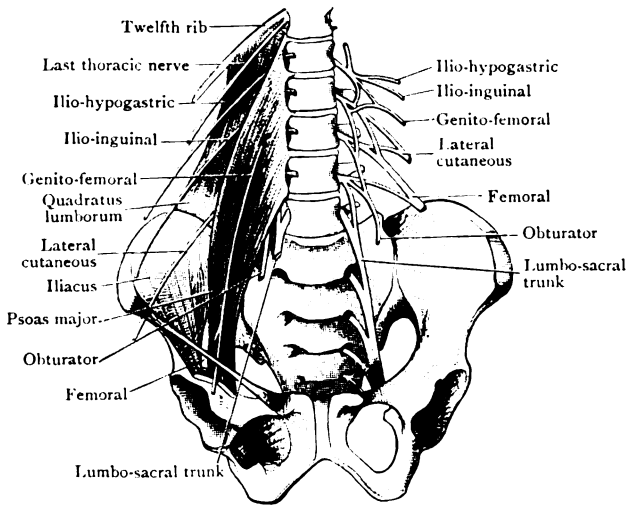


FIG. 213.—The Lumbar Plexus (semi-diagrammatic).

ring. There it comes into relation with the constituents of the spermatic cord, and, leaving the abdomen, is distributed to the cremaster muscle. In the female, this branch is very small, and ends in the round ligament of the uterus and the labium pudendi. The *lumbo-inguinal branch* runs downwards along the lateral side of the external iliac artery, and, crossing the deep circumflex iliac artery, passes behind the inguinal ligament. It supplies a limited portion of the skin on the front of the thigh.

The *lateral cutaneous nerve of the thigh* (O.T. *external cutaneous nerve*) emerges from the lateral border of the psoas major about

its middle, and descends obliquely across the iliacus muscle, behind the fascia iliaca, to the anterior superior spine of the ilium. At that point it leaves the abdomen by passing behind the inguinal ligament. It supplies the skin upon the lateral and anterior aspect of the thigh.

The *femoral nerve* (O.T. *anterior crural nerve*) is the largest branch of the plexus. It runs downwards in the interval between the psoas major and iliacus, and passes out of the abdomen behind the inguinal ligament. It gives a branch to the iliacus muscle.

The *obturator nerve* emerges from the medial border of the psoas major, where this muscle reaches the brim of the pelvis minor, and extends forwards upon the inner surface of the wall of the pelvis minor, a short way below the ilio-pectineal line of the hip bone. At the upper part of the obturator foramen it joins the artery of the same name, and, escaping from the pelvis, enters the thigh.

A small nerve, called the *accessory obturator*, is occasionally found. It may spring either from the obturator or from the third and fourth lumbar nerves. It proceeds downwards along the medial side of the psoas major, and it enters the thigh by passing over the pubic bone under cover of the pectineus. In the thigh it gives branches to the hip-joint, and unites with the obturator nerve. It supplies a twig occasionally to the pectineus muscle.

**Truncus Lumbosacralis** (O.T. **Lumbo-sacral Cord**).—The lumbo-sacral trunk is formed by the union of the anterior ramus of the fifth lumbar nerve with the descending branch of the fourth lumbar nerve. It passes downwards over the base of the sacrum into the pelvis minor, and joins the sacral plexus.

**Last Thoracic Nerve.**—The anterior ramus of this nerve will be found running laterally in front of the quadratus lumborum, and under cover of the fascia spread over that muscle, along the lower border of the last rib. Near the vertebral column it sends a small offset downwards to the first lumbar nerve, and at the lateral border of the quadratus lumborum it pierces the aponeurosis of the transversus abdominis, and then passes forwards in the abdominal wall between that muscle and the internal oblique. Its course and distribution in the wall of the abdomen have already been described (p. 394).

**Arteriæ Lumbales.**—The lumbar arteries have been traced to the medial border of the psoas major. They are now observed to pass backwards behind this muscle to the intervals between the transverse processes of the vertebræ, where each gives off a dorsal branch.

Each *dorsal branch* runs backwards, between the transverse processes, and after giving a *spinal branch* which enters the vertebral canal through the intervertebral foramen, it ends in the muscles and integument of the back.

After giving off their *dorsal* branches, the trunks of the arteries, with the exception of the last, proceed laterally behind the quadratus lumborum, and are then directed forwards between the internal oblique and transversus muscles, where they anastomose, *superiorly*, with the intercostal arteries, *inferiorly*, with the deep circumflex iliac and ilio-lumbar arteries, and *anteriorly*, with the branches of the superior and inferior epigastric arteries. The last lumbar artery, as a rule, passes in front of the quadratus lumborum.

**Venæ Lumbales.**—The lumbar veins accompany the corresponding arteries, and pour their blood into the inferior vena cava. The veins of the left side pass behind the aorta. The lumbar veins of each side are linked together, in front of the transverse processes of the vertebræ, by anastomosing channels which form a continuous longitudinal vessel, called the *ascending lumbar vein.* By its upper end this venous trunk is connected with the corresponding azygos vein.

**Last Thoracic** or **Subcostal Artery.**—At this stage of the dissection the subcostal artery, the last parietal branch of the thoracic aorta, will be seen crossing the upper part of the quadratus lumborum, in company with the last thoracic nerve. It lies in series with the abdominal branches of the lumbar arteries.

*Dissection.*—The lower limbs having, by this time, been removed from the trunk, the pelvis also may be detached. Place a ligature around the aorta and inferior vena cava at the level of the bifurcation of the former, and divide them immediately above that point. Then carry the knife through the intervertebral fibro-cartilage which intervenes between the third and fourth lumbar vertebræ, and, having cut the nerves and soft parts, complete the separation of the pelvis from the remainder of the trunk by means of the saw.

## PELVIS.

The pelvis, using the term in its widest sense, is the region bounded *posteriorly* by the sacrum and coccyx, and *laterally*

and *anteriorly* by the hip bones. The bony wall is deficient, on each side posteriorly, between the sacrum and coccyx behind and the hip bone in front. This interval is partially filled in by the ligamentum sacro-tuberosum (O.T. *great sacro-sciatic ligament*) and the ligamentum sacro-spinosum (O.T. *small sacro-sciatic ligament*), which divide it into the greater and lesser sciatic foramina. Anteriorly, on each side, the bony wall is broken by the obturator foramen, which is closed by the obturator membrane; and directly in front there is a gap bounded by the pubic arch and occupied by the uro-genital diaphragm and its fasciæ (O.T. *triangular ligament*).

The area thus enclosed is separated into an upper and a lower part by an imaginary plane, the plane of the pelvic brim. The margin of this plane is the linea terminalis which is separable into sacral, iliac and pubic portions. The part above the plane is the pelvis major (O.T. *false pelvis*), which has already been studied as part of the abdomen. The part below the plane is the pelvis minor (O.T. *true pelvis*). The inner aspect of the wall of the pelvis minor is partially covered by the following muscles. *Posteriorly*, on the front of the sacrum, are the two *piriformes muscles*. *Laterally*, on the inner surface of each hip bone, is the *obturator internus muscle*. *Anteriorly* is the uro-genital diaphragm, formed by the deep transverse perineal muscles and the *sphincter urethræ membranaceæ*. The inner surfaces of these muscles and the intervening skeletal structures are covered by a continuous layer of fascia, the *parietal pelvic fascia*. The wall of the pelvis minor may, therefore, be regarded as consisting of three strata, viz.—1. A bony stratum. 2. A muscular stratum. 3. A membranous stratum.

The pelvis minor is separated into an upper part and a lower part by the *pelvic diaphragm* and the fascia covering it. The pelvic diaphragm is formed by the two *levatores ani* and the two *coccygei muscles*. In the following account the upper part will be spoken of as the *pelvis*. The lower part has already been called the *perineum*.

The pelvis, as thus defined, is the smaller, basin-shaped, lower part of the abdominal cavity. It communicates with the upper portion or pelvis major through a somewhat constricted aperture, the superior aperture of the pelvis.

The contents of the pelvic cavity differ in the two sexes; in both, however, the bladder occupies the anterior part of the

space, and the rectum and pelvic colon the posterior part. The difference is to be found in the generative organs and their blood-vessels. It is necessary, therefore, to describe the male and the female pelvis separately.

## Male Pelvis.

The male pelvis contains the following structures:—

| | |
|---|---|
| *Viscera.* | The rectum and the pelvic colon.[1] |
| | The bladder, with the lower portions of the ureters, the prostate, and the prostatic part of the urethra.[1] |
| | The ductus deferentes and the vesiculæ seminales.[1] |
| *Blood-Vessels.* | The hypogastric vessels and their branches and tributaries. |
| | The superior hæmorrhoidal vessels. |
| | Venous plexuses associated with the viscera. |
| *Nerves.* | The pelvic plexuses of the sympathetic system and their offshoots. |
| | The obturator nerves. |
| *Other Structures.* | The extraperitoneal fat. |
| | The pelvic part of the peritoneum. |

The following structures lie between the pelvic fascia and the bony and muscular strata of the pelvic wall:—

| | |
|---|---|
| *Blood-Vessels.* | The middle sacral vessels. |
| | The parietal branches of the hypogastric vessels, after they have pierced the fascia. |
| *Nerves.* | The sacral and pudendal plexuses of nerves. |
| | The pelvic parts of the sympathetic trunks. |

**General Position of the Viscera.**—The *pelvic colon* and the *rectum* occupy the posterior part of the cavity, the colon extending in flexuous curves from the left margin of the superior pelvic aperture to the middle of the third piece of the sacrum, where it becomes the rectum. The rectum follows the concavity of the sacrum and coccyx, and runs forwards to the base of the bladder. The *bladder* lies in the anterior part of the cavity, behind the pubic bones, and in front of the rectum. The *seminal vesicles* lie in a plane between the bladder and the rectum, and the ductus deferentes having crossed the brim, behind the origins of the inferior epigastric arteries, run downwards and backwards, and then turn medially, across the ureters, to gain the base of the bladder,

[1] Strictly speaking, the bladder, the prostate, the seminal vesicles, and the lower parts of the rectum, ductus deferentes and ureters are not in the pelvis, for they are embedded in the pelvic fascia and, therefore, lie in the pelvic wall.

at the medial sides of the seminal vesicles. The pelvic portions of the ureters can be seen descending, outside the peritoneum, along the fronts of the hypogastric arteries, and turning medially, below the ductus deferentes, towards the base of the bladder. The prostate lies below the bladder and encloses the prostatic part of the urethra (Fig. 214).

**The Pelvic Peritoneum.**—The peritoneum passes into the

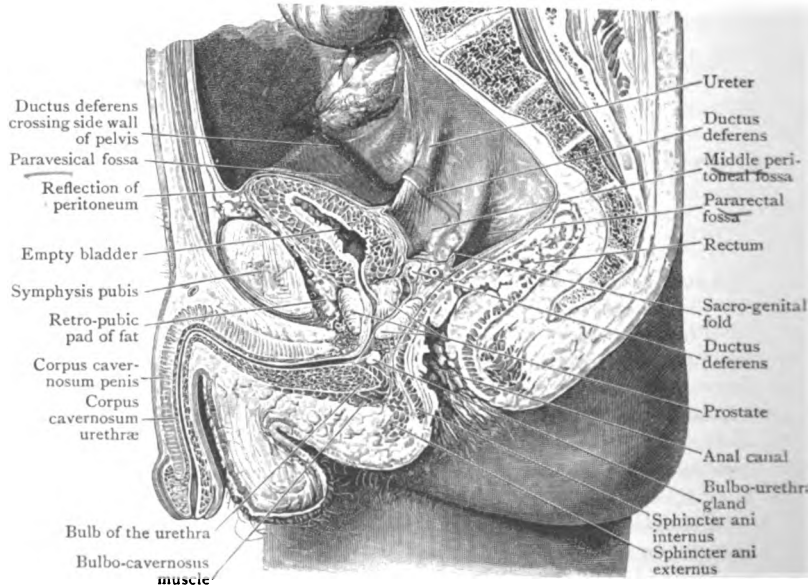


FIG. 214.—Median section through the Male Pelvis. The bladder, which is empty, does not present the usual form.

pelvis through the superior aperture, and gives partial or complete coverings to various pelvic viscera. It covers the upper surface of the bladder, and passes from the lateral borders of that surface to the side walls of the pelvic cavity, as the *lateral false ligaments* of the bladder. Turning over the posterior border of the upper surface of the bladder, it descends, for a slight distance, on the fundus or base of the viscus, and then, if the bladder is empty, it projects backwards as a semilunar ledge or fold, called the *sacro-genital fold.* In the middle portion of that fold the seminal vesicles are enclosed and

parts of the ductus deferentes. The lateral borders of the fold curve backwards to the sacrum, passing at some little distance from the sides of the rectum. From the lower surface of the sacro-genital fold the peritoneum passes to the front of the rectum, on which it is reflected upwards to the pelvic colon. Below the line of reflection from the sacro-genital fold there is a part of the rectum entirely devoid of peritoneal covering. The part immediately above that is covered only in front, but at a higher level the front and the sides also are covered; and when the pelvic colon is reached the peritoneum entirely surrounds that part of the gut and attaches it to the posterior wall of the pelvis by a fold or mesentery, called the *pelvic meso-colon.* The hollow or pouch between the sacro-genital fold in front and the rectum behind is the *recto-vesical* or *recto-genital excavation.*

**The Peritoneal Fossæ.**—As the peritoneum follows the contours of the more projecting viscera, three hollows or secondary pouches are formed on each side: an *anterior* or *paravesical*, a *middle* or *genital*, and a *posterior* or *pararectal.* The paravesical fossa is bounded medially by the bladder, laterally by the pelvic wall, and posteriorly by a ridge of peritoneum, caused by the ureter, which runs backwards and laterally from the postero-lateral angle of the upper surface of the bladder towards the hypogastric artery. Beneath the floor of this fossa the ductus deferens runs medially towards the genital fossa. The genital fossa lies between the ureteral ridge and the margin of the sacro-genital fold; and the pararectal fossa is between the sacro-genital fold and the side of the rectum. The two pararectal fossæ are continuous with each other across the front of the rectum and form together the recto-vesical excavation. When the rectum is distended the peritoneum of the pararectal fossæ is lifted up to cover the expanding wall of the viscus, the fossæ are obliterated, and the posterior ends of the sacro-genital folds terminate on, or in close relation with, the wall of the rectum. When the bladder is distended the middle part of the sacro-genital fold is also opened out to help to cover the upper part of the fundus of the bladder, but the lateral parts remain. If, however, the bladder and rectum are simultaneously distended the lateral parts of the sacro-genital fold pass from the back of the bladder either to the rectum or to the posterior wall of the pelvis close to the rectum.

and under those conditions the folds in question were formerly

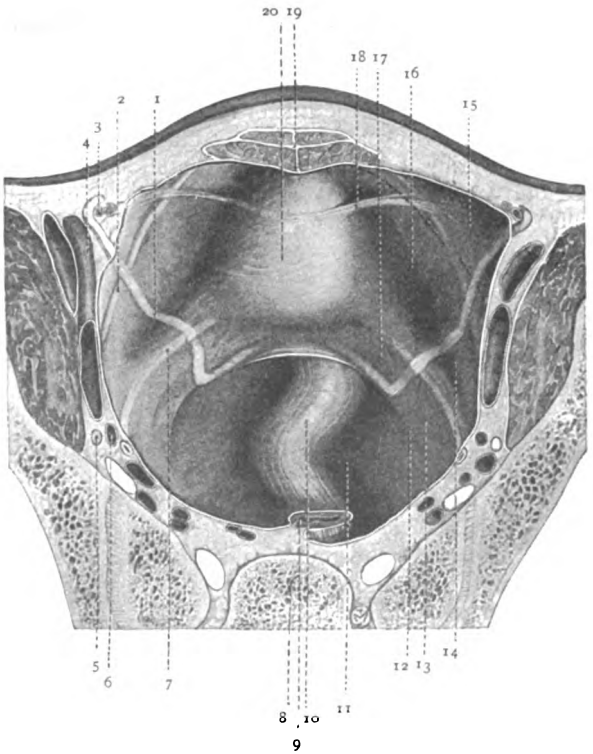


FIG. 215.—The Peritoneum of the Pelvic Cavity.

The upper part of the posterior wall of the pelvis minor has been removed to show more clearly the disposition of the peritoneum within its cavity. (Dixon and Birmingham.)

1. Ductus deferens.
2. Umbilical artery.
3. Inferior epigastric artery.
4. External iliac vessels.
5. Obturator nerve.
6. Umbilical artery.
7. Ureter.
8. Third sacral vertebra.
9. Lower part of pelvic meso-colon.
10. Rectum.
11. Pararectal fossa.
12. Sacro-genital fold.
13. Lateral portion of middle fossa.
14. Genital fossa.
15. Lateral inguinal fovea.
16. Paravesical fossa.
17. Median portion of middle fossa.
18. Plica vesicalis transversa.
19. Urachus.
20. Bladder.

described as the *recto-vesical folds* or *posterior false ligaments* of the bladder.

**The False Ligaments of the Bladder.**—The false ligaments of the bladder are parts of the pelvic peritoneum. When the bladder is empty, a fold extends from the anterior end of its upper surface, *i.e.*, the *apex* of the bladder, to the posterior surface of the anterior abdominal wall. This is the *plica umbilicalis media* (O.T. *superior false ligament*) of the bladder. It separates the right and left paravesical and supravesical fossæ from each other, and is caused by the projection of the *ligamentum umbilicale medium*, consisting of the urachus, a fibrous remnant of part of the cloaca. The peritoneum extending from each lateral border of the upper surface of the bladder to the side wall of the pelvis constitutes a *lateral false ligament*, and forms the floor of the corresponding paravesical fossa. Not uncommonly each lateral false ligament and the peritoneum on the upper surface of the bladder are divided into anterior and posterior portions by a transverse fold, the *plica vesicalis transversa*, which crosses from one side of the superior aperture of the pelvis to the other. It is questionable if the term *posterior false ligament* should be retained; it is still applied, however, to the remnants of the sacro-genital folds which extend from the back of the distended bladder to the sides of the distended rectum, or to the front of the sacrum.

*Dissection from above.*—All the peritoneum above the level of the pelvic brim should now be removed, care being taken not to injure or displace the ureter or the ductus deferens. The dissector should then stitch the ureter to the artery it crosses at the brim, common or external iliac as the case may be. He must also stitch the ductus deferens to the external iliac artery, close to the origin of the inferior epigastric branch. This being done, he must carefully detach the peritoneum from the extraperitoneal fat, separating any adhesions with the knife. The separation should be commenced at the brim, and be carried medially until the root of the pelvic meso-colon, the side of the rectum, and the lateral border of the upper surface of the bladder are reached. When this has been done on both sides, the dissector should displace the bladder backwards, and pass his finger down between the viscus and the symphysis, through the soft extraperitoneal fat, till it meets a resisting membrane. This is the visceral layer of the pelvic fascia or upper layer of the fascia of the pelvic diaphragm. By his sense of touch the dissector will recognise not only that it is attached to the lower part of the posterior surface of the symphysis, but also that two thickened bands of its substance extend backwards, one on each side of the median plane, from the back of the symphysis to the anterior border of the bladder. These bands are the *anterior true ligaments* of the bladder or the medial *pubo-prostatic ligaments*, the latter name indicating that, in the male, they are placed above the prostate. Having satisfied himself regarding these ligaments, the dissector should carry his finger backwards, between the bladder and the wall of the pelvis, displacing the soft fat, until he touches the ureter. The region which he will thus investigate is the lower and anterior part of a large area, known as the *cave of Retzius*, in which the extraperitoneal fat has very slight attachment either to the peritoneum or to the pelvic fascia, and in which, therefore, it is very easily displaced. The area extends from the hypogastric artery of one side round the front of the bladder to the hypogastric artery of the opposite side, downwards to the visceral layer of the pelvic fascia, and upwards, between the umbilical (O.T. obliterated hypogastric) arteries, to the umbilicus. The facility with which he displaces the fatty tissue should demonstrate to the dissector how easy, in this area, will be the spread of urine effused from a ruptured bladder, or of blood running from a divided artery, or of effusions due to inflammatory conditions. The dissector must now remove the extraperitoneal fat first from the ductus deferens, then from

the region of the ureter, and afterwards from the hypogastric vessels and their branches and tributaries. Whilst this is being done, the obturator nerve will be brought into view to the lateral side of the ureter, and below the level of the umbilical artery. Whilst removing the fat and displaying the structures embedded in its substance, the dissector must be careful not to injure either the parietal or the visceral pelvic fascia. He will find that some of the branches of the hypogastric artery pierce the parietal fascia as they leave the pelvis, and that the visceral branches, the rectum, the ureter, and the ductus deferens, pass into the substance of the visceral layer.

When the dissection is completed the student should note the relative positions of the structures he has exposed. The ductus deferens will be seen passing downwards and backwards, on the side wall of the pelvis, till it meets the ureter, which is passing downwards, from the junction of the lateral and posterior walls of the cavity and along the front of the hypogastric artery. Before they meet, both the ductus deferens and the ureter turn medially and, medial to the point of crossing, they both enter the visceral layer of the pelvic fascia. Behind the ureter is the hypogastric artery, dividing into its anterior and posterior divisions. Running forwards on the lateral side of the ureter and the ductus deferens are the umbilical, the obturator, the middle and inferior vesical, and, not uncommonly, the middle hæmorrhoidal branches of the anterior division of the hypogastric artery. Springing from the umbilical artery are one or more superior vesical arteries, whilst below the umbilical artery and above the obturator artery is the obturator nerve, which pierces the parietal fascia at the back of the pelvis and runs forwards, above the corresponding artery and vein, to the obturator canal. Behind the ureter the lateral sacral branches and the gluteal continuation of the posterior division of the hypogastric artery will be seen piercing the pelvic fascia, and when the posterior division of the artery is displaced medially its ilio-lumbar branch will be found. The hypogastric vein lies along the posterior border of the artery, and those of its tributaries which correspond to the anterior branches of the artery pass, usually, to the medial side of the anterior division of the artery on their way to the main vein. There is no vein with the umbilical artery or its superior vesical branch. As a rule only one vein accompanies the obturator artery, but the inferior vesical and middle hæmorrhoidal veins are usually numerous, and, as they pass to their termination, they ensheathe the lower part of the

ureter. The lateral sacral and gluteal veins end in the hypogastric vein, but the ilio-lumbar vein is, usually, a tributary of the common iliac vein.

**Endo-Pelvic Fascia.**—When the dissector has studied the general position of the structures exposed by the removal of

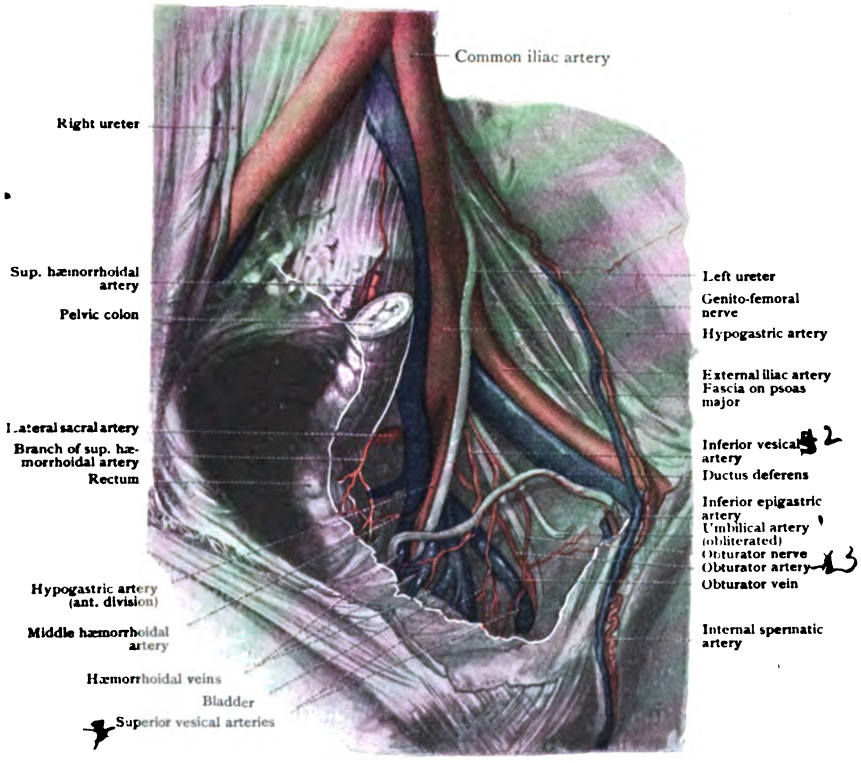


FIG. 216.—The Structures exposed in the left half of the Pelvis by the removal of the peritoneum and extraperitoneal fat.

the peritoneum and the extraperitoneal fat of the pelvis, he should turn his attention to the endo-pelvic fascia. It consists of two main parts: a parietal part, which forms part of the pelvic wall, and a diaphragmatic part, which covers the upper and lower surfaces of the pelvic diaphragm. The upper fascia of the diaphragm is known as the *visceral layer*, because

it enters into intimate relationship with the pelvic viscera. The visceral part stretches across the cavity and helps to separate the perineum from the remainder of the pelvis. If the upper part of the parietal layer is examined it will be found that it is continuous at the pelvic brim with the fascia on the psoas major muscle, from which it descends to the level of a line drawn from the lower part of the back of the body of the pubis to the spine of the ischium. At this level the visceral layer springs from the parietal layer, its origin serving to separate the latter into lower and upper parts. If the upper part of the parietal portion is traced backwards it will be found to extend round the lateral side of the hypogastric vessels and across the front of the sacrum, behind the pelvic meso-colon and the rectum, to the opposite side. If it is traced forwards, a short distance below the brim, it will be found to blend with the periosteum on the back of the superior ramus of the pubis, along an oblique line which descends from the junction of the middle third with the lower third of the external iliac artery to the upper margin of the obturator foramen. Below the superior ramus of the pubis it forms a distinct thickened border which bridges across the upper part of the obturator foramen, and forms the lower boundary of the commencement of the obturator canal, by which the obturator artery and nerve leave the pelvis. To the medial side of the obturator foramen the parietal fascia blends with the periosteum on the back of the body of the pubis, along a line which descends towards the apex of the pubic arch and passes below the line of attachment of the visceral layer. The parietal layer is deficient, therefore, in the region of the upper part of the anterior wall of the pelvis, and as its anterior margin blends with the periosteum on the pubis any effusion lying external to the fascia will be prevented from extending forwards to the anterior part of the pelvis.

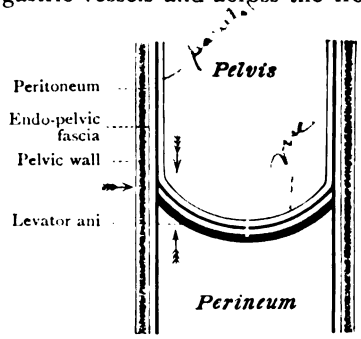


FIG. 217.—Diagram of the Pelvic Wall and Pelvic Floor.

The lower part of the parietal layer should next be examined. In the dissection of the perineum the student saw that the lower part of the parietal pelvic fascia formed the lateral wall of the ischio-rectal fossa, and that it blended, immediately below the origin of the levator ani, with the lower layer of the fascia of the pelvic diaphragm, which covers the lower surfaces of the levator ani and the coccygeus (anal fascia). He saw also that, in the anterior part of the peri-

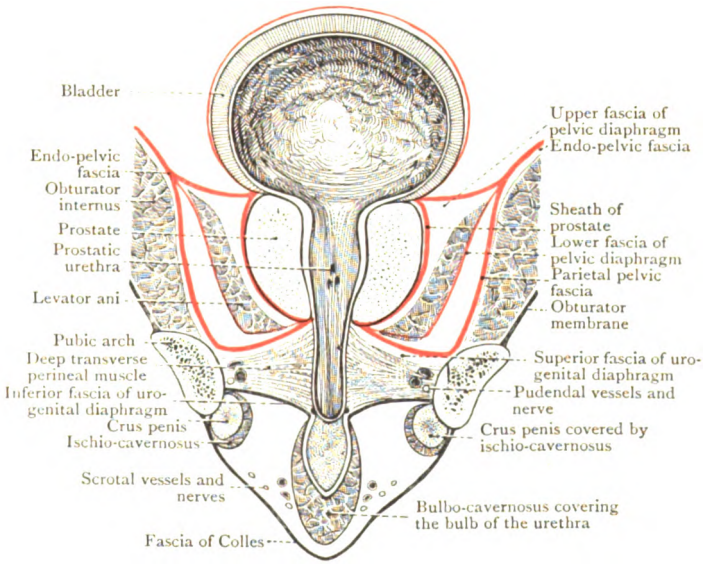


FIG. 218.—Vertical transverse section through the Bladder, Prostate, and Pubic Arch to show the arrangement of the Endo-pelvic Fascia: schematic. The endo-pelvic fascia is depicted in red.

neum, the parietal fascia extended medially, as the *superior fascia of the urogenital diaphragm*, from the margin of the pubic arch to the side of the urethra, where it not only blended with the fascia coming from the opposite side, but also became continuous, round the anterior border of the levator ani, with the fascia on the upper surface of that muscle, that is, with the visceral layer of the pelvic fascia. To display the details of the visceral layer of the fascia the final stages of the dissection of the perineum must now be completed.

*Dissection.*—The dissector must carefully define the anterior borders of the levatores ani muscles, and then he must cut boldly through the centre of the perineum between the bulb and the anal orifice until he reaches the fascial interval between the posterior surface of the prostate and the front of the lower part of the rectum. When the interval is reached the knife may be discarded and the forefinger introduced into the space and carried from side to side. In this way it is possible to demonstrate that the visceral layer of the pelvic fascia, as it descends on the levator ani, divides into a lower layer, which passes behind the rectum, and a layer which passes between the rectum and the prostate. (Fig. 220, p. 567.)

The right levator must now be divided, from before backwards, about midway between its origin from the parietal fascia and its insertion into the wall of the anal passage, care being taken to avoid injury to the fascia on its upper surface. The lower part of the muscle should be followed to

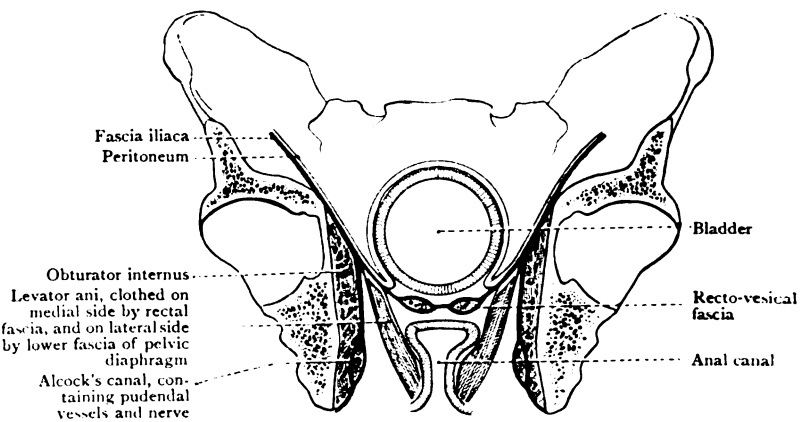
Fascia iliaca
Peritoneum
Bladder
Obturator internus
Levator ani, clothed on medial side by rectal fascia, and on lateral side by lower fascia of pelvic diaphragm
Alcock's canal, containing pudendal vessels and nerve
Recto-vesical fascia
Anal canal

FIG. 219.—Diagram of the Endo-pelvic Fascia. The pelvis is divided in a frontal plane and the pelvic fascia is represented in red.

its insertion into the wall of the anal canal, and the mode of insertion between the internal and the external sphincters noted. The upper part should be turned laterally and the fingers of the left hand passed along its upper surface till its origin from the fascia is reached. When this has been done the dissector will find that the only structure which separates his fingers from the cavity of the pelvis is the upper layer of the fascia of the pelvic diaphragm (*visceral layer of the pelvic fascia*), which extends from the parietal fascia, at the level of the origin of the levator ani, and passes medially to the walls of the viscera, which it ensheathes. If the dissector will now place the fingers of one hand on the upper surface of the visceral fascia and those of the other hand on the lower surface, and then carry both hands medially, he will find that the one hand passes on to the upper surface of the bladder and the other behind the rectum. He will thus demonstrate that as the visceral fascia crosses the pelvis from side to side it separates into an upper or vesical layer and a lower or rectal layer. The third or recto-vesical layer, which covers the posterior surface of the prostate, and separates the gland from the rectum, has already

been demonstrated. The recto-vesical layer must now be incised, in the median plane, on the posterior surface of the prostate and each half must be turned laterally. As the borders of the prostate are approached a plexus of veins will be exposed on each side, and immediately beyond the plexus the recto-vesical layer of the fascia will be found to blend with the vesical layer, which passes over the upper surface of the prostate. The ductus deferentes and the seminal vesicles will be exposed when the reflection of the recto-vesical layer is carried backwards beyond the prostate (Fig. 220).

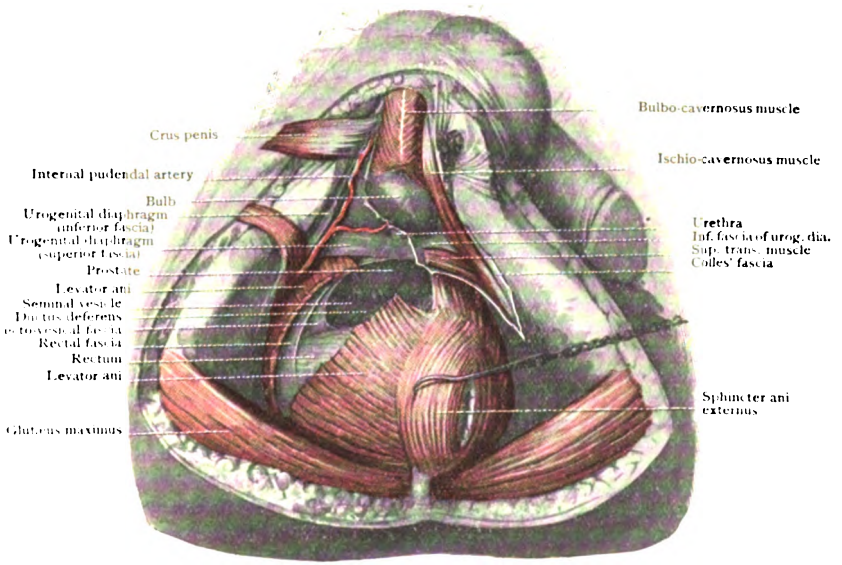


FIG. 220.—Dissection to expose the Prostate from the Perineum.

**The True Ligaments of the Bladder.**—There are five so-called true ligaments of the bladder: two *lateral*, the lateral pubo-vesical ligaments; two *anterior*, the medial pubo-vesical ligaments; and one *superior*. The lateral are the lateral parts of the vesical layer of pelvic fascia. The anterior are two thickenings of the same layer, one on each side of the median plane, in front of the bladder; they contain smooth muscle fibres which pass from the bladder to the back of the pubic bones at the margins of the symphysis. The superior, the lig. umbilicale medium, is formed by the urachus.

During the various stages of this dissection the student

should repeatedly convince himself, by introducing the index finger of his right hand into the rectum and that of his left hand into the pelvis, that he can quite easily define the outlines of the prostate and the seminal vesicles by a process of palpation; and when he has completed the dissection he should note that he has demonstrated that the visceral layer of the pelvic fascia, which is single laterally, is cleft medially

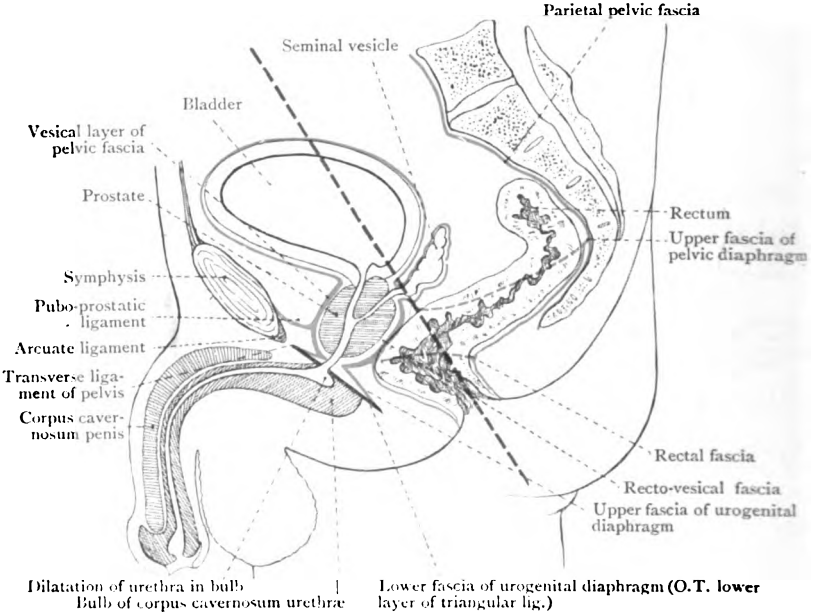


FIG. 221.—Diagram of the Pelvic Fascia as seen in a sagittal section of the Pelvis. Pelvic fascia represented in red.

into three lamellæ by the interposition of the rectum between a middle and a lower layer, and the interposition of the bladder and the prostate between the middle and an upper layer. There are two compartments, therefore, in the substance of the fascia: a lower or posterior, which contains the rectum; and an upper or anterior, in which lie the bladder, the prostate, the seminal vesicles, and the lower parts of the ductus deferentes.

*Dissection.*—The suspensory ligament of the penis must be detached from the front of the symphysis. The left crus of the penis has already

been separated, and the right crus should now be cut away from the margin of the pubic arch and the inferior fascia of the uro-genital diaphragm, care being taken to avoid injuring the latter. As the penis is turned down, the median and single deep dorsal vein will be seen to pass backwards, between the arcuate ligament and the upper border of the *transverse ligament of the pelvis* (which is the thickened upper border of the fasciæ

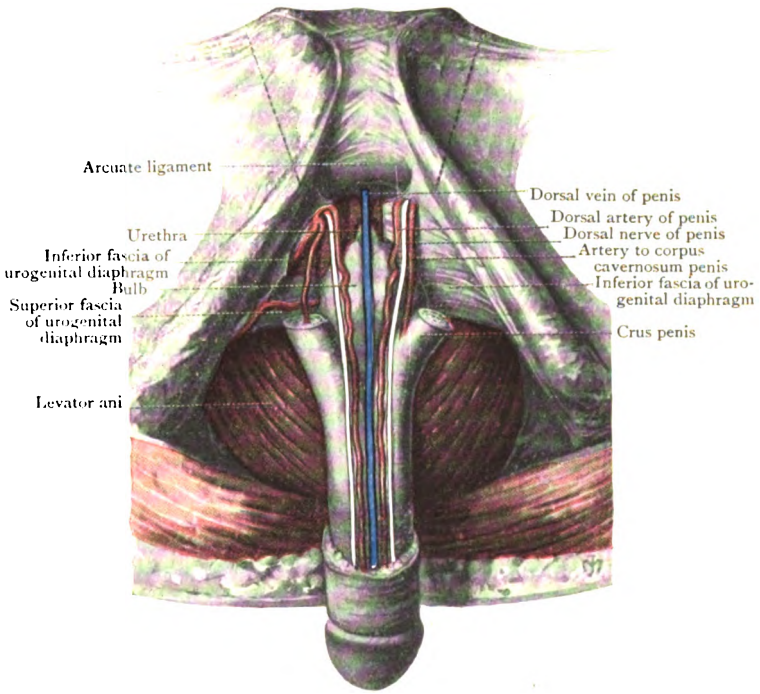


FIG. 222.—Dissection to show the Dorsal Vessels and Nerves of the Penis and their relations to the fasciæ of the Urogenital Diaphragm. The upper part of the deep transverse perineal muscle has been left between the two fasciæ. The lower part has been removed to expose the superior fascia. The lines of the saw-cuts to be made at the next stage of dissection are indicated on the bones by the dotted lines.

of the urogenital diaphragm), into the pelvis, where it will be followed at a later stage. The dorsal artery and the dorsal nerve of the penis pierce the inferior fascia of the urogenital diaphragm near the upper part of the margin of the pubic arch, and the artery to the corpus cavernosum frequently passes through the diaphragm immediately to the lateral side of the nerve (Fig. 222). The proximal parts of these structures have already been seen in the dissection of the perineum. The bulb of the corpus cavernosum urethræ should now be carefully detached from the upper part of the inferior

fascia of the urogenital diaphragm and turned downwards until the urethra is brought into view. It pierces the upper part of the fascia in the median plane and passes at once into the bulb.

The muscles and fascia must now be detached from the anterior surfaces and upper borders of the bodies of the pubic bones, and from the upper parts of the pubic rami. Then the bones must be cut through, with the saw, on each side, along a line running from below the attachment of the arcuate ligament to the lateral side of the pubic tubercle (see Fig. 222). By these saw-cuts a considerable part of the anterior wall of the pelvis is isolated, and it can be removed when the vesical layer of the endo-pelvic fascia has been detached from its posterior surface. Having been removed, it must be kept for the examination of the inter-pubic joint. Whilst the bone is being removed care must be taken to avoid injuring the dorsal vein of the penis. After the bone is removed the dissector will see the anterior border of the vesical layer of the endo-pelvic fascia, which has been detached from the back of the pubis. In this fascia he will readily recognise the thickened bands of the pubo-prostatic ligaments. The vesical layer must now be divided in the median plane and turned laterally to each side. Whilst this is being done it will be noticed that above the prostate the vesical layer is gradually lost on the anterior border and infero-lateral surfaces of the bladder (Fig. 223). When the fascia has been turned laterally to its junction with the recto-vesical layer, already displayed from below, the dorsal vein of the penis must be followed backwards. It divides, immediately after entering the pelvis, beneath the vesical layer of fascia, into right and left branches which join the corresponding parts of the pudendal (O.T. *prostatic*) venous plexus.

The dissector should notice that, by the removal of the bone in the region of the symphysis, he has exposed not only the structures already noted, but also the whole of the anterior border of the bladder and parts of its infero-lateral surfaces. If he now replaces the pelvic peritoneum, he will find that it has no relation to the border and surfaces mentioned; they lie entirely below the level of the peritoneum. They form the posterior boundary of the lower part of the cave of Retzius, and lie in relation with the anterior and antero-lateral parts of the pelvic wall, from which they are separated by the extra-peritoneal fatty tissue which was removed at an earlier stage of the dissection. The dissector has now seen three surfaces of the bladder—the superior surface, covered with peritoneum, and the two infero-lateral surfaces. The bladder possesses also a fourth surface, the fundus or base, which lies in relation with the deferent ducts, the seminal vesicles, and to a less extent with the lower part of the anterior wall of the rectum. This surface and the interior of the bladder should now be investigated.

*Dissection.*—Enter the knife through the anterior border of the bladder, a little below its upper extremity, and carry it backwards first on one side and then on the other, just below the upper border of each infero-lateral

surface. When the incisions have been made, push the upper surface of the bladder backwards and press the infero-lateral surfaces downwards and forwards. An excellent view of the interior will thus be obtained, and, when its surface has been sponged, the mucous lining and the orifices may be examined, and the relations of the base may be investigated. If it is necessary, the anterior border may be divided vertically from the apex of the bladder to the upper border of the prostate.

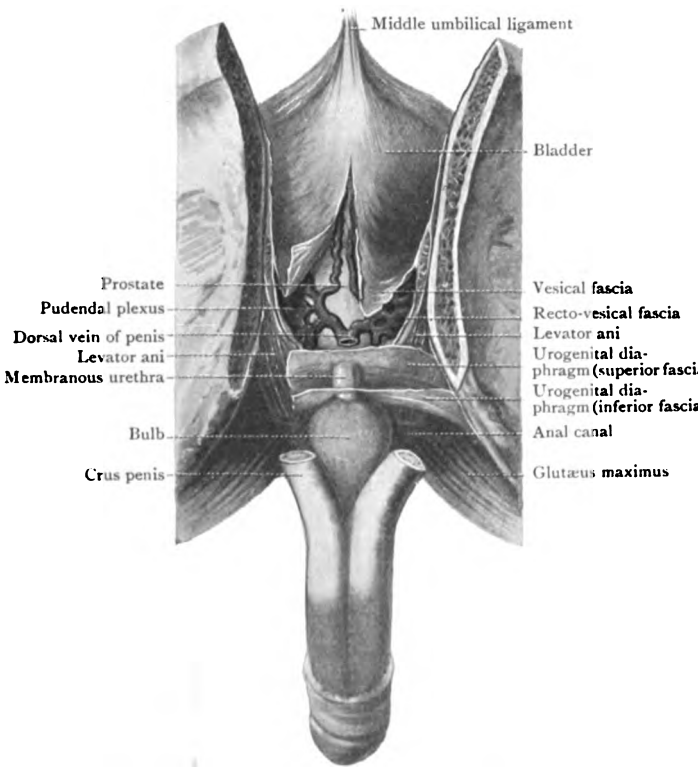


FIG. 223.—Dissection of the Bladder, the Endo-Pelvic Fascia, and the Prostate from the front.

The mucous membrane is rugose, when the bladder is empty, over the whole of the inner surface, except a small triangular area on the basal wall. The rugosity is due to the loose manner in which the membrane is bound to the muscular coat by the layer of submucous tissue. When the

bladder is distended the folds are effaced, and the mucous lining becomes smooth throughout.

**Orifices and Trigone of the Bladder.**—There are three orifices in the bladder wall—two orifices of inlet, the orifices of the ureters; and one orifice of outlet, the orifice of the

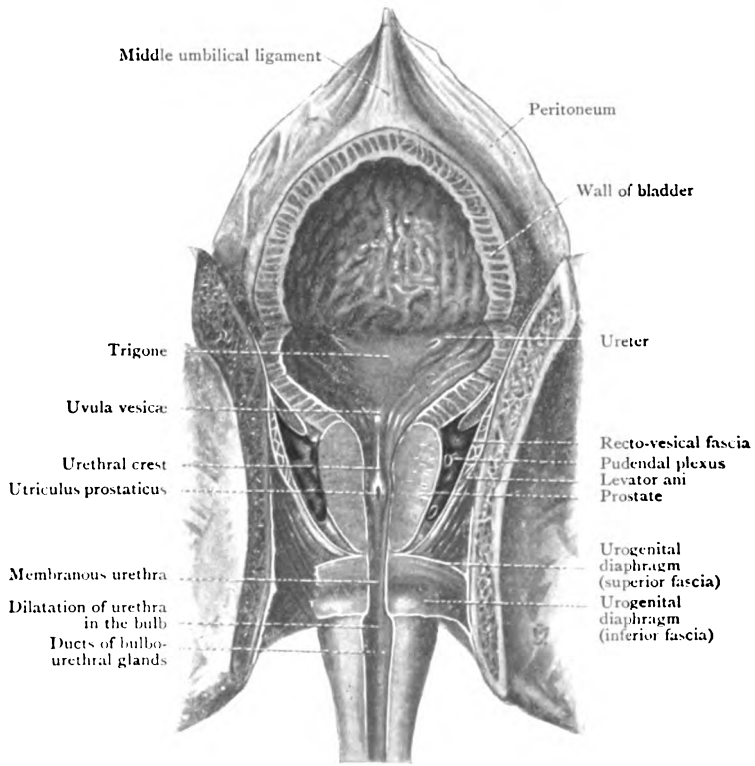


FIG. 224.—Dissection of Bladder and Urethra from the front.

urethra. They are situated at the three angles of the triangular smooth area of the mucous membrane which is known as the *Trigonum Vesicæ* (*Trigone of the Bladder*). In this area the mucous membrane is always smooth, whether the bladder is distended or empty, on account of the close connection which exists between the mucous and muscular coats. At the anterior angle of the area is the internal

urethral orifice, semilunar or V-shaped in outline, with a slightly elevated posterior lip, which is known as the *uvula* of the bladder (Figs. 224 and 225). The elevation indicates the position of the middle lobe of the prostate gland below. When the bladder is empty and contracted a number of radial ridges of mucous membrane diverge from the margins of the orifice.

The ureteral orifices lie at the posterior angles of the trigone. They are small semilunar slits, and are frequently connected together by a transverse bar of mucous membrane (*torus vesicalis*) which covers a bar of muscle. This ridge is sometimes spoken of as Mercier's bar. Not uncommonly a ridge of mucous membrane will be found connecting each ureter with the urethra, and the muscular bands which underlie the latter ridges are known as Bell's muscles. Probes should be passed along the ureters to demonstrate the obliquity with which the ducts pass through the bladder wall. It will be found that each ureter runs through the substance of the bladder wall for about three-quarters of an inch (20 mm.). This arrangement serves the purpose of a valve which allows urine to pass easily into the bladder but tends to prevent its backward flow. When the bladder is distended the openings of the ureters are about an inch and a half apart (35 mm.), and about the same distance from the orifice of the urethra, but when the viscus is empty and contracted the distance between the orifices is reduced to about one inch (25 mm.) in each case.

The dissector should now investigate the relations of the fundus of the bladder by palpation. Keeping one index finger in the bladder and passing the other into the rectum, he will find that he can distinguish the prostate below and around the internal urethral orifice. Above the level of the prostate he can feel the thick walls of the deferent ducts, one on each side of the median plane, and more laterally he will recognise the convoluted coils of the seminal vesicles. If he passes his finger upwards, along the median plane, he will find that the deferent ducts diverge, and that between them the rectum and bladder lie in contact. The area in which this contact occurs corresponds with the posterior part of the trigone, and varies considerably in size. When the bladder is empty the area is small or absent; but it increases considerably when the bladder is distended, and at one

time it was a common surgical procedure to puncture the bladder through this region for the purpose of relieving over-distension.

*Dissection.*—When the dissector has satisfied himself regarding the relations of the base of the bladder and the possibility of easily distinguishing

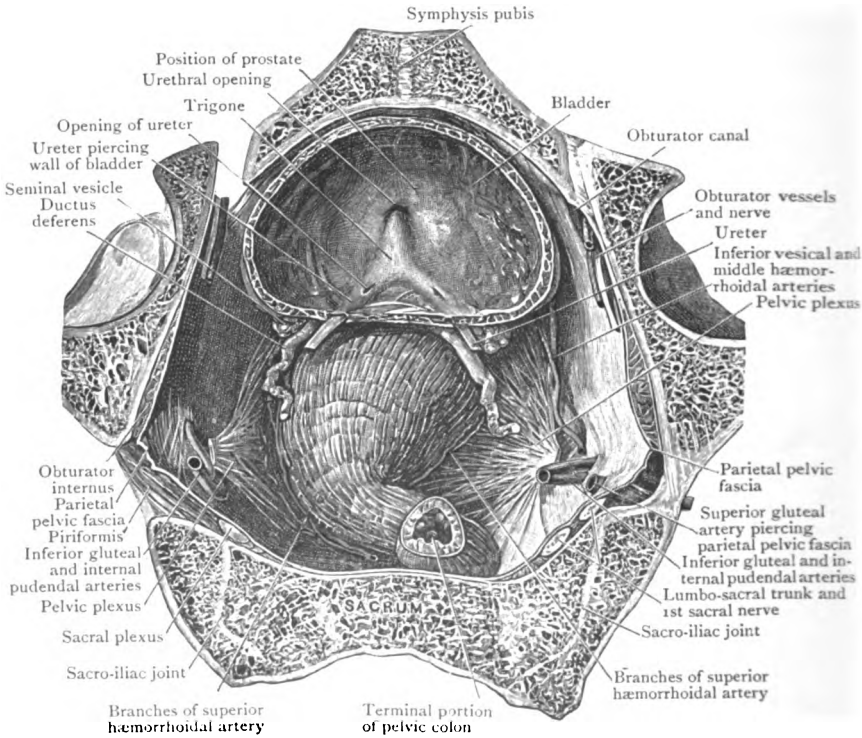


FIG. 225.—Oblique Section from above downwards and forwards through the Pelvis. The peritoneum has been removed so as to expose the viscera and the parietal pelvic fascia clothing the pelvic wall.

them with the finger through the rectal wall, he should introduce a blunt-pointed knife, or a pair of scissors, through the internal urethral orifice into the urethra, and lay the canal open by dividing its dorsal wall from the bladder to the end of the penis.

**Urethra Virilis.**—The male urethra is the canal through which the urine, the semen, and the secretions of the seminal vesicles, the prostate, and bulbo-urethral glands

(Cowper's), are emitted from the body. It commences at the internal urethral orifice of the urinary bladder and ends on the glans penis. Its average length is about eight or nine inches (200-225 mm.). It is customary to divide the canal into three parts, from the different characters of the structures which it traverses. The first part, *pars prostatica urethræ*, is contained within the substance of the prostate gland; the second part, *pars membranacea urethræ*, extends from the prostate to the bulb of the corpus cavernosum urethræ, and is surrounded, between the fasciæ of the urogenital diaphragm, by the fibres of the sphincter muscle of the membranous urethra; the third part, *pars cavernosa urethræ*, traverses the entire length of the corpus cavernosum urethræ.

**Pars Prostatica Urethræ.**—The prostatic part of the urethra is about one inch and a quarter in length (30 mm.). It is fusiform, being wider in the middle than at either its commencement or its termination. It traverses the prostate in front of its so-called middle lobe, and takes a very nearly vertical course through its substance. It is the widest, and at the same time the most dilatable part of the canal.

In connection with the posterior wall or floor of the prostatic portion of the urethra there are certain important features to be noted. The mucous membrane along the median plane is raised into a prominent ridge called the *crista urethræ* or urethral crest. This commences a short distance below the internal orifice of the urethra in the bladder, and extends downwards for about three-quarters of an inch. At first it increases gradually in height, until it forms a prominent eminence, the *colliculus seminalis* or seminal hillock; then its height suddenly diminishes, and, finally, the ridge fades away into the membranous part of the canal. On each side of the urethral crest the floor of the urethra is a longitudinal depression, termed the *prostatic sinus*, into which the numerous prostatic ducts open. The dissector may render these evident by squeezing the prostate, when fluid will be found to exude into the sinuses through the ducts. A close inspection of the floor of the urethra, above the crista, will reveal the apertures of the ducts of the so-called middle lobe of the prostate.

Immediately below the seminal hillock the mucous

membrane dips backwards and upwards, forming a small *cul-de-sac* behind the middle lobe of the prostate. This is the *utriculus prostaticus*. Its orifice is narrow, but the recess widens out towards its blind upper end, and its length, which may be gauged with a probe, varies from a quarter to half an inch (6-12 mm.). It is of interest both practically and developmentally,—practically, because it is sometimes large enough to entangle the point of a small catheter or bougie;

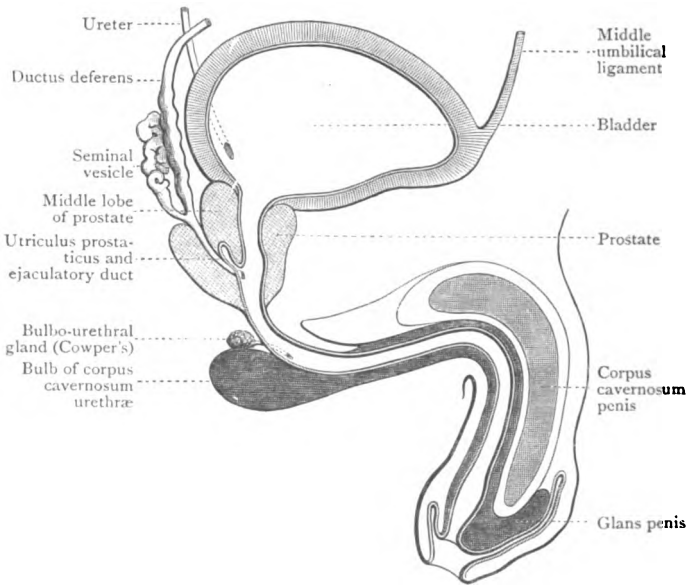


FIG. 226.—Diagram of the Bladder, Urethra, and Penis. (Délépine.)

and developmentally, because it represents, in the male, the vagina and uterus of the female.

On the margins of the orifice of the prostatic utricle the dissector will find the slit-like orifices of the ejaculatory ducts. The ducts themselves run downwards, along the lateral walls of the utricle, between the middle and lateral lobes of the prostate. Bristles should be passed through the apertures into the ducts.

Owing to the projection of the urethral crest from the middle of the floor of the canal a transverse section of the prostatic portion of the urethra presents a crescentic figure—

the convexity of the crescent being directed forwards and the concavity backwards.

The prostate is very liable to become enlarged as old age approaches. When this happens the most important result is the effect exerted on the urethra. If the enlargement is uniform the canal is merely lengthened, but, if excessive growth is localised the enlarged part may compress the urethra and interfere with micturition. When the middle lobe enlarges it projects upwards and forwards, over the orifice of the urethra, and forms a kind of ball valve, which may prevent the exit of urine through the internal urethral orifice. It is only in pathological conditions that the so-called middle lobe becomes a very distinct and more or less independent part of the organ. During health it is marked off from the rest of the prostate merely by the utricle and by the passage of the ejaculatory ducts through the substance of the gland.

**Pars Membranacea Urethræ.**—The membranous part of the urethra is the narrowest and the shortest division of the urethra. It extends from the prostate to the bulb of the urethra, curving gently downwards and forwards, behind the lower border of the symphysis pubis, from which it is distant about one inch (25 mm.). Its length is barely three-quarters of an inch; and the concavity of its curve is directed forwards and upwards. Throughout its entire length it is enveloped by the fibres of the sphincter urethræ membranaceæ (O.T. compressor urethræ) muscle. Towards its termination the bulbo-urethral glands are placed behind it—one on each side.

The membranous part of the urethra has important relations to the urogenital diaphragm and to the pelvic fascia. As it emerges from the prostate, it pierces the parietal pelvic fascia (*i.e.* the upper fascia of the urogenital diaphragm), and the margins of the aperture through which it passes are carried backwards to become continuous with the sheath of the prostate. At its termination it pierces the inferior fascia of the urogenital diaphragm, about an inch below the symphysis. It lies therefore in the interval between these two fasciæ.

The mucous membrane of the membranous part of the urethra is directly surrounded by a thin coat of erectile tissue, and this is embraced by a muscular tunic composed of involuntary fibres arranged circularly.

**Pars Cavernosa Urethræ** (O.T. **Spongy Portion of Urethra**).—This is the longest division of the urethra. It is embedded in the substance of the corpus cavernosum urethræ, and its calibre varies considerably at different points. In each expansion of the corpus cavernosum urethræ, viz., the bulb posteriorly and the glans anteriorly, there is a corresponding dilatation of the urethra; between the dilatations the canal is of uniform diameter, and slightly wider than the membranous portion. The dilatation of the urethra in the glans is termed the *fossa navicularis*. At its orifice, the *external urethral orifice*, the canal is much contracted, and is even narrower than any part of the membranous portion. The orifice is a vertical slit, and its lower end is connected with the prepuce by a fold of skin, termed the *frenulum præputii*.

In the bulb and in the glans penis the erectile tissue of the corpus cavernosum urethræ is disposed very unequally around the urethra. In the bulb it is massed chiefly below or behind the tube, whilst in the glans it is placed chiefly in front and on each side, a very thin layer lying posteriorly.

The ducts of the bulbo-urethral glands (O.T. Cowper's) pierce the floor and open into the cavernous part of the urethra about an inch in front of the inferior fascia of the urogenital diaphragm. The orifices are minute and difficult to find, but by making a small hole in the wall of the duct, as it emerges from the gland, and passing a fine bristle along it, the dissector may be able to find the opening in the urethral floor. After piercing the inferior fascia of the urogenital diaphragm the ducts proceed forwards, first in the erectile tissue, and then in the submucous layer, towards their terminations.

The walls of the urethra are always in apposition except when urine is flowing through it, and a transverse section through the spongy portion, except at its anterior part, has the appearance of a transverse slit. In the fossa navicularis, however, the slit becomes vertical, showing that there the side walls are in contact.

**Mucous Membrane of the Urethra.**—The mucous lining of the urethra is continuous posteriorly with that of the bladder, and anteriorly with the integument of the glans penis. It is continuous also with the mucous membrane of the various ducts which open into the urethra. Scattered over its whole surface are the mouths of numerous minute recesses, called *lacunæ urethrales*. As a general rule, their openings

are directed forwards, and they are largest on the dorsal wall, where some are large enough to catch the point of a small catheter or bougie.

**Direction of the Urethral Canal.**—The prostatic portion is directed downwards and very slightly forwards. The membranous part describes a gentle curve behind the symphysis. The concavity of the curve looks forwards and upwards. The cavernous part first ascends, and then curves downwards. The urethra, therefore, in the flaccid condition of the penis, takes a course in which there are two curves, like the letter ∩ placed on its side. When the penis is raised towards the front of the abdomen the curve in the cavernous

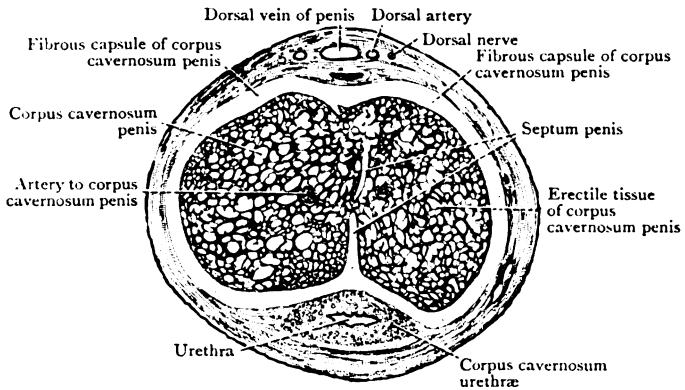


FIG. 227.—Transverse section through the anterior part of the body of the Penis.

part of the canal is obliterated, and there is then only one curve, the concavity of which is directed upwards.

*Dissection.*—The corpus cavernosum penis was separated into two parts by the incision which opened the urethra. Transverse incisions should now be made through each part.

**Structure of the Penis.**—The corpus cavernosum penis consists of a mass of erectile tissue surrounded by a strong fibro-elastic sheath, the *tunica albuginea*. It is more or less completely separated into two halves by a median septum connected with the internal surface of the sheath. This septum receives the name of *septum penis*; and it is frequently termed the *septum pectiniforme* because, in front, it is very imperfect, being broken up by vertical slits into a

number of processes like the teeth of a comb. Fibrous lamellæ and bands proceed from the deep surface of the sheath and join together to form a spongy framework. The interstices of this framework communicate freely with each other and are filled with venous blood. If the dissector squeezes the corpus cavernosum under the tap and washes out the blood, he will gain some idea of its trabecular structure.

The corpus cavernosum urethræ has a similar structure. The enclosing sheath, however, is very delicate, and the trabeculæ are much finer.

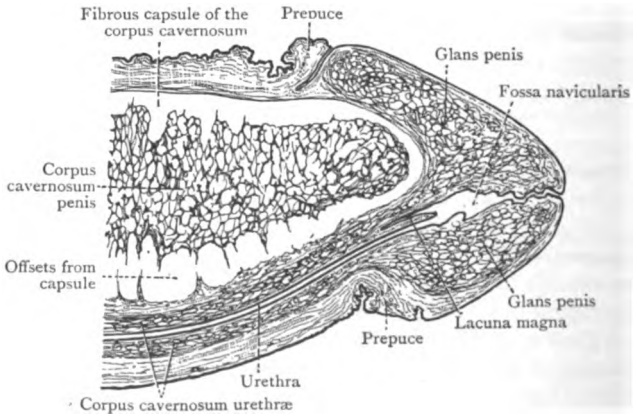


FIG. 228.—Median section through terminal part of the Penis : Prepuce extremely short.

*Dissection.*—Divide the peritoneum along the junction of the superior surface with the fundus of the bladder, and extend the incision to the side-wall of the pelvis, to separate each lateral false ligament from the peritoneum posterior to it. Next, divide the peritoneum in the median plane on the superior surface of the bladder and then divide the superior and posterior walls of the viscus in the median plane. After the division is completed dissect the fundus of the bladder from the deferent ducts and the seminal vesicles, taking care not to injure the ureters as they enter the bladder wall. When the separation is completed note the relations of the bladder and ureters to the more posterior structures.

In the median plane there may be a slight interval between the deferent ducts in which the rectum is separated from the bladder wall merely by the recto-vesical fascia ; this interval, if it is present, corresponds to the middle and back part of the trigone of the bladder. On each side of it the deferent duct and the seminal vesicle separate the bladder

from the anterior surface of the rectum, and, still more laterally, the apical part of the seminal vesicle lies on the levator ani at the side of the rectum, while the lower part of the ureter intervenes between the vesicle and the bladder wall.

*Dissection.*—The anterior part of the prostate was divided when the urethra was opened. The dissector should now divide the posterior part in the median plane. The rectum must then be divided in the median plane, and afterwards the sacrum and coccyx must be divided vertically by a saw-cut, to the left of the middle sacral artery. The separation of the two halves of the pelvis from each other must be completed by the division of any remaining soft parts with the knife. All the subsequent stages of dissection and the examination of the relations of the viscera can be quite conveniently carried out on each side separately.

**Relations of Blood Vessels and Nerves to the Pelvic Fascia.**—The dissector should again note that the blood vessels of the pelvis are placed on the peritoneal surface of the pelvic fascia. It follows, therefore, that all the branches pierce the fascia as they pass to the viscera or as they pass out of the pelvis, and they carry with them prolongations of the fascia which blend with their sheaths. There is one exception to this rule, viz., the obturator artery, which passes over the upper border of the parietal pelvic fascia into the obturator canal. The nerves lie outside the fascia, and, *with the exception of the obturator nerve*, those which are leaving the pelvis do not require to pierce it, but the branches which are to supply the viscera pass through its substance to gain their terminations, and the obturator nerve pierces it posteriorly to gain the interior of the pelvis. This difference in the nerves and blood vessels can be well studied by an examination of the fascia as it passes over the greater sciatic foramen.

The relation of the pelvic blood vessels to the lining fascia is a matter of some practical importance. The margins of the apertures in the fascia through which the vessels pass are usually strengthened by some encircling fibres; still, a portion of gut may make its way through one or other of the openings in the fascia and form a hernia. Sciatic hernia consists of a protrusion of the gut through the greater sciatic foramen. The hernia may be situated either above or below the piriformis. In the former case it escapes through the aperture in the fascia made by the superior gluteal artery, and in the latter, through the aperture for the inferior gluteal artery or the internal pudendal artery.

A hernia may occur through the obturator foramen also (obturator hernia). In this case the gut follows the obturator artery over the upper border of the fascia and through the obturator canal.

**Intestinum Rectum.**—The rectum is the portion of the large intestine which extends from the termination of the

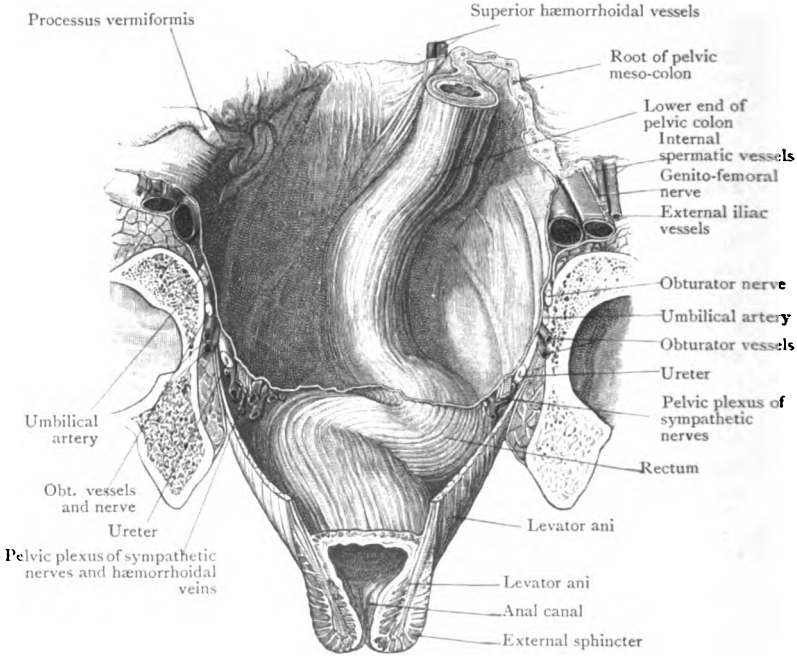


FIG. 229.—Dissection of the Rectum from the front in a specimen hardened by formalin injection. The anterior wall of the pelvis has been removed, and the bladder, prostate, and seminal vesicles have been taken away.

pelvic colon, opposite the middle of the third piece of the sacrum, to the point about one and a half inches in front of the tip of the coccyx, that is, to the apex of the prostate in the male, and to the apex of the perineal body in the female. At this point it bends abruptly backwards, pierces the rectal layer of pelvic fascia, and becomes the anal canal.

The rectum is about five inches long. For the greater part of its length it is adapted to the anterior surface of the

sacrum and coccyx. It is curved, therefore, with the concavity forwards. Beyond the coccyx, the lower inch and a half of the rectum is supported by pelvic floor, formed by

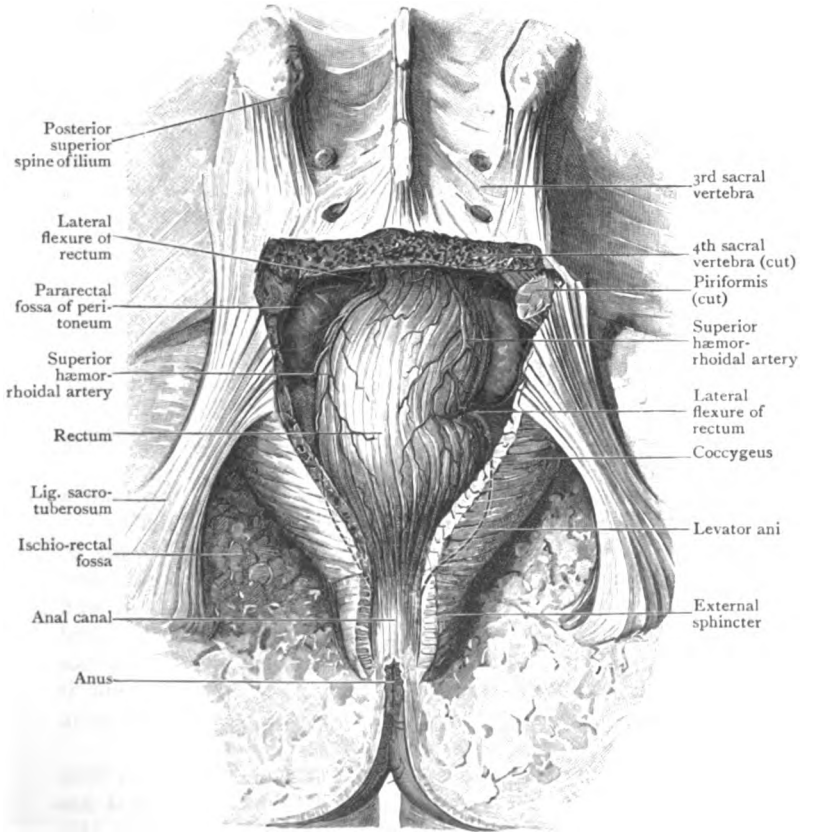


FIG. 230.—Dissection of the Rectum from behind. The sacrum below the 4th sacral vertebra and also the coccyx have been removed. Portions of the levatores ani, coccygei, and external sphincter have also been taken away. (Birmingham.)

the levatores ani muscles, and by the *ano-coccygeal body*. The ano-coccygeal body consists of a dense mass of fibrous tissue which fills the interval between the coccyx and the anus. It receives the insertion of some of the fibres of the levatores

ani muscles. Below the pelvic floor, in this region, lies the posterior part of the sphincter ani externus muscle.

**Peritoneal Relations of the Rectum.**—These relations are of practical importance. In its upper third the gut is clothed with the peritoneum both in front and on the sides; then the peritoneum passes away from the sides, so that in its middle third the gut is covered merely in front; finally, about an inch above the base of the prostate, at the bottom of the recto-vesical excavation, the membrane quits the rectum altogether, and is reflected on to the deferent ducts and the seminal vesicles, as they lie at the fundus of the bladder. The lower third of the rectum is thus altogether devoid of peritoneum. It is separated from the fundus of the bladder and the posterior surface of the prostate by the recto-vesical layer of pelvic fascia; and embedded in the fascia, behind the bladder, are the lower parts of the deferent ducts and the seminal vesicles.

On each side of the upper part of the undistended rectum is a pararectal fossa, and each lateral part of the wall of the lower portion of the gut is supported by the corresponding levator ani muscle (Figs. 229 and 230).

**Flexures of the Rectum.**—The rectum does not take a straight course along the dorsal wall and floor of the pelvis. On the contrary, it presents three abrupt lateral bends or flexures, of which, as a rule, two are convex to the right and one to the left. The sharply marked infoldings of the wall of the gut opposite the flexures are the cause of the so-called *plicæ transversales recti* (O.T. rectal valves) in the interior of the gut. The flexures are best marked when the gut is distended, but even when it is empty they are usually quite obvious.

The rectum lies between the bladder and prostate in front and the sacrum and coccyx behind, and, when empty, it has its anterior wall pressed against its posterior wall, and in this condition its lumen appears, in transverse section, as a transverse slit (Fig. 231). Behind the apex of the prostate, where the gut bends to become the anal canal, its anterior wall, in the distended condition, sometimes shows a slight bulging *cul-de-sac*, called the *ampulla recti*, which descends to a lower level than the prostate.

**Anal Canal.**—This is the narrow slit-like passage, about an inch and a half in length (37 mm.), which leads from the rectum

to the anal orifice. The canal commences opposite the apex of the prostate, and proceeds downwards and backwards. It is totally destitute of peritoneum, but it is clothed and supported by a prolongation of the rectal layer of the pelvic fascia, which it pierces. In addition, it is closely surrounded by

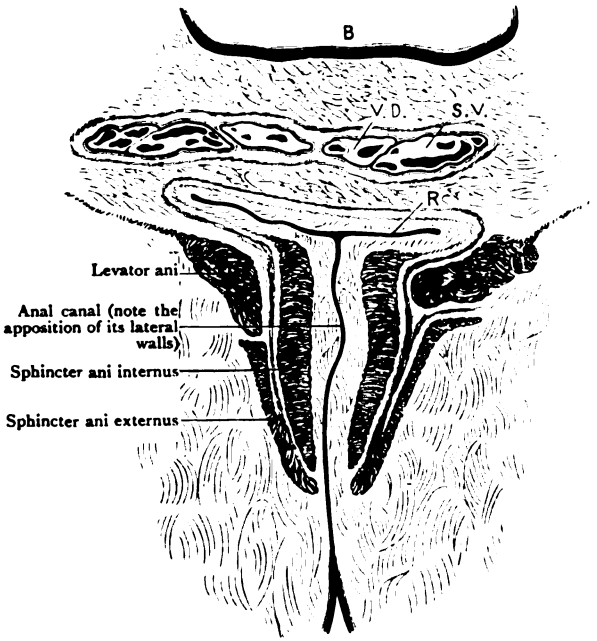


FIG. 231.—Frontal section through the whole length of the Anal Canal. (Symington.)

B. Bladder.
V.D. Ductus deferens.
S.V. Seminal vesicle.
R. Terminal portion of the rectum (note the apposition of its anterior and posterior walls).

strong muscles, which keep close guard over it and allow its side walls to separate from each other only during defæcation. The muscles are:—the *internal sphincter*, developed from the circular muscle of the gut and encircling the canal in nearly its whole length; the *external sphincter*, which surrounds the lower orifice and lower part of the wall; the *levatores ani*, whose medial margins grasp the sides of the canal near its

upper end, and pinch in its walls. The membranous part of the urethra and the bulb of the urethra are in front of the canal, but, on account of the backward inclination of the gut, they are separated from it by a mass of fibro-elastic tissue corresponding to the perineal body of the female. Behind the anal canal is the ano-coccygeal body (Symington).

**Vesica Urinaria.**—The urinary bladder is a hollow viscus, with strong muscular walls, which acts as a temporary reservoir for the urine before it is emitted from the body by the process of micturition. Its form, and, in a great measure, its position and relations, are influenced by the amount of fluid it contains, and by the age of the subject.

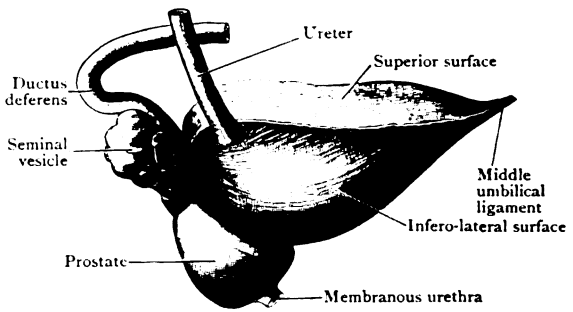


FIG. 232.—Bladder, hardened *in situ*, viewed from the right side. It contained a very small quantity of fluid. (A. F. Dixon.)

The different forms which the bladder assumes, under constantly changing conditions, render its description a matter of serious difficulty. As a rule it is found in the dissecting room with contracted walls and empty. For this reason, and also because our information regarding the empty bladder is more exact, the dissector should study, in the first place, the form it presents when in this condition, and afterwards consider the changes it undergoes as it becomes filled with urine. The following description is based upon the account given by Professor Dixon.

The *empty bladder* lies completely within the cavity of the pelvis. It has the form of a three-sided pyramid, possessing an apex, a base or fundus, and three surfaces, viz.,—a superior surface and two infero-lateral surfaces.

The *fundus* looks backwards towards the rectum, from which

it is separated by—(1) the recto-vesical fascia, (2) the deferent ducts and seminal vesicles, which are enclosed in the fascia, and (3) the peritoneum of the anterior wall of the recto-vesical excavation.

The *apex* is placed in relation with the upper part of the symphysis pubis. It is continuous with a strong fibrous cord, the ligamentum umbilicale medium (*urachus*), which proceeds upwards, on the posterior aspect of the anterior abdominal wall, to the umbilicus. The urachus is the remains of the cephalic part of the ventral section of the cloaca of the embryo.

The *superior surface* looks upwards and backwards, and is completely covered with peritoneum. It supports some coils of small intestine and, as a rule, a coil of the pelvic colon. It is slightly convex; it is triangular in outline, and is bounded by three borders, viz.—two lateral, which diverge from the apex, and a posterior, which separates it from the base. The lateral and posterior borders meet at the posterior angles, and at these angles the ureters enter the bladder wall. Each lateral border is in relation with the side wall of the pelvis, along a line considerably below the level of the deferent ducts and the umbilical artery.

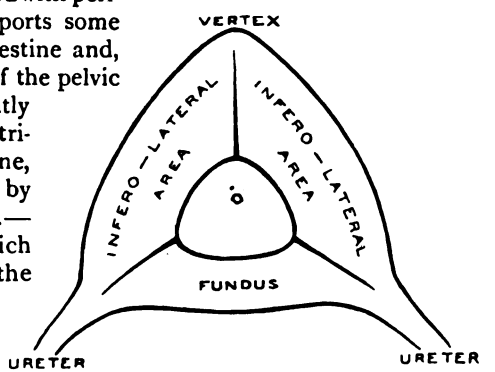


FIG. 233.—Diagram of the Empty Bladder, seen from below. (After A. F. Dixon.)

The *infero-lateral surfaces* are separated from each other by a rounded, anterior border. Each infero-lateral surface forms part of the posterior wall of the cave of Retzius, and is separated by extra-peritoneal fat from the back of the body of the pubic bone and the fascia covering the pelvic surfaces of the obturator internus and the levator ani muscles.

The anterior border, which separates the infero-lateral surfaces, lies behind the symphysis and above and in front of the prostate. It extends downwards and backwards to the internal

urethral orifice, which separates it from the lower end of the fundus. This border is separated from the back of the symphysis and the pubo-prostatic ligaments by the retro-pubic pad of fat, which appears in median sections of the pelvis as a small wedge-shaped mass of soft, fatty areolar tissue (Fig. 235). This pad is part of the extra-peritoneal fat, and adapts itself to the changing conditions of the bladder.

The internal urethral orifice, by which the urine leaves the bladder, is placed at the junction of the fundus with the anterior border, and occupies the most dependent position. It is surrounded by the base of the prostate, which presents

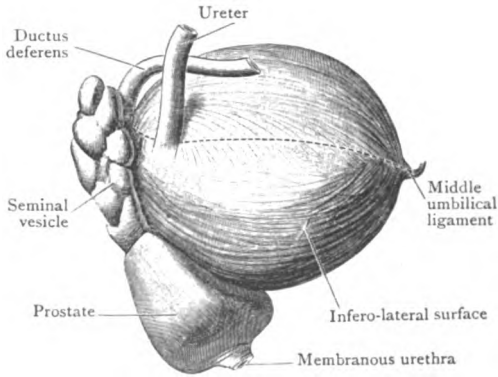


FIG. 234. — Bladder, hardened *in situ*, viewed from the right side. It contained a slightly larger amount of fluid than the specimen depicted in Fig. 232. (A. F. Dixon.)

a structural continuity with the bladder wall. The term *neck* is frequently applied to this region of the bladder.

**Changes in the form of the Bladder as it becomes filled with Urine.**—The neck of the bladder is firmly fixed in position by its attachment to the prostate and by its connection with the upper fascia of the pelvic diaphragm, and the prostate is securely held in place by its strong sheath of pelvic fascia; therefore, as the bladder becomes filled, the internal urethral orifice suffers very little change of position. It is only in cases of excessive distension that any marked change in its level becomes manifest, and under such circumstances the internal urethral orifice sinks, to a certain extent, in the pelvic cavity.

As the bladder fills, its superior wall is raised from the fundus and infero-lateral walls. All its surfaces are increased in area, and the borders, which in the empty bladder intervene between them, become rounded off and finally obliterated. The organ thus becomes oval in form, and the walls, which are thick and firm in the contracted state, become com-

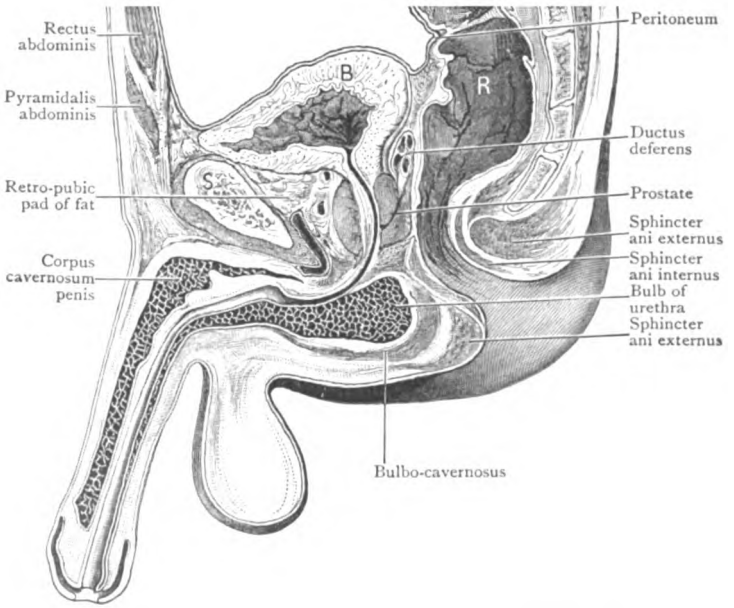


FIG. 235.—Median section through the Pelvis of an Adult Male. The bladder is nearly empty, and the urethra is divided along its whole length.

R. Rectum. S. Symphysis. B. Bladder.

paratively thin. The apex appears above the symphysis pubis, and, as distension goes on, the organ rises higher and higher into the hypogastric region until a considerable extent of its wall becomes applied to the abdominal wall above the pubis. The infero-lateral surfaces of the distending bladder encroach on the paravesical fossæ, and finally obliterate them, thus coming into contact with a greater extent of the side walls of the pelvis.

When the bladder is excessively distended it assumes a

spherical form or, in some cases, an ovoid form, with the large end above (Fig. 236). In the latter case its long axis is no longer horizontal, but oblique, being directed from above downwards and backwards.

When the urine is ejected from the bladder, the superior wall descends till it becomes approximated to the infero-lateral walls and the fundus. The viscus, therefore, becomes flattened from above downwards, and comes to lie again entirely within the cavity of the pelvis minor. When such a bladder is examined in a median section, in a subject from whom the urine was expelled shortly before death, the walls of the bladder are thick and firm, and the lumen of the viscus may be reduced to a mere slit. The part of the lumen which lies behind the internal urethral orifice is called the posterior limb, and the part in front of the orifice, bounded by the approximated superior and infero-lateral walls, is called the anterior limb of the cavity. The anterior limb is long and nearly horizontal. The posterior limb is short and sometimes barely recognisable; further, it is oblique or vertical, and joins the anterior limb at an angle. Viewed in median section, therefore, the lumen of the perfectly empty bladder usually forms two limbs of a Y, the stem being the urethra.

In other cases the empty bladder is firm and rounded, and when divided in the median plane its cavity is seen to present only one limb or slit, which is directly continuous with the urethra.

**Relation of the Peritoneum to the Bladder.**—In the empty bladder only the superior surface is directly covered with peritoneum. The membrane is separated from the upper part of the fundus by the seminal vesicles and the deferent ducts. The infero-lateral surfaces are entirely devoid of peritoneum.

When the bladder fills it rises into the hypogastric region, and it is important to note that the peritoneal reflection from the apex is raised along with the organ, and, as a result, a considerable area of the bladder wall, below the ligamentum umbilicale medium (*urachus*), becomes applied directly to the anterior abdominal wall, no peritoneum intervening. Consequently, in those cases of retention of urine in which a catheter cannot be passed into the bladder through the urethra, relief can be given, without fear of injuring the

peritoneum, by puncturing the bladder, with a trocar and cannula, immediately above the symphysis pubis in the median plane.

Laterally, also, the line of peritoneal reflection is raised until it may appear to leave the lateral border of the bladder along the line of the ductus deferens, as this passes backwards

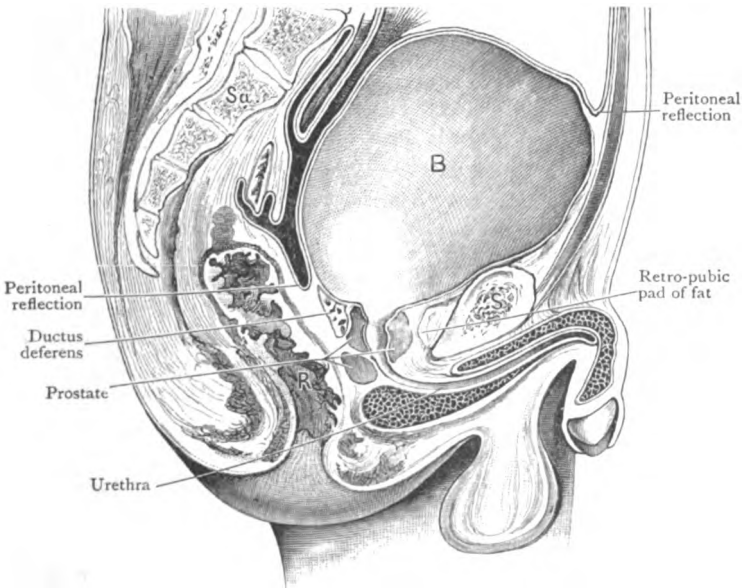


FIG. 236.—Median section through a Male Pelvis in which the Bladder was greatly distended.

B. Bladder. S. Symphysis pubis.
R. Rectum. Sa. Sacrum.

along the side wall of the pelvis, or even as high as the level of the umbilical artery.

Posteriorly, the sacro-genital folds are opened out and obliterated to provide a covering for the expanding basal portion of the bladder, but the level of the reflection of the peritoneum which forms the bottom of the recto-vesical excavation undergoes no change. When the rectum is distended the recto-vesical reflection assumes a higher level, but this is not due to any change in the position of the peritoneum in

relation to the bladder, but to the entire bladder, with the reflection, being pushed upwards and forwards by the expanding gut.

In the new-born infant the bladder differs both in form and in position from the bladder of the adult. It is more or less pyriform, the narrow end passing into the urethra, and there is little or no appearance of a basal portion (Fig. 237). Further, it is placed very much higher. The internal urethral orifice is at the level of the upper border of the symphysis pubis, and the antero-lateral surfaces of the organ, devoid of peritoneum, lie in direct contact with the abdominal wall (Symington). As growth goes on the urethral orifice sinks rapidly from the period of birth up to the fourth year, and

FIG. 237.—Median section through Pelvis of a newly-born full-time Male Infant.

R. Rectum. Sa. Sacrum. S. Symphysis pubis.

more slowly from that period up to the beginning of the ninth year. Then it remains stationary till puberty, after which it sinks slowly till it attains its normal adult position (Disse). It should be noted also that the recto-vesical reflection of peritoneum, in the infant at birth, is at the level of the base of the prostate.

**Ureters.**—Having crossed the lower end of the common iliac artery, or the upper end of the external iliac artery, at the brim of the pelvis minor, the ureter descends, along the front of the hypogastric artery and its anterior division, till the level of the visceral layer of the pelvic fascia is reached, *i.e.*, the level of the spine of the ischium. It then turns medially and forwards on the upper surface of the visceral fascia. In this part of its course it passes deep to the deferent duct, pierces the vesical layer of the visceral fascia, and enters the bladder

wall at the corresponding posterior angle, immediately in front of the upper end of the seminal vesicle. Its point of entry into the bladder wall is about one and a half inches (37 mm.) above the base of the prostate, and about two inches (50 mm.) from its fellow of the opposite side. It is covered on its anterior and median surfaces by the peritoneum, which it raises into a ridge. To its lateral side, from above downwards, lie the umbilical artery, the obturator nerve, the obturator artery, the inferior vesical artery, and, occasionally, the middle hæmorrhoidal artery, but that vessel may pass behind the ureter.

The obturator vein, which lies at a lower level than the

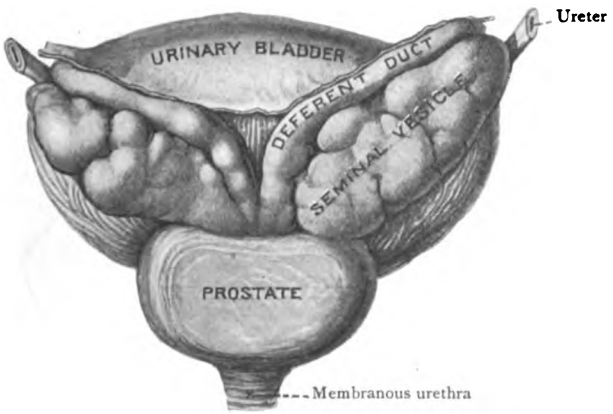


FIG. 238.—Basal aspect of Bladder, Seminal Vesicles, and Prostate, hardened by formalin injection.

artery, may pass either lateral to or medial to the ureter, on its way to the hypogastric vein. As a rule there is no vein with the superior vesical artery. The veins which correspond to the inferior vesical and middle hæmorrhoidal arteries are irregular in number and large in size; they emerge from venous plexuses on the walls of the respective viscera, and enclose the lower part of the ureter in tortuous coils as they pass to the hypogastric vein.

**Prostata.**—The prostate is a solid body, partly glandular and partly muscular, which embraces the neck of the bladder and surrounds the first part of the urethra.

It is conical in shape, with its base directed upwards and

its apex downwards. In size it is variable, but its average dimensions are: *length*, about one and a quarter inches (31 mm.) from base to apex; *breadth*, one and a half inches (37 mm.) from side to side at its broadest part.

*Position.*—The prostate rests upon the anterior aspect of the lowest part of the rectum. Its apex is about an inch and a half distant from the anus, whilst its anterior border lies

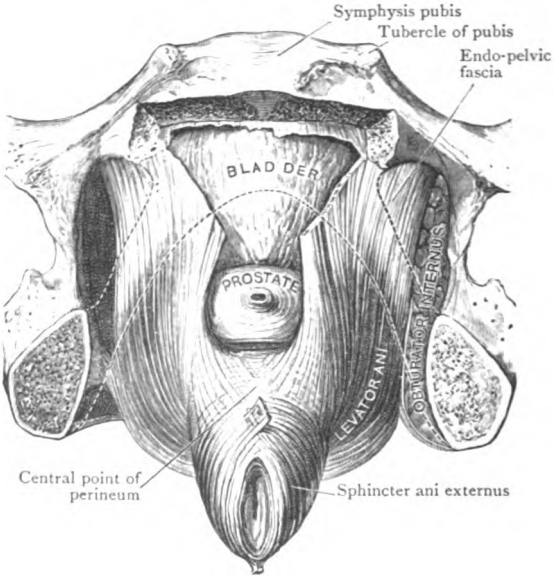


FIG. 239.—Dissection of the two Levatores Ani. The lower part of the pelvis is tilted forwards and the pubic arch has been removed. Both fasciæ of the urogenital diaphragm, the parts in relation to them, and the pubic origins of the levatores ani, have also been taken away. The portion of bone removed is indicated by the dotted lines.

three-quarters of an inch behind the lower part of the symphysis pubis. As already mentioned, the prostate is enclosed in a strong fibrous *sheath*, derived from the pelvic fascia. This sheath is firmly fixed not only by the pubo-prostatic ligaments, which form a part of it, but also, at the apex of the gland, by the continuity which is established between the sheath and the upper fascia of the urogenital diaphragm. These connections of the sheath prevent the prostate altering its position in response to the continual

changes which occur in the state of the distension of the bladder. It is a matter of importance to notice that the prostate lies loosely in its sheath. Only in the median plane, in front, and around the urethra as it emerges from the gland, is there any degree of adhesion between the prostate and its fascial envelope (Fig. 224).

Within the sheath, and attached more closely to its inner surface than to the prostate, is a plexus of thin-walled veins, called the *pudendal plexus* (Fig. 223). The plexus is spread over the anterior border and the lateral surfaces of the prostate, and is denser in the latter situation than in the former. It receives the dorsal vein of the penis; it communicates with the internal pudendal vein, and it becomes continuous above, at the base of the prostate, with the prostatico-vesical venous plexus, from which the blood is drained by the inferior vesical veins.

Immediately surrounding the prostate, and quite independent of the sheath, is the fibrous *capsule* of the prostate. This capsule varies in thickness, in some cases being extremely thin and in others forming a distinct cortex. In association with operations for the removal of the prostate, now frequently performed, it is important to notice that the capsule has but very slight connection either with the venous plexus or with the sheath of pelvic fascia. It is on this account that the gland can be so easily shelled out from its surroundings.

The prostate presents for examination a *base* or superior surface, an *apex* or inferior extremity, a *posterior surface*, two *lateral surfaces*, and an *anterior, rounded border*. The *base* looks upwards, surrounds the internal urethral orifice, and, in a considerable part of its extent, is structurally continuous with the bladder. Around the greater part of its circumference, however, it is separated from the bladder by a groove in which is lodged a group of thin-walled veins, known as the *prostatico-vesical plexus*. The *apex* abuts against the upper fascia of the urogenital diaphragm (Fig. 224). The posterior surface is usually a flat triangular area which rests on the anterior aspect of the rectum, but, occasionally, it is marked by a median, vertical groove. The two lateral surfaces rest upon the levatores ani muscles, and are separated from each other by the prominent, rounded, anterior border, from which the urethra emerges immediately above the apex of the gland.

The delicate ejaculatory ducts pierce the base of the prostate a short distance behind the internal urethral orifice of the bladder, and, as they descend, they separate the so-called middle lobe from the remainder of the gland, which is generally spoken of as consisting of two lateral lobes, though there is no structural demarcation between them.

**Vesiculæ Seminales.**—The two seminal vesicles lie between the fundus of the bladder and the rectum. Each is about two inches (50 mm.) in length and is conical or pyriform in shape. The lower, pointed end of each vesicle rests on the

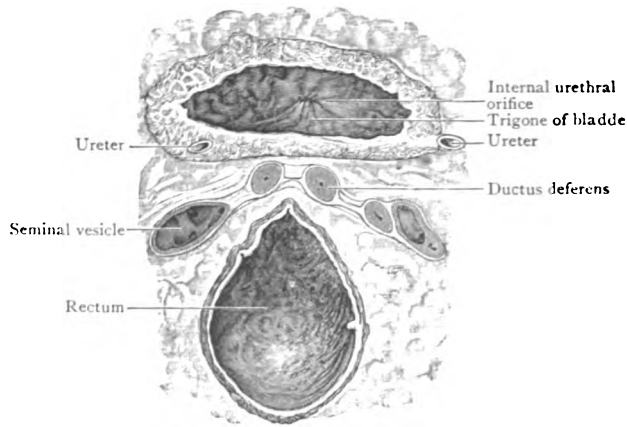


FIG. 240.—Horizontal section through the Bladder and Rectum at the level at which the ureters enter the bladder.

base of the prostate, and the blunt, upper end lies in the sacro-genital fold of peritoneum, in relation with the recto-vesical excavation of peritoneum, and with the entrance of the ureter into the bladder. At their lower extremities the vesicles are separated from each other only by the interposed deferent ducts, but they diverge as they ascend, and their upper ends are wide apart. They are enclosed, together with the deferent ducts, which lie along their medial sides, in a dense sheath derived from the recto-vesical layer of the visceral pelvic fascia.

Each vesicula seminalis is in reality a closed tube, five or six inches long, which is coiled upon itself and bound into vesicular form by the dense areolar tissue in which it is

embedded. When it is unravelled, several blind diverticula will be found to proceed from the main tube. The lower end of the tube, which is called the *excretory duct*, emerges from the pointed lower end of the vesicle and joins with the ductus deferens, at an acute angle, to form the *ejaculatory duct*.

**Ductus Deferens** (O.T. **Vas Deferens**).—The deferent duct, or duct of the testis, was previously traced to the abdominal inguinal ring (p. 410), through which it enters the abdomen. Separating itself from the other constituents of the spermatic cord, it hooks round the inferior epigastric artery, and descends on the medial side of the external iliac vessels to the pelvis minor. It then runs backwards, on the side wall of the pelvis, immediately external to the peritoneum, through which it is clearly visible, and it crosses, in turn, the umbilical artery, the obturator nerve, the superior vesical artery, and the ureter. Immediately beyond the ureter it turns sharply medially towards the fundus of the bladder, enters the pelvic fascia, comes into relation with the blunt, upper end of the seminal vesicle, and runs downwards and medialwards, in close apposition with the upper or medial side of the vesicle, to the base of the bladder. There, lying close to the median plane, and to its fellow of the opposite side, it turns vertically downwards to the base of the prostate. The lower part of the duct is dilated, tortuous, and sacculated, and is termed the *ampulla*, but its lower end narrows greatly and joins with the duct of the seminal vesicle to form the ejaculatory duct.

**Triangle on the Base of the Bladder.**—It is customary to describe a triangle at the base of the bladder, bounded laterally by the deferent ducts, and above by the reflection of the peritoneum at the bottom of the recto-vesical excavation. When the pelvic viscera are hardened *in situ*, by formalin injection, such a space can hardly be said to exist, owing to the approximation of the ampullæ of the deferent ducts, but it is possible that when the bladder is distended the space between the deferent ducts may be increased.

*Dissection.*—The peritoneum has already been lifted up and the extraperitoneal fat removed to show the visceral branches of the hypogastric artery. The pelvic fascia must now be removed and the remaining branches of the hypogastric artery and the accompanying veins must be followed, so far as they lie in the pelvis. Accompanying the arteries a number of nerve twigs from the pelvic plexuses, and from the third and fourth sacral nerves, should be noticed and preserved. As the dissector approaches the posterior pelvic wall he must pull the rectum forwards, and as he does this he should note that branches from the sympathetic trunk and from the

third and fourth sacral nerves pass to its walls. Whilst the pelvic fascia is being removed from the sacral region care must be taken not to injure the pudendal and coccygeal plexuses and their roots and the sympathetic trunk, which all lie immediately behind the fascia. The lateral sacral arteries will serve as useful guides, for as they run medially, from the posterior division of the hypogastric artery, they lie in front of the sacral plexus, and as one or other of them descends along the front of the sacrum it lies immediately to the lateral side of the sympathetic trunk and across the roots of the sacral nerves as they issue from the anterior sacral foramina.

**Pelvic Blood-Vessels.**—The pelvic arteries, in the male, are the following:—

1. The hypogastric and its branches (upon each side).
2. The middle sacral
3. The superior hæmorrhoidal } (near the median plane).

**Arteria Hypogastrica** (O.T. **Internal Iliac Artery**).—The hypogastric artery is the medial terminal branch of the common iliac artery; it is a short, wide vessel, about one and a half inches long (37 mm.) and much smaller in the adult than the external iliac artery. It commences opposite the sacro-iliac articulation, at the level of the lumbo-sacral articulation; it runs downwards and backwards in the pelvis, and ends, near the upper border of the greater sciatic notch, by dividing into an anterior and a posterior division.

*Relations.*—To its *lateral side* are the obturator nerve, and, at a higher level, the external iliac vein, which separates it from the medial border of the psoas major. In *front* is the ureter, and *behind* is the hypogastric vein. *Medially*, it is covered by peritoneum, which separates the right artery from coils of the ileum, and the left from the pelvic colon. In the female the ovary and the ovarian end of the uterine tube are anterior relations of the artery and of the ureter, from both of which they are separated by the parietal peritoneum.

*Condition in the Fœtus.*—Very different is the condition of the hypogastric artery in the fœtus. It is twice as large as the external iliac artery. Instead of terminating at the sciatic notch it runs forwards, and ascends, on the posterior aspect of the anterior abdominal wall, to the umbilicus, through which it passes, in company with its fellow of the opposite side and the umbilical vein. Outside the abdominal cavity the hypogastric arteries enter the umbilical cord, and, twining spirally round the umbilical vein, they reach the placenta, where the impure blood which they carry is brought into relation with the maternal blood.

After birth, when the umbilical cord is ligatured and divided, a portion of each hypogastric artery, from the umbilicus to the sciatic notch, undergoes atrophy, and is ultimately converted into a fibrous cord known as the *lateral umbilical ligament.* This springs from the lower end of the trunk, or from the anterior division, of the hypogastric artery, and runs forwards on the side wall of the pelvis to the apex of the bladder, whence it ascends to the umbilicus. At the side of the pelvis it lies at a higher level than the obturator nerve, and it passes to the lateral side of the ductus deferens. For about the first two inches of its extent it has a small lumen, and from this part one or more superior vesical branches arise.[1]

**Branches of the Divisions of the Hypogastric Artery.**

| Anterior Division. | | Posterior Division. | |
|---|---|---|---|
| Parietal. | Visceral. | Parietal. | Visceral. |
| Obturator. | Superior vesical. | Ilio-lumbar. | None. |
| Internal pudendal. | Inferior vesical. | Lateral sacral. | |
| Inferior gluteal. | Middle hæmorrhoidal. | Superior gluteal. | |

**Arteriæ Vesicales Superiores.**—As a rule there are two or three slender superior vesical arteries which spring from the umbilical artery. They supply the greater part of the superior and infero-lateral surfaces of the bladder, and occasionally one of them gives off the *artery to the ductus deferens*, an extremely slender branch, which can be traced along the deferent duct to the testis.

**Arteria Vesicalis Inferior.**—The inferior vesical artery is usually of larger size than any of the superior vesical

[1] Although the portion of the hypogastric artery of the fœtus which runs from the greater sciatic notch through the umbilicus to the placenta is the direct continuation of the main trunk, it is frequently called the *umbilical artery* and is spoken of as a branch of the hypogastric artery. When this terminology is adopted the lateral umbilical ligament is said to be the remains of the umbilical artery.

branches. It crosses in front of the ureter and over or under the angular bend of the deferent duct, to reach the base of the bladder, where it ramifies, sending twigs to the bladder, the seminal vesicle, the ductus deferens, and the prostate. It frequently gives off the *artery to the ductus deferens.*

**Arteria Hæmorrhoidalis Media.**—The middle hæmorrhoidal artery may arise independently or in common with the inferior vesical, and it may pass in front of the lower part of the ureter or behind it. It is distributed mainly to the muscular coat of the rectum, where it anastomoses with the superior and inferior hæmorrhoidal vessels. It supplies twigs also to the prostate, the deferent ducts, the seminal vesicles, and the bladder.

**Arteria Obturatoria.**—The obturator artery runs forwards on the inner aspect of the pelvic wall to the upper margin of the obturator foramen, where it enters the obturator canal. In the pelvis it lies in the extraperitoneal fat below the obturator nerve and above the vein. It gives some small *iliac branches* to the iliac fossa, and a *pubic branch*, which ascends on the pelvic surface of the pubis to anastomose with the pubic branch of the inferior epigastric artery. This anastomosis may become converted into either the commencement of the obturator, which then arises from the inferior epigastric, or the commencement of the inferior epigastric, which then arises from the obturator, and, in either case, it may pass to the medial side or to the lateral side of the femoral ring; thus it attains a close relationship with a femoral hernia.

**Arteria Pudenda Interna** (O.T. **Internal Pudic Artery**).—In the pelvic part of its course the internal pudendal artery proceeds downwards in front of the piriformis muscle and the sacral nerves. It leaves the pelvis by passing between the piriformis and the coccygeus muscles, and through the lower part of the greater sciatic foramen.

**Arteria Glutæa Inferior** (O.T. **Sciatic Artery**).—The inferior gluteal artery is usually the largest branch given off by the anterior division of the hypogastric artery, and, as a rule, it lies behind the internal pudendal. It passes down in front of the piriformis muscle and the sacral plexus, and frequently through one of the loops of the plexus. It leaves the pelvis by passing between the piriformis and coccygeus muscles, and through the lower part of the greater sciatic foramen (Fig. 85).

**Arteria Ilio-lumbalis.** — The ilio-lumbar artery springs from the posterior division of the hypogastric artery and passes upwards, laterally, and backwards, behind the obturator nerve, the external iliac vessels, and the psoas major muscle, into the iliac fossa, where it divides into lumbar and iliac branches. The *lumbar branch* runs upwards, and terminates in the substance of the quadratus lumborum and psoas major muscles, where it anastomoses with the lower lumbar arteries. It gives off a small *spinal branch*, which enters the vertebral canal through the intervertebral foramen between the fifth lumbar vertebra and the sacrum. The *iliac branch* breaks up into branches, some of which run laterally in the substance of the iliacus and others between the muscle and the bone. One of the latter set enters the nutrient foramen in the iliac fossa. The terminal branches reach the crest of the ilium, where they anastomose with the deep circumflex iliac and lumbar arteries.

**Arteria Glutæa Superior** (O.T. **Gluteal Artery**).—The superior gluteal artery is the largest branch of the hypogastric artery, and may be regarded as the continuation of its posterior division. Its course in the pelvis is short. It passes backwards, between the lumbo-sacral trunk and the first sacral nerve, and leaves the cavity through the upper part of the greater sciatic foramen, above the piriformis muscle.

**Arteria Sacralis Lateralis.**—The lateral sacral artery is occasionally a single vessel, but more commonly it is represented by two branches, which run medialwards, in front of the sacral nerves, to the lateral borders of the anterior sacral foramina. The upper of the two enters the first sacral foramen. The lower runs downwards, lateral to the foramina and the sympathetic trunk, and across the roots of the sacral nerves, to the tip of the coccyx where it anastomoses with the middle sacral artery. As it descends it sends spinal branches into the foramina. These assist the upper artery to supply the membranes and nerve-roots within the canal; then they emerge through the posterior sacral foramina and anastomose with branches of the superior gluteal artery.

**Arteria Hæmorrhoidalis Superior.**—The superior hæmorrhoidal artery is the direct continuation of the inferior mesenteric artery. It enters the root of the pelvic mesocolon and descends in it as far as the third piece of

the sacrum. There it divides into two branches which proceed downwards, one on each side of the rectum. Each of these branches soon breaks up into smaller branches, which range themselves round the gut and pierce its muscular coat about the middle of its length. Within the submucous coat they proceed down to the anal canal, where it is usual to find one within each rectal column (p. 610). The terminal twigs anastomose freely with each other and with branches of the middle and inferior hæmorrhoidal arteries.

**Arteria Sacralis Media (Middle Sacral Artery).**—During the dissection of the abdomen the middle sacral artery was seen springing from the back of the termination of the aorta, above the common iliac arteries. It descends in front of the bodies of the lower two lumbar vertebræ and behind the left common iliac vein. Reaching the sacrum, it continues downwards in the median plane to the tip of the coccyx. It supplies the glomus coccygeum, and, from each side, it gives off small twigs which anastomose with the lateral sacral arteries.

**Veins of the Pelvis.**—The arrangement of the veins in the pelvis corresponds in great measure to that of the arteries; but there are some important differences, viz.:—

(1) The *dorsal vein of the penis*, instead of joining the internal pudendal vein, enters the pelvis and divides into two branches, which join the pudendal plexus of veins.

(2) The *ilio-lumbar* and *middle sacral veins* pour their blood, as a rule, into the common iliac veins.

(3) The veins around the prostate, bladder, and rectum are large and numerous, and form dense plexuses, which communicate freely with each other. The *pudendal* (O.T. *prostatic*) and *vesical plexuses* have already been noticed; the blood is drained from them chiefly by the vesical veins. The *hæmorrhoidal plexus* consists of two parts, one in the submucous coat and one on the surface of the gut. It is the latter which is seen in the dissection. The blood is drained from it by three groups of channels, viz., the *superior hæmorrhoidal vein*, which ends in the inferior mesenteric vein; the *middle hæmorrhoidal veins*, which end in the hypogastric veins; and the *inferior hæmorrhoidal veins*, which go to the internal pudendal veins. The hæmorrhoidal plexus is therefore a link between the portal and systemic

systems of veins. This is of practical importance in association with the production of hæmorrhoids or piles, which are due to a varicose condition of the hæmorrhoidal veins. The portal vein and its larger tributaries are without valves; consequently, anything which retards the flow of blood through the portal system will react upon the hæmorrhoidal plexus, cause its distension, and predispose to the formation of hæmorrhoids.

**Vena Hypogastrica** (O.T. **Internal Iliac Vein**).—The hypogastric vein is a trunk which lies behind the hypogastric artery. Its tributaries correspond to the branches of the hypogastric artery, except that the ilio-lumbar vein opens into the common iliac vein.

**The Lymph Vessels of the Pelvis.**—It is only in rare circumstances that the dissector will be able to display any of the pelvic lymph vessels, but in favourable subjects he will be able to localise some of the pelvic lymph glands. The main groups of lymph glands of the pelvis are (1) the *hypogastric glands*; (2) the *sacral glands*; and (3) the *rectal glands*. The hypogastric glands are situated on the side wall of the pelvis, near the origins of the branches of the hypogastric artery. They receive lymph vessels from the membranous part of the urethra, the lower part of the bladder, the prostate, the upper part of the anal canal, and the lower part of the rectum. Their efferent vessels pass to glands situated round the common iliac artery. The sacral glands lie along the medial sides of the anterior sacral foramina. They receive lymph vessels from the adjacent bones and ligaments, from the rectal glands, and from the prostate. Their efferent vessels end in the common iliac glands. The rectal glands, four or five in number, lie in relation with the superior hæmorrhoidal vein and its two main tributaries. They receive lymph from the rectum, and their efferent vessels terminate in the lateral sacral glands.

*Dissection.*—As soon as the examination of the pelvic vessels is completed the viscera should be drawn as far as possible from the side wall of the pelvis, and any vessels which tend to prevent the movement should be divided, and then the pelvic diaphragm should be examined. It is composed of two muscles on each side, viz.—the levator ani and the coccygeus. Both the muscles must be cleaned, and whilst this is being done care must be taken to avoid injuring the fifth sacral and the coccygeal nerves as they pierce the coccygeus near the coccyx.

**M. Levator Ani.**—This is a strong sheet of muscle fibres,

which forms the anterior and greater part of the pelvic diaphragm. It has a triple origin. The anterior fibres arise from the back of the pubic bone, between the attachments of the visceral and parietal layers of the endo-pelvic fascia; the posterior fibres arise from the pelvic surface of the ischial spine; the intermediate fibres, constituting the greater part of the muscle, take origin in the angle between the visceral and parietal layers of the pelvic fascia.

*Insertion.*—The *anterior fibres* pass downwards and backwards. A few of them are inserted into the central point of the perineum; others are inserted into the wall of the anal canal, between the internal and external sphincters; and some join with the *intermediate fibres*, which sweep round into the angle between the posterior wall of the rectum and the upper end of the anal canal, where they unite with their fellows of the opposite side and form a strong muscular collar round the gut; the lower fibres of this group are inserted into the posterior wall of the anal canal between the two sphincters. The *posterior fibres* pass backwards and medially, and are inserted into the median ano-coccygeal raphe, behind the rectum, and into the side of the lower part of the coccyx. The anterior fibres of the muscles of the opposite sides embrace the lateral surfaces of the prostate as they pass backwards, and are frequently called the *levatores prostatæ* (Fig. 239). As the intermediate and posterior fibres pass to their insertions they support the infero-lateral surfaces of the bladder and the lateral walls of the rectum. When the muscle contracts, as a whole, it tends to elevate the pelvic viscera. The fibres inserted into the wall of the anal canal pull that wall upwards over descending fæces, and therefore aid defæcation. The fibres which form the collar-like loop round the angle between the rectum and the anal passage will, on contraction, increase that angle, and tend to prevent the passage of the contents of the rectum into the anal passage.

**M. Coccygeus.**—This is a small triangular muscle which continues the plane of the pelvic diaphragm posterior to the levator ani. It *arises* from the pelvic surface of the ischial spine and the adjacent pelvic fascia, and, expanding as it passes medially, it is *inserted* into the margin of the last piece of the sacrum and the anterior surface of the upper part of the coccyx. Its anterior margin is continuous with the levator ani,

and its posterior margin is separated from the lower border of the piriformis by the inferior gluteal and pudendal vessels and the sciatic and pudendal nerves, as they pass out of the pelvis.

**The Pelvic Nerve Plexuses.**—There are three pelvic spinal nerve plexuses, viz., the sacral, the pudendal, and the coccygeal. The former two are situated on the posterior wall of the pelvis

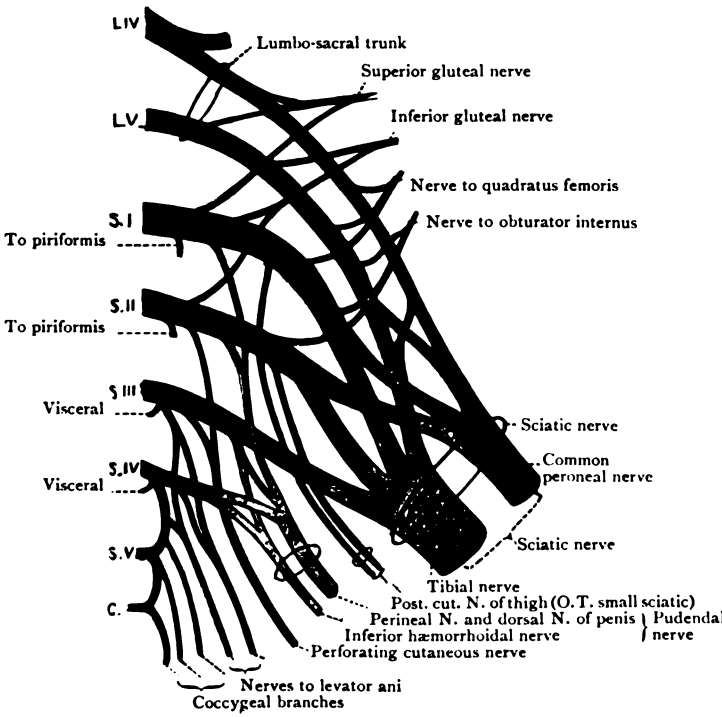


FIG. 241.—Diagram of the Sacral, the Pudendal, and the Coccygeal Plexuses.

in front of the piriformis muscle, and the latter lies on the coccygeus muscle close to the side of the coccyx.

**The Sacral and Pudendal Plexuses (O.T. Sacral Plexus).**—The anterior rami of six spinal nerves take part in the formation of these plexuses, viz., part of the fourth lumbar nerve, the fifth lumbar, the first, second, and third sacral nerves, and part of the fourth sacral nerve. The first and

second sacral nerves are very large, and of about equal size; the third is much smaller, and the fourth still smaller. Each of the anterior rami, before it joins the plexus, receives a branch from the nearest sympathetic ganglion, and the third and fourth sacral nerves give white rami communicantes to the sympathetic pelvic plexuses. By the union of the branch of the fourth lumbar nerve with the fifth lumbar nerve, in the abdomen, a *lumbo-sacral trunk* is formed. This descends behind the common iliac artery and over the pelvic brim into the pelvic cavity, where it unites with the first sacral nerve, forming a loop through which the superior gluteal artery passes. By the union of the other sacral roots a series of similar loops is formed, and the inferior gluteal artery frequently runs through one or other of these before it leaves the pelvis. Beyond the loops the plexuses usually take the form of two flattened bands, viz.—an upper or *sciatic band* and a lower or *pudendal band*. The *sciatic band* is very large, and consists of the lumbo-sacral trunk with the first sacral nerve and the greater portions of the second and third sacral nerves. It runs downwards and laterally, narrowing but thickening as it descends, and, passing first between the adjacent borders of the piriformis and coccygeus, and then through the greater sciatic foramen, it leaves the pelvis and enters the buttock as the sciatic nerve.

The *pudendal band* is small. It consists of fibres of the second, third, and fourth sacral nerves. It also passes between the adjacent borders of the piriformis and coccygeus muscles, and it is continued from the pelvis through the lower part of the greater sciatic foramen as the pudendal nerve.

The student who has already dissected the lower extremity will remember that the sciatic nerve breaks up into common peroneal (O.T. ext. popliteal) and tibial (O.T. int. popliteal) divisions. It occasionally happens that the two divisions arise separately from the sacral plexus. When this is the case there is no sciatic band, and it becomes evident that the common peroneal nerve is derived from the dorsal divisions of the anterior branches of the fourth and fifth lumbar and the first and second sacral nerves, and the tibial nerve, from the ventral divisions of the anterior branches of the same nerves, and also from the ventral division of the anterior branch of the third sacral nerve. Moreover, when the common peroneal

thus arises directly from the sacral plexus, it usually perforates the piriformis muscle on its way out of the pelvis.

In addition to the two main bands into which the sacral and pudendal plexuses resolve themselves (sciatic and pudendal) various other branches are given off. They are :—

1. Superior gluteal.
2. Inferior gluteal.
3. Posterior cutaneous of the thigh (O.T. small sciatic).
4. Nerve to the obturator internus and superior gemellus.
5. Nerve to the quadratus femoris and inferior gemellus.
6. Perforating cutaneous nerve.
7. Branches to the piriformis muscle.
8. Branches to the pelvic viscera.

**Nervus Glutæus Superior.**—The superior gluteal nerve arises from the posterior aspect of the plexus and contains fibres of the fourth and fifth lumbar and first sacral nerves. It passes, with the superior gluteal vessels, above the upper border of the piriformis muscle, and leaves the pelvis through the upper part of the greater sciatic foramen. It is distributed, in the gluteal region, to the glutæus medius and glutæus minimus, and to the tensor fasciæ latæ muscles.

**Nervus Glutæus Inferior.**—The inferior gluteal nerve is the special branch of supply to the glutæus maximus. It also springs from the back of the plexus; and it contains fibres of the fifth lumbar and the first and second sacral nerves. It passes below the piriformis and through the greater sciatic foramen into the buttock.

**Nervus Cutaneus Femoris Posterior** (O.T. **Small Sciatic**).—The posterior cutaneous nerve arises from the back of the plexus and contains fibres of the second and third sacral nerves. It passes between the piriformis and coccygeus, and leaves the pelvis through the lower part of the greater sciatic foramen.

**The Nerve to the Obturator Internus** springs from the anterior aspect of the plexus, and contains fibres of the fifth lumbar and the first and second sacral nerves. It leaves the pelvis with the pudendal nerve, and, after giving a twig to the superior gemellus in the gluteal region, it reaches the obturator internus by passing through the lesser sciatic foramen. It sinks into the medial aspect of the muscle.

**The Nerve to the Quadratus Femoris** springs from the anterior aspect of the plexus, receiving fibres from the fourth and fifth lumbar and the first sacral nerves. It accompanies

the sciatic trunk out of the pelvis, and supplies not only the quadratus femoris but also the inferior gemellus and the hip-joint.

**The Perforating Cutaneous Nerve** springs from the back of the plexus and contains fibres of the second and third sacral nerves. It pierces the sacro-tuberous ligament, winds round the lower border of the glutæus maximus, and supplies the skin over the lower and medial part of that muscle.

**The Twigs to the Piriformis** spring usually from the first and second sacral nerves.

**The Visceral Branches** (white rami communicantes) are derived mainly from the third and fourth sacral nerves.

**Plexus Coccygeus.**—The coccygeal plexus is a small, looped plexus. It is formed by the lower branch of the fourth sacral nerve, the fifth sacral nerve, and the coccygeal nerve. Besides joining with the fifth, the *fourth sacral nerve* gives branches to the coccygeus and the levator ani, the latter branch being known as the *perineal branch of the fourth sacral.* It also supplies white *rami communicantes* which join the pelvic plexuses of the sympathetic and supply the pelvic viscera.

The *fifth sacral nerve* enters the pelvis by piercing the coccygeus. It communicates with the fourth sacral and the coccygeal nerves and gives branches to the coccygeus muscle.

The *coccygeal nerve* also enters the pelvis by piercing the coccygeus muscle. Having communicated with the fifth sacral nerve it runs downwards and leaves the pelvis by again piercing the coccygeus muscle. It ends in the skin in the neighbourhood of the tip of the coccyx.

**Pelvic Plexuses of the Sympathetic.**—It has already been noted that the hypogastric plexus, which lies in front of the last lumbar vertebra, ends below by dividing into the two pelvic plexuses. These are prolonged downwards, one on each side of the rectum. Each pelvic plexus receives numerous branches from the third and fourth sacral nerves and from the pelvic portion of the sympathetic trunk of the same side. The points at which these unite with the plexuses are marked by minute ganglia.

Prolongations from each pelvic plexus are sent along the various branches of the hypogastric artery of the same side. There are thus formed various secondary plexuses, viz.—the *vesical* plexus, associated with the bladder, the seminal vesicles, and the vas deferens; the *hæmorrhoidal* plexus, distributed to

the rectum; and the *prostatic* plexus, connected with the prostate. The prostatic plexus proceeds forwards between the prostate and the levator ani, and sends branches, called the *cavernous nerves*, to the penis.

**Trunci Sympathici.**—The sympathetic trunks reach the pelvis considerably reduced in size. They pass downwards along the medial margins of the anterior sacral foramina, and they end in the median plane, in front of the coccyx, in a minute unpaired ganglion, called the *ganglion impar.* There are generally four ganglia on the pelvic portion of each sympathetic trunk, and each ganglion is connected with one of the sacral nerves by a grey communicating ramus. The other branches from the ganglia are distributed chiefly to the anterior surface of the sacrum, around the middle sacral artery. From the upper ganglia branches proceed to the pelvic plexuses, and from the ganglion impar branches are given to the parts about the coccyx and to the glomus coccygeum.

**Glomus Coccygeum** (O.T. **Coccygeal Body**).—This is a lobulated body, about the size of a small pea, which lies in front of the tip of the coccyx. It is composed of masses of polyhedral cells, intermingled with strands of connective tissue, numerous sympathetic nerve twigs, and branches of the middle sacral artery. Its function is unknown.

*Dissection.*—The viscera should now be removed, and the structure of the walls of the rectum and bladder should be examined.

**Structure of the Rectum.**—The rectum possesses the following coats:—1. Serous. 2. Fascial. 3. Muscular. 4. Submucous. 5. Mucous.

The peritoneal, serous coat, and the fascial coat, derived from the visceral layer of the pelvic fascia, have already been examined.

**Muscular Coat of the Rectum.**—This coat is strong, and is composed of an external longitudinal and an internal circular layer of involuntary or unstriped muscle-fibres. The longitudinal fibres are continuous, above, with the three longitudinal bands of the colon. As those bands pass downwards the fibres which compose them spread out to form a continuous layer round the rectum. The layer is not, however, uniformly thick on all aspects of the gut, for in front and on the back the fibres are massed to form two broad bands, which main-

tain the flexures and prevent the rectum from elongating as it becomes loaded. The circular muscle fibres form a more or less uniform layer, internal to the longitudinal fibres, and they are prolonged into the bases of the rectal valves.

**Muscular Coat of the Anal Canal.**—The muscular wall of the anal canal is very thick and powerful. The internal circular layer of muscle-fibres, prolonged down from the rectum, is greatly thickened to form a muscular cylinder, the *internal sphincter*, which embraces the whole length of the canal, except the lower half-inch. The longitudinal fibres from the rectum are also prolonged downwards, outside the internal sphincter, and they blend with the fibres of the levator ani, which are inserted into the wall of the canal between the internal and the external sphincters. The external sphincter surrounds the lower part of the canal outside the levator ani.

**Submucous coat of the rectum and anal canal.**—This is composed of lax areolar tissue, which allows the mucous coat to move freely on the muscular coat. It contains vessels and nerves.

**Mucous Membrane of the Rectum and Anal Canal.**—This is thicker and more movable upon the muscular tunic than the mucous membrane of the colon, and, in consequence of this mobility, it is thrown into irregular folds or rugæ when the gut is empty. In the upper part of the anal canal the mucous membrane is thrown into a series of longitudinal folds, called *columnæ rectales* (Morgagni). A short distance above the anal orifice the columns are connected by a number of irregular semilunar folds, called the *anal valves*. In the concavity of each valve is a pocket-like recess, termed the *sinus rectalis*. The folds are of importance in connection with the condition known as fissured anus, and they indicate the level at which the scaly epithelium of the integument merges into the columnar epithelium of the gut.

**Plicæ Transversales Recti** (O.T. **Valves of Houston**).—These folds are not always visible, and are usually seen best in a rectum which has been fixed with formalin when in a state of distension. They are three in number, in conformity with the inflections of the gut; consequently there are two on the left side and one, the largest, on the right side. Each is formed by an infolding of the mucous, submucous, and part of the muscular coat. The positions of the folds are variable; but the right and largest is usually placed at the level of the bottom of the recto-vesical excavation of peritoneum, whilst

the two folds of the left side are situated, one an inch and a half above the right fold, and the other the same distance below it (Birmingham).

**The Structure of the Walls of the Bladder.**—The bladder possesses the following five coats:—

1. Serous. 2. Subserous. 3. Muscular. 4. Submucous. 5. Mucous.

The serous or peritoneal covering has already been examined. The subserous coat is a thin stratum of areolar tissue which connects the peritoneum with the muscular coat.

**The Muscular Coat.**—The fibres of the muscular wall of the bladder are arranged in three layers:—

1. External longitudinal fibres. 2. Circular fibres. 3. Internal longitudinal fibres.

The *external longitudinal fibres*, frequently spoken of as the *detrusor urinæ*, spring from the back of the pubic bones, the pubo-prostatic ligaments, and the base of the prostate. They ascend from these attachments over the anterior border and the medial parts of the infero-lateral surfaces of the bladder. At the apex a few pass into the urachus, but the majority pass backwards over the superior surface and the base of the bladder to the prostate, to which they are attached. On the lateral parts of the infero-lateral surfaces and on the lateral borders of the bladder, this layer is less complete, and the fibres take a more oblique direction.

The *circular fibres* are arranged in coarse bundles which run obliquely as well as circularly round the bladder, and constitute the greater part of its muscular coat. At the internal urethral orifice the bundles become finer and are massed together to form a sphincter, the fibres of which are more or less continuous with those of the prostate.

The *internal longitudinal fibres* are absent on the fundus, and form only an incomplete layer on the other walls of the bladder.

**The Submucous Coat.**—This is a layer of loose areolar tissue which forms a loose connection between the mucous and muscular coats, except in the region of the trigone, where the connection is much closer. The blood-vessels and nerves ramify in the submucous laye: before they enter the mucous coat.

**The Mucous Coat.**—This coat was examined when the bladder was opened (p. 571).

*Dissection.*—Remove the levator ani, leaving small portions attached to its bony origins, viz., the body of the pubis and the spine of the ischium. Take away all the remains of the parietal pelvic fascia from the side wall of the pelvis, and the obturator internus muscle will be exposed.

**M. Obturator Internus.** — This muscle clothes the side wall of the pelvis on its inner aspect. It is fan-shaped and takes an extensive origin, viz.—(1) from the circumference of the obturator foramen, except above, where the obturator vessels and nerves quit the pelvis; (2) from the pelvic surface of the obturator membrane; (3) from the surface of bone behind the obturator foramen, as far back as the greater sciatic notch. A few fibres are derived also from the parietal pelvic fascia which covers it. From these origins the fibres converge towards the lesser sciatic notch, and end in a tendon which issues from the pelvis through the lesser sciatic foramen. In the gluteal region the tendon is inserted, together with the two gemelli, into the medial margin of the upper border of the greater trochanter of the femur. The margin of the lesser sciatic notch over which the tendon glides is coated with smooth cartilage, and this is raised into three or four parallel ridges which fit into fissures in the deep surface of the tendon. A mucous bursa intervenes between the tendon and the cartilage.

The obturator internus is supplied by a special branch from the front of the upper part of the sacral plexus (p. 607).

**M. Piriformis.**—The piriformis lies on the anterior aspect of the posterior pelvic wall. It *arises* by three processes from the anterior surface of the sacrum, in the region of the second, third, and fourth sacral segments, between and lateral to the foramina and, to a slight extent, medial to the foramina; it takes origin also from the upper border of the greater sciatic notch and from the sacro-tuberous ligament. The muscle leaves the pelvis through the upper part of the greater sciatic foramen, and is *inserted*, by a rounded tendon, into the middle of the upper border of the greater trochanter of the femur. It is supplied by branches from the first and second sacral nerves.

## Ligamenta Cinguli Extremitatis Inferioris (Ligaments of the Pelvic Articulations).

The pelvis is attached to the last lumbar vertebra at the lumbo-sacral articulation, and its several parts are held

together by the following articulations:—(1) Sacro-coccygeal; (2) Coccygeal; (3) Sacro-iliac; (4) Pubic.

*Dissection.*—The nerves and blood-vessels of the pelvis, and all adhering portions of muscle, must now be removed from the hip bone and from the front and back of the sacrum. When this is done the pelvis should be soaked for some time in warm water. By this proceeding the dissection of the ligaments will be rendered much easier.

**Lumbo-sacral Articulations.**—The last lumbar vertebra is joined to the sacrum by one *synchondrosis*, which connects the body of the vertebra to the base of the sacrum, and by two *diarthrodial joints*, between the two pairs of articular processes.

*Articular capsules*, consisting of a fibrous stratum lined with a synovial stratum, surround the articulations formed by the apposition of the articular processes.

*Ligamenta Longitudinalia* (O.T. *Anterior and Posterior Common Ligaments*).—The anterior longitudinal ligament of the vertebral column is continued downwards, over the anterior aspect of the body of the last lumbar vertebra, to the anterior aspect of the first segment of the sacrum. In a similar manner the posterior longitudinal ligament is prolonged downwards, within the vertebral canal, over the posterior aspect of the body of the last lumbar vertebra, to the upper part of that portion of the sacrum which forms the anterior wall of the sacral canal.

*Ligamenta Flava* (O.T. *Ligamenta Subflava*) also are present. These are two short bands of yellow elastic tissue, placed one on each side of the median plane. Superiorly, they are attached to the anterior aspect of the lower borders of the laminæ of the last lumbar vertebra; whilst, inferiorly, they are fixed to the posterior aspect of the upper margins of the laminæ of the first sacral segment.

*Ligamentum Interspinale.*—An interspinous ligament connects the lower border of the spinous process of the last lumbar vertebra with the upper border of the spinous process of the first sacral vertebra. A *ligamentum supraspinale* passes between the extremities of the same spinous processes.

So far, then, the ligaments of the lumbo-sacral articulations are identical with those which, above the level of the sacrum, bind the several segments of the vertebral column together. Two additional ligaments, viz., the lumbo-sacral and the ilio-lumbar, must now be examined.

The *lumbo-sacral ligament* is the representative of the anterior costo-transverse ligaments. It is a strong, triangular, fibrous band, attached by its apex to the tip and lower border of the transverse process of the last lumbar vertebra. Expanding as it proceeds downwards, it is fixed below to the posterior

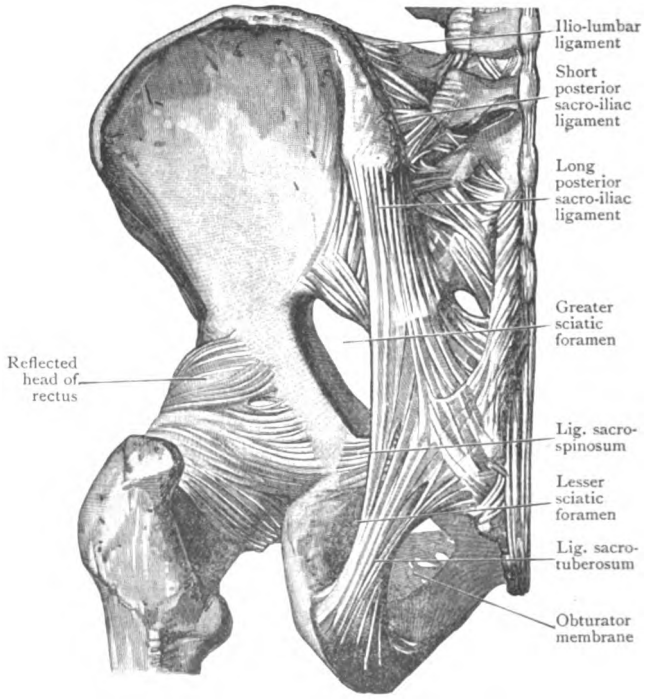


FIG. 242.—Posterior View of the Pelvic Ligaments and of the Hip-joint.

part of the base of the sacrum, where some of its fibres intermingle with those of the sacro-iliac ligaments.

*Ligamentum Iliolumbale.*—The *ilio-lumbar ligament* may be considered a thickened and specially developed part of the anterior lamella of the lumbar fascia. It lies in the same plane and is directly continuous with it. It is triangular in shape, and is fixed by its apex to the tip of the transverse process of the last lumbar vertebra. Proceeding horizontally

and laterally, it is inserted into the internal lip of the iliac crest, at the posterior part of the iliac fossa.

The *synchondrosis* between the body of the last lumbar vertebra and the base of the sacrum corresponds, in every respect, to the similar articulations between the bodies of the vertebræ above. The opposed bony surfaces are each coated with a thin layer of hyaline cartilage, and are firmly united by an intervening disc of fibro-cartilage, which is dense and laminated externally, but soft and pulpy towards the centre. The dissector should observe that this disc is the thickest of the series, and further, that it is wedge-shaped, being thicker in front than behind.

**Sacro-coccygeal Articulation.**—This is a synchondrosis. The articulating surfaces are each covered with a thin cartilaginous plate, and these are united by a disc of fibro-cartilage. The joint is strengthened in front by an *anterior ligament*, which extends downwards from the front of the sacrum to the anterior aspect of the coccyx, and by a *posterior ligament*, which, attached above to the posterior border of the lower aperture of the sacral canal, proceeds downwards upon the posterior aspect of the coccyx. The posterior ligament is much the stronger of the two. In addition, fibrous bands will be found passing between the cornua of the sacrum and the coccyx, and also between the lateral angles of the sacrum and the transverse processes of the first piece of the coccyx.

As regards the *coccygeal joints* (when such exist), the union of the different segments of the bone is brought about by intervening fibro-cartilaginous discs and anterior and posterior ligaments.

**Sacro-iliac Articulation.**—The sacrum is wedged in between the two hip bones, and is held fast in this position by the sinuous form of the opposed articular surfaces, and by the strong ligaments which pass between the bones. These ligaments are:—

1. The anterior sacro-iliac. 2. The interosseous sacro-iliac. 3. The long posterior sacro-iliac. 4. The short posterior sacro-iliac ligament. 5. The sacro-tuberous ligament. 6. The sacro-spinous ligament.

*Ligamentum Sacroiliacum Anterius.*—The anterior sacro-iliac ligament is by no means strong. It is composed of a series of short fibres stretching across the front of the joint and connecting the bones anteriorly.

*Ligamentum Sacroiliacum Interosseum.*— The *interosseous sacro-iliac ligament* is exceedingly strong. It consists of fibrous bands which connect the rough surface on the posterior part of the lateral aspect of the sacrum with a corresponding rough surface on the ilium, behind the auricular surface. Upon the interosseus sacro-iliac ligaments the strength of the articulation chiefly depends. Since the sacrum narrows towards its dorsal surface it cannot be regarded as forming a typical keystone of an arch. It may be regarded as being, in a great measure, suspended from the iliac bones by ligaments.

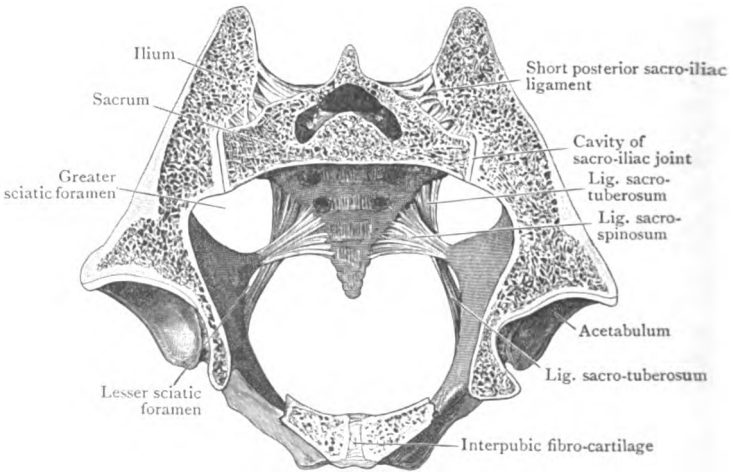


FIG. 243.—Frontal section through the Pelvis.

*Ligamentum Sacroiliacum Posterius Longum.*— The *long posterior sacro-iliac ligament* is fixed, above, to the posterior superior spine of the ilium; whilst, inferiorly, it is inserted into the third tubercle on the posterior surface of the lateral mass of the sacrum. It lies posterior to the interosseous ligament.

*Ligamentum Sacroiliacum Posterius Breve.*— *The short posterior sacro-iliac ligament* also lies behind the interosseous ligament, and is a short band of fibres which extends from the posterior inferior spine of the ilium to the back of the sacrum.

*Ligamentum Sacrotuberosum* (O.T. *Great Sacro-sciatic Liga-*

*ment*).—The sacro-tuberous ligament has a wide attachment to the posterior superior and posterior inferior iliac spines and to the side of the sacrum and coccyx. Narrowing considerably as it proceeds downwards and forwards, it again expands, and is inserted into the medial border of the tuberosity of the ischium. Thence it sends upwards a sharp *falciform process*, which extends forwards for a short distance upon the inferior ramus of the ischium, and gives attachment to the parietal pelvic fascia. It should be noticed that at its ischial attachment some of the fibres of the ligament pass continuously into the tendon of the biceps femoris muscle.

*Ligamentum Sacrospinosum* (O.T. *Small Sacro-sciatic Ligament*).—The sacro-spinous ligament is triangular in form. By its base it is fixed to the side of the sacrum and coccyx, in front of the sacro-tuberous ligament, the fibres of both mingling together; by its apex it is attached to the spine of the ischium. The pelvic surface of this ligament presents an extremely intimate connection with the coccygeus muscle; indeed, it is generally believed that the ligament is derived from the posterior part of the muscle by the fibrous degeneration of its fasciculi.

The sacro-tuberous and the sacro-spinous ligaments convert the sciatic notches of the hip bone into foramina.

Through the *greater sciatic foramen* pass the superior gluteal vessels and nerve, the piriformis muscle, the pudendal and inferior gluteal vessels and nerves, the nerve to the obturator internus, the sciatic nerve, the nerve to the quadratus femoris, and the posterior cutaneous nerve of the thigh.

The *lesser sciatic foramen* transmits the tendon of the obturator internus muscle, the pudendal vessels and nerve, and the nerve to the obturator internus muscle.

The sacro-iliac joint is a diarthrodial joint. The ligaments of the joint should now be divided, and the two bones forcibly wrenched asunder. It will then be seen that each articular surface is covered with a plate of cartilage, and that a small synovial space intervenes between and partially separates the two plates.

The sacro-iliac joint is not immovable. A slight amount of movement can take place—the sacrum rotating round an imaginary line drawn transversely through its second piece. In the erect posture the promontory of the sacrum is withdrawn to the full extent from the symphysis; when the body is bent

forwards, the symphysis and the promontory are approximated, and, in consequence, the tension of the sacro-tuberous and sacro-spinous ligaments is increased.

**Symphysis Ossium Pubis.**—The symphysis pubis is an example of a synchondrosis. In addition to the intervening disc of fibro-cartilage which connects the cartilage-covered opposing surfaces of the two pubic bones, *four* ligaments are present, viz. :—

1. Anterior pubic. 2. Posterior pubic. 3. Superior pubic. 4. Arcuate.

*Ligamentum Pubicum Anterius.*—The ***anterior pubic ligament*** is strongly marked, and consists of two layers of fibres—a superficial and a deep. The *superficial fibres* are oblique, and cross each other like the limbs of the letter X, mingling with the decussating fibres of the superior crura of the subcutaneous inguinal rings. The *deep fibres* are transverse and extend across from one bone to the other.

*Ligamentum Pubicum Posterius.*—The ***posterior pubic ligament*** consists of a very few transverse fibres on the pelvic aspect of the joint.

*Ligamentum Pubicum Superius.*—The ***superior pubic ligament***, like the preceding, is weak. It is placed upon the upper aspect of the symphisis, and stretches between the crests of the two pubic bones.

*Ligamentum Arcuatum Pubis* (O.T. *Sub-pubic Ligament*).—*The arcuate pubic ligament* is situated on the lower aspect of the joint, rounds off the apex of the pubic arch. It is a strong band, somewhat triangular in shape, which is attached, on each side, to the inferior ramus of the pubic bone, and above, to the fibro-cartilaginous disc. Between the crescentic lower margin of this ligament and the upper border of the urogenital diaphragm there is an oval aperture through which the dorsal vein of the penis passes backwards.

*Dissection.*—The saw should now be used, and a portion sliced off from the front of the joint. The intervening plate of fibro-cartilage can in this way be studied. It will be seen to be thicker and denser in front than behind. As a general rule, a small synovial cavity will be found towards its posterior part, and nearer its upper than its lower end.

**Membrana Obturatoria** (O.T. **Thyroid Membrane**).—The obturator membrane stretches across the obturator foramen. It is attached to the circumference of the foramen, except at its upper part, where it bridges across the groove on the inferior surface of the superior ramus of the pubic bone, and

converts it into a canal for the escape of the obturator vessels and nerve. At this point it is continuous, over the upper border of the obturator internus muscle, with the parietal pelvic fascia.

THE FEMALE PELVIS.

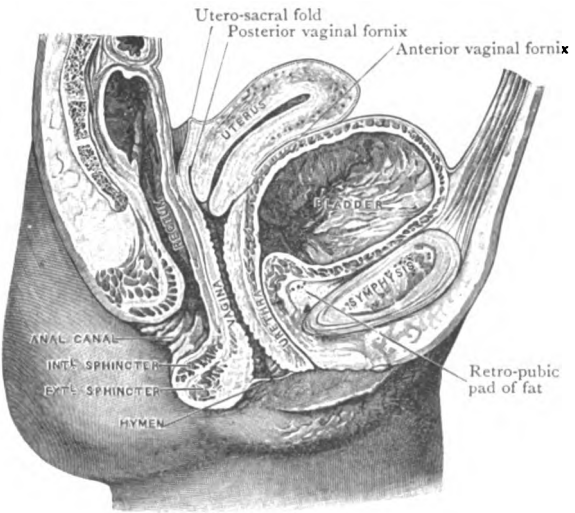


FIG. 244.—Median section through Female Pelvis.

The contents of the female pelvis are the following:—

*Viscera.*
- The pelvic colon and rectum.[1]
- The bladder and urethra.[1]
- The uterus and vagina.[1]
- The uterine appendages.
  - Uterine tubes.
  - Ovaries.
  - Round ligaments.

*Blood-vessels.*
- The hypogastric vessels and their branches.
- The superior hæmorrhoidal vessels.
- The ovarian vessels.
- Certain venous plexuses in relation with the viscera.

*Nerves.*
- The obturator nerves.
- The pelvic plexuses of the sympathetic and their offsets.

*Peritoneum.*

[1] Strictly speaking, the bladder and urethra, the vagina and the lower part of the rectum, lie in the visceral layer of the pelvic fascia.

The following structures lie in the wall of the pelvis, outside the pelvic fascia:—

*Blood-vessels.*
- The middle sacral vessels.
- The parietal branches of the hypogastric vessels after they have pierced the fascia.

*Nerves.*
- The sacral, pudendal, and coccygeal plexuses.
- The pelvic parts of the sympathetic trunks.

**General Position of the Viscera.**—The *pelvic colon* lies in the posterior and upper part of the cavity, and its loops tend to overlap the other viscera. The *rectum* occupies the lower and posterior part of the cavity, and is adapted to the concavity of the sacrum and coccyx. The *bladder* and *urethra* are situated in front, the former lying against the bodies of the pubic bones. The *uterus* and *vagina* occupy an intermediate position; and the *uterine appendages* lie laterally between the uterus and the side walls of the pelvis.

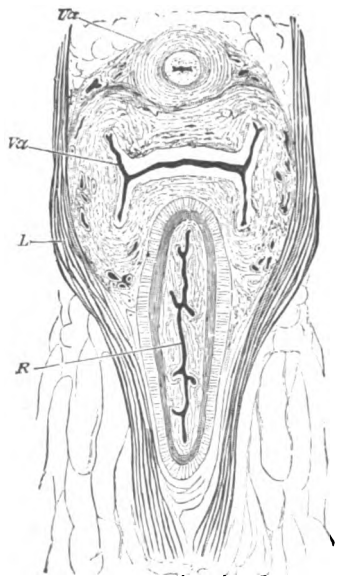


FIG. 245.—Horizontal section through the Urethra, Vagina, and Anal Canal, a short distance above their terminations. (Henle.)

*Ua.* Urethra. | *L.* Levator ani.
*Va.* Vagina. | *R.* Rectum.

**Peritoneum.**—As the peritoneum descends from the posterior abdominal wall into the pelvis, it gives a complete covering to the pelvic colon and attaches it to the anterior surface of the sacrum by a pelvic meso-colon. At a lower level it gives a partial covering to the rectum, first clothing it on its anterior and lateral surfaces, then on its anterior surface alone. Finally, it quits the gut about three inches above the level of the anus, and is reflected on to the upper part of the posterior wall of the vagina, upon which it ascends to the uterus. It covers the whole of the supravaginal portion of the posterior surface of the uterus, and, reaching the fundus, turns over and descends on the anterior surface of

the organ. It covers only the upper two-thirds of that surface, and is then reflected on to the fundus of the bladder. The vagina, therefore, receives a partial covering of peritoneum posteriorly, but is altogether devoid of peritoneum anteriorly. The whole of the supra-vaginal portion of the posterior surface of the uterus is covered, but only the upper two-thirds of the anterior surface. From each lateral border of the uterus the peritoneum extends laterally in the form of a wing-like fold, the *broad ligament*, which connects the uterus with the side wall of the pelvis.

From the upper surface of the bladder the peritoneum

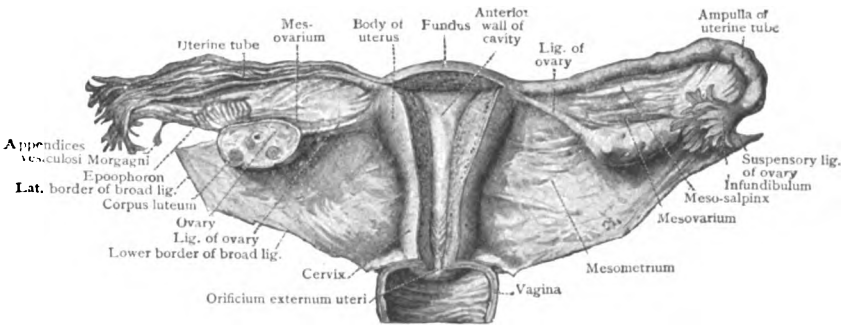


FIG. 246.—The Uterus, the Uterine Tubes, the Ovaries, the Broad Ligaments, and the upper part of the Vagina, seen from behind. The posterior wall of the uterine cavity has been removed, and the left Uterine Tube and the upper part of the Vagina have been opened.

is conducted upwards to the posterior surface of the anterior abdominal wall by the middle umbilical ligament, over which it forms a fold known as the *median umbilical fold.* From each lateral border of the upper surface of the bladder the peritoneum extends laterally to the side wall of the pelvis, forming the *lateral false ligaments.*

**Ligamenta Lata Uteri (Broad Ligaments of the Uterus).**—Each broad ligament is a wide fold composed of two layers of peritoneum. It stretches from the lateral border of the uterus to the side wall of the pelvis. The greater part of the *superior or anterior border* of the ligament is occupied by the *uterine tube.* The smaller part, which extends beyond the tube, forms the *suspensory ligament of the ovary*, and contains the ovarian vessels and nerves. The *lower or*

*inferior border or base* rests, medially, on the upper end of the vagina and, laterally, on the levator ani. The anterior or inferior layer of the peritoneal fold is reflected forwards, from the lower border, to become continuous with the lateral false ligament of the bladder, and the posterior layer

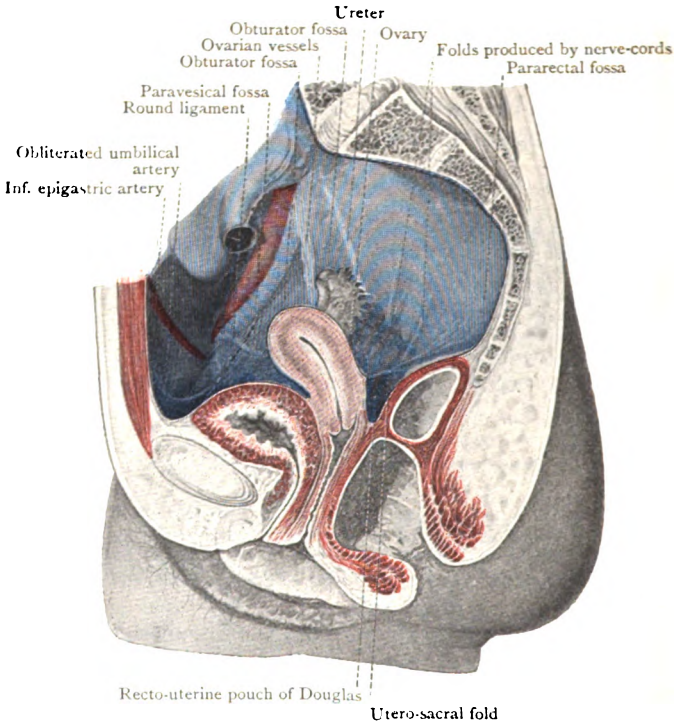


FIG. 247.—Median section through the Female Pelvis to show the disposition of the Peritoneum in relation to the Viscera and to the Side Wall of the Cavity. (Dixon and Birmingham.)

passes backward into the floor of the genital or middle pelvic fossa. The *lateral border* of the ligament is attached to the side wall of the pelvis, a short distance in front of the hypogastric artery.

Two secondary folds spring from the broad ligament, one from each surface. The one from the posterior surface contains the *ovary and its ligament*, and the one from the

anterior surface contains the *round ligament of the uterus*. The portion of the broad ligament between the uterine tube and the ovary is termed the *mesosalpinx*. The fold which proceeds from the posterior surface of the ligament to the ovary is the *mesovarium*, and the portion of the broad ligament below the level of the mesovarium is sometimes called the *mesometrium*. In addition to the uterine tube, the ovary and its ligament, and the round ligament of the uterus, the two layers of the broad ligament include between them other structures, viz., (1) the *paroophoron*; (2) the *uterine* and *ovarian vessels* and *nerves*.

**Peritoneal Fossæ.**—The paravesical fossa lies in front of the broad ligament, at the side of the bladder.

The middle or genital fossa is bounded anteriorly by the back of the broad ligament and the ureteral ridge, and posteriorly by a fold of peritoneum, similar to the sacro-genital fold of the male (p. 558), which is called the *utero-sacral fold*. This is semilunar in form, and curves, on each side, from the back of the uterus to the posterior wall of the pelvis, at the side of the rectum. Between its two layers there are some unstriped muscular fibres as well as connective tissue. Where it crosses the back of the uterus it is known as the *torus uterinus*.

The pararectal fossæ are situated at the sides of the empty rectum, between it and the utero-sacral fold.

**Excavatio Recto-uterina** (O.T. **Pouch of Douglas**).—The recto-uterine pouch corresponds to the recto-genital pouch or recto-vesical excavation in the male. *Anteriorly*, it is bounded by the peritoneum covering the upper part of the posterior wall of the vagina and the lower part of the back of the uterus; *posteriorly*, by the peritoneum on the rectum; while *on each side* is the sacro-uterine fold of peritoneum. It is continuous with the pararectal fossæ, which are obliterated when the rectum is distended (p. 559).

**Excavatio Vesico-uterina.**—The vesico-uterine pouch is a shallow depression, not always distinguishable, between the uterus and the upper part of the base of the bladder. It is bounded laterally by two slight folds of peritoneum termed the *utero-vesical folds*.

**The False Ligaments of the Bladder.**—These are the same as in the male (p. 561), except that the utero-vesical folds take the place of the longer sacro-genital folds or posterior false ligaments of the bladder of the male.

*Dissection.*—The dissector should cut through the lateral false ligaments of the bladder at their junctions with the lower borders of the anterior surfaces of the broad ligaments: he should then turn the lateral false ligaments medially to the lateral borders of the upper surface of the bladder. Next, he should draw the apex of the bladder backwards and pass his index finger down through the soft fat, between the anterior border of the bladder and the back of the symphysis pubis, till he feels the resistance of the upper fascia of the pelvic diaphragm, which passes medially from the wall of the pelvis to the bladder, and which is thickened on each side of the median plane to form the *medial pubo-vesical ligaments*. These ligaments having been recognised, the finger should be carried laterally and then backwards between the wall of the pelvis and the bladder, above the visceral layer of the pelvic fascia, as far as the lateral border of the broad ligament. The dissector will find he can do this quite easily, and by doing it he will demonstrate the fact that between the anterior border and infero-lateral surfaces of the bladder and the wall of the pelvis there is a space filled with easily displaced extra-peritoneal fat; this is the lower and anterior part of the so-called *cave of Retzius*. The finger should now be passed still farther backwards along the side wall of the pelvis, beyond the lateral border of the broad ligament, until the front of the hypogastric artery is reached; but little resistance will be met, and the dissector will be able to satisfy himself that the lower part of the so-called cave extends round the sides and front of the pelvis from the hypogastric artery of one side to the corresponding vessel of the opposite side. The upper part of the cave lies behind the anterior abdominal wall, extending upwards between the inferior epigastric arteries to the level of the umbilicus. The cave is of practical importance, because, on account of the laxity of its fatty contents, urine escaping from a ruptured bladder, or effused blood, or inflammatory exudations, can spread rapidly throughout the area; moreover, it is an area in which the surgeon can readily separate the pelvic contents from the pelvic wall. Having satisfied himself as to the presence and the boundaries of the cave, the dissector should carefully remove the extra-peritoneal fat which lies between the bladder and the wall of the pelvis, taking care to avoid injuring any vessels which may be passing through the fat. When he has completed this part of the dissection he will have displayed on the side wall of the pelvis the following structures:—The lateral umbilical ligament, lying a short distance below the level of the pelvic brim; the obturator nerve, below the ligament; and, at a still lower level, the obturator artery and vein. Crossing from the umbilical ligament to the bladder, the superior vesical artery will be found. Lateral to the obturator vessels and nerve, the parietal pelvic fascia will be seen; and at the bottom of the space he will find the visceral layer of the pelvic fascia passing medially from the parietal layer to the bladder. Just to the lateral side of the junction of the lateral border with the posterior border of the bladder he will find the lower end of the ureter, and, if he passes a finger into the vagina, he will recognise that the lower end of the ureter is crossing a recess of the vagina, at the side of the lower end of the uterus, which is called the *lateral fornix* of the vagina (Fig. 248). If the lower border of the broad ligament is now carefully raised, the uterine artery will be found passing medially above the ureter to the side of the uterus (Fig. 248).

Having displayed the structures in front of the broad ligament, the dissector should turn to the posterior part of the pelvis, where he must carefully divide the peritoneum along the back of the lower border of the

[1] See p. 599.

broad ligament, and then turn the membrane behind the incision medially from the side wall of the pelvis to the rectum. When this has been done and the extra-peritoneal fat has been dissected away, the ureter, the divisions and branches of the hypogastric artery, the accompanying veins, and the pelvic plexuses of the sympathetic passing forwards at the sides of the rectum, will be exposed. Whilst this stage of the dissection is proceeding care must be taken to avoid injuring the parietal or the visceral pelvic fascia. The hypogastric vessels lie inside the fascia, and their visceral branches pierce the visceral layer, whilst the parietal branches pierce the parietal layer. The main nerve trunks and the trunks of the sympathetic are outside the parietal fascia ; therefore their branches do not pierce the fascia as they pass out of the pelvis. The obturator nerve, however, pierces the parietal pelvic fascia, from without inwards, at the posterior part of the pelvis, and runs forwards, lateral to the hypogastric vessels and below the pelvic brim, to the upper part of the obturator foramen, where it enters the obturator canal, through which it passes into the thigh.

When the extra-peritoneal fat has been removed, the general positions of the structures behind the broad ligament should be noted (Figs. 248, 249). The hypogastric artery serves as a prominent landmark as it descends at the junction of the side wall with the posterior wall of the pelvis. In front of the hypogastric artery the ureter runs downwards till it reaches the level of the visceral layer of the pelvic fascia; then it turns forwards and medially to the corresponding posterior angle of the bladder. In this part of its course it passes beneath the lower border of the broad ligament and the uterine artery, and obliquely above and in front of the upper end of the vagina.

The student should verify the important relations of the ureter to the vagina and to the uterus by passing a finger into the vagina, and noting that when the tip of his finger lies at the top of the vagina and at the side of the lower end of the uterus, it is immediately below the medial part of the lower border of the broad ligament, and that the ureter passes obliquely, from behind forwards and medially, across it.

Running forwards on the side wall of the pelvis, and passing to the lateral side of the ureter, will be found the obliterated part of the umbilical artery and the obturator nerve and vessels. In the female, the obliterated part of the umbilical artery is frequently below the level of the obturator nerve behind the broad ligament, but it rises above the nerve as it passes forwards. The uterine artery will be found descending in front of the ureter, before it turns medially to cross above the duct, beneath the lower border of the broad ligament. The hypogastric vein lies behind the stem of

the hypogastric artery, and frequently conceals its posterior division.

**Endo-Pelvic Fascia.**—This should now be examined. It is a strong membranous layer which is separable into two

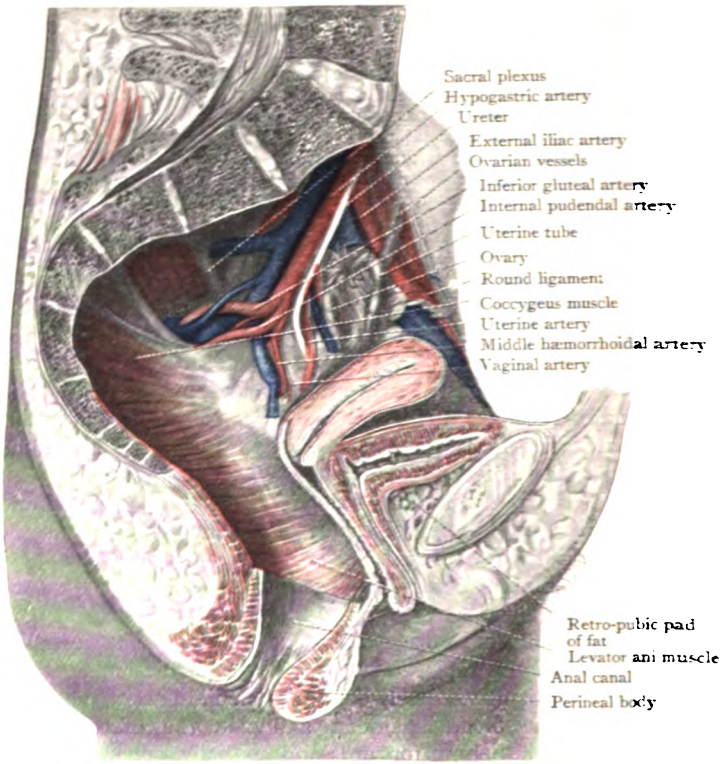


FIG. 348.—Dissection of a median section of a Female Pelvis, showing the Pelvic Diaphragm and the structures on the side wall of the Pelvis behind the Broad Ligament.

parts: a *parietal portion* which forms one of the strata of the walls of the pelvis; and a *visceral portion*, the upper fascia of the pelvic diaphragm, which forms part of the pelvic floor, and lies upon the muscular diaphragm which separates the pelvis proper from the perineum. The parietal layer passes down below the level of the visceral layer into the perineum, where it is still spoken of as parietal pelvic fascia.

The dissector should commence his examination of the fascia by noting that the parietal part is continuous above with the fascia on the psoas major muscle. Traced downwards from the psoas, it can be followed to the level of a line extending from the lower part of the back of the symphysis to the spine of the ischium, *i.e.*, to the level at which the visceral layer springs from its inner surface. Traced backwards, it passes lateral to the hypogastric vessels and then across the front of the sacrum to the opposite side, concealing the sacral plexuses and the piriformis muscles.

When it is traced forwards it will be found to terminate, anteriorly, along a curved line which commences at the medial side of the ilio-pectineal eminence, on the medial surface of the superior ramus of the pubis, descends to the lower border of the symphysis pubis, and then ascends to a corresponding point on the opposite side. The parietal fascia is deficient, therefore, on the anterior boundary of the lower part of the cave of Retzius. Each half of this anterior border of the parietal fascia is separable into three parts: A lateral part, where the fascia blends with the periosteum on the pelvic surface of the ascending ramus of the pubis; an intermediate part, below the highest portion of the obturator foramen, where the fascia turns over the upper border of the obturator internus and runs outwards into the thigh, forming the lower wall of the obturator canal; a median part, which is attached to the periosteum on the pelvic surface of the body of the pubis. Turning next to the visceral layer, the dissector will find as he traces it medially, in the posterior part of the pelvis, that the rectum sinks into its substance. In front of the rectum it is carried over the upper part of the vagina on to the uterus, and in front of the uterus it is lost on the bladder. Still more anteriorly, it can be followed across the median plane to the opposite side. In this last part of its extent two thickened bands of its substance, one on each side of the median plane, extend from the back of the pubis to the anterior border of the bladder. These bands are the medial pubo-vesical ligaments or anterior true ligaments of the bladder, already referred to. The dissector should note that the attachment of the visceral layer to the back of the body of the pubis lies at a higher level than the attachment of the anterior border of the parietal layer. In the space between the two lines of

attachment on each side the anterior fibres of the levator ani arise from the back of the body of the pubis.

The dissector should now turn to the perineum and examine the pelvic fascia from below. He has already seen that it forms the lateral wall of the ischio-rectal fossa and is carried medially from the margin of the pubic arch, as the superior fascia of the urogenital diaphragm, to the median plane, where it turns backwards along the urethra and round the anterior border of the levator ani.

He has seen also that the levator ani arises from the parietal fascia of the lateral wall of the ischio-rectal fossa and passes downwards and medially to the wall of the anal canal, into which many of its fibres are inserted. The levator ani must now be divided from before backwards, midway between its origin and its insertion, and the upper portion must be turned laterally towards the pelvic wall. When this has been done, the lower surface of the superior fascia of the pelvic diaphragm will be exposed, and the dissector will see, after the removal of the peritoneum and extra-peritoneal fat above, and the levator ani below, that the visceral fascia alone separates the pelvic cavity above from the perineum below, and he can convince himself that the visceral layer springs from the parietal layer immediately above the origin of the levator ani, and that, as it runs towards the median plane, it encloses the pelvic viscera. He will find also, if he traces the inferior surface of the visceral layer forwards, that it blends anteriorly, round the anterior border of the levator ani, with the upper fascia of the urogenital diaphragm, which is formed by the parietal layer of the pelvic fascia. He has still to demonstrate the cleavage of the visceral layer into secondary lamellæ which ensheathe the pelvic viscera. To do this he must take the following steps:—

*Dissection.*—Detach the crura of the clitoris from the margins of the pubic arch and trace the dorsal vein of the clitoris beneath the arcuate ligament. Divide the dorsal vein and turn the clitoris down. Separate the inferior fascia of the urogenital diaphragm from the margin of the pubic arch on each side, if that has not already been done during the dissection of the perineum. Examine the sphincter urethræ membranaceæ, which lies above the inferior layer of the urogenital diaphragm. Divide the sphincter urethræ membranaceæ on each side and turn it towards the median plane. Pass a probe into the urethra and note that the anterior fibres of the sphincter pass in front of the urethra, and that its posterior fibres pass over the wall of the vagina. Behind the sphincter urethræ membranaceæ lies the

upper fascia of the urogenital diaphragm, which is now seen from the front. Pass a finger into the vagina, and note that both the urethra and the vagina pass through the upper fascia of the urogenital diaphragm, which is reflected backwards along their borders.

Divide the upper fascia of the urogenital diaphragm on both sides, and again note that, at the sides of the urethra and the vagina, it is continuous round the anterior border of the levator ani with the visceral layer of the pelvic fascia.

Divide the pubes on each side, with the saw, along a line commencing on the margin of the pubic arch, below the attachment of the arcuate ligament, and terminating above at the lateral border of the tubercle of the pubis. Pass the knife behind the pubis and separate the visceral layer of the pelvic fascia from its attachment to the bone between the saw cuts. The separated piece of bone may now be removed and should be kept for the examination of the ligaments of the symphysis (see pp. 618, 650). If necessary, a further portion of the margin of the pubic arch may be removed, on each side, to give room for the examination of the relations of the vagina and the urethra. The dissector should now make his final examination of the pelvic fascia. Tracing the upper surface of the visceral layer medially, he will find that it spreads out on the infero-lateral surfaces and anterior border of the bladder, and that, below the bladder, it covers the front of the urethra and the vagina. The latter part presents a free border where it was detached from the back of the pubes, and beneath this border the dorsal vein of the clitoris can be traced towards the bladder, where it joins the vesical plexus. In this part of the fascia the two thickened bands which form the medial pubo-vesical ligaments will be noted. If the dissector next traces the fascia medially, *following its lower surface*, he will find that it passes behind the rectum, and he will thus demonstrate that the visceral layer of the pelvic fascia splits as it passes towards the median plane, one layer, *the vesical*, passing on to the bladder and in front of the urethra and vagina, and a second layer, *the rectal*, which passes behind the rectum. There is, however, a third layer, *the recto-vaginal*, which crosses between the rectum and the vagina. To demonstrate this layer the dissector should divide the vesical layer in the median plane in front of the bladder, and turn the lateral halves towards the lateral walls of the pelvis. In this way he will expose the urethra and the anterior wall of the vagina, the two being closely bound together, and when the lateral border of the vagina is reached he will find that the vesical layer of the fascia blends with a deeper layer which passes behind the vagina; this is the recto-vaginal layer. On the anterior wall of the vagina, and, more particularly, along its lateral border, the dissector should note a plexus of veins, the *vaginal plexus*.

The recto-vaginal layer of the pelvic fascia should be displayed from below also. To do this the dissector must cut transversely through the tissue of the perineal body, which lies in front of the anal orifice, until he reaches the junction of the anal passage with the rectum. When this point is attained he will find that he can quite easily separate the rectum from the vagina with his finger, and that intervening between the two is the recto-vaginal layer of fascia which he previously exposed from above.

Before terminating his study of the visceral layer of the pelvic fascia the student should note that the floor of the pelvic cavity of the female is formed, as in the male, by the levatores ani and the coccygei muscles, and the upper and lower fascial

layers of the urogenital diaphragm, but it is pierced by three canals instead of two, viz., the urethra and the anal passage, as in the male, and, between them, the vagina. In this way the floor of the pelvis, in the female, is rendered relatively weak

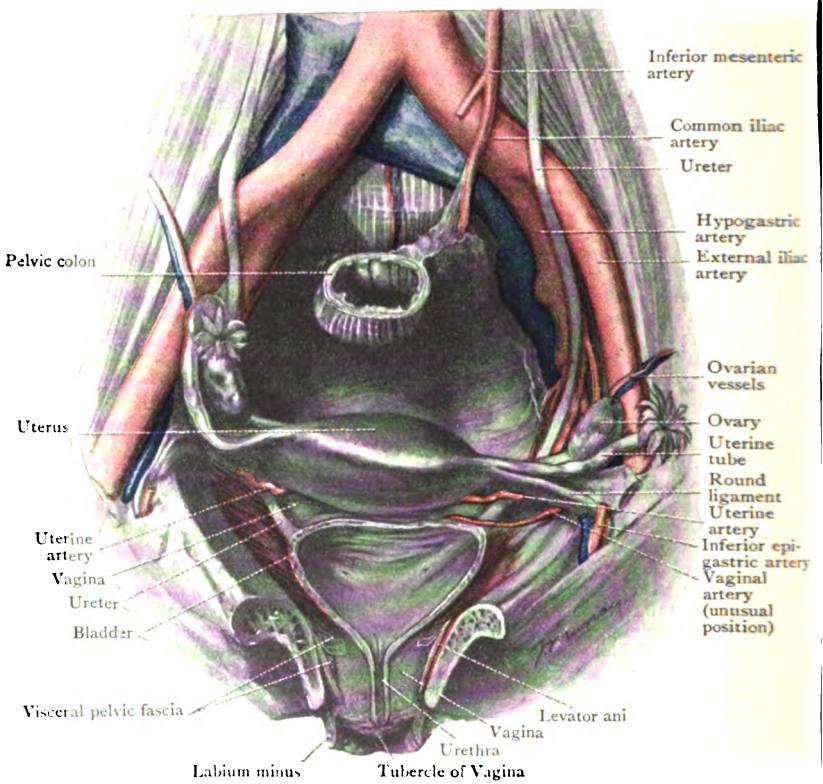


FIG. 249.—Dissection of the Pelvis of a multiparous female, showing the relations of the Bladder to the Uterus and Vagina, the relations of the Vagina to the Urethra and Broad Ligaments, and the relations of the Ureters to the Broad Ligaments and Vagina.

and less capable of resisting strain, whilst at the same time it is adapted to the function of child-bearing, for it is cleft by the [illegible]nal canal into two [illegible]—an anterior, including the vaginal wal[illegible]arts in front of it, and a formed b[illegible]ginal wall and the parts

behind it. The former can be lifted into the pelvis and the latter can be forced downwards, much as the two segments of a folding door are displaced in opposite directions, and thus a passage is made for the exit of the child (Berry Hart). The dissector should note also, as a matter of clinical importance, that, whilst the urethra and the anterior wall of the vagina are closely bound together and cannot be separated, except by the use of the knife, the posterior wall of the vagina and the anterior wall of the rectum are only loosely united together, and can easily be torn apart.

**Vesica Urinaria.**—The urinary bladder, in the female, has normally a smaller capacity, and it lies at a somewhat lower level in the pelvis than the male bladder; but its shape when empty and slightly contracted is the same as in the male, *i.e.*, it has the form of a three-sided pyramid, possessing a *superior surface*, two *infero-lateral surfaces*, a *fundus* or *base*, and an *apex*. The superior surface is covered with peritoneum. It is bounded by two lateral borders, which separate it from the infero-lateral surfaces, and by a posterior border, which separates it from the base. The two lateral borders converge anteriorly and meet at the *apex*, from which a fibrous cord, the middle umbilical ligament or urachus, passes up the posterior surface of the anterior abdominal wall to the umbilicus. The urachus is the remains of part of the cloaca of the fœtus. The lateral borders meet the posterior border of the upper surface at the *posterior angles* of the bladder, where the ureters enter the wall of the viscus. The infero-lateral surfaces, and the anterior border, which separates them, are devoid of peritoneum. They form the posterior wall of the lower part of the cave of Retzius, and are separated from the back of the symphysis and the pelvic surfaces of the pubic bones by a layer of loose, extra-peritoneal fat. The term *retro-pubic pad* is applied to that portion of the fatty tissue which intervenes between the back of the symphysis pubis, the upper surfaces of the medial pubo-vesical ligaments, and the anterior border of the bladder. To examine the relation of the fundus of the bladder to the uterus and vagina, the student must cut through the peritoneum at the bottom of the recto-vesical excavation, and then separate the bladder from the front of the neck of the uterus and the upper part of the anterior wall of the vagina. Whilst he is dividing the peritoneum he should notice that the

membrane may extend down over the fundus of the bladder for a very short distance.

**The False Ligaments of the Bladder.**—As in the male, there are five false ligaments of the bladder, two *lateral*, two *posterior*, and one *superior*. They are all formed by the peritoneum. The two *lateral* are merely the parts of the peritoneal membrane which connect the lateral borders of the superior surface of the bladder with the side walls of the pelvis; they form the floors of the paravesical fossæ. The *superior*, or middle umbilical fold, is the fold of peritoneum which is raised up by the middle umbilical ligament; and the two *posterior* are the ill-marked folds which pass from the upper part of the base of the bladder to the front of the neck of the uterus; they form the lateral boundaries of the utero-vesical excavation.

**The True Ligaments of the Bladder.**—These are five in number, two *anterior*, two *lateral*, one *superior*. The lateral and the anterior ligaments are portions of the visceral layer of pelvic fascia. The lateral pubo-vesical ligaments are merely the lateral parts of the vesical lamella; whilst the anterior or medial pubo-vesical ligaments are thickenings of the anterior part of the same lamella, one on each side of the median plane. The lateral connect the infero-lateral surfaces of the bladder to the main layer of the visceral pelvic fascia, and indirectly to the side wall of the pelvis. The anterior bind the anterior border of the bladder to the back of the symphysis pubis. It is doubtful if the term superior true ligament is properly applied, but it is sometimes given to the middle umbilical ligament, which connects the apex of the bladder with the anterior abdominal wall.

*Dissection.*—To examine the interior of the bladder, the dissector should make an incision through the anterior border, and through the infero-lateral surfaces immediately below their junction with the superior surface. When this has been done the superior surface should be raised and the anterior border and infero-lateral surfaces should be depressed; a good view of the interior will then be obtained. The mucous membrane should then be cleaned with a sponge and its general characters and the orifices of the bladder should be studied.

**The Mucous Membrane, the Trigone, and the Orifices of the Bladder.**—Over the greater part of the inner surface of the empty bladder the mucous membrane is rugose, on account of the laxity of its connection with the muscular coat; but in a triangular area on the lower part of the fundus,

which is known as the *trigone*, the connection is closer and the mucous membrane is always smooth. The rugæ on the other parts of the inner surface become unfolded as the bladder distends, until the whole inner surface is smooth. The trigone is also the most sensitive area of the bladder wall. At its apex, which marks the lowest point of the base of the bladder, is situated the semilunar or Y-shaped *internal orifice of the urethra*; and at its lateral angles, which are about one inch from each other and the same distance from the orifice of the urethra, lie the slit-like orifices of the ureters. The student should pass probes into the ureters; he will then be able to convince himself that each ureter runs for about three-quarters of an inch in the substance of the bladder wall, and that this part of each duct can be easily palpated through the anterior wall of the vagina. The obliquity of the ureters in the substance of the bladder wall is believed to produce a valve-like action of the lower parts of the ducts, permitting the passage of urine into the bladder, but preventing its return.

**Relations of the Bladder.**—The relations of the infero-lateral surfaces and the anterior border of the bladder are practically the same in the female as in the male (see p. 587), except that there is no prostate beneath the lower part of the anterior border, and the neck of the bladder, which is embraced by the prostate in the male, is closely bound to the anterior wall of the vagina in the female.

The superior surface, which is in relation, in the male, with coils of small intestine and pelvic colon, is overhung posteriorly by the uterus in the female, and is in relation with small intestine or a coil of the pelvic colon only in the anterior part of its extent. The fundus of the bladder, which, in the male, is in relation with the deferent ducts and the seminal vesicles, is closely bound, in the female, to the anterior surface of the neck of the uterus and to the upper part of the anterior wall of the vagina (Fig. 244).

**Peritoneal Relations.**—The peritoneal relations of the bladder are the same in the female as in the male (see p. 590), except that the upper part of the base may be covered by peritoneum in the female. The alterations in the peritoneal relations which occur as the bladder distends are the same in both sexes (see p. 588).

**Changes in the form of the Bladder.**—The changes which

occur in the form of the bladder as it passes from the empty to the distended condition are the same in the female as in the male (see p. 588).

**Urethra Muliebris (Female Urethra).**—The urethra is the canal by which the urine leaves the bladder. Its length is about one and a half inches, and it takes a slightly curved course from the neck of the bladder downwards and forwards to the base of the vestibule, where it opens on the surface by an aperture called the *orificium urethræ externum.* The orifice usually presents the appearance of a vertical slit, and lies immediately in front of a prominent projection of the mucous membrane at the lower extremity of the anterior vaginal wall. The projection is easily felt, and when the finger is passed over the vestibular area the position of the external orifice is readily localised. On its way to the surface the urethra passes through the two fasciæ of the urogenital diaphragm, and in the interval between them it is surrounded by the fibres of the sphincter urethræ membranaceæ muscle. In the whole of its length it is closely bound to the anterior wall of the vagina, and its walls are in close apposition, except when the passage is opened by the flow of urine through it.

The urethra should be split open longitudinally so that its coats can be examined. They are—(1) a muscular coat; (2) a submucous coat; (3) a mucous coat. The muscular coat consists of an outer layer of circular and an inner layer of longitudinal fibres. The circular fibres are strongly developed in the region of the neck of the bladder, where they form a distinct sphincter. The submucous coat connects the mucous coat loosely with the muscular coat. The mucous coat is thrown into longitudinal folds. It contains a number of gland follicles and lacunæ, and, in addition, there are present in its ventral wall two longitudinal tubules, the *para-urethral ducts*, which are known also as Skene's tubules. They open either into the canal, close to the orifice, or directly into the vestibule, close to the orifice.

**The Ureters.**—The pelvic portions of the ureters in the female are slightly longer than in the male, owing to the greater width of the pelvis and to the greater depth at which the bladder lies. Their relations to the hypogastric arteries and the structures on the side wall of the pelvis are practically similar to those of the male ureters (p. 592); but the relations of the

lower part of each duct, which runs medially from the sidewall of the pelvis to the fundus of the bladder, are very different in the two sexes, and in the female they are of great practical importance in association with operations on the lower part of the uterus and the upper part of the vagina. This portion of the ureter, in the female, passes obliquely beneath the lower border of the broad ligament and obliquely across the side

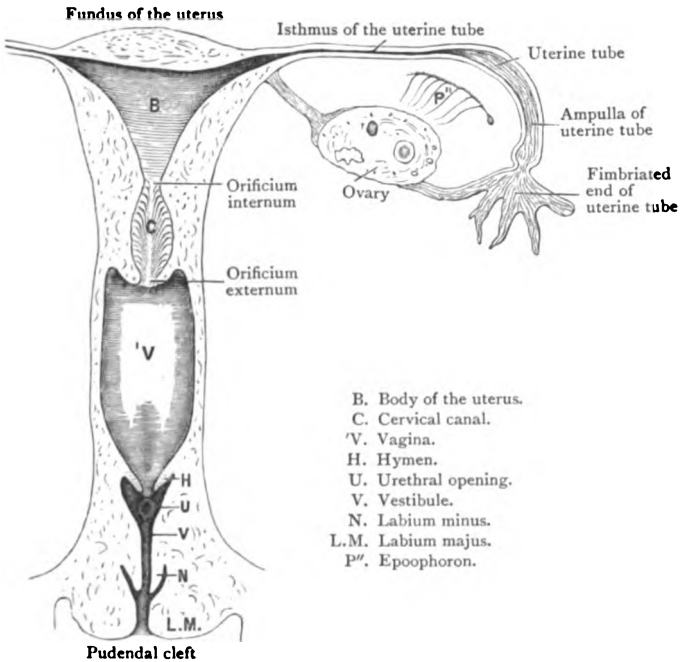


FIG. 250.—Diagram of the Vulva, Vagina, and the Uterus, with its Appendages. (Symington.)

and front of the upper end of the vagina (Fig. 249), and it enters the corresponding posterior angle of the bladder about two inches from its fellow of the opposite side. Beneath the broad ligament, and at the lateral border of the upper end of the vagina, the uterine artery crosses above it, and, just before it enters the bladder, it lies immediately in front of the upper part of the anterior vaginal wall (Fig. 249). When the bladder is distended and the vagina is narrow the posterior

angles of the bladder may extend beyond the lateral borders of the vagina; in such cases the relation of the ureter to the vagina is much less intimate.

**Uterus.** — The uterus is the organ in which the impregnated ovum is retained until the fœtus is fully developed. It lies in the middle part of the pelvis, resting upon the posterior part of the upper surface of the bladder, and lying beneath coils of small intestine. It is of modified piriform shape, being flattened from before backwards. It measures about three inches in length (75 mm.), and its long axis lies in the axis of the upper aperture of the pelvis minor, and almost at right angles with the long axis of the vagina (Fig. 244).

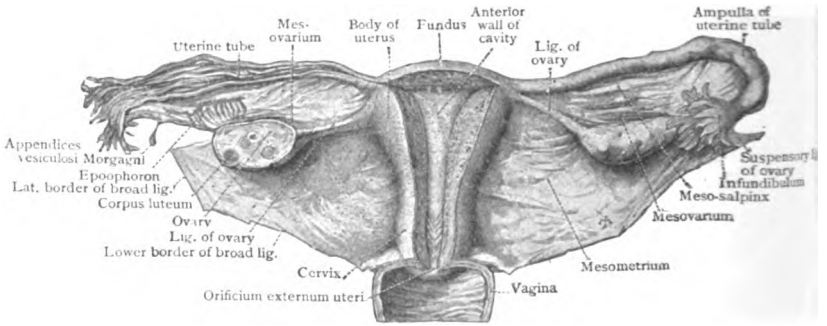


FIG. 251.—The Uterus, the Uterine Tubes, the Ovaries, the Broad Ligaments, and the upper part of the Vagina, seen from behind. The posterior wall of the uterine cavity has been removed, and the left Uterine Tube and the upper part of the Vagina have been opened.

Its *breadth*, at the broadest part, is about two inches, and its greatest *thickness* is one inch. Its broad, upper end is directed upwards and forwards, and is continuous at each side with a uterine tube. Its narrower, lower end is directed downwards and backwards, and passes through the upper part of the vaginal wall into the cavity of the vagina.

It is customary to describe the uterus as consisting of three parts, viz., a fundus, a body, and a cervix.

**Fundus Uteri.**—The fundus is that portion of the rounded upper end which lies above a line drawn transversely across the organ between the points where the uterine tubes enter. It is completely covered with peritoneum.

**Corpus Uteri.**—The body of the uterus diminishes in breadth as it proceeds downwards to the neck. In front and

behind, it is convex, the convexity of the posterior surface, however, being much more marked, especially in its upper part, than that of the anterior surface. Each lateral border is connected to the corresponding broad ligament, and immediately below the entrance of the uterine tube it is joined, in front, by the *round ligament*, and, behind, by the *ligament of the ovary*. Inferiorly, the body of the uterus is marked off from the cervix by a slight constriction, which, although very apparent in the infant, becomes less distinct as puberty approaches, and usually disappears altogether after parturition. This constriction is called the *isthmus*.

**Cervix Uteri.**—The cervix, or neck, of the uterus is about an inch in length (25 mm.); it is narrower than the body and more cylindrical in form. It projects into the upper end of the vagina, the walls of which are attached around it.

To obtain a satisfactory view of the relation of the uterus to the vagina, both organs should now be split sagittally, care being taken to avoid injuring the rectum. When this has been done, the posterior wall of the vagina will be found to ascend to a higher level on the cervix than the shorter anterior wall (Figs. 244, 247). On the lower extremity of the cervix, which rests against the posterior vaginal wall, there is an orifice, the *orificium externum uteri* (O.T. *os uteri externum*). This opening, in nulliparæ, is always a small transverse slit, with rounded anterior and posterior lips, but in women who have borne children it is usually larger, and its margins are more irregular in outline. The anterior lip is the shorter, and it is placed at a lower level in the vagina. This difference in the level and in the length of the two lips is due to the fact that the uterus passes obliquely through the vaginal wall. The part of the cervix which projects into the vagina is the *vaginal portion*; the part above is termed the *supravaginal portion*.

**Cavum Uteri.**—The cavity of the uterus is separable into two parts, the cavity of the body and the cavity of the cervix. The cavity of the body is a mere cleft, triangular in outline, which lies between the anterior and posterior walls. The base of the triangle is above, and at each of its angles a uterine tube opens into the cavity. The apex is below, where the cavity of the body joins the cavity of the cervix, at a constricted aperture of communication called the *orificium internum uteri* (O.T. *os uteri internum*).

The cervical portion of the cavity is spindle-shaped and slightly compressed from before backwards. It extends from the internal orifice, where it is continuous with the cavity of the body, to the external orifice, where it opens into the vagina.

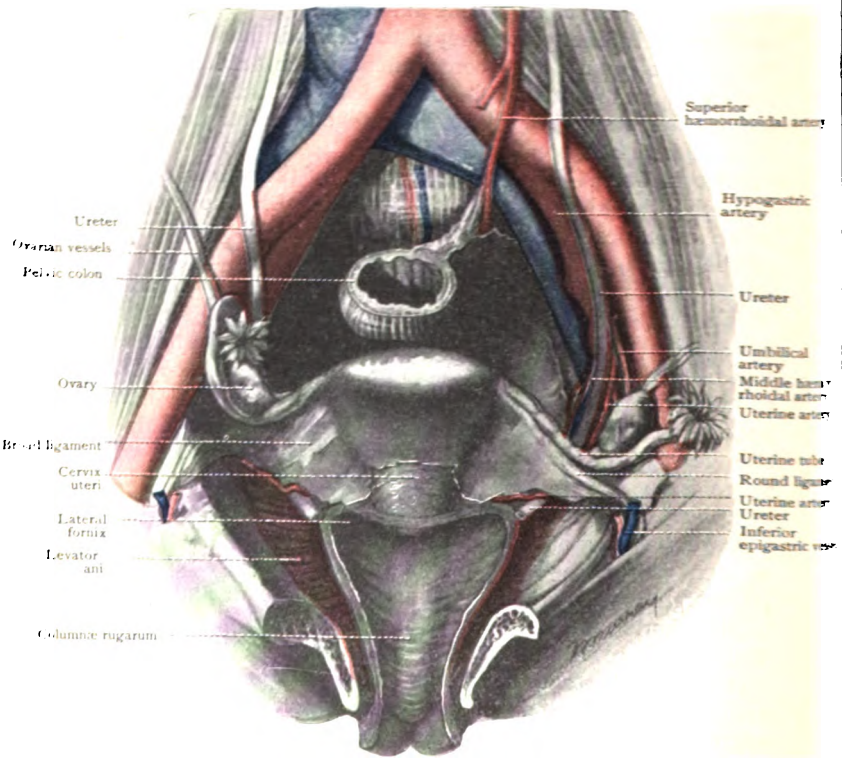


FIG. 252.—Further Dissection of the Pelvis shown in Fig. 249. The Uterus has been pushed backwards, and the Bladder, the lower parts of the Ureters, and the anterior wall of the Vagina have been removed.

**The Relations of the Uterus.**—The posterior surface of the uterus is completely covered with peritoneum, and it is separated from the rectum by the recto-vaginal excavation, in which lie coils of the small intestine and part of the pelvic colon. The anterior surface of the body, which rests on the bladder, is covered with peritoneum, but the anterior surface of the

cervix is devoid of peritoneum, and is in direct relation with the fundus of the bladder. The lateral borders of the uterus are connected with the broad ligaments, and between the layers of the ligaments each is associated with the corresponding uterine artery, and uterine plexus of veins, which are embedded in a mass of loose fatty tissue called the *parametrium*. The parametric tissue is most abundant in the region of the upper part of the vagina and at the side of the neck of the uterus.

**Ligamentum Teres Uteri (Round Ligament).**—The round ligaments of the uterus are two cord-like bands, one on each side, composed of involuntary muscle fibres and connective tissue. They are attached to the body of the uterus, immediately below and in front of the entrance of the uterine tubes. Each ligament runs forwards and laterally from the uterus, between the layers of the broad ligament, to the side wall of the pelvis. There it lies for a short distance on the external iliac vessels, and then turns round the inferior epigastric artery, and passes through the abdominal inguinal ring into the inguinal canal, where it has already been examined. It represents the lower part of the gubernaculum of the ovary, the upper part being represented by the ligament of the ovary.

**Position of the Uterus.**—In women who have borne no children (nulliparæ), and in whom the bladder and the rectum are both empty, the uterus is normally *anteflexed* and *anteverted*. The statement that the uterus is anteflexed means that it is bent forwards on itself at the isthmus, so that the body and the cervix meet at an angle which is open in front. This forward flexion depends upon two circumstances, viz.—(1) upon the greater pliability of the body as compared with the firmer consistence and greater resistance of the cervix; and (2) upon the fact that the cervix is more or less held in position by its attachments to the anterior vaginal wall and the fundus of the bladder in front, and to the posterior vaginal wall behind. The term anteversion means that the whole uterus—body and cervix—is inclined forwards and forms an angle of greater or less magnitude with the vertical axis of the trunk. In this position of the uterus, coils of small intestine and a loop of the pelvic colon rest upon its posterior surface, and its anterior surface is supported by the bladder. It is only on rare occasions that a coil of small

intestine is found between the uterus and the bladder, in the utero-vesical pouch of peritoneum. In multiparæ (women who have borne children) the anteflexion is not so marked as in nulliparæ.

The uterus possesses a great degree of mobility, however, and its position is constantly liable to change, but under no circumstances does it occupy an exactly median position. As a rule, its anterior surface is directed forwards and to the

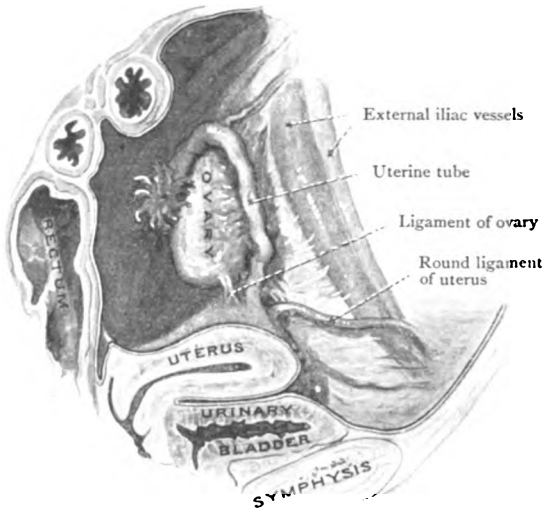


FIG. 253.—Left Side Wall of Female Pelvis to show position of the Ovary. The ovary is much scarred owing to the shedding of ova.

right. The ordinary anteflexion and anteversion may be diminished or exaggerated by alterations of the general intra-abdominal pressure, and by distension of the bladder and the rectum. They may be altered also by pathological contractions of the peritoneal ligaments connected with the uterus, or of the connective tissue between the folds of the ligaments. Every contraction of the diaphragm, every movement of the body, is accompanied or followed by some slight change in the position of the uterus. When the bladder fills, the uterus is raised, the anteflexion and anteversion become less marked, and, in cases of over-distension of the bladder, the uterus may assume an erect position, or may be even forced back-

wards until it lies in the same line as the vagina. When the uterus attains the last-mentioned position it is said to be *retroverted*. As it becomes retroverted the coils of intestine are displaced from the recto-vaginal excavation, and the uterus is forced into intimate relation with the rectum. When the rectum becomes distended the uterus is pushed forwards and usually to the right side.

*Dissection.*—When the examination of the relations of the uterus is concluded, the dissector should cut through the rectum in the median plane. Then, with the saw, he should divide the sacrum and coccyx to the left of the middle sacral vessels, and when this has been done he should cut through all the remaining tissues in the same plane and separate the two halves of the pelvis. All the remaining stages of the dissection and examination can be carried out on each half separately.

**Vagina.**—The vagina is the passage which leads from the uterus to the vulva. In length it is about three inches, and it is widest at its upper end. Its distensibility is very great, to allow the passage of the child during parturition. The direction of the canal, when the bladder and rectum are empty, is from above downwards and forwards, parallel with the plane of the superior aperture of the pelvis minor, so that it forms with the uterus an angle which is open towards the symphysis. Its anterior and posterior walls are closely applied, and in section, therefore, its cavity appears either as a transverse or as a longitudinal slit, according to the direction in which it is divided (Figs. 244 and 245).

At its upper end the vagina is attached round the neck of the uterus, upon which it ascends farther posteriorly than anteriorly, so that the uterus appears to pierce the anterior wall of the vagina. The shallow sulcus at the upper end of the cavity of the vagina, around the neck of the uterus, is known as the *fornix* of the vagina. It is formed by the reflection of the mucous membrane of the vagina on to the neck of the uterus, and is separable into anterior, posterior, and lateral parts. The dissector should examine carefully the relations of the fornices. The *anterior fornix* is in relation with the base of the bladder. The *posterior fornix* is in relation with the recto-vaginal excavation of peritoneum, and therefore an injury of the vagina in that region may open into the lower part of the peritoneal cavity. Each *lateral fornix* lies below the lower medial angle of the broad ligament, and is in close relation with the ureter, the uterine artery, and the mass of

fatty, vascular tissue, previously mentioned as the parametrium. The opening of the lower end of the vagina into the urino-genital cleft is partly closed, in the virgin, by the ***hymen***. This is formed by two antero-posteriorly placed crescentic folds which are united in front and behind. After the hymen has been ruptured, its torn fragments, called *caruncula hymenales*, persist round the opening.

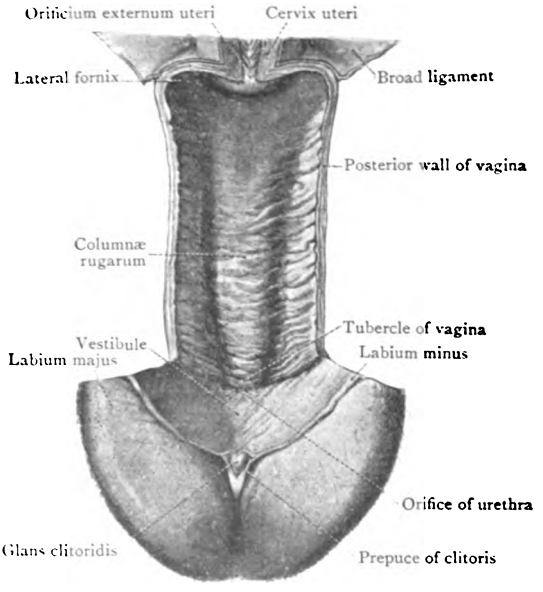


FIG. 254.—The lower part of the Cervix Uteri, the anterior wall of the Vagina, and the Vestibule. The Vagina has been opened from behind.

**The Relations of the Vagina.**—The posterior wall of the vagina is in relation, above, with the recto-vaginal excavation of peritoneum. Below this, it is in apposition with the anterior wall of the rectum (Fig. 244). The anterior wall of the vagina is related to the lower part of the base of the bladder and to the urethra. The lower end of the vagina is embraced between the vestibular bulbs, and is clasped by the bulbo-cavernosus, and each lateral border is supported by the corresponding levator ani muscle. The anterior borders of the vatores ani muscles, as they pass backwards from the pubic

bones to the central point of the perineum, closely embrace the vagina, and act as a superior or second sphincter of the canal (Figs. 249, 252).

**Tubæ Uterinæ** (O.T. **Fallopian Tubes**).—There are two uterine tubes, one on each side, and their function is to convey ova from the ovaries to the uterus. Each uterine tube is about four inches long, and it is contained, in the greater part of its length, in the medial four-fifths of the upper border of the broad ligament. Its medial end pierces the uterus at the junction of the body and fundus. At a short distance from its lateral end it pierces the surface of the broad ligament, curls over the upper pole of the ovary, and opens into the peritoneal cavity by a constricted orifice, the *ostium abdominale*, which is surrounded by a number of fringe-like processes called the *fimbriæ*. By one of these fimbriæ, the *fimbria ovarica*, it is attached to the tubal or upper pole of the ovary. Its calibre is by no means uniform. As it is traced from the uterus it is at first very narrow, scarcely admitting a bristle. This portion is the *isthmus tubæ uterinæ*. More laterally it dilates considerably, and becomes convoluted and less closely attached to the peritoneum of the broad ligament. This part is called the *ampulla tubæ uterinæ*, and the *fimbriæ*, which are merely the segments of the cleft wall of a funnel-like extremity, constitute collectively the *infundibulum tubæ uterinæ*. The ovarian fimbria is longer than the others, and is attached along its whole length to the broad ligament. On its surface is a gutter-like groove leading from the constricted mouth of the tube to the ovary. Traced from the uterus, the tube runs first laterally, then, at the side wall of the pelvis, it turns upwards, and finally, having gained the upper pole of the ovary, it bends downwards and covers the posterior free border and the greater part of the medial surface of the ovary (Fig. 253).

**Ovarium (The Ovary).**—The ovaries are two small, solid bodies, each of which is attached to the posterior surface of the corresponding broad ligament, by a secondary fold of the posterior layer of the ligament called the *mesovarium*. Each ovary has the form of a slightly compressed ovoid, and is about the size of a pigeon's egg. It presents two flattened surfaces, two extremities or poles, and two borders.

Its natural or typical position can be studied only in women who have borne no children, for the ovaries become

displaced during pregnancy, and it is doubtful if they ever regain their original positions. In the nulliparous female each ovary occupies a peritoneal fossa on the back part of the side wall of the pelvis, below the external iliac vessels and in front of the hypogastric vessels and the ureter. This recess is termed the *fossa ovarica*. The long axis of the ovary is vertical. From its *upper pole* the suspensory ligament of the ovary passes to the side wall of the pelvis, and to the same extremity the mouth of the uterine tube is attached by one of its fimbriæ; from the latter connection the upper pole is frequently called the *tubal extremity* of the ovary. The lower, or *uterine extremity*, is connected with the lateral border of the uterus, immediately below and posterior to the entrance of the uterine tube, by the round cord-like *ligament of the ovary*, which lies in the medial part of the mesovarium, and is a remnant of the gubernaculum of the ovary. The *anterior border* is thinner and straighter than the posterior border. It is commonly called the *attached border* or *hilum*, because it is connected to the back of the broad ligament by the mesovarium, and through it the vessels and nerves pass into and out of the ovary. The *posterior border* of the ovary is free, and looks backwards towards the ureter.

In the natural position of the organs the uterine tube encircles the greater part of the circumference of the ovary.

On each surface of the ovary, close to the anterior border, a white line marks the transition of the flat endothelial cells of the peritoneum into the cubical epithelium of the surface of the ovary. Before puberty the surface of the ovary is smooth; after that period it becomes scarred and puckered by the cicatrices which mark the positions of the ruptured Graafian or vesicular ovarian follicles from which ova have escaped.

**Epoophoron** (O.T. **Parovarium**).—This structure is of interest because it represents the lobules of the epididymis and part of the duct of the epididymis of the male. The dissector will find it by stretching the broad ligament, holding it to the light, and examining the lateral part, between the ovary and the uterine tube. It lies between the layers of the broad ligament, and consists of a horizontal tubule and a series of vertical tubules. The vertical tubules radiate from the region of the hilum of the ovary to the horizontal tubule, in which they terminate. The horizontal tubule lies about midway between the ovary and the uterine tube, and runs parallel with the latter.

Traced towards the uterus, it is found to end blindly. Laterally, it may end in a similar manner, or it may pierce the posterior layer of the broad ligament and end in a dilated vesicle, of piriform shape, called the *vesicular appendix* or *hydatid of Morgagni*. This may be attached to one of the fimbriæ of the uterine tube.

**The Rectum.**—A detailed account of the rectum in the male is given on p. 582; the student should read that account and then note the points of difference in the female.

In the upper part of its extent the rectum of the female is separated from the uterus and vagina by the recto-vaginal excavation of peritoneum and the coils of intestine which it

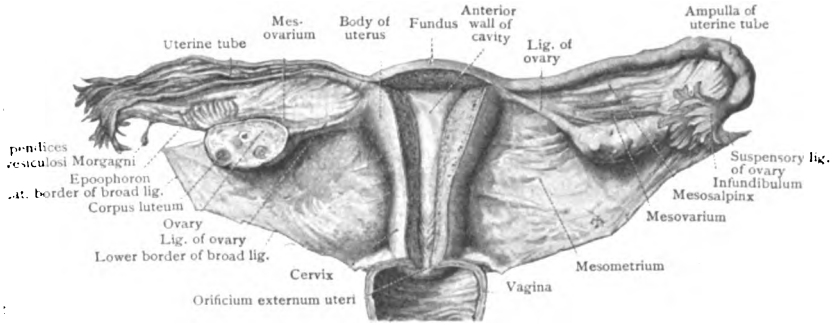


FIG. 255.—The Uterus, with the Broad Ligaments stretching out from its sides.

contains. Below the bottom of the pouch the rectum is in apposition with the posterior wall of the vagina, the layer of recto-vaginal fascia alone intervening. The connection between the rectal and vaginal walls is very loose above, but is closer below. This arrangement has an important bearing upon the manner in which prolapse of the uterus occurs.

**The Anal Canal.**—The anal canal bends downwards and backwards from the rectum, commencing about one inch and a half in front of the tip of the coccyx and terminating at the anal orifice. An angular area is thus left between the anterior wall of the canal and the back of the genito-urinary cleft. This area is occupied by a pyramidal mass of firm fibro-muscular tissue called the *perineal body*.

## The Pelvic Blood-vessels.

The manner in which the pelvic blood-vessels should be dissected has been described on p. 597. In the female, the dissector will find three arteries which were either not studied at all, or not under the same name, in the dissection of the male pelvis, viz.—

1. The uterine, } branches of the hypogastric.
2. The vaginal, }
3. The ovarian, from the abdominal aorta.

**Arteria Uterina.**—The uterine artery springs either from the anterior division of the hypogastric or from the umbilical artery. It runs downwards in front of the vertical part of the pelvic portion of the ureter, and then medially along the lower border of the broad ligament and above the lower part of the ureter (Figs. 249, 252). Having crossed the ureter, it passes above the lateral fornix of the vagina and turns upwards along the side of the uterus. It ends by anastomosing with branches of the ovarian artery beneath the isthmus of the uterine tube. It gives branches to the uterus, the vagina, and the isthmus of the uterine tube, and frequently it supplies twigs to the ovary.

**Arteria Vaginalis.**—The vaginal artery springs from the anterior division of the hypogastric artery. It probably represents the inferior vesical artery of the male, and whilst it is distributed mainly to the vagina it gives twigs also to the base of the bladder and to the rectum.

**Arteria Ovarica.**—The ovarian artery corresponds to the internal spermatic artery of the male, and the abdominal part of its course is similar to that of the latter artery. When it arrives at the pelvis it crosses the upper part of the external iliac vessels, and insinuates itself between the two layers of the broad ligament where they form the suspensory ligament of the ovary. It is highly tortuous, and is enclosed, in the terminal part of its extent, in the coils of the *pampiniform plexus* formed by the veins which issue from the hilum of the ovary. Its terminal branches are distributed mainly to the ovary, which they enter at the hilum, but some pass on to anastomose with branches of the uterine artery. It supplies twigs to the uterine tube also.

The remaining arteries of the female pelvis correspond very closely to those of the male, of which descriptions will be found on pp. 598-601.

**The Veins of the Pelvis.** — Little requires to be said beyond what was stated regarding the veins of the male pelvis on p. 602. The pudendal plexus, into which the *dorsal vein of the clitoris* opens, is smaller than in the male, but is connected in a similar manner with the vesical plexus.

A bulky *uterine venous plexus* is formed on each side of the uterus, between the two layers of the broad ligament. This enters into the formation of the parametrium, and from its lower part the blood is drained away by one or more uterine veins which end in the hypogastric vein.

A *vaginal venous plexus* is also formed around the vagina. It is most dense along each lateral border, in the angle between the vesical and the recto-vaginal layers of the pelvic fascia. One or more *vaginal veins* proceed from its upper end on each side; they end in the hypogastric veins.

A *pampiniform plexus of veins* is formed by the veins which issue from the hilum of the ovary. From this plexus, which lies between the layers of the broad ligament, two ovarian veins issue. They accompany the ovarian artery, and ultimately fuse into a single vein which ends in a manner similar to the corresponding internal spermatic vein of the male (p. 542).

**The Pelvic Lymph Vessels.**—The lymph vessels of the bladder and rectum are the same in the female as in the male (see p. 603); but, in the female, the lymph vessels of the vagina, uterus, uterine tubes, and ovaries, have also to be considered. Lymph vessels from the lower part of the vagina pass to the superficial subinguinal and the sacral lymph glands. From the middle and upper parts of the vagina and from the cervix uteri they pass to the hypogastric and external iliac and the sacral lymph glands. From the body of the uterus they pass to the external iliac and hypogastric lymph glands and along the round ligament to the superficial subinguinal lymph glands. The lymph vessels from the upper part of the uterus and from the ovary terminate in the lymph glands around the aorta.

## The Visceral Nerves of the Pelvis.

Very little requires to be added to what has already been said about the visceral nerve plexuses (p. 608). There is no *prostatic plexus*; but a *vaginal plexus*, an *ovarian plexus*, and a

*uterine plexus* are present in addition to those mentioned in the description of the male pelvis.

The *uterine plexus* proceeds from the pelvic plexus. It ascends between the layers of the broad ligament, along the uterine artery, and is distributed to both aspects of the uterus.

The *vaginal plexus* is also an offset from the pelvic plexus, and the nerves which compose it are derived mainly from the visceral branches which enter the pelvic plexus from the third and fourth sacral nerves.

The *ovarian plexus* is derived from the aortic and renal plexuses. It accompanies the artery of the same name, and is distributed to the ovary.

*Dissection.*—When the blood-vessels and the visceral nerve plexuses have been examined, the pelvic viscera should be removed. The vessels and nerves passing to them must be cut; the visceral layer of pelvic fascia on the upper surface of the levator ani must be divided, from before backwards, and stripped medially from the upper surface of the muscle. Finally, the rectum must be separated from the upper end of the anal canal, and then the viscera can be removed. When this has been done the structure of the walls of the viscera should be studied.

**Structure of the Uterus.**—The uterus possesses three well-marked coats—a serous or peritoneal, a muscular and a mucous. The *serous covering* has already been fully studied (p. 623). The *muscular part* of the wall constitutes its chief bulk. It is composed of involuntary muscular tissue, with a considerable admixture of areolar tissue. It is not equally thick throughout, and is relatively thin towards the angles or points where the uterine tubes open into the uterus.

The *mucous membrane* which lines the cavity is not of uniform appearance. In the body of the uterus it is smooth and closely bound to the adjacent muscle. In the cervix it presents a striking arrangement, which from its appearance has been termed the *arbor vitæ*. This consists of a series of prominent folds or rugæ, called *plicæ palmatæ*, arranged in a definite manner. There is a median fold on the anterior and another on the posterior wall of the canal. Secondary folds branch off from each median fold and pass obliquely upwards and laterally. The plicæ palmatæ are better marked on the anterior than on the posterior wall. Between the plicæ palmatæ the dissector may discover some minute vesicles filled with yellowish fluid; these are the *ovula Nabothi*. They result from the obstruction of the mouths

and the distension of the cavities of certain tubular glands which lie in the mucous membrane.

**The Coats of the Vagina.**—The vagina possesses an external muscular coat, an internal mucous coat, and an intermediate layer of erectile tissue. The muscular coat is formed of unstriped muscle fibres arranged in two layers, an external longitudinal layer and an internal circular layer, of which the former is much the stronger. The mucous membrane presents two well-marked median longitudinal folds, one on the anterior, and one on the posterior wall. They are termed the *columnæ rugarum*, and from each side they send off numerous transverse ridges, which are arranged so that those of the anterior wall fit in between those on the posterior wall. The folds are best marked near the vaginal orifice, and are absent at the upper part of the canal. The intermediate layer of erectile tissue is thin.

**Structure of the Uterine Tubes.**—Each uterine tube has an external serous, an intermediate muscular, and an internal mucous lining coat. The serous coat is the peritoneal covering formed by the layers of the broad ligament. The muscular coat consists of an external longitudinal and an internal circular layer of unstriped muscle fibres. The tube is so narrow in the region of the isthmus that the mucous membrane in that region can be satisfactorily examined only in sections and with the aid of the microscope, but the ampulla is easily opened, and when this has been done the dissector will recognise that the mucous membrane is arranged in longitudinal folds. To obtain a proper idea of the fimbriæ the tube should be immersed in water, when they will float out and separate from each other.

**The Coats of the Rectum and Anal Canal.**—The coats of these portions of the intestinal canal are identical in both sexes. The student should refer, therefore, to p. 609, where the walls of the male rectum and anal canal are described.

*Dissection.*—When the dissector has completed his study of the structure of the pelvic viscera he should return to the investigation of the pelvic spinal nerve plexuses, and the sympathetic trunk, and the coccygeal glomus (see p. 609). After he has satisfied himself regarding the formation and distribution of the plexuses, and the position and connections of the sympathetic trunk, he should study the pelvic diaphragm.

The sacral, the pudendal, and the coccygeal nerve-plexuses are the same in both sexes, and the description of their constitution and relations will be found on pp. 605 and 608.



PLATE I

Radiograph of the Shoulder-joint. Showing the relation of the head of the humerus to the acromion and the coracoid process.

Note the epiphyseal line of the proximal end of the humerus.

(Radiograph by Mr. A. D. Reid.)

The pelvic portions of the sympathetic trunks are described on p. 609.

The position and constitution of the coccygeal glomus are given on p. 609.

## The Pelvic Diaphragm.

This is described on pp. 556, 604. The dissector should note that the levator ani muscle passes downwards and backwards and that it gives support to the lateral border of the vagina; he should note also that the anterior borders of the two levatores ani muscles embrace the lower part of the vagina very closely, and exert a sphincter action upon it.

*Dissection.*—After he has studied the pelvic diaphragm the dissector should remove the levator ani to display the obturator internus, and examine the attachment and arrangement of that muscle (see p. 612). He should then study the piriformis (see p. 612), and should complete his dissection of the pelvis by an examination of the pelvic articulations.

**The Pelvic Articulations.**—These are described at p. 612. In the later months of pregnancy the ligamentous structures of the various pelvic joints become softened and thickened by the infiltration of fluid. The pelvic bones are thus separated from each other to some extent, and the calibre of the pelvic canal is increased, in preparation for the passage of the child.

For radiograms of Abdomen and Pelvis see end of volume.

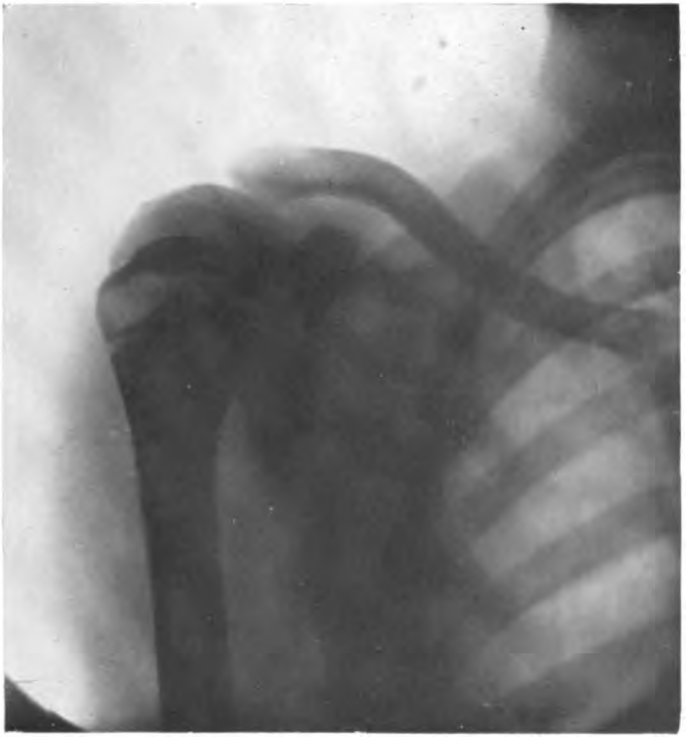

PLATE I

**Radiograph** of the Shoulder-joint. Showing the relation of the head of the **humerus** to the acromion and the coracoid process.

Note the epiphyseal line of the proximal end of the humerus.

(Radiograph by Mr. A. D. Reid.)

PLATE II

Radiograph of the Elbow-joint.

Note (1) The medial epicondyle has not yet united with the shaft.
(2) The proximal epiphysis of the radius.
(3) That the nodular epiphysis of the olecranon is not distinctly visible.

(Radiograph by Mr. A. D. Reid.)

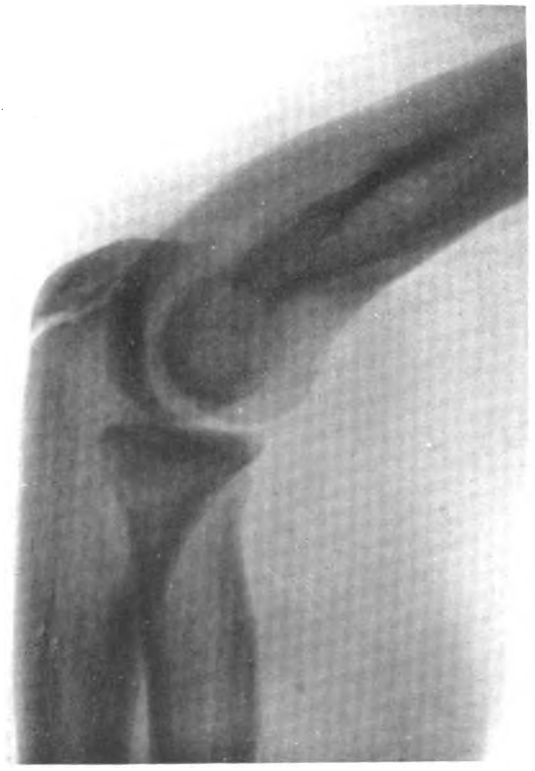

PLATE III

Radiograph of the Elbow-joint taken from the side.

Note the epiphysis of the olecranon.

(Radiograph by Mr. A. D. Reid.)

PLATE IV

Radiograph of a normal adult Elbow-joint.

Note that the joint-line produces the appearance of separation of the olecranon.

(Radiograph by Dr. C. Gouldesbrough.)

PLATE IV

Radiograph of a normal adult Elbow-joint.

Note that the joint-line produces the appearance of separation of the olecranon.

(Radiograph by Dr. C. Gouldesbrough.)

PLATE V

Radiograph of the Hand of a Child.

Note (1) The distal epiphyses of the radius and ulna.
(2) That the os multangulum majus is not yet ossified.
(3) The proximal epiphyses of the metacarpal bone of the thumb and the phalanges.
(4) The distal epiphyses of the four medial metacarpal bones.

(Radiograph by Mr. A. D. Reid.)

PLATE VI

Radiograph of an adult Hand.

**Note** the sesamoid bone at the metacarpo-phalangeal joint of the thumb.

(Radiograph by Dr. C. Gouldesbrough.)

PLATE VII

Radiograph of the Pelvis of a subject over 10 and under 15 years old.
(Radiograph by Dr. C. Gouldesbrough.)

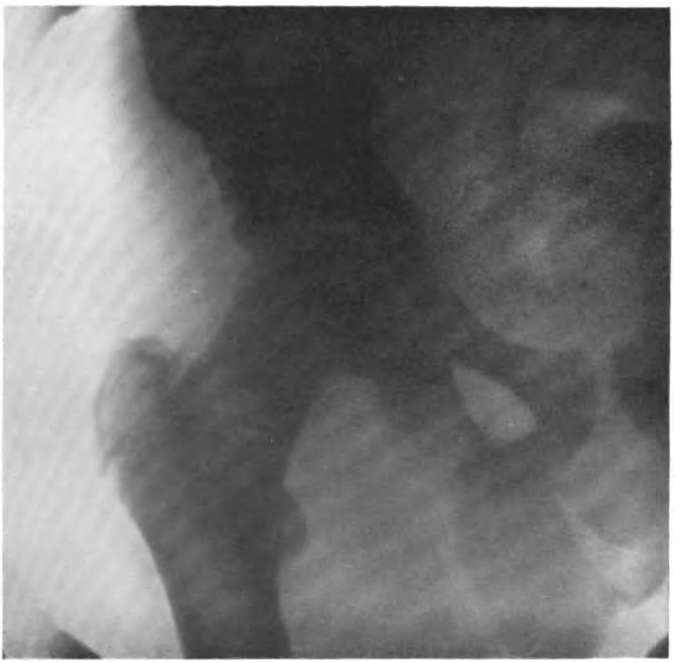

PLATE VIII

Radiograph of the Hip-joint of a young subject.

Note the epiphyseal line of the greater trochanter.

(Radiograph by Dr. C. Gouldesbrough.)

PLATE IX

Radiograph of a normal Hip-joint in an adult.

(Radiograph by Dr. C. Gouldesbrough.)

PLATE X

Radiograph of the Knee-joint taken from the side.

Note the sesamoid bone in the lateral head of the gastrocnemius. (From one of Professor Alexis Thomson's cases.)

## PLATE XI

Radiograph of the distal end of the Leg and the posterior part of the Foot.

Note (1) The distal epiphysis of the tibia.
(2) The epiphysis of the calcaneus.
(3) The epiphysis at the posterior end of the 1st metatarsal.

(Radiograph by Dr. C. Gouldesbrough.)

PLATE XII

Radiograph of the Renal Pelvis and the Lumbar portion of the Ureter, injected with collargol. By Frank Kidd, F.R.C.S.

Note (1) The relation of the pelvis of the ureter to the last rib.

(2) That the ureter does not possess the usual convex curve towards the median plane.

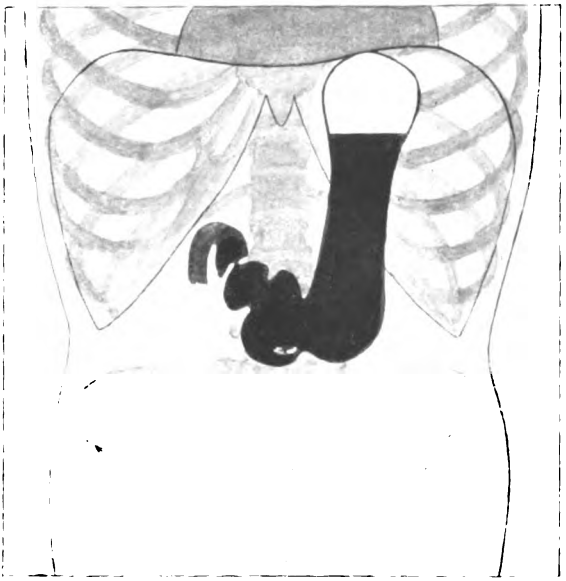

PLATE XIII

Drawing from radiograph of normal stomach as seen in the vertical position after an ordinary bismuth and barium meal consisting of two ounces of bismuth and two ounces of barium sulphate. It shows the depressions caused by peristaltic contractions towards the pylorus, and as these are constantly moving towards the pylorus they are not due to fixed anatomical constrictions, and are therefore omitted from the other plates. The pylorus and commencement of the duodenum are shown.

As the drawing was made orthodiagraphically, it is therefore to scale and not distorted. Drawing by A. F. Hertz, M.D., F.R.C.P.

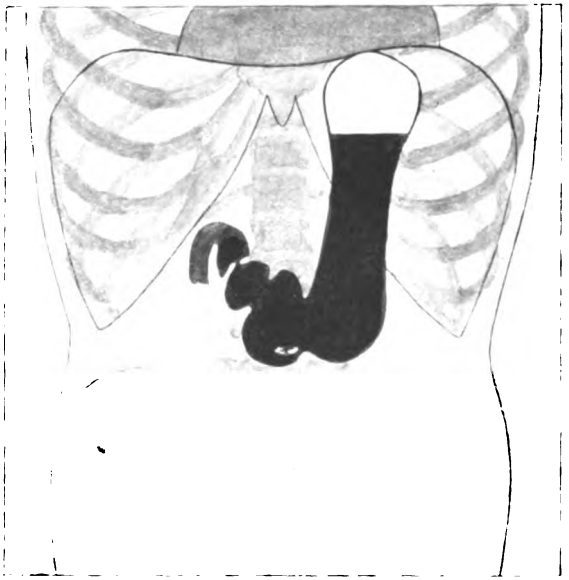

## PLATE XIII

Drawing from radiograph of normal stomach as seen in the vertical position after an ordinary bismuth and barium meal consisting of two ounces of bismuth and two ounces of barium sulphate. It shows the depressions caused by peristaltic contractions towards the pylorus, and as these are constantly moving towards the pylorus they are not due to fixed anatomical constrictions, and are therefore omitted from the other plates. The pylorus and commencement of the duodenum are shown.

As the drawing was made orthodiagraphically, it is therefore to scale and not distorted. Drawing by A. F. Hertz, M.D., F.R.C.P.

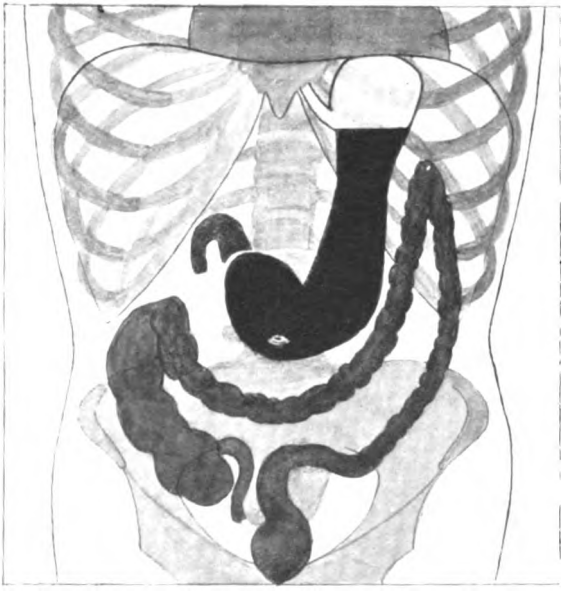

PLATE XIV

Drawing of radiograph of a normal stomach in the vertical position after an ordinary bismuth meal without the contractions seen in the preceding plate.

The lighter shadow is a composite drawing taken at varying periods after the meal, showing the appearance of the lowest part of the ileum, the cæcum, and large intestine as the bismuth was passing through.

The tracings were made orthodiagraphically, and are therefore to scale and not distorted. Drawing by A. F. Hertz, M.D., F.R.C.P.

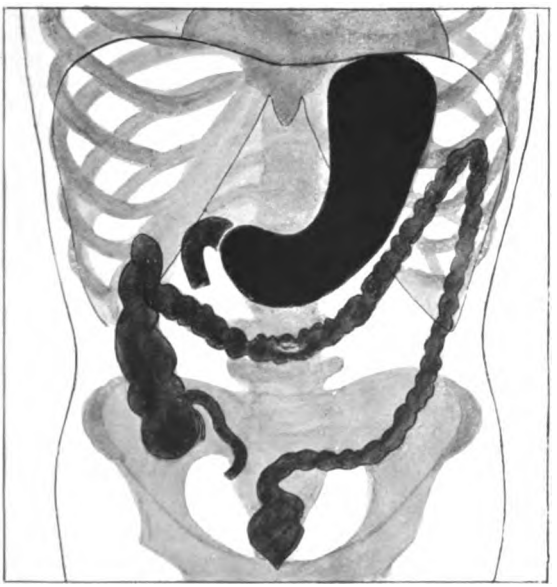

PLATE XV

Drawing from tracing of radiograph of a normal stomach taken in the *horizontal position* immediately after an ordinary bismuth and barium meal.

The lighter shadow is a composite tracing of the ileum and large intestine taken as in Plate XIV.

The tracings were made orthodiagraphically, and are therefore to scale and not distorted. Drawing by A. F. Hertz, M.D., F.R.C.P.

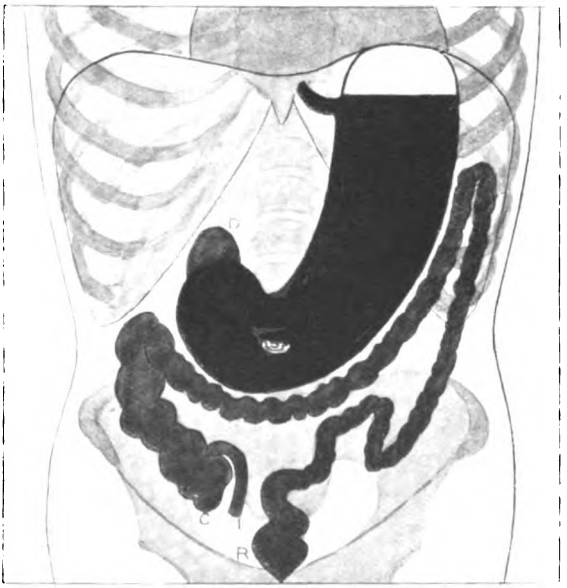


PLATE XVI

Drawing of a normal stomach as seen with X-Rays in the vertical position after an ordinary dinner with two ounces of barium sulphate added. D = the duodenum, and the light mark indicates the position of the umbilicus.

As in the previous plates the lighter shadow represents a composite tracing of the ileum (I), caecum (C), large intestine, and rectum (R), taken at varying periods after. Note the additional loop at the commencement of the pelvic colon, often seen in normal individuals.

The drawings were made orthodiagraphically, and are therefore to scale and not distorted. Drawing by A. F. Hertz, M.D., F.R.C.P.

# INDEX.


Abdomen, 40, 340
**Abdominal cavity**, 426
boundaries, 427
contents, 431
peritoneum, 457
planes, 429
relations between thoracic and abdominal organs, 443, 465, 471
subdivisions, 429
tunic, 380
**wall**, 376
adaptation to viscera, 431
arteries, 401, 403
cutaneous nerves, 381
vessels, 383
fascia, 378, 380, 400
muscles, 385, 390, 395
nerves, 394
posterior, 440-547
surface anatomy, 376, 430
surgical anatomy, 381
Aggregated lymph nodules, 487
**Alcock's canal**, 348, 350, 361
Allantois, 377, 631
Ampulla of ductus deferens, 597
of rectum, 584
of uterine tube, 643
of Vater, 503, 505
**Anal canal**, 582, 584, 645
structure of, 610
female, 645
**Anastomosis**. *See* Arterial anastomosis
Ankle-joint, 322
Ano-coccygeal body, **349**, 583, 586
Aorta, abdominal, 460, 476, **539**
branches of, 540
Aortic opening of diaphragm, 538
plexus, 476, 484, **515**, 540, 550
**Aponeurosis** of external oblique, 386
of internal oblique, 391
palmar, 115
plantar, **291**, 330
of transversus abdominis, 395
Appendices epiploicæ, 438
Arbor vitæ uterina, 648
**Arch**, anterior carpal, 106
coraco-acromial, 57, 58
femoral deep, 182
superficial, 182
plantar, 303
volar (palmar), deep, 130
superficial, 116
branches of, 118
Arches of foot, 329, 334
Arcus lumbo-costalis lateralis, 547
medialis, 548, 550
tendineus, 213, 250
Areola mammæ, 9
**Arm**, 62
back of, 83
cubital fossa, 81
cutaneous nerves, 65
fascia, 70
front of, 62
osteo-fascial compartments, 71
superficial veins, 69
surface anatomy, 62
**Arterial Anastomosis** of ankle, 288
of back of thigh, 250
crucial, of thigh, 232
of elbow, 140
of knee, 307
of scapula, 61, 64
**Artery or Arteries**, appendicular. *See* A. of vermiform process
articular, of knee, 198, **244**, 276, 282, 307

**Artery or Arteries** (*contd.*)—
articular (*contd.*)—
of hip, 214
axillary, 22
brachial, 73
of breast, 9, 10
of bulb of penis, 358, **362**, 375
cæcal, 481
carpal, radial, 99
ulnar, 106
*circumflex*, anterior, of the humerus, 26, 54
iliac, deep, 393, 401, **405**, 545-601
superficial, 171, 384
lateral, of the thigh, 188, **199**, 207
medial, of thigh, 188, 207, **208**, 227, 231
posterior, of the humerus, 26, 88
of the scapulæ, 26, 52, **60**
clavicular, 15, 25
coccygeal, 227
cœliac, 460, 461
*colic*, left, 478, **482**, 534
middle, 476, 478, **481**
right, 476, **481**
comitans nervi ischiadici, 227
common iliac, 476, 540, 543, **544**, 550, 602
common volar digital, 118
communicating, of anterior tibial, 110, 284
of corpus cavernosum. *See* A. profunda penis
cremasteric. *See* A. spermatic, external
cystic, 463
deep circumflex iliac. *See* Art., circumflex
deep volar, 118, **130**
descending branch of the transverse cervical, 61
digital, of foot, 304
dorsal metatarsal, 270
*dorsalis* clitoridis, 375, 376
indicis, 143
pedis, 267, 268
penis, 358, **362**, **417**, 569
pollicis, 144
of ductus deferens, 410, **599**, 600
*epigastric*, inferior, 393, 402, 403, **404**, 422, 425, 545, 597, 624, 639
superficial, 171, 384
superior, 406, 539

**Artery or Arteries** (*contd.*)—
femoral, 188, **190**, **195**, 196, 209, 545
fibular, superior, 282
*gastric*, left, 461
right, 445, 450, **462**
short, 460, **464**
gastro-duodenal, 448, 460, **463**, 498, 504
gastro-epiploic, 448, 450, 460, **463**, 464
genicular, 244
genu superior, 244
inferior, 244
middle, 244
genu suprema, 176, 194, **195**, 307
gluteal, inferior, 224, 226, **227**, 250, 347, **600**
superior, 223, 226, **233**, 562, **601**, 606
*hæmorrhoidal*, inferior, 347, **348**, 349, 362, 602
middle, 593, 600, 602
superior, 482, **601**
hepatic, 445, 447, 451, **462**, 463, 504, 523
hypogastric, 544, 557, 561, **598**, 624
ileal, 487
ileo-cæcal, 447
ileo-colic, 476, **480**, 534
iliac, common, 476, 540, 543, **544**, 550, 602
condition in fœtus, 598
external, 541, **545**, 597, 639-644
internal. *See* A. hypogastric
ilio-lumbar, 562, **601**
infraspinous, 66
intercostal, 404
*interosseous*, common, 106
dorsal, 138
recurrent, 140
volar, 109, 142
intestinal, 480
lumbar, 404, 539, **542**, 550, **554**, 601
malleolar, 268
mammary, lateral, 11, 25
internal, 9
medial calcaneal, 284, 295
median, 110
*mesenteric*, inferior, 476, 478, **482**, 540, 602
superior, 463, 476, **478**, 499, 501, 534, 540, 543

**Artery or Arteries** (*contd.*)—
metatarsal, 304
arcuate, 270
musculo-phrenic, **406**, 539
*nutricia* humeri, 75
femoris, 208
ilii, 601
tibiæ, 283
*obturator*, **214**, 425, 562, 581, 593, **600**
abnormal, 186, 600
œsophageal, 462
ovarian, 534, **542**, 543, 623, **646**
pancreatic, 464
pancreatica magna, 464
pancreatico-duodenal, inferior, 463, 478, **480**, 499, 543
superior, 460, **463**, 478, 480, 543
pectoral, 25
*perforating*, of foot, 303
of hand, 130, 143
of internal mammary, 6, 9
of peroneal, 271
of profunda femoris, 206, **207**, 208, **250**
perineal, 350, 362, 374
transverse, 350
peroneal, 271, 284, 287
phrenic, inferior, 460, **541**, 543
*plantar*, lateral, 295, 303
medial, 294
popliteal, 242, 281
princeps pollicis, 131
*profunda* brachii, 75, 82, 85, **87**
clitoridis, 373, 375
femoris, 188, 205
penis, 362, 569
proper volar digital, 118
pubic, of inferior epigastric, 425
of obturator, 600
*pudendal*, deep external, 191
internal, 229, 348, 358, **360**, 375, **600**
superficial external, 170, 383
to quadratus femoris, 227
*radial*, 98, 142
dorsal arteries of the thumb, 143
dorsal carpal, 143
dorsal of the index, 143
dorsal metacarpal, 143
volar carpal, 99
volar of the index, 131
radial recurrent, 99
ramus carpeus volaris, 99
**Artery or Arteries** (*contd.*)—
*recurrent*, of deep palmar arch, 130
interosseous, 140
radial, 99
tibial, anterior, 268, 308
posterior, **282**, 309
ulnar, 182
renal, 541, 543
*sacral*, lateral, 562, 598, **601**
middle, 540, 601, **602**, 609
sciatic. *See* A. gluteal, inferior
scrotal, posterior, 350
sigmoid, 483, 534
spermatic, external, 393, **405**, 410
internal, **410**, 476, 478, 499, 534, 539, **542**, 543
splenic, 448, 451, **463**, 502
subscapular, 26, 61
*superficial* external pudendal, 383
circumflex iliac, 383
epigastric, 384
volar, 99
*suprarenal*, superior, 326, 541
inferior, 542
middle, 541
supraspinous, 60
sural, 243
tarsal, lateral, **270**, 303
*thoracic*, alar, 25, 34
last, 555
lateral, 25
supreme, 25
thoraco-acromial, 25
*tibial*, anterior, 263, **267**, 273, **282**
posterior, 281, **282**
transverse cervical, 47, 61
transverse scapular, 45, **60**, 61
*ulnar*, **105**, 116
branches of, 105
carpal, 106
common interosseous, 106
dorsal recurrent, 106
volar interosseous, 109
volar recurrent, 105
umbilical, 421, 561, 562, 587, 593, 597, **599**, 625
uterine, 623, 624, 625, 635, **646**, 647
vaginal, 646
of vermiform process, 481
vesical, 562, 593, 597, **599**
**Articulations.** *See* **Joints**
**Axilla**, 4, 13
boundaries, 13
contents, 14

**Axilla** (*contd.*)—
fascia, 10
folds, 4
lymph glands, 17, 19
nerves, 28
structures passing from neck, 30
surface anatomy, 4
surgical anatomy, 4
vessels, 16, 19, 22, 26
Axillary sheath, 16, 22

**Back**, 37
cutaneous vessels and nerves, 38
fascia, 38
intermuscular spaces, 44
muscles to upper limb, 45, 46
structures beneath trapezius, 44
surface anatomy, 35
**Band**, ilio-tibial. *See* Tract
pudendal, of sacral plexus, 606
sciatic, of sacral plexus, 606
Bartholin's gland. *See* Vestibular gland
**Bell's** muscles, 573
**Bile-Ducts**, 445, 447, 498, 501, **504**
**Bladder**, 556, 570, **586**, **631**
apex, 561
coats, 571, 632
distended, 573, 588, 634, 635
empty, 573, 586, 634
false ligaments, 561
female, 631
in new-born, 592
orifices, 570, 571, 588, 611, 632
peritoneal relations, 590, 633
relations of female, 633
sphincter of, 611
structure of walls, 611
triangle at base, 573, 597
trigone, 571, **572**, 611, 632
uvula, 573
Brachial plexus, 28
**Breast.** *See* Mammary gland
Brunner's glands. *See* Duodenal glands
**Bulb** of urethra, **353**, 357, 416, 577, 578
of vestibule, 371
Bulbo-urethral glands (Cowper's), 351, 359, **360**, 574, 578
**Bursa**, intertubercular, 78
omentalis, 445, 447, 448, **450**, 460-463, 467, 491, 492, 501, 526, 530
over ischial tuberosity, 224
patellar, 179
**Bursa** (*contd.*)—
subacromial, 52
subscapular, 91
under gastrocnemius, 280
glutæus maximus, 224
minimus, 234
ilio-psoas, 215
ligamentum patellæ, 180
sartorius, 193
semimembranosus, 193, 218
**Buttock.** *See* Gluteal region

**Cæcum**, 431, 438, 439, **488**
Calyces of kidney, 532
**Canal** of Alcock, 348, 350, 361
adductor, 193
anal, 341, 582, **584**
female, 645
femoral, **185**, 424, 425
inguinal, 402, 420
obturator, 564, 600, 627
portal, 522
pyloric, 468, **509**
of Wirsung, 503
Capsule of Glisson, 522, 524
Caput epididymidis, 413
Cardiac orifice, 434
Carpal arch, anterior, 106
Cartilages, semilunar. *See* Menisci
Carunculæ hymenales, 368, 642
Catheter, passage of, 368
Cauda epididymidis, 413, 416
Caudate lobe of liver, 520, 521
Cave of Retzius, **561**, 570, 587, **624**, 626, 631
Central point of perineum, 355
tendon of diaphragm, 535, 538
**Cervix uteri**, 637
**Cisterna Chyli**, 482, 539, 540, **546**
Cleft, natal, 216
pudendal, 365, 645
Clitoris, 365, 367, **372**
Coccygeal body, 583, 586, 602, **609**, 649
Cœliac plexus, 460, 461, 482, 484, 514
Colliculus seminalis, 575
**Colon**, ascending, 438, 439, 454, **491**
descending, 439, 454, **495**, 530
iliac, 431, 439, **495**, 496
pelvic, 439, 534, 557, 587, 598, 620
transverse, 432, 437, 438, 439, 467, **491**, 499
Columnæ rectales, 602, 610
rugarum vaginæ, 649
**Commissure, anterior, of vulva**, 365

Congenital hernia, 423
Coni vasculosi. *See* Lobuli epididymidis
Conjoined tendon. *See* Falx inguinalis
Coraco-acromial arch, 57
**Cord**, gangliated, of sympathetic, and lumbo-sacral. *See* Trunk, sympathetic, and lumbo-sacral
spermatic, 377, 386, 389, 392, 404, **407**
Corona glandis, 416
**Corpus cavernosum** clitoridis, 372
penis, **352**, 363, 416
urethræ, 352, 353, **416**, 569, 578
Corpus epididymidis, 413
Costal zone, 427
Costo-coracoid ligament, 16
membrane, 10, **15**
Crest of urethra, 575
Crucial anastomosis of thigh, 231
**Crura** clitoridis, 370, **373**, 628
of diaphragm, 450, 460, 461, 535, **537**, 540, 543
of penis, 352, 416, 568
of subcutaneous inguinal ring, 387
Crural canal. *See* Femoral
Crypts of Lieberkühn, 494
Cubital fossa, 81
Cutaneous arteries of arm, 5
nerves of arm, 5, 65
Cystic duct, **444**, 447, 504

Deep fascia of arm, 5
of axilla, 10
of pectoral region, 10
of shoulder, 50
**Diaphragm**, 395, 427, 450, 453, 500, 511, **535**
central tendon, 535, 538
crura, 450, 460, 461, 535, **537**
foramina, 538, 547
ligamentum arcuatum medium, 537
lumbo-costal arches, 535, 536
pelvic, 347, 427
urogenital, 341, 343, 347, **351**, 352, 353, **359**, 361, 363, 371, 374, **375**, 506, 569, 649
inferior fascia of, 341, 343, 352, 353, **356**, 357, 358, 359, 360, 361, 362, 364, **374**, 375, 577, 628, 634
superior fascia of, 352, **358**, 359, **Diaphragm** (*contd.*)— 360, 361, 364, 374, **565**, 577, 594, 628, 629, 634
Diaphragmatic plexus, 515
Digital fossa of tunica vaginalis. *See* Sinus epididymidis
Discus articularis of clavicular joints, 28, 57
of wrist, 156
**Dissections: Abdomen**—
abdominal viscera, 444, 445, 448, 458, 475, 484, 485, 489, 491, 493, 496, 503, 505, 506, 508
abdominal wall, 378, 380, 384, 388, 390, 393, 397, 401, 406, 407, 409
diaphragm, 534
female pelvis, 624, 628, 632, 641, 648, 649, 650
hernia, 421
lumbar fascia, 418
male **pelvis**, 561, 566, 568, 570, 574, 579, 580, 581, 597, 603, 609, 612, 613, 618
penis, 417
perineum, female, 368, 369, 371, 372, 373, 374
male, 341, 342, 345, 347, 351, 356, 359, 363
posterior wall of abdomen, 539, 548, 551, 555
removal of viscera, 516
sympathetic plexuses, 514
testis, 412, 413, 415
**Lower Extremity**—
ankle-joint, 323, 329
anterior crural region, 259, 263
back of thigh, **245**, 246, 249, **251**
deep, of thigh, 182, 185, 187, 191, 195, 203
foot-joints, 331, 335
gluteal region, 218, 221, 223, 224, 226, 229, 231, 232
hip-joint, 254, 257
knee-joint, 310, 312, 313, 315, 318
medial side of thigh, 205, 208, 210, 215
popliteal fossa, 236, 237
posterior crural region, 276, 280, 281
sole of foot, 289, 292, 294, 298, 300, 303, 306, 307

**Dissections : Lower Extremity** (*contd.*)—
superficial, of thigh, 169, 170, 172, 174, 177
**Upper Extremity**—
axilla, 14, 16, 17, 28, 35
back, 37, 38, 40, 42, 44, 45, 46, 47
dorsum and lateral border of the forearm, 132, 136, 146, 148
dorsum of the arm, 83, 85, 88
forearm and hand, 94, 96, 98, 101, 104, 112, 113, 116, 126, 130
front of the arm, 62, 65, 77, 80
pectoral region, 2, 5, 7, 10
radio-carpal joint, 151
removal of upper extremity, 47
shoulder, 48, 50, 51, 52, 59, 61
Diverticulum Meckelii, 473
Dorsal expansion of extensor tendons, 145, 266
**Douglas**, fold of. *See* Linea semicircularis
pouch of. *See* Pouch, recto-uterine
**Duct**, bile, 447, 462, 498, 501, **504**
cystic, **444**, 447, 504
ejaculatory, 576, **596**, 597
hepatic, 445, 447, **504**
pancreatic, 449, **503**
prostatic, 576
thoracic, 538, **547**
Ductuli efferentes testis, 413, 415
Ductus choledochus. *See* Duct, bile
deferens, 377, 405, 410, **413**, 422, 545, 561, 562, 567, 568, 570, 580, 587, 596, **597**, 599
venosus, 506, 523
Duodenal fossæ, 474
glands, 511
Duodeno-jejunal flexure, 438, 472, 502
Duodeno-pyloric constriction, 466
**Duodenum**, 443, 471, 474, 476, 479, **496**-500, 504, 534, 540, 543
coats, 511
suspensory muscle, 472, 500

**Elbow**, 63
arterial anastomoses, 140
cubital fossa, 81
joint, 148
superficial veins, 69
surface anatomy, 63
surgical anatomy, 63

Endo-pelvic fascia. *See* Fascia, pelvic
**Epididymis**, 413, 415
ductus epididymidis, 416
Epigastric region, 431
Epoophoron, 644
Excavation. *See* Fossa or Pouch
Extensor tendons of fingers, 145
of toes, 266

Fallopian tubes. *See* Uterine tubes
Falx inguinalis, 391, 397, 403
**Fascia** of abdomen, 378
**anal**, 347
of arm, 6, 70, 77, 79
**axillary**, 10
of back, 38
bicipital. *See* Lacertus fibrosus
of Camper, 169, 379, 380
clavi-pectoral, 15, 17
of Colles, 343, 345, 380
**cremasteric**, **393**, 407, 423
**cribrosa**, 178
external spermatic, 385, **386**, 388, 407, 423
femoris, 169, 177, 228, 229
of foot, 291
of forearm, 97, 132
gluteal, 218-22
of hand, 115, 116
iliaca, 125, 183, 401, 548
infundibuliform. *See* internal spermatic *below*
intercolumnar. } *See* external sper-
intercrural. } matic *above*
internal spermatic, **401**, 407, 422, 423
lacertus fibrosus, 71, 73, 79, 82
of leg, 261, 285
**lumbar**, 395, 418
palmar. *See* Aponeurosis, palmar
**pectoral**, 5, 10
**pelvic**, 347, 361, 556, 563, 626
parietal or diaphragmatic, 563, 565, 588, 604, 612, 624, 625, 626
recto-vaginal, 629, 645
recto-vesical, 566, 587, 596
vesical, 567, 570, 592, 629
visceral layer, 563, 565, 566, 568, 592, 596, 597, 604, 624, 625, 626, 629, 632
of pelvic diaphragm, 347, 565, 624, 626, 628, 629, 634
of perineum, 342, 368
**pectinea**, 178, 184, 425

**Fascia** (*contd.*) —
piriformis, 581
plantar. *See* Aponeurosis, plantar
popliteal, 178, **236**
of popliteus, 239, 243, 249, 284
of psoas and iliacus, 548, 563, 627
of quadratus lumborum, 547
rectal, 582, 585, 629
of Scarpa, 169, 344, 379, 380
semilunar. *See* Lacertus fibrosus
of shoulder, 50
of sole, 289
spermatic, 385, **386**, 388, **401**, 407, 422, 423
of thigh and buttock, 169, 245, 246
transversalis, 183, 399, **400**, 401,
of urogenital diaphragm, 341, 343, 352, 353, **356**, 357, **358**, 359, 360, 361, 362, 364, **374**, 375, **565**, 577, 594, 628, 629, 634
**Femoral** canal, **185**, 424-425
hernia, **185**, 424
ring, **185**, 424, 425, 600
septum, **185**, 425
sheath, 178, **182**, 389, 402
Fibræ intercrurales, 388
**Fibro-cartilages, semilunar**. *See* Menisci
triangular, of wrist. *See* Discus articularis
Fimbria, ovarian, 643
Fimbriæ of uterine tube, 643
**Fingers**, extensor tendons, 145
flexor sheaths and tendons, 104, 123, 125
movements, 163, 164, 165
surgical anatomy, 131
**Fissure** of ductus venosus. *See* **Fossa**
transverse, of liver. *See* Porta hepatis
umbilical, 443
urogenital, 365
Flexor tendons of foot, 292, 294, 299
of hand, 104, 123, 125
sheaths of, 104, 123, 125
**Flexure**, duodeno-jejunal, 474
left colic, 436, **495**, 513
right colic, 439, **491**, 529
**Fold**, axillary, 4
of Douglas. *See* Linea semi-circularis
**Fold** (*contd.*) —
gastro-pancreatic, 448, 451, 460, 461, 462
of nates, 216
ovarico-pelvic. *See* Lig., suspensory, of ovary
patellar synovial, 315
recto-vesical, 560
sacro-genital, 457, **558**, 559, 561, 591, 596
transverse vesical, 561
umbilical, 421, 561, 621
utero-sacral, 623
utero-vesical, 623
**Foot**, arches, 329, 334
cutaneous nerves, 259, 272, 289, 296, 298
dorsum, 259
fascia, 269, 291
intermuscular septa, 292
joints, 330, 338
sole, 289. *See also* Sole
surface anatomy, 258
synovial cavities, 338
**Foramen** epiploicum, 445, 447, 448, 451, 453, 462, 504, 505, 543
sciatic, greater, 226, **227**, 229, 230, 233, 600, 601, 606, 607, **617**
lesser, 226, 230, 231, 607, **617**
venæ cavæ, in diaphragm, 538
**Forearm**, 94
cutaneous nerves, 95, 96, 119, 120
deep anterior structures, 108
deep posterior structures, 136
dorsum and lateral border, 132
fascia, 97
muscles, anterior superficial, 101
posterior superficial, 133
superficial veins, 94
surface anatomy, 111
Fornix of vagina, 624, 641
**Fossa**, cubital, 73, 81
digital, of tunica vaginalis. *See* Sinus epididymidis
for ductus venosus, 443, 450, 518, 519, 520
duodenal, upper and lower, 474
duodeno-jejunal, 474
for gall-bladder, 519
genital, 559, 623
ileo-cæcal, anterior and posterior, 414
ileo-colic, 474
infraclavicular, 2
infrasternal, 4

**Fossa** (*contd.*)—
inguinal, 421
medial and lateral, 421
intersigmoid, 475
ischio-rectal, 346
navicularis penis, 578
vestibuli, 367
ovalis, 172, 173
ovarica, 644
paraduodenal, 474
pararectal, 559, 584
paravesical, **559**, 561, 589, 623, 632
popliteal, 234
recto-vaginal, 645
recto-vesical, 559, 584, 587, 591, 592, 596, 610, 631
retro-colic, **475**, 489
retro-duodenal, 474
supravesical, 421, 561
umbilical, 443, 506, 519
utero-vesical, 632
for vena cava inferior, 518, 519, 521, 522
**Fossæ**, peritoneal, 421, 474, 475, 561, 644
Frenula of colic valve, 490
**Frenulum** clitoridis, 365
labiorum pudendi, 366
preputii, 417, 578
Fundus of stomach, 434, 465
uteri, 636
Furrow, iliac, 216

**Gall-bladder**, 437, 443, **444**
fossa for, 444, 519
Gangliated cord of sympathetic. *See* Trunk, sympathetic
Ganglion impar, 609
coeliac, 460, 514, 543
Gastro-colic omentum. *See* Omentum, greater
Gastro-hepatic omentum. *See* Omentum, lesser
Gastro-pancreatic folds, **448**, 451, 460, 461, 462
Gastro-splenic ligament. *See* Ligament, gastro-lienal
Genital fossa, 559, 623
Glands, suprarenal, 450, 460, 467, 501, 503, 514, **524**, 529, 530, 543
Glans clitoridis, 367, 372
penis, 416
Glisson's capsule, 522, 524
**Gluteal region**, 215
cutaneous nerves, 218
**Gluteal region** (*contd.*)—
fascia, 221
parts beneath glutæus maximus, 224
parts beneath glutæus medius, 233
parts beneath glutæus minimus, 234
surface anatomy, 216
sulcus, 216
Gubernaculum testis, 409
ovarii, 639, 644

Hæmorrhoidal plexus of nerves, 608
of veins, 602
**Hand**, 111, 142
cutaneous nerves, 87, 96, 97, 107, 108, 119, 120
dorsum, 142
extensor tendons, 145
fascia, 114, 115
flexor tendons, 104, 123, 125
joints, 158
**palm**, 111. *See also* Palm
superficial veins, 69
surface anatomy, 111
surgical anatomy, 131
Hepatic ducts, 447, **504**
Hepatic flexure of colon. *See* Flexure, right colic
Hepatic plexus, 447, **515**
**Hernia**, 420
femoral, 185, 424
inguinal, 423
direct, 422
coverings of, 423
oblique, 423
coverings of, 422
lumbar, 418
obturator, 582
sciatic, 581
umbilical, 426
coverings of, 426
Hiatus tendineus, 194
**Hilum** of kidney, 528, 532
of ovary, 644, 646, 647
of spleen, 513
of suprarenal gland, 525
Hunter's canal. *See* Canal, adductor
Hydatid of Morgagni, 645
Hymen, **367**, 375, 642
Hypochondriac region, 431
Hypogastric plexus, 484, 516, 608
region, 431
zone, 430
Hypothenar eminence, 111

**Ileo-cæcal** fossa, 474
orifice, 490
valve. *See* Valve of the colon
Ileum, 438, 471, 472, 485
**Iliac** colon, 431, 439, 495, **496**
furrow, 216
region, 431
Ilio-tibial tract, 168, 177, 179
**Impression**, cardiac, 518
colic, 520
duodenal, 520
gastric, 520
hepatic, 528
œsophageal, 520
renal, 520
suprarenal, 520, 522
**Incisura** angularis, 468
umbilicalis, 443
Inferior gastric plexus, 621
Infraclavicular fossa, 2
Infrapatellar pad, 314
Infrasternal fossa, 4
Infundibula of kidney, 533
**Inguinal** canal, **402**, 420
fossæ, 421
hernia, 422, 423
ring, abdominal, **402**, 404, 410, 420, 422, 424, 639
subcutaneous 377, **386**, 394, 420
Inscriptiones tendineæ, 398
Intercrural fibres, 388
**Intermuscular septa** of arm, 71
of leg, 262, 279
of shoulder, 51
of sole, 292
of thigh, 178, 201
spaces of back, 44
**Interosseous membrane** of forearm, 156
of leg, 327
Intersigmoid fossa, 475
Intertubercular plane, 429
**Intestine**, large, 438, 488, 494, 495
small, 436, 438, 471, 485
Ischio-rectal fossa, 346
boundaries, 346
contents, 347
Isthmus of uterine tube, 653
uteri, 637

**Jejunum**, 438, 471, 485
**Joint or Joints**, acromio-clavicular, 57
**ankle** (*talocruralis*), 322
capsule, 324
lig. calcaneo-fibular, 325
lig. deltoid, 326
lig. talo-fibular, anterior, 324
posterior, 325
movements, 326
synovial layer, 326
calcaneo-cuboid, 333
**carpal**, 158
intercarpal, 159
articular surfaces, 163
ligaments, 160
movements, 161
synovial layer, 162
carpo-metacarpal, 161
movements, 163
coccygeal, 615
cubo-cuneiform, 335, 336
cubo-navicular, 335
cuneo-navicular, 335
**elbow** (cubiti), 149
capsule, 149
lig., collateral, radial, 134, 148, **149**
ulnar, 149
synovial layer, 150
movements, 151
of foot, 329, 338
**hip**, 251
labrum glenoidale, 251, 254
ligaments, cervical, 256
ilio-femoral, 253
ischio-capsular, 253
pubo-capsular, 253
teres, 214, 251, **255**
transversum acetabuli, 255
movements and muscles, 254
synovial layer, 256
zona orbicularis, 253
intercuneiform, 334
intermetacarpal, 161
intermetatarsal, 337
interphalangeal, of foot, 320
of hand, 165
**knee**, 310
capsule, 310
interior of joint, 314
ligaments, collateral, fibular, 312
tibial, 276, **312**
cruciate, 316, **318**, 322
patellæ, 204, **311**
popliteal, oblique, 239, 245, 249, 309, 313
transverse, 321

**Joint or Joints** (*contd.*)—
**knee** (*contd.*)—
menisci, 320
movements at the, 318
patellar synovial fold, 315
plicæ alares, 315
synovial layer, 315
lumbo-sacral, 613
**metacarpo-phalangeal**, 163
accessory volar ligament, 163
collateral ligaments, 164
movements, 164
synovial layer, 164
metatarso-phalangeal, plantar accessory ligaments of, 338
of pelvis, 612
pisiform, 158
**radio-carpal**, 152
capsule, 152
lig., dorsal radio-carpal, 152
lig., radial collateral carpal, 152
lig., volar radio-carpal, 152
lig., ulnar collateral carpal, 152
movements, 154
synovial layer, 154
**radio-ulnar**, 154
annular ligament of the radius, 148, 149, **155**
capsule of distal radio-ulnar joint, 155
discus articularis, 156
movements, 157
synovial layer, 156
sacro-coccygeal, 615
**sacro-iliac**, 615
lig. anterior, 615
interosseous, 616
long posterior, 616
short posterior, 616
movements, 617
**shoulder**, 88
articular surface, 94
movements, 94
synovial layer, 94
**sterno-clavicular**, 28
taloid, 330
ligaments, 331
tarso-metatarsal, 336
**tibio-fibular**, 326, 328
ligaments of, 328
syndesmosis, 328
transverse carpal, 159
tarsal, 333
wrist, 152

**Kidney**, 440, 450, 454, 460, 463, 467, 476, 499, 501, 503, 513, **526**
calyces, 533
capsule, 532
columns, 534
cortex, 534
form, 527
hilum, 528, 532, 542
impressions, colic, 529
duodenal, 529
hepatic, 528
infundibula, 533
**medulla**, 533
papillæ, 533
pelvis, 532
position, 526
posterior relations, 531
shape, 527
sinus, 528, 532, 542
size and weight, 527
structure, 533
surfaces, 528
ureter, 474, 476, 478, **534**, 557, 562, 573, **592**, 593, 597, 624, 625, 633, **634**, 635, 641, 644, 646
**Knee**, arterial anastomosis, 307
articular nerves, 212, 240, 242, 245, 249, 275, 276, 309
joint, 310
surface anatomy, 168

Labia majora, 365
minora, 365
Labrum glenoidale of hip-joint 251, 254
of shoulder, 90, 92
Lacertus fibrosus, 70, 71, 73, 79
Lacteal vessels, 474, 482
Lacunæ urethrales, 578
**Leg**, 257
anterior compartment, 259
crural region, 258
cutaneous nerves, 259, 277
fascia, 261, 278, 285
intermuscular septa, 262, 279
interosseous membrane, 327
lateral crural region, 259
medial crural region, 259
posterior osteo-fascial compartment (posterior crural region), 259
superficial veins, 259, 276
surface anatomy, 257

**Ligamentum or Ligamenta**, acromio-clavicular, 57
*of ankle-joint*, 322
capsule, 324
lig. calcaneo-fibular, 325
lig. deltoid, 326
lig. talo-fibular, anterior, 324
posterior, 325
annular, of the radius, 148, 149, **155**
anterior longitudinal, 543, **613**
anterior pubic, 618
arcuate pubic, 340, 357, 376, **618**, 629
bifurcatum (of foot), 333
of bladder, 558, 560, 561, 621, 627, 632
lateral false, 558, 561, 621
posterior false, 560, 561. *See also* Fold, sacro-genital
true, 561, **567**, 627, **632**
brevia, 125
broad, of uterus, 440, **621**, 625, 635, 641, 646
calcaneo-cuboid, 330, 333, 334
calcaneo-navicular, lateral, 333
calcaneo-navicular, plantar, 330, 332
capsular, of shoulder-joint, 90
*of carpal joints*, 160
carpal, dorsal, 97, 132, **143**, 145
transverse, 97, 105, **120**
volar, 97, **121**
cervical, of hip-joint, 256
chorda obliqua, 155, 157
coccygeal, 613
conoid, 57
of Cooper, 9
coraco-acromial, 57
coraco-clavicular, 57
coraco-humeral, 92
coronary, 442, 453, **516**
costo-coracoid, 16
cruciate, of knee, 316, **318**, 319, 322
cruciatum cruris, 261, 265, **273**
cubo-cuneiform, 335
cubo-navicular, 335
cuneo-navicular, 335
cutaneous, of phalanges, 116
digital, cruciate, 124
digital, vaginal, 124
of elbow-joint, 149
ulnar collateral, 104, **149**
falciform, of liver, 427, 432, 442, 453, **518**

**Ligamentum or Ligamenta** (*cont.*)—
fibular collateral, 247, **312**, 320
of fingers, 125
flava, 613
of foot, 329
gastro-colic. *See* Omentum, greater
gastro-lienal, 435, 447, 451, 458, 464, 468
gastro-phrenic, 435, 468
gleno-humeral, 92
hepato-duodenal, 458
hepato-gastric, 458
of Hey, 173
of hip-joint, 251-256
ilio-femoral, 253
ilio-lumbar, 547, **614**
inguinale, 166, **180**, 188, 377, 380, 385, **389**, 403, 422, 424, 545
inguinale reflexum, **390**, 403
intercuneiform, 334
intermetacarpal, 162
intermetatarsal, 336, 337
interphalangeal, 162, 338
interspinous, 613
ischio-capsular, 253
of kidney, 528
of knee-joint, 310, 320
collateral, fibular, 247, **312**, 320
tibial, 213, 248, 249, 276, **312**, 321
cruciate, 316, **318**, 321-322
menisci, 320, 321, 322
oblique popliteal, 239, 245, 249, 309, **313**
transverse, 321
labrum glenoidale of hip-joint, 251, 254
of shoulder-joint, 90, 92
laciniatum cruris, 278, 279, 284, **288**
lacunar, 172, 173, **181**, **389**, 402, 425
lieno-renal, 436, 451, 454, 460, 464, 506
of liver, 427, 432, 442, 443, 453, 506, 516, 518
longa, 125
longitudinal, of vertebral column, 613
lumbo-sacral, 614
metacarpo-phalangeal, 163
metatarso-phalangeal, 338
mucosum. *See* Patellar synovial fold *on next page*

**Ligamentum or Ligamenta** (*contd.*)—
oblique popliteal, 239, 245, 249, 309, **313**
ovarico-pelvic. *See* Lig., suspensory, of ovary
of ovary, 622, 637-639, **644**
suspensory, 621, 646
patellæ, 204, **311**
patellar synovial fold, 315
of peritoneum, 513
phrenico-colic, 436, 454, 495, 513
plantar, long, 306, 333
posterior longitudinal, 613
posterior pubic, 618
pubic, 618
pubo-capsular, 253
pubo-prostatic, 561, 570, 588, 594, 611. *See also* Lig., pubo-vesical
pubo-vesical, lateral, 567, 632
medial, **567**, 624, 627, 629, 631, **632**
radial collateral, of elbow, 134, 148, **149**
of wrist, 142, **152**
radio-ulnar, 155-156
round, of liver, **426**, 443, 506
of hip-joint, 214, 256
of uterus, 386, **388**, 403, 545, 623, 637, **639**
sacro-coccygeal, 613
sacro-genital. *See* Fold
sacro-iliac, 613, 614
sacro-spinosum, 226, 227, 556, **617**
sacro-tuberosum, 222, 226, 227, 340, 347, 556, 608, 612, **616**
of shoulder, 94
subflava, 613
supraspinous, 613
superior pubic, 618
suspensory, of ovary, 621, 646
suspensory, of penis, 417, 568
talo-calcaneal, 330
talo-calcaneum interosseum, 330
laterale, 331
mediale, 331
posterius, 331
talo-navicular, 331
tarso-metatarsal, 336
teres, of hip, 214, **255**, 256
of liver, **426**, 443, 506
of uterus, 386, **388**, 403, 545, 623, 637, **639**
tibial collateral, 213, 248, 249, 276, **312**, 321

**Ligamentum or Ligamenta** (*contd.*)—
tibio-fibular, 326, 328
*transverse*, of ankle, 325
of hip, 255
of knee, 321
metacarpal, 115, 146
of the heads of the metatarsal bones, 146
of palm, 120, 143
of pelvis, 352, 359, 374, 375, 569
transverse superficial ligament of hand, 113
transversum cruris, 261, 265, **273**
transversum scapulæ interius, 62
superius, 62
trapezoid, 57
triangular, of liver, 443, 516-518
of perineum. *See* Fascia of urogenital diaphragm
ulnar collateral, of elbow, 104, **149**
of wrist, 152
umbilicale laterale, 599, 624
medium, 561, 567, 587. *See also* Urachus
venosum, 506
zona orbicularis, 253
**Limb, lower**, 166
back of thigh, 245
foot, 259, 289
front of thigh, 169
gluteal region, 215
joints, 251, 310, 322, 329, 338
leg, 257
medial side of thigh, 204
popliteal space, 234
**surface anatomy**, 166, 168, 216, 218, 235, 257
**Limb, upper**, 1
axilla, 13
dorsal structures, 37. *See also* Back
dorsum of the arm, 62
forearm, 94
front of the arm, 62
hand, 110
joints, 82, 139
pectoral structures, 2. *See also* Pectoral region
scapular region, 48. *See also* Shoulder
**surface anatomy**, 2, 35, 62, 111, 131
wrist, 110, 142
Line of Nélaton, 218

**Linea** alba, 376, 384, **399**
semicircularis, 399
semilunaris, 377
Lineæ transversæ, 398
**Liver**, 432, 441, 517
bare area of, 521, 522
connections, 441
ducts, 445, 447, 498, 501, 504
fissures or fossæ, 443
impressions, colic, 520
duodenal, 520
gastric, 520
œsophageal, 520
renal, 520
suprarenal, 520-522
ligaments, 427, 432, 442, 443, 453, 506, 516, 518
lobes, 442, 520, 521
porta hepatis, 443-445, 447, 498, 505, **519**, 520, 522
position, 441, 442
structure, 524
surfaces, 442, 443, 517
vessels, 462, 504
Lobuli epididymidis, 416
Lobus caudatus of liver, 450, 451, 518, 520, **521**
**Lumbar** glands, 411, 539, 546
plexus, 551
region, 431
Lumbo-sacral trunk, 551, 554
**Lymph glands**, aortic, 647
of arm, 70
axillary, 17, 19
cardiac, 445
femoral, 172
hypogastric, 603, 647
iliac, common, 603
iliac, external, 546, 647
infraclavicular, 11
inguinal, 172, 647
lumbar, 411, 539, 546
mesenteric, 474, 476, 482
pectoral, 20
of popliteal fossa, 237
rectal, 603
sacral, 603
sternal, 20
subinguinal, 172
subscapular, 21
**Lymph vessels**,
deep femoral, 546
of breast, 10
lumbar trunks, 546
of pelvis, 603, 647
spermatic, 411
Mammary gland, 8
blood supply, 10
lymph vessels, 10
position, 9
Meatus urinarius. *See* Orifice, external, of urethra
Meckel's diverticulum, 473
Mediastinum testis, 414
Medulla of kidney, 533
of suprarenal gland, 467
**Membrane**, costo-coracoid, 15
interosseous, of forearm, 156
of leg, 327
obturator, 214, 556, 612, **618**
Menisci, 320, 321
Mercier's bar, 573
Mesenteric glands, 474, 476, 482
plexus, inferior, **484**, 516
superior, 479, **481**, 515
**Mesentery**, 438, 472, **473**, 499, 540, 543
suspensory muscle of, 472, 500
of vermiform process, 440, 489
**Meso-colon**, pelvic, 483, 559, 601, 620
transverse, 438, 447, 450, 456, 467, 476, 493
Mesometrium, 623
Mesorchium, 409
Mesosalpinx, 623
Mesovarium, 623, 643
Metatarso-phalangeal joints, 305
Mid-Poupart plane. *See* Plane, lateral
Mons Veneris, 364
Morgagni, hydatids of, 645
Mucous sheaths of flexor tendons, 122
**Musculus or Musculi**, *abductor* digiti quinti of foot, 194
of hand, 128
hallucis, 194
indicis, 147
pollicis brevis, 127
longus, 136, 137, 138
*adductor* brevis, 189, 209
hallucis, 301
longus, 189, 205
magnus, 194, 213
pollicis, 127
anconæus, 85, 135
of ankle-movements, 326
articularis genu, 204
biceps brachii, 72, 78, 93
femoris, 246, 312, 327
brachialis, 72, 79

**Musculus or Musculi** (*contd.*)—
brachio-radialis, 72, 80, 81, **133**
bulbo-cavernosus, 350, 354, **355**, 371, 642
coccygeus, 556, 600, 603, **604**, 605, 606, 617
coraco-brachialis, 71, 72, **78**
corrugator cutis ani, 342
cremaster, 392
dartos, 343, 369, 406
deltoideus, 50
detrusor urinæ, 611
of elbow movements, 151
*extensor* carpi radialis brevis, 134
longus, 72, 80, **133**
carpi ulnaris, 135
digiti quinti proprius, 135, 146
digitorum brevis, 271
digitorum communis, 135
digitorum longus, 263, **265**
hallucis longus, 263, 266
indicis proprius, 138, 145
pollicis brevis, 137
pollicis longus, 138
**of finger movements**, 164, 165
*flexor* carpi radialis, 102, 147
ulnaris, 103
digiti quinti brevis of foot, 299, 303
of hand, 128, 129
digitorum brevis, 293, 299
longus, 286, 298, 299
profundus, 109, 123, 125
sublimis, 104, 123, 125
hallucis brevis, 301
longus, 285, 286, 298
pollicis brevis, 127
longus, 109, 126
**of foot movements**, 339
gastrocnemius, 279
gemelli, **230**, 607, 608
glutæus maximus, 218, **222**, 223, 347
glutæus medius, 220, 221, **232**, 607
glutæus minimus, 234, 607
gracilis, 213, 275
hamstring, 246
**of hand movements**, 154
**of hip movements**, 254
iliacus, 189, **214**, 547, **549**, 554, 601
ilio-psoas, 183, 189, **214**, **549**
infraspinatus, 59
inserted into clavicle and scapula, 48
intercostal, internal, 391

**Musculus or Musculi** (*contd.*)—
interosseous, of foot, 306
of hand, 146, 147
interosseus primus volaris, 147
ischio-cavernosus (female), 370
(male), 350, 354, 355
**of knee movements**, 318
lateral rotators of thigh, 254
latissimus dorsi, 40, **42**, **56**, 220, 385
levator scapulæ, 40, 46
ani, 347, 349, 355, 556, 566, 583, 584, 585, 595, **603**, 609, 628
action of, 604
prostatæ, 604
lumbricales, of foot, 299, 300
of hand, 126
obliquus externus abdominis, 384, 385, 394
internus abdominis, 384, 390, **392**, 394
obturator externus, 214, 231
internus, 230, 556, 612
omo-hyoideus, 45
opponens digiti quinti, 128, 129
pollicis, 127
palmaris brevis, 113
longus, 102
pectineus, 189, 208
pectoralis major, 12
minor, 17
peronæus brevis, 274
digiti quinti, 274
longus, 274, 306
tertius, 263, 267
piriformis, **230**, 556, 600, 601, 605, 606, 607, **612**
plantaris, 280
platysma, 5
popliteus, 239, **242**, 284, **285**, 309, 312, 327
pronator quadratus, 109
teres, 81, 101
psoas major, **214**, 474, 476, 531, 534, 547, **549**, 551, 601
minor, 549
pyramidalis, 384, 394, **398**
quadratus femoris, 231, 607
lumborum, 396, 476, 531, 547, **549**, 551, 601
plantæ, 299, 300
quadriceps femoris, 201, 204
**of radio-ulnar movements**, 158
rectus abdominis, 384, 392, **398**
femoris, 201, 234

**Musculus or Musculi** (*contd.*)—
rhomboideus major, 40, 46
minor, 40, 45
sacro-spinalis, 220, 396
sartorius, 192, 249, 275
semimembranosus, 249, 313
semitendinosus, 248, 275
serratus anterior, 34, 35, 385
short, of little finger, 128
of thumb, 127
soleus, 281
sphincter ani externus, 342, **346**, 349, 585
internus, 349, 585
urethræ membranaceæ, 351, 359, **360**, 374, **375**, 556, 628, 634
vaginæ. *See* M. bulbo-cavernosus
vesicæ, 632
subanconæus, 85, 88
subclavius, 15, 27
subscapularis, 59
supinator, 81, 148
supraspinatus, 58
suspensory, of duodenum and mesentery, 472, 500
tensor fasciæ latæ, 199, 607
teres major, 56
minor, 58
**of thumb movements, 163**
tibialis anterior, 263, 265
posterior, 285, 286, 306, 330
transversus abdominis, 384, 393, 394, **395**, 547
perinei superficialis, 350, **354**, 357, **370**
profundus, 351, 356, **359**, **375**
trapezius, 40, 41
triceps brachii, 74, 83
vastus intermedius, 203
lateralis, 202
medialis, 194, 203

Natal cleft, 216
Navel, 377, 399, 426, 506
Nélaton's line, 218
**Nerve or Nerves**, accessory, 42
accessory obturator, 208, 551, 554
anastomotic peroneal, 242, 278
to anconeus, 136
anterior crural. *See* Femoral
anterior cutaneous, of thoracic nerves, 6, 381, 394, 398

**Nerve or Nerves** (*contd.*)—
**articular**, of ankle, 284
of hip, 212
of knee, 212, 240, 242, 245, 249, 275, 276, 309
of shoulder, 55
axillary, 48, 49, **54**, 59
to bulb of urethra, 356
cavernous, 609
cervical, 6, 42
circumflex. *See* Nerve, axillary
coccygeal, 603, 608
to coccygeus, 605
**common peroneal**, 229, 235, **241**, 274, 309, 606
to coraco-brachialis, 78
**cutaneous**, of abdomen, 381
of arm, 49, 65, 67
of back, 38
of buttock, 218
of chest, 16, 21
of foot, 259
of forearm, 65, 67, 95
of leg, 259
lumbar, 219
of radial, 59, 80
sacral, 219
of thigh, 174, 245
**deep** peroneal, 261, 263, 266, 267, 268, **271**, 273
ramus of radial, 87, 99, 134, 135
descending cutaneous, of cervical plexus, 6
digital, of foot, 296, 298
of hand, 119, 120
**dorsal**, of clitoris, 374, 376
cutaneous nerves of forearm, 65
of penis, 358, 361, **363**, 417, 569
dorsalis scapulæ, 31, 46
external spermatic, 393, 410, 545, **553**
**femoral**, 183, 189, 193, **196**, 202, 203, 309, 489, 496, 549, 551, 554
to femoral artery, 212
furcalis, 551
geniculate, of obturator, 212, 237
**gluteal**, inferior, 223, 227, 607
superior, 199, 226, 232, **233**, **607**
hæmorrhoidal, inferior, 346, 362
hypogastric, 552
iliac, 551
ilio-hypogastric, 220, 381, 383, 390, **394**, 549, 551, **552**

**Nerve or Nerves** (*contd.*)—
ilio-inguinal, 174, 382, 390, **394**, 549, 551, **552**
intercostal, 21, 29, 394
intercosto-brachial, 21, 167
intermediate dorsal cutaneous, of the foot, 260
cutaneous, of thigh, 175, 191, 197
interosseous, dorsal, 134-141, 146
volar, 108, 109, 110
last thoracic, 220, 383, 390, **394**, 398, 536, 549, 554
**lateral cutaneous**, of arm, 49, 56
of calf, 242, 260
of the forearm, 67
of thigh, 175, 183, 189, 220, 549, 552, 553
of thoracic nerves, 6, 21, 381-383, 394
to levator ani, 346, 348, 349
long thoracic nerve, 31
to longus colli, 31
lumbar, 551, 605
lumbo-inguinal, 175, 182, 183, 189, 393, 476, 478, 534, 549, 551, **553**
lumbo-sacral trunk, 551, 554, 601, 605
medial calcanean, 278, 284
**medial cutaneous**, of arm, 24, 67, 77
of calf, 237, 240, 278
of foot, 260
of forearm, 24, 67, 77
of thigh, 175, 191, 197, 278
**median**, **77**, 102, 104, 105, **107**, **119**
**musculo-cutaneous**, 78, 80
nervus furcalis, 551
**obturator**, 205, 210, **211**, 214, 245, 246, 309, 551, **554**, 593, 597, 598, 601, 624, 625
accessory, 551, 554
to obturator internus, 229, 607
palmar cutaneous, 95
to pectineus, 197
perforating cutaneous, 220, 347, 608
**perineal**, 347, 350, 351, 355, 360, 361, 362, 374, 375, 376
of fourth sacral, 346, 348, 349
of posterior cutaneous of thigh, 228, 343, 351, 605
phrenic, 538
communication with, 31

**Nerve or Nerves** (*contd.*)—
to piriformis, 230, 608
**plantar**, lateral, 294, **298**, 300, 302, 303, **304**
medial, 294, **296**, 300, 301
to popliteus, 240
**posterior cutaneous**, of the arm, 67
of the thigh, 220, 221, 226, **227**, 236, **239**, 246, 277, 347, **607**
pudendal, 229, 348, 361, **362**, 375, **606**
to quadratus femoris, 231, 607
**radial**, 67, 73, 75, 80, 82, 84, **85**, 136
to rectus femoris, 198
sacral, 230, 346, 347, 600, 601, 603, 605, 608
saphenous, 176, 194, **198**, **260**, 275, 278
to sartorius, 197
to scalenus anterior, 31
medius, 31
posterior, 31
**sciatic**, 226, **229**, 249, 605, **606**
scrotal, 343
spinal accessory. *See* **N.**, accessory
**splanchnic**, greater, 460, 515, 539
lesser, 515, 539
lowest, 515, 539
subscapular, 31, 32, 59
**superficial** peroneal, 260, 274, 275
ramus of radial, 87, 96, 98, 99
supraclavicular, 6, 48
suprascapular, 32, 58, 60
sural, 260, 277, 278
to tensor fasciæ latæ, 199
to teres minor, 56
thoracic, anterior, 13, 16, 17, 32
long, 18, 23, 32
thoracodorsalis, 19, 32
**tibial**, 229, **239**, 281, 282, **284**, 286, 287, 309, 606
**ulnar**, 75, **77**, 96, 105, **106**, **120**
deep branch, 120, 128, 129
dorsal branch, 96
superficial branch, 120
ulnar collateral, 87
vagus, 445, 460, 539
to vasti, 197, 198
volar digital, 119
Nipple, 9
Nymphæ. *See* Labia minora

Œsophageal opening of diaphragm, 538

Œsophageal orifice of stomach, 434
Œsophagus, 465, 470
Omental bursa, 445, 447, 448, **450**, 460, 461, 462, 463, 467, 491, 492, 501, 526, 530
**Omentum**, greater, 431, 435, 437, 439, **447**, 451, 452
lesser, 432, 435, 443, **445**, 448, 451, 467, 504, 519
Opening in adductor magnus, 242, 250
Organ of Rosenmüller, 644
**Orifice** of bladder, 570, 571, 588, 611, 632
cardiac, 434, 465
external, of urethra, female, 367, 634
male, 416, 578
ileo-cæcal, 490
pyloric, 509
of uterus, 637
Ostium abdominale of uterine tube, 643
Os uteri. *See* Orifice
Ovarian fimbria, 643
plexus, 484, 516, 647, **648**
**Ovary**, 598, **643**
fossa ovarica, 644
hilum, 644, 646, 647
ligament of, 622, 637, 639, **644**
posterior border, 644
relations, 644
suspensory ligament of, 621
tubal extremity, 644
uterine extremity, 644
Oviducts, 643
Ovula Nabothi, 648

Pacinian bodies, 120
Pad of fat, infra-patellar, 314
retro-public, 588, 631
**Palm**, 111
aponeurosis, 114, 115
cutaneous nerves, 87, 96, 97, 107, 119, 120
fascia. *See* aponeurosis *above*
flexor tendons and sheaths, 104, 123, 126
short muscles, 127, 128
surface anatomy, 111
surgical anatomy, 131
Palmar arch. *See* Arch, volar
Pampiniform plexus, 410, 646, 647,
**Pancreas**, 450, 460, 461, 467, 476, 478, 480, 481, 498, **500**, 504, 505, 513, 530, 540, 543
**Pancreas** (*contd.*)—
processus uncinatus of, 501, 505
tuber omentale, 502
Pancreatic duct, 499, 503
Pancreatico-duodenal plexus, 515
Panniculus adiposus (superficial fascia), of lower extremity, 169, 218, 245
of upper extremity, 5
abdominal wall, 378
back, 38
perineum, 342
Papilla duodeni, 503, 505
Papillæ of kidney, 533
Paraduodenal fossa, 474
Parametrium, 639, 647
Pararectal fossa, 559, 584
Para-urethral ducts, 634
**Paroophoron**, 623
Patellar plexus, 177, 191
synovial fold, 315
Pectiniform septum, 579
**Pectoral region**, 4
axilla, 13. *See also* Axilla
cutaneous nerves and arteries, 16, 19, 22, 26, 28
fascia, 10
mammary gland, 8
muscles, 12, 17, 27
surface anatomy, 4
**Pelvic colon**, 439, 534, 557, 587, 598, 620
fascia. *See* Fascia, pelvic
parietal. *See* Fascia, pelvic
rectal layer, 582, 585, 629
recto-vaginal layer, 629, 645
recto-vesical layer, 566, 587, 596
relation of vessels and nerves, 581
vesical layer, 566, 587, 596
visceral. *See* Fascia, vesical
white line, 604
**Pelvis, male**, 555
articulations, 612
blood-vessels, 557, 598
cavity, 429
contents of, 557
diaphragm, 347, 427
fascia. *See* Fascia, pelvic
floor, 452, 583
major, 556
minor, 556
viscera, 556
**female**, 619
blood vessels, 646

**Pelvis, female** (*contd.*)—
contents of, 619
floor, 626, 629
general position of viscera, 620
segments of, 630
of kidney, 532
peritoneum, 557, 620
spinal nerves, 598, 600, 605, 649
sympathetic nerves, 609
**Penis**, 351, **352**, 354, 357, **416**, **579**, 609
structure of, 579
septum pectiniforme, 579
**Perineal** body, 371, 629, 645
triangle, 356, 369
**Perineum**, 340
anal triangle, 341, 345, 369
body, 371, 629, 645
boundaries, 340
central point, 355, 370
fascia, 342, 368
female, 364
ischio-rectal fossa, 346
male, 340
muscles, deep, 359, 375
superficial, 346, 354, 370
surface anatomy, 340, 364
urogenital triangle, 341, 349, 369
**Peritoneum**, 432, 458
bursa omentalis, 450. *See also* Bursa
fossæ, 474
large sac, 445, 451
lateral gutters of, 455
ligaments, 435, 447, 451, 458, 495, 513, 567
mesenteries, 438, 455, 472, 473, 499, 540, 543
omenta, 445, 447, 458
parietal, 458
pelvic, 557
vertical gutters of, 454
visceral, 458
Peroneal septa, 262
Petit's lumbar triangle, 418
Peyer's patches. *See* Aggregated lymph nodules
Phrenico-colic ligament, 436, 454, 495, 513
**Plane**, intertubercular, 429
lateral, 430
subcostal, 429
transpyloric, 469, 496
vertical 430
Plantar arch, 303
Platysma, 5
Pleural cavity, 531
**Plexus or Plexuses**, aortic, 476, 484, **515**, 540, 550
**brachial**, 28
branches of, 31
divisions of, 30
relations of, 30
coccygeal, 598, **608**, 649
cœliac, 460, 461, 482, 484, **514**
diaphragmatic, 515
gastric, 515
hæmorrhoidal, of nerves, 608
venous, 602
hepatic, 447, 515
hypogastric, 484, 516, 608
lienal, 515
lumbar, 551
mesenteric, inferior, **484**, 516
superior, 479, **481**, 515
obturator, 197, **212**
ovarian, 484, 516, 647, **648**
pampiniform, 410, 646, 647
pancreatico-duodenal, 515
patellar, 177, 191
pelvic, 605, 625
pelvic, sympathetic, 608
phrenic, 515
prostatic, of nerves, 609
of veins. *See* Pl., pudendal
prostatico-vesical, 595
pudendal, of nerves, **605**, 649
of veins, 417, 595, 602
renal, 484, 515
sacral, 598, 600, **605**, 649
pudendal band of, 606
sciatic band of, 606
sartorial, 197, **212**
solar. *See* Pl., cœliac
spermatic, 484, 516
venous. *See* Pl., pampiniform
subtrapezial, 45
suprarenal, 515
uterine, 648
venous, 647
vaginal, 647, 648
venous, 629, 647
vesical, 608
venous, 602, 647
Plica vesicalis transversa, 561
Plicæ circulares, intestinal, 486, 488
palmatæ uteri, 648
umbicales, 421
Pons hepatis, **522**
Popliteal fascia, 178, **236**

**Popliteal fossa**, 234
boundaries, 235, 237
contents, 235, 236
floor, 239
in section, 239
surface anatomy, 235
Porta hepatis, 443, 445, 447, 498, 505, **519**, 520, 522
Portal canal, 522
**Pouch**, perineal, 343, 352
recto-genital, 559, 584, 587
recto-uterine, 457, 623
recto-vaginal, 645
recto-vesical, 457
utero-vesical, 457, 623
Præputium clitoridis, 365
Prepuce, 417
Prevertebral plexuses, 476, 484, 515, 540, 550
Processus vaginalis, 408, 409, 420, 423
**Prostate**, 364, 567, 568, 575, **593**, 609
capsule, 595
'middle lobe,' 577, 596, 611
position, 594
sheath, 594
Prostatic ducts, 575
plexus, 609
venous. *See* Pl., pudendal
sinus, 575
Pudendal band of sacral plexus, 606
cleft, 365
**Pyloric** antrum, 468
canal, 468, 509
orifice, 509
valve, 437, 509
vestibule. *See* antrum *above*
**Pylorus**, 434, 466, 498, 501
position of, 469, 470
sphincteric ring, 510

Quadrate lobe of liver, 498, 520
Quadrilateral space of shoulder, 51, 55

**Rami communicantes**, 550
grey, 550
white, 550
Rectal channel, 532
Rectal triangle. *See* Anal, 369
Recto-genital pouch, 559, 584, 587
Recto-uterine pouch, 457, 623
Recto-vaginal pouch, 645
Recto-vesical pouch, 584
**Rectum**, 440, 556, **582**, 610, 620
ampulla of, 584
columns, 602, 610
flexures, 584
interior, 610
lymph vessels of, 603
peritoneal relations of, 584
plicæ transversales, 584, 610
structure, 609, 649
valves, 610
**Regions**, anterior crural, 259
anterior, of knee, 168
anterior, of thigh, 166
epigastric, 431
gluteal, 215
hypochondriac, 431
hypogastric, 431
iliac, 431
inguinal, 166
lateral crural, 273
lateral, of thigh, 168
lumbar, 431
medial crural, 275
of thigh, 166
posterior crural, 276
subinguinal, 166
trochanteric, 167
umbilical, 431
Renal plexus, 484, 575
Rete testis, 414, 515
Retinacula of hip-joint, 256
peroneal, 262, 274
Retro-colic fossæ, 474, 489
Retro-pubic pad, 588, 631
Retzius, cave of, **561**, 570, 587, **624**, 626, 631
Rima pudendi, 365
**Ring**, abdominal inguinal, **402**, 404, 410, 420, 422, 424, 639
femoral, **185**, 424, 425, 600
subcutaneous inguinal, 377, **386**, 394, 420

Sac, vulvo-scrotal, 369
Sacro-genital fold, 457, **558**, 559, 561, 596, 591
Sacro-sciatic foramen. *See* Sciatic
Santorini, duct of, 503
Sartorial plexus, 197, 212
Scapula, arterial anastomosis around, 64
Scapular region. *See* Shoulder, 48
Sciatic band of sacral plexus, 608
foramina, 226, 227, 229, 230, 231, 233, 600, 601, 606, 607, **617**
hernia, 581

Scrotum, 406
Semilunar cartilages. *See* Menisci
fold of Douglas. *See* Linea semicircularis, 399
ganglion. *See* Cœliac, 460, 514, 543
Seminiferous tubules, 415
**Septa**, intermuscular, of arm, 71
of leg, 262, 279
of sole, 292
of thigh, 178, 201
peroneal, 262
Septum femorale, 185, 425
pectiniforme, 579
**Sheath**, axillary, 15, 19, 23
femoral, 178, **182**, 389, 402
of flexor tendons of foot, 292, 294, 299
of hand, 131, **222**
of prostate, 594
of rectus abdominis, 398, 399
*Seminal Vesicles*. *See* Vesiculæ Seminales
**Shoulder**, 48
cutaneous nerves, 48
fascia, 50
intermuscular spaces, 51
joint and ligaments, 88, 94
muscles, 50, 52, 56, 58, 59
parts beneath deltoid, 52
surface anatomy, 2, 4
**Sinus** epididymidis, 413
of kidney, 528, 532, 542
lactiferi, 9
pocularis. *See* Utriculus prostaticus
of portal vein, 523
prostatic, 575
of rectum, 610
Skene's tubules, 634
Solar plexus. *See* Plexus, cœliac
**Sole of foot**, 289
cutaneous nerves, 296, 298
fascia, 289, 291
first layer of muscles, 293
fourth layer of muscles, 306
intermuscular septa, 292
second layer of muscles, 298
third layer of muscles, 301
Solitary lymph nodules, 487, 488, 494
**Spermatic** cord, 170, 377, 386, 389, 392, 404, **407**
parts of, 409
plexus, 484, 516
vein, 410, 503, 542
Spigelian lobe of liver. *See* Caudate lobe
**Spleen**, 435, 467, **511**, 526, 530
lienal plexus, 515
structure of, 513
variations in shape, 513
**Stomach**, 434, **464**, 530
blood-vessels, 464
body, 468
cardiac opening, position of, 470
cardiac part, 465
fundus, 434, 465, 468
greater curvature, 434, 467
incisura angularis, 468
lesser curvature, 434, 467
position, 465, 468
pyloric part, 434, 466
structure, 506
**Stomach-bed**, 435, 467, 501
Subacromial bursa, 52
Subcostal plane, 429
Subscapular bursa, 91
Sulcus, gluteal, 216
Superficial fascia. *See* Panniculus adiposus
Supraclavicular nerves, 5
**Suprarenal glands**, 450, 460, 467, 501, 503, 514, **524**, 525, 529, 530, 543
plexus, 515
**Surface anatomy, abdomen**, 376, 430
**lower extremity**, 166, 188, 216, 218, 235, 257
**upper extremity**, 2, 35, 62, 111, 131
Surgical anatomy of psoas fascia, 548
**Sympathetic trunk**, 478, 500, 539, 540, 549, **550**, 597, 598, 601, 649
**Sympathetic ganglia**, 550, 608, 609
plexuses, 514
rami communicantes, 550, 608, 609
**Sympathetic** nerves to testis, 410
cavernous nerves to penis, 609
to levator ani, 609
to prostate, 609
to rectum, 598
**Symphysis ossium pubis**, **618**, 629, 650

Tænia coli libera, 438, 493, 495
meso-colica, 438, 493, 495
omentalis, 438, 493, 495

Tarso-metatarsal articular surfaces, 337
Tendo calcaneus, 280, 281
Tendon, conjoined. *See* Falx inguinalis
Tendons, extensor, of the fingers, 145
**Testis**, 393, 411
  body, 412
  descent, 408
  epididymis, 413
  gubernaculum, 409
  lobules of, 415
  structure, 414
Thenar eminence, 111
**Thigh**. 166
  adductor muscles, 205
  anterior aspect, 166
  cutaneous nerves, 197, 218, 227, 240, 246
  external rotator muscles, 230, 232, 234
  fascia, 169, 177, 178, 183, 199, 221, 236, 246
  femoral trigone, 188
  hamstring muscles, 246
  intermuscular septa, 179, 201
  medial aspect, 204
  osteo-fascial compartments, 193
  posterior aspect, 245
  superficial veins, 174
  surface anatomy, 166, 235
Thoracic duct, 538, 547
Thyroid membrane. *See* Obturator membrane
Toes, flexor sheaths, 299
Torus uterinus, 623
  vesicalis, 573
Tract, ilio-tibial, 168, 177, 199
**Triangle**, anal, 341, 345, 369
  of base of bladder, 573, 597
  deltopectoral. *See* Infraclavicular fossa
  of Hesselbach, 403, 404
  lumbar, 418
  perineal, 356, 371
  of Scarpa. *See* Trigonum femorale
  urogenital, 341, 349, 369
    pouches of, 343, 352
Triangular fibro-cartilage of wrist. *See* Discus articularis, 156
  space at elbow, 81
  space of shoulder, 52
**Trigone** of bladder, 571, **572**, 611, 632
Trigonum femorale, 188
Trigonum lumbale Petiti, 418
Trunk, lumbo-sacral, 551, 554
  sympathetic, 478, 500, 539, 540, 549, **550**, 597, 598, 601, 609, 649
**Tube, Fallopian**. *See* Uterine tubes, 598, 621, **643**, 646, 647
Tuber omentale, 467, 520
Tubules, seminiferous, 425
  Skene's, 634
Tunic, abdominal, 380
Tunica albuginea, 414
  vaginalis, 392, 407, 411
    development, 408
  vasculosa testis, 414

**Umbilical** fissure, 443
  folds, 421, 561, 621
  hernia, 426
  notch of liver, 443
  region, 430
  zone, 430
**Umbilicus**, 377, 399, 426, 506
Upper extremity, parts of, 1
  surface anatomy, 2
Urachus, 421, 426, 561, 587, 590, 611, 631
**Ureter**, 474, 476, 478, **534**, 557, 562, 573, **592**, 593, 597, 624, 625, 633, **634**, 641, 644, 646
  female, 635, 641, 644, 646
Ureteral orifices of bladder, 573
**Urethra**, 574
  aperture in inferior fascia of the urogenital diaphragm for, 358, 374
  bulb of, **353**, 357, 416, 577, 578
  corpus cavernosum of, 575, 577
  direction of canal, 575, 578
  external orifice, 367
  female, 367, 374, 634
  membranous, 351, 359, 360, 575, **577**, 586
  mucous membrane, 575, 577, 578
  prostatic, 575
Urethral orifice of bladder, 570-571, 588, 611, 632
Urogenital diaphragm, 341, 343, 347, **351**, **359**, 374, **375**
  fissure, 365
  triangle, 341, 349, 369
Uterine plexus, 648
  venous, 647

**Uterine tubes**, 598, 621, **643**, 646, 647
ampulla, 643
fimbriæ, 643
fimbria ovarica, 643
infundibulum, 643
isthmus, 643
ostium abdominale, 643
structure of, 649
Utero-sacral fold, 623
**Uterus**, 440, **636**
body, 636
broad ligaments, 440, **621**
cavity, 637
cervix, 637
portio vaginalis, 637
supra-vaginalis, 637
external orifice, 637
internal orifice, 637
isthmus, 637, 646
position, 638, 639
round ligament, 386, **388**, 403, 545, 623, 637, **639**
structure, 648
wall, 648
Uterus masculinus, 576
Utriculus prostaticus, 576
Uvula vesicæ, 573

**Vagina**, 367, 374, 624, 625, 629, 635, **641**, 649
coats of, 649
columnæ rugarum, 649
relations of, 642
Vaginal orifice, 642
plexus, 629, 647, 648
**Valve** of the colon, 490
of Heister, 444
pyloric, 437, 509
Valves, anal. *See* Plicæ transversales recti, 580, 610
Valvula pylori, 437
Valvulæ conniventes. *See* Plicæ circulares
Vasa efferentia. *See* Ductuli
Vater, ampulla of, 503, 505
**Vein or Veins**, axillary, 16, 17, 23, 26
ascending lumbar, 547, **555**
azygos, 339, 540, **547**
basilic, 73
cephalic, 11, 16, 69
circumflex iliac, deep, 545
superficial, 171, 384
coronary, of stomach, 460, 462, 506
**Vein or Veins** (*contd.*)—
cystic, 463, 505, 506
dorsal, of clitoris, 374, 376, 628, 647
of penis, 359, 417, 595, 602
epigastric, inferior, 393, 402
femoral, 191, 196
gastric, 506
gastro-epiploic, left, 506
right, 463
hæmorrhoidal, 593
inferior, 603
middle, 603
superior, 603
hemiazygos, 539, **547**
hepatic, 516, 523
hypogastric, 545, 546, 562, 593, 598, **603**, 625, 647
iliac, common, 476, 543, **544**, 546, 602
external, 545, **546**, 598
ilio-lumbar, 545, 602
lateral sacral, 601
lumbar, 543, 550, 555
ascending, 547, 555
median, of the forearm, 69
median-basilic, 69
median-cephalic, 169
mesenteric, inferior, 478, **484**, 503, 583
superior, 463, 476, 479, **481**, 505, 506
obturator, 562, 593
ovarian, 542, 647
pampiniform, 410, 646, 647
pancreatico-duodenal, 463
para-umbilical, 506
of pelvis, 602
phrenic, 541
popliteal, 243, 245
portal, 445, 447, 462, 463, 481, 501, 504, **505**, 523, 543
profunda, 69
pudendal, 567, 570, 595, 603
radial, 98
renal, 499, 500, 540, **542**
sacral, middle, 545, 602
saphena magna, **174**, 176, 259, 275, 276
saphena parva, 236, 259, **277**
spermatic, 410, 503, 542
splenic, 478, 503, 505, 506, 540
superficial, of arm, 69
of elbow, 69
of foot, 294
of forearm, 94

**Vein or Veins** (*contd.*)—
superficial (*contd.*)—
of leg, 243, 258, 259
of lower limb, 176, 243
suprarenal, 525, 541
thoraco-acromial, 25
ulnar, 105
umbilical, 377, 426, 506, 598
uterine, 647
vaginal, 647
vesical, 562
Vena cava inferior, 474, 476, 499, 505, **543**, 550
fossa for, 489, 518, 519, 521, 522
Vena-caval opening of diaphragm, 538
Vermiform process, 439, 489
structure of, 494
valve of, 491
Vesical plexus, 608
venous, 602, 647
Vesiculæ seminales, 556, 567, 568, 587, 593, **596**, 597
excretory duct of, 597
Vesicular appendix, 645
Vestibular glands, 368, 375
Vestibule of vulva, 367, 374
bulb of, 371
Villi intestinales, 486, 487
Vincula accessoria. *See* V. tendinum *below*
brevia, 125
longa, 125
tendinum, 124
Vulva, 364
Vulvo-scrotal sacs, 369

White line of pelvis, 604
Whitlow, 131
Winslow, foramen of. *See* Foramen epiploicum
Wirsung, duct of, 503
**Wrist**, 110, 142, 143, 144
anterior aspect, 110, 142
discus articularis, 156
dorsum, 143, 144
joint, 152
lig. carpi volare, 116, 122

Zona orbicularis, 253
**Zone**, costal, 430
hypogastric, 430
umbilical, 430

THE END

*Printed by* R. & R. Clark, Limited, *Edinburgh.*